

MGMT Promoter Methylation and Parathyroid Carcinoma

Sara Storrvall,¹ Eeva Ryhänen,¹ Ikka Heiskanen,² Tiina Vesterinen,³ Frank V. Bensch,⁴ Jukka Schildt,⁵ Soili Kytölä,⁶ Auli Karhu,^{6,7,8} Johanna Arola,³ and Camilla Schalin-Jääntti¹

¹Department of Endocrinology, Abdominal Center, University of Helsinki and Helsinki University Hospital, Helsinki FI-00290, Finland; ²Department of Surgery, Abdominal Center, University of Helsinki and Helsinki University Hospital, Helsinki FI-00290, Finland; ³Department of Pathology, HUSLAB, University of Helsinki and Helsinki University Hospital, Helsinki FI-00290, Finland; ⁴Department of Radiology, University of Helsinki and Helsinki University Hospital, Helsinki FI-00250, Finland; ⁵HUS Medical Imaging Center, Department of Clinical Physiology and Nuclear Medicine, University of Helsinki and Helsinki University Hospital, Helsinki FI-00290, Finland; ⁶Laboratory of Genetics, HUSLAB, Helsinki University Hospital, Helsinki FI-00290, Finland; ⁷Department of Medical and Clinical Genetics, University of Helsinki, Helsinki FI-00290, Finland; and ⁸Department of Applied Tumor Genomics, Research Programs Unit, University of Helsinki, Helsinki FI-00290 Finland

ORCID numbers: 0000-0002-2428-0161 (C. Schalin-Jääntti).

Context: Parathyroid carcinoma (PC) is extremely rare. Prognosis is poor, with no known evidence-based systemic therapies. We previously reported complete remission in a patient with metastasized parathyroid carcinoma and high tumor *MGMT* promoter methylation status who was treated with temozolomide.

Objective: To study *MGMT* promoter methylation status in an additional set of aggressive parathyroid tumors.

Design/Setting: The study included 12 patients: 7 with sporadic and 5 with familial primary hyperparathyroidism (two of the latter carried a *CDC73* gross deletion). Patient 9 is the previously described patient with PC and high *MGMT* methylation status. Her daughter (patient 12) had surgery for severe primary hyperparathyroidism due to atypical parathyroid adenoma during pregnancy. Eleven patients thus had PC and one had atypical parathyroid adenoma. *MGMT* promoter methylation status was determined from DNA extracted from primary (n = 10) or metastatic (n = 2) tumors. A mean methylation level >20% was considered high. Patient 11 had metastatic PC and received temozolomide cycles.

Results: Only the previously published patient (patient 9) had high tumor *MGMT* promoter methylation status. This was not a characteristic of the atypical parathyroid adenoma of the daughter (patient 12). Patient 11 (*CDC73* intragenic deletion) has disseminated PC, low *MGMT* promoter methylation, and stable disease on follow-up after temozolomide treatment.

Conclusion: High *MGMT* promoter methylation status seems rare in PC. However, as demonstrated in other neuroendocrine tumors, some patients with disseminated PC might benefit from temozolomide. Demonstration of high methylation status could be a predictor of positive response to temozolomide treatment.

Copyright © 2019 Endocrine Society

This article has been published under the terms of the Creative Commons Attribution Non-Commercial, No-Derivatives License (CC BY-NC-ND; <https://creativecommons.org/licenses/by-nc-nd/4.0/>).

Freeform/Key Words: parathyroid carcinoma, treatment, *MGMT* promoter methylation, temozolomide

Abbreviations: FFPE, formalin-fixed, paraffin-embedded; NET, neuroendocrine tumor; PC, parathyroid carcinoma; PHPT, primary hyperparathyroidism; TEM, temozolomide.

Parathyroid carcinoma (PC) is an extremely rare malignancy and therefore difficult to diagnose. PC cannot be confirmed before surgery because no specific biomarkers are available. PC underlies 1% of primary hyperparathyroidism (PHPT) cases and should be suspected in patients with biochemically severe disease, often kidney and bone manifestations [1]. However, there are reports of increasing incidences in Australia, the United States, and Europe [2–4]. Reported recurrence rates are 20% to 50%, and 5-year survival in patients with metastatic disease is <50% [5–7]. Radical primary surgery is the only curative treatment and is the first-line therapy also for recurrent disease.

The prognosis for inoperable disease is especially poor because no effective systemic therapies have been identified so far. There are some reports of treatment responses to external radiotherapy and anecdotal case reports of successful response to dacarbazine (an alkylating agent), sorafenib (a multikinase inhibitor), and immunotherapy with intradermal injections of synthetic human and bovine PTH peptide fragments [8–12]. Patients with metastatic PC usually die of severe hypercalcemia and renal insufficiency rather than of the tumor burden itself [1].

We recently reported a case of recurrent, disseminated PC with complete remission in response to repeat surgery, temozolomide (TEM), external radiotherapy, cinacalcet, and bisphosphonates [13]. This patient's PC demonstrated high O6-methylguanine DNA methyltransferase (*MGMT*) promoter methylation status. High *MGMT* promoter methylation is a known predictor of positive treatment response to TEM in other neuroendocrine tumors, such as aggressive pituitary tumors [14] and pancreatic neuroendocrine tumors (NETs) [15, 16]. The *MGMT* enzyme is a DNA-repairing enzyme that counteracts the DNA-damaging effects of alkylating agents, such as TEM. Silencing of the *MGMT* gene by promoter methylation enhances the cytotoxic effects of TEM [17]. *MGMT* promoter methylation status has not been systematically investigated in PC, except for the one previously reported case [10].

Our aim here was to investigate whether high *MGMT* promoter methylation status is common in aggressive parathyroid tumors by studying an additional set of PCs (n = 11, including tumor tissue from the previously described patient with PC, patient 9) and one atypical parathyroid adenoma (this patient with APA is the daughter of the previously described patient 9) and corresponding patient characteristics and outcomes. We also describe treatment with TEM, external radiotherapy, cinacalcet, and denosumab in another patient with metastasized PC, who had an underlying *CDC73* mutation and low tumor *MGMT* promoter methylation status.

1. Materials and Methods

A. Patient Cohort

The study cohort consists of 12 patients with PC (n = 11) and 1 patient with atypical parathyroid adenoma (patient 12), all diagnosed, operated on, and treated at the Department of Endocrinology, Helsinki University Hospital between 1993 and 2018. The successful combined treatments of patient 9 (including TEM cycles for 1 year), resulting in complete remission, have been previously described [13].

Patient data and laboratory results were obtained from the electronic patient record database at the Helsinki University Hospital in November 2018. Patient 11 was followed until the end of May 2019. All biochemical measurements were performed with in-house methods at HUSLAB, the central laboratory of our hospital. The most recent serum ionized calcium (normal range, 1.16 to 1.3 mmol/L at a pH of 7.4) and fasting plasma PTH (normal range, 15 to 70 ng/L) concentrations, as well as detailed information on therapies and recurrences, were retrieved from our electronic patient files. All histopathological characteristics of the tumors were reviewed by an expert parathyroid pathologist.

The Helsinki University Hospital Ethics Committee and the Finnish National Supervisory Authority for Welfare and Health (Valvira) (Dnro 8031/06.01.03.01/2015) approved the study. The patients have given their informed consent for participation in this study.

B. MGMT Promoter Methylation and CDC73 Gene Mutation Status

MGMT promoter methylation status was determined from formalin-fixed, paraffin-embedded (FFPE) tumor tissue excised at primary surgery (n = 10) or from a metastatic lesion (n = 2, patients 9 and 11). A mean methylation level >20% of all investigated CpGs was considered methylated.

Tumor DNA for determination of *MGMT* promoter methylation status was isolated by using GeneRead DNA FFPE Kit (Qiagen, Hilden, Germany), optimized for isolation of DNA from FFPE tissues. The quantity and quality of DNA were assessed by using NanoDrop 8000 Spectrophotometer (ThermoFisher Scientific, Waltham, MA). DNA concentrations were 300 to 1000 ng/ μ L per sample, and A260/A280 ratios in the range of 1.8 to 2.0 were considered satisfactory for purity standards. Unmethylated cytosine residues were converted to uracils by sodium bisulfite treatment of DNA (EpiTect Bisulfite Kit, Qiagen, Hilden, Tyskland), whereas methylated residues were left unchanged. Methylation of the five CpGs and one control CpG was analyzed in duplicated reactions by a cyclic minisequencing after PCR [18]. One negative and two positive (high, low) controls were used in each run to confirm successful PCR and calculate cutoff values for automated genotype calling from 20 previous test runs.

CDC73 mutation status was determined as previously described [2]. None of the patients had multiple endocrine neoplasia type 1 based on genetic screening and/or the absence of multiple endocrine neoplasia type 1 manifestations on clinical follow-up. Next-generation sequencing of a PHPT gene panel (*AIRE*, *AIP*, *APC*, *CDC73*, *CDKN1A*, *CDKN1B*, *CDKN2B*, *CDKN2C*, *GCM2*, *GNA11*, *MEN1*, *PTH*, and *RET*) was introduced as a standard procedure in our clinic in 2016 and thus was performed among the patients diagnosed in 2016 and later (patients 1 and 2), with negative results.

2. Results

The clinical characteristics of the 12 patients are given in Table 1. Five are female and 7 are male, and the age at diagnosis ranged from 17 to 76 years. Four patients (patients 6, 8, 9, and 11) have been treated for local recurrent PC or distant metastases. All patients except patient 11 are in remission at the time of this report (serum ionized calcium < 1.30 mmol/L). Patients 4 and 9 through 12 are characterized by familial PHPT. Patient 1 underwent neck exploration and parathyroidectomy because of tertiary hyperparathyroidism due to focal segmental glomerulosclerosis and end-stage renal failure. Histopathological diagnosis was parathyroid carcinoma of the right lower parathyroid, atypical adenoma of the right upper parathyroid, and hyperplasia of both left parathyroids. Patient 5 was diagnosed with gonadal dysgenesis (46XY/45X0) at birth. Patient 12 was diagnosed with severe PHPT during pregnancy and is the daughter of patient 9; her PHPT was due to an atypical parathyroid adenoma (Tables 1 and 2).

Data on familial PHPT, *CDC73* gene mutation status, affected parathyroid glands, histopathological criteria of PC, and Ki67 and parafibromin staining are given in Table 2. All tumors except that from patient 9 (the previously published case [13]) had low tumor *MGMT* promoter methylation status.

A. Surgery, TEM, and Other Adjuvant Treatments in a Patient With a CDC73 Mutation, Disseminated PC, and Low MGMT Methylation Status

Patient 11 was diagnosed with severe PHPT due to PC in 1993 at age 32 years. He carries a *CDC73* gross deletion of exons 1 to 10, as previously reported [18]. Parafibromin staining was negative and Ki67 was 20% (Table 2). He was not cured by primary surgery and has been operated on several times because of metastases in the neck and in the vicinity of the thoracic spine. At the end of 2017, his serum ionized calcium (1.45 to 1.69 mmol/L) and PTH (786 ng/L) concentrations again increased. The underlying lesion was difficult to localize, and the patient underwent planar scintigraphy with ^{123}I 99mTc-sestamibi, ^{18}F -fluorodeoxyglucose

Table 1. Patient Characteristics

Patient No.	Sex	Year of Primary Surgery	Age at Diagnosis (y)	Ionized Calcium at Diagnosis (mmol/L)	PTH at Diagnosis (ng/L)	Current Ionized Calcium (mmol/L)	Current PTH (ng/L)	Recurrent Disease
1	F	2016	25	1.35	2207	1.23	132	No
2	M	2018	76	2.11	2389	1.21	82	No
3	F	2014	49	2.08	576	1.22	75	No
4	M	2008	17	1.76	1187	0.81	16	No
5	M	2004	35	2.58	4000	1.21	93	No
6	M	2009	45	1.88	358	1.18	56	Local recurrence 2012, reoperation + left lobectomy
7	F	2010	61	2.71	3300	1.21	60	No
8	M	2007	42	1.5	178	1.19	97	Recurrent PHPT in 2014, reoperation: left lower parathyroid: hyperplasia or adenoma
9	F	2001	48	2.16	2020	1.05	31	Previously published: recurrent, disseminated disease
10	M	2011	18	1.88	693	1.15	108	No
11	M	1993	32	3.96 (total serum calcium)	1830	1.62	450	Persistent, disseminated disease
12	F	2008	33	1.96	823	1.19	91	No

Abbreviations: F, female; M, male.

positron emission tomography and 11C-methionine positron emission tomography/MRI. MRI confirmed a recurrent metastasis in vertebra C6 (Fig. 1A) and a 3-cm tumor in the right kidney (Fig. 1B) that proved to be papillary type 1 renal carcinoma. *MGMT* methylation status, determined from the metastatic lesion resected in March 2018, was low (Table 2).

The patient was treated with TEM cycles (280 mg for 5 days, with 28-day intervals) between March and October 2018, cinacalcet, zoledronic acid 4 mg every 4 weeks, and external radiotherapy of the C6 metastatic lesion.

In October 2018, CT demonstrated growth of the C6 metastasis (Fig. 1C) and lung metastases. TEM treatment was subsequently stopped. Zoledronic acid was replaced by denosumab 120 mg every 4 weeks, and cinacalcet was discontinued in March 2019 because of nausea. In January 2019, thoracic CT demonstrated stable disease, with minor tumor shrinkage. As of May 2019, the serum ionized calcium was 1.62 mmol/L and creatinine level was 117 μ mol/L. This patient is also the uncle of patient 10, who was diagnosed with severe PC at age 18 years and carries the same *CDC73* gross deletion [18]. This patient had two abnormal parathyroids and low *MGMT* promoter methylation of the PC (Table 2).

3. Discussion

We studied *MGMT* promoter methylation status in aggressive parathyroid tumors from 12 (11 with PC and 1 with atypical parathyroid adenoma) well-characterized patients operated on for PHPT; this has not previously been done in any series of PC/aggressive parathyroid tumors before. High *MGMT* methylation status was found in only one of these tumors

Table 2. Details on Familial PHPT, CDC73 Germ-Line Mutations, Histopathological Tumor Characteristics, and MGMT Promoter Methylation Status

Patient No.	Familial Disease	CDC73 Germline Mutation	Location of Tumor	Diagnosis	Ki-67 (%)	Paraffin Stain	MGMT Promoter Methylation
1	No	No	Right lower parathyroid; right upper parathyroid; left parathyroids	Atypical adenoma; carcinoma (vascular invasion); hyperplasia	APA: 10, PC: 15	Unreliable, with negative spots	Low
2	No	No	Right lower parathyroid	Carcinoma (vascular invasion)	3	Negative	Low
3	No	No	Right lower parathyroid	Carcinoma (vascular invasion)	10	Negative	Low
4	Aunt	No	Left and right lower parathyroids; right upper parathyroid	Carcinoma (vascular and capsular invasion); hyperplasia or metastasis	5	Positive	Low
5	No	No	Right lower parathyroid	Carcinoma (invasion of vasculature and surrounding tissue)	10	Positive	Low
6	No	No	Left upper parathyroid	Carcinoma (vascular invasion)	10	Negative	Low
7	No	No	Left upper and right lower parathyroids	Both carcinoma (invasion in surrounding fat tissue)	20	Positive	Low
8	Yes	No	Left upper parathyroid; right upper parathyroid	Carcinoma (capsular and vascular invasion); hyperplasia	5	Positive	Low
9	Daughter and brother	No	Primary tumor not available	Metastasis	10	Negative	High, 35%
10	Several	Gross deletion (exons 1–10)	Right upper parathyroid; left upper parathyroid	Carcinoma (vascular invasion); atypical adenoma	8	Negative	Low
11	Several	Gross deletion (exons 1–10)	Primary tumor not available	Metastasis	20	Negative	Low
12	Mother and uncle	No	Left Lower left parathyroid	Atypical parathyroid adenoma	5	Focal positive spots	Low

Abbreviation: APA, atypical parathyroid adenoma.

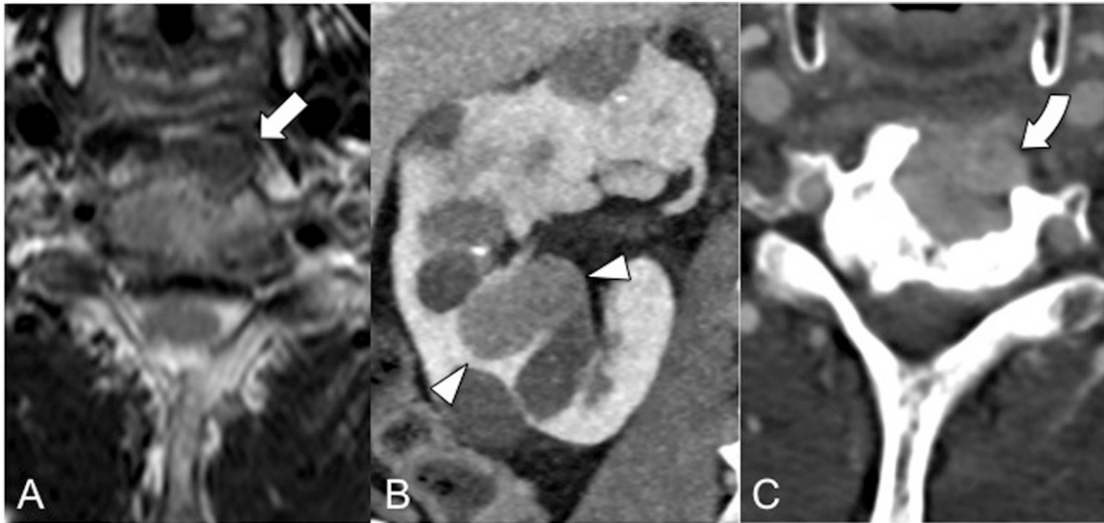


Figure 1. (A) 1.5-T axial plane T2-weighted MRI demonstrating a metastatic soft tissue mass in the left anterolateral cortex of C6 (straight arrow). (B) Contrast-enhanced CT scan in coronal plane of the right kidney shows multiple cortical cysts and a solid tumor mass (arrowheads). (C) Contrast-enhanced CT scan in axial plane reveals marked growth of the C6 metastatic mass, which has caused a large lytic cortical lesion (curved arrow).

(patient 9), as previously described [10]. High *MGMT* promoter methylation is a known predictor of positive treatment response to TEM in other NETs, such as aggressive pituitary tumors and pancreatic NETs [14–16].

All parathyroid tumors underwent careful histopathological examination by our expert parathyroid pathologist. In addition, all patients are under regular follow-up and have been treated accordingly for possible recurrent PHPT in our institution. In patient 1, PC may have been driven by proliferation of parathyroid cells due to tertiary hyperparathyroidism and underlying end-stage renal failure, as describe by Miki et al [19]. We wanted to include both familial and sporadic cases of PC to explore whether these factors could be related to *MGMT* promoter methylation status. Some of the familial cases may represent phenocopies. For patient 9, who had PC and high *MGMT* methylation status, and her daughter (patient 12), the underlying gene defect has not been identified. For instance, possible *GCM2* mutations have not been ruled out. *MGMT* methylation was also low in the atypical adenoma of the daughter, revealing distinct methylation reprogramming of *MGMT* promoter in the tumor of this first-degree relative. According to the current study, the *MGMT* gene promoter is thus supposedly not regularly methylated in aggressive parathyroid tumors. However, because PC is very rare, only 12 patients/tumors were included in the present series. It is difficult to gather a large enough PC cohort for more comprehensive analyses. Considering the prevalence of PC, our patient cohort is of reasonable size.

There are different methods of assessing *MGMT* methylation status. Although immunohistochemistry is the simplest and cheapest method, it does not correlate well with other methods or with clinical treatment response to alkylating agents [20]. Bisulfite treatment methylation-specific PCR, as used in our study, is considered the gold standard because it gives quantitative information on *MGMT* methylation status [21]. It is, however, possibly associated with inaccurate results because only a few CpG methylation sites are analyzed. In addition, promoter methylation status of tumors with variable methylation status of specific CpG sites might be falsely considered low [20]. With the cycling minisequencing method used, false results have been minimized by using duplicate reactions, controls, and follow-up of results from previous runs. Because different PCR assays can yield different results, the specificity and sensitivity depend on the method used. For the current study it depends on the PCR protocol [22].

Methylation-specific PCR, with its high sensitivity, is widely used for assessing *MGMT* methylation in the research setting but suffers from increased false-positivity. Pyrosequencing is considered the most accurate and robust method for determining *MGMT* methylation status [23, 24]. With FFPE DNA, there is a risk of false-positive or false-negative results, especially when the DNA quality and/or quantity is low [25]. We tried to avoid inaccurate results by isolating DNA with a method designed for FFPE material and used only specimens with good DNA concentrations and satisfactory purity (260/280 1.8 to 2.0).

The *MGMT* gene is epigenetically inactivated by promoter hypermethylation in ~40% of primary glioblastomas [26], in which *MGMT* methylation is associated with improved overall survival [27]. Owen *et al.* [28] studied *MGMT* expression in gastroenteropancreatic NETs as well as in NETs originating from the lung and thymus. At 2 years, patients with low *MGMT* protein expression on immunohistochemistry receiving capecitabine and TEM treatment had better outcomes than patients with higher *MGMT* protein expression. However, there were also patients in the high *MGMT* expression group who responded to treatment (*i.e.*, reached partial remission or stable disease) [28]. Some studies did not show different treatment response to TEM according to *MGMT* status [29]. It is thus possible, as in patient 11 of the current study, that partial response or stable disease can be achieved with TEM in some patients with PC regardless of *MGMT* status, as previously demonstrated in other NETs. However, further studies are needed to clarify this.

Because PC is very rare, treatment of patients with recurrent PC could benefit from developments in personalized cancer care in the future. Some suggested treatment targets include different inhibitors of the PIK3CA-PTEN-mTOR-AKT pathway, such as sorafenib and everolimus [12, 30, 31]. For patients with recurrent PC, efficient treatment therapies are scarce and thus urgently needed. Demonstration of high *MGMT* methylation status could thus serve as a predictor of positive treatment response to TEM and tailoring of the treatment.

4. Conclusion

We recommend *MGMT* promoter methylation testing in recurrent PC not curable by surgery because high methylation status could indicate good treatment response to TEM. Some treatment response may be achieved regardless of *MGMT* methylation status.

Acknowledgments

Financial Support: This work was supported by grants from the Helsinki University Hospital Research Funds (TYH2017138 and TYH2018223) and Finska Läkaresällskapet (C.S.J.).

Additional Information

Correspondence: Camilla Schalin-Jääntti, MD, PhD, Associate Professor, Department of Endocrinology, Abdominal Center, Helsinki University Hospital, P.O. Box 340, FI-00290 Helsinki, Finland. E-mail: camilla.schalin-jantti@hus.fi.

Disclosure Summary: The authors have nothing to disclose.

Data Availability: All data generated or analyzed during this study are included in this published article or in the data repositories listed in the references.

References and Notes

1. McClenaghan F, Qureshi YA. Parathyroid cancer. *Gland Surg.* 2015;4(4):329–338.
2. Ryhänen EM, Leijon H, Metso S, Eloranta E, Korsoff P, Ahtiainen P, Kekäläinen P, Tamminen M, Ristamäki R, Knutar O, Löyttyniemi E, Niskanen L, Väisänen M, Heiskanen I, Välimäki MJ, Laakso M, Haglund C, Arola J, Schalin-Jääntti C. A nationwide study on parathyroid carcinoma. *Acta Oncol.* 2017;56(7):991–1003.
3. Lee PK, Jarosek SL, Virnig BA, Evasovich M, Tuttle TM. Trends in the incidence and treatment of parathyroid cancer in the United States. *Cancer.* 2007;109(9):1736–1741.

4. Brown S, O'Neill C, Suliburk J, Sidhu S, Sywak M, Gill A, Robinson B, Delbridge L. Parathyroid carcinoma: increasing incidence and changing presentation. *ANZ J Surg*. 2011;**81**(7-8):528–532.
5. Talat N, Schulte KM. Clinical presentation, staging and long-term evolution of parathyroid cancer. *Ann Surg Oncol*. 2010;**17**(8):2156–2174.
6. Lo WM, Good ML, Nilubol N, Perrier ND, Patel DT. Tumor size and presence of metastatic disease at diagnosis are associated with disease-specific survival in parathyroid carcinoma. *Ann Surg Oncol*. 2018;**25**(9):2535–2540.
7. Villar-del-Moral J, Jiménez-García A, Salvador-Egea P, Martos-Martínez JM, Nuño-Vázquez-Garza JM, Serradilla-Martín M, Gómez-Palacios A, Moreno-Llorente P, Ortega-Serrano J, de la Quintana-Basarrate A. Prognostic factors and staging systems in parathyroid cancer: a multicenter cohort study. *Surgery*. 2014;**156**(5):1132–1144.
8. Calandra DB, Chejfec G, Foy BK, Lawrence AM, Paloyan E. Parathyroid carcinoma: biochemical and pathologic response to DTIC. *Surgery*. 1984;**96**(6):1132–1137.
9. Munson ND, Foote RL, Northcutt RC, Tiegs RD, Fitzpatrick LA, Grant CS, van Heerden JA, Thompson GB, Lloyd RV. Parathyroid carcinoma: is there a role for adjuvant radiation therapy? *Cancer*. 2003;**98**(11):2378–2384.
10. Bradwell AR, Harvey TC. Control of hypercalcaemia of parathyroid carcinoma by immunisation. *Lancet*. 1999;**353**(9150):370–373.
11. Horie I, Ando T, Inokuchi N, Mihara Y, Miura S, Imaizumi M, Usa T, Kinoshita N, Sekine I, Kamihara S, Eguchi K. First Japanese patient treated with parathyroid hormone peptide immunization for refractory hypercalcemia caused by metastatic parathyroid carcinoma. *Endocr J*. 2010;**57**(4):287–292.
12. Rozhinskaya L, Pigarova E, Sabanova E, Mamedova E, Voronkova I, Krupinova J, Dzeranova L, Tiulpakov A, Gorbunova V, Orel N, Zalian A, Melnichenko G, Dedov I. Diagnosis and treatment challenges of parathyroid carcinoma in a 27-year-old woman with multiple lung metastases. *Endocrinol Diabetes Metab Case Rep*. 2017;**2017**(March):16-0113.
13. Storrvall S, Ryhänen E, Bensch FV, Heiskanen I, Kytölä S, Ebeling T, Mäkelä S, Schalin-Jäntti C. Recurrent metastasized parathyroid carcinoma - long-term remission after combined treatments with surgery, radiotherapy, cinacalcet, zoledronic acid and temozolomide. *JBMR Plus*. 2018;**3**(4):e10114.
14. Raverot G, Burman P, McCormack A, Heaney A, Petersenn S, Popovic V, Trouillas J, Dekkers OM; European Society of Endocrinology. European Society of Endocrinology clinical practice guidelines for the management of aggressive pituitary tumours and carcinomas. *Eur J Endocrinol*. 2018;**178**(1):G1–G24.
15. Cros J, Hentic O, Rebours V, Zappa M, Gille N, Theou-Anton N, Vernerey D, Maire F, Lévy P, Bedossa P, Paradis V, Hammel P, Ruszniewski P, Couvelard A. MGMT expression predicts response to temozolomide in pancreatic neuroendocrine tumors. *Endocr Relat Cancer*. 2016;**23**(8):625–633.
16. Campana D, Walter T, Pusceddu S, Gelsomino F, Graillot E, Prinzi N, Spallanzani A, Fiorentino M, Barritault M, Dall'Olio F, Brighi N, Biasco G. Correlation between MGMT promoter methylation and response to temozolomide-based therapy in neuroendocrine neoplasms: an observational retrospective multicenter study. *Endocrine*. 2018;**60**(3):490–498.
17. Thomas A, Tanaka M, Trepel J, Reinhold WC, Rajapakse VN, Pommier Y. Temozolomide in the era of precision medicine. *Cancer Res*. 2017;**77**(4):823–826.
18. Korpi-Hyövälti E, Cranston T, Ryhänen E, Arola J, Aittomäki K, Sane T, Thakker RV, Schalin-Jäntti C. CDC73 intragenic deletion in familial primary hyperparathyroidism associated with parathyroid carcinoma. *J Clin Endocrinol Metab*. 2014;**99**(9):3044–3048.
19. Miki H, Sumitomo M, Inoue H, Kita S, Monden Y. Parathyroid carcinoma in patients with chronic renal failure on maintenance hemodialysis. *Surgery*. 1996;**120**(5):897–901.
20. Dullea A, Marignol L. MGMT testing allows for personalised therapy in the temozolomide era. *Tumour Biol*. 2016;**37**(1):87–96.
21. Mikeska T, Bock C, El-Maarri O, Hübner A, Ehrentraut D, Schramm J, Felsberg J, Kahl P, Büttner R, Pietsch T, Waha A. Optimization of quantitative MGMT promoter methylation analysis using pyrosequencing and combined bisulfite restriction analysis. *J Mol Diagn*. 2007;**9**(3):368–381.
22. Philteos J, Karmur BS, Mansouri A. MGMT Testing in Glioblastomas. *Am J Clin Oncol*. 2018;**00**(00):1.
23. Karayan-Tapon L, Quillien V, Guilhot J, Wager M, Fromont G, Saikali S, Etcheverry A, Hamlat A, Loussouarn D, Campion L, Campone M, Vallette FM, Gratas-Rabbia-Ré C. Prognostic value of O6-methylguanine-DNA methyltransferase status in glioblastoma patients, assessed by five different methods. *J Neurooncol*. 2010;**97**(3):311–322.
24. Shaw RJ, Hall GL, Lowe D, Liloglou T, Field JK, Sloan P, Risk JM. The role of pyrosequencing in head and neck cancer epigenetics. *Arch Otolaryngol Head Neck Surg*. 2008;**134**(3):251–256.

25. Hamilton MG, Roldán G, Magliocco A, McIntyre JB, Parney I, Easaw JC. Determination of the methylation status of MGMT in different regions within glioblastoma multiforme. *J Neurooncol.* 2011; **102**(2):255–260.
26. Riemenschneider MJ, Hegi ME, Reifenberger G. MGMT promoter methylation in malignant gliomas. *Target Oncol.* 2010; **5**(3):161–165.
27. Binabaj MM, Bahrami A, ShahidSales S, Joodi M, Joudi Mashhad M, Hassanian SM, Anvari K, Avan A. The prognostic value of MGMT promoter methylation in glioblastoma: A meta-analysis of clinical trials. *J Cell Physiol.* 2018; **233**(1):378–386.
28. Owen DH, Alexander AJ, Konda B, Wei L, Hemminger JA, Schmidt CR, Abdel-Misih SRZ, Dillhoff ME, Sipos JA, Kirschner LS, Shah MH. Combination therapy with capecitabine and temozolomide in patients with low and high grade neuroendocrine tumors, with an exploratory analysis of O⁶-methylguanine DNA methyltransferase as a biomarker for response. *Oncotarget.* 2017; **8**(61):104046–104056.
29. Ekeblad S, Sundin A, Janson ET, Welin S, Granberg D, Kindmark H, Dunder K, Kozlovacki G, Orlefors H, Sigurd M, Oberg K, Eriksson B, Skogseid B. Temozolomide as monotherapy is effective in treatment of advanced malignant neuroendocrine tumors. *Clin Cancer Res.* 2007; **13**(10):2986–2991.
30. Pandya C, Uzilov AV, Bellizzi J, Lau CY, Moe AS, Strahl M, Hamou W, Newman LC, Fink MY, Antipin Y, Yu W, Stevenson M, Cavaco BM, Teh BT, Thakker RV, Morreau H, Schadt EE, Sebra R, Li SD, Arnold A, Chen R. Genomic profiling reveals mutational landscape in parathyroid carcinomas. *JCI Insight.* 2017; **2**(6):e92061.
31. Clarke CN, Katsonis P, Hsu T-K, Koire AM, Silva-Figueroa A, Christakis I, Williams MD, Kutahyaloglu M, Kwatampora L, Xi Y, Lee JE, Koptez ES, Busaidy NL, Perrier ND, Lichtarge O. Comprehensive genomic characterization of parathyroid cancer identifies novel candidate driver mutations & core pathways. *J Endocr Soc.* 2018; **3**(3):544–559.