

<https://helda.helsinki.fi>

---

## Cyclosporine Treatment in Severe Gestational Pemphigoid

Huilaja, Laura

2015

---

Huilaja , L , Makikallio , K , Hannula-Jouppi , K , Vakeva , L , Hook-Nikanne , J & Tasanen , K 2015 , ' Cyclosporine Treatment in Severe Gestational Pemphigoid ' , Acta Dermato-Venereologica , vol. 95 , no. 5 , pp. 593-595 . <https://doi.org/10.2340/00015555-2032>

---

<http://hdl.handle.net/10138/161810>

<https://doi.org/10.2340/00015555-2032>

---

publishedVersion

---

*Downloaded from Helda, University of Helsinki institutional repository.*

*This is an electronic reprint of the original article.*

*This reprint may differ from the original in pagination and typographic detail.*

*Please cite the original version.*

## CLINICAL REPORT

# Cyclosporine Treatment in Severe Gestational Pemphigoid

Laura HUILAJA<sup>1</sup>, Kaarin MÄKIKALLIO<sup>2</sup>, Katariina HANNULA-JOUPPI<sup>3</sup>, Liisa VÄKEVÄ<sup>3</sup>, Johanna HÖÖK-NIKANNE<sup>4</sup> and Kaisa TASANEN<sup>1</sup>

Departments of <sup>1</sup>Dermatology, Medical Research Center, <sup>2</sup>Obstetrics and Gynecology, University of Oulu, Oulu University Hospital, Oulu, <sup>3</sup>Department of Dermatology and Allergology, Skin and Allergy Hospital, Helsinki University Central Hospital, Helsinki, and <sup>4</sup>Department of Dermatology, Lohja District Hospital, Lohja, Finland

**Gestational pemphigoid, a rare autoimmune skin disease typically occurring during pregnancy, is caused by auto-antibodies against collagen XVII. Clinically it is characterised by severe itching followed by erythematous and bullous lesions of the skin. Topical or oral glucocorticoids usually relieve symptoms, but in more severe cases systemic immunosuppressive treatments are needed. Data on immunosuppressive medication controlling gestational pemphigoid are sparse. We report 3 intractable cases of gestational pemphigoid treated with cyclosporine. Key words: pemphigoid gestationis; treatment; cyclosporine.**

Accepted Dec 10, 2014; Epub ahead of print Dec 18, 2014

Acta Derm Venereol 2015; 95: 593–595.

Laura Huilaja, MD, PhD, Department of Dermatology, Medical Research Center, University of Oulu, Oulu University Hospital, P.B. 20, FIN-90029 Oulu, Finland. E-mail: laura.huilaja@oulu.fi

Gestational pemphigoid (PG) is a rare pregnancy-associated autoimmune dermatosis with an incidence of about 1:50,000 pregnancies (1, 2). The pathologic mechanism is suggestedly a local allogenic autoimmune reaction against collagen XVII (BP180) in the placenta, and thus a cross-reaction with collagen XVII in the maternal cutaneous basement membrane (3, 4). The diagnosis is based on a positive direct immunofluorescence (DIF) analysis of a perilesional skin biopsy (5), and elevated BP180 antibody levels parallel disease activity (6). PG typically occurs in the second and 3<sup>rd</sup> trimester of pregnancy with pruritic urticarial papules and plaques followed by blistering (5, 7, 8). In addition to maternal morbidity, PG is associated with prematurity and foetal growth restriction (8–10).

PG is usually in relative remission during the last weeks of pregnancy, but most patients have a flare-up at the time of delivery. It typically heals spontaneously within weeks after delivery, but may persist even for years and exacerbate during menstruation and hormonal contraception (5). In mild cases topical glucocorticoids combined with oral antihistamines are sufficiently helpful, but with more severe symptoms oral prednisolone is the drug-of-choice (5). In cases unresponsive to conventional therapy, other immunosuppressive medications (i.e., azathioprine, dapsone, cyclosporine), intravenous immunoglobulin and

plasmapheresis have been used (5, 7, 8, 11). To the best of our knowledge, only 2 case reports on cyclosporine treatment have been published (12, 13).

## CASE REPORTS

*Case 1.* A 33-year-old healthy woman presented at gestational week (gw) 27+6 in her second pregnancy with pruritic skin symptoms that had started 2 weeks earlier on her ankles. She was first diagnosed to have polymorphic eruption of pregnancy and a potent topical glucocorticoid was initiated, but DIF analysis confirmed the PG diagnosis. Due to severe symptoms she was hospitalised at gw 28+4 with prednisolone treatment, which relieved her symptoms, and the dose was later decreased. However, at gw 32+4 she had a drastic worsening of symptoms (Fig. 1 A, B) and she was re-hospitalised, and cyclosporine medication was combined with prednisolone. In addition, she required insulin treatment for her gestational diabetes. After 2 weeks her skin symptoms relieved and the prednisolone dose was reduced.

The mother was closely monitored in our high-risk pregnancy unit due to foetal growth restriction, and gestational diabetes. Evaluations of placental and foetal haemodynamics gave repeatedly normal results. At gw 36+4 she delivered spontaneously a growth-restricted boy (2,280 g, 6<sup>th</sup> growth percentile), who had an uneventful neonatal period.

Her cyclosporine treatment was discontinued after the delivery, although on the first day after the delivery she had itching on her palms and a few new lesions appeared. Despite minor pruritic lesions in her extremities tapering of the prednisolone medication was started 6 weeks after the delivery and finally discontinued 6 months postpartum. She had been previously diagnosed with endometriosis, which was under control with combined oral contraceptives. This type of hormonal contraception was thought to bear a risk for PG recurrence. After discussion she opted for an intra-uterine progesterone-releasing device, and has had no symptoms of PG or endometriosis for 6 months during lactation (Table S1<sup>1</sup>).

*Case 2.* A 27-year-old healthy woman developed pruritic skin symptoms on her trunk and extremities at 27 gw in her first pregnancy. She first visited a dermatologist at 31+4 gw with erythema multiforme-like lesions, and was diagnosed to have erythema multiforme. Prednisolone combined with topical glucocorticoids and narrow-band UVB therapy partially relieved her symptoms. After 5 weeks, these treatments were discontinued. However, erythema multiforme-like lesions kept developing, and at 38+4 gw her symptoms were aggravated. PG was confirmed by DIF analysis, and prednisolone and a potent topical glucocorticoid were initiated.

Foetal growth restriction was detected prenatally, but umbilical artery velocimetry and cardiotocograms remained normal during the follow-up. At gw 39+3, labour was induced, and a growth-restricted boy (2,595 g, 4<sup>th</sup> growth percentile) was delivered.

<sup>1</sup><http://www.medicaljournals.se/acta/content/?doi=10.2340/00015555-2032>

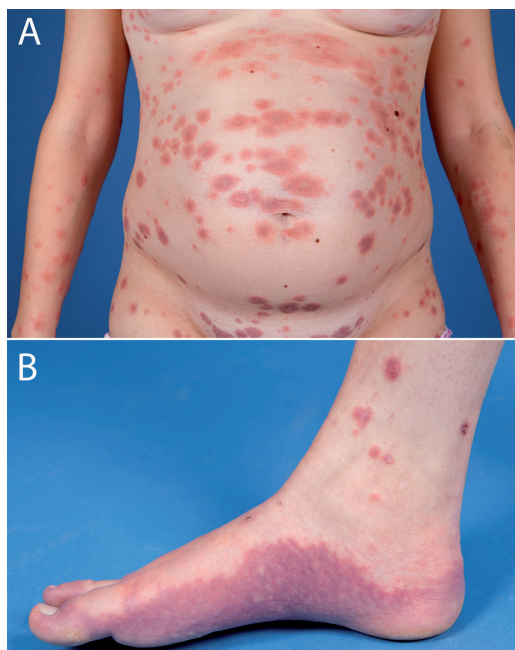


Fig. 1. Clinical presentation of case 1. A: Widespread urticarial and partially blistering eruption. B: Erythematous non-blistering eruption on soles.

Maternal skin symptoms worsened immediately after the delivery and oral prednisolone dose was increased. As blistering and intense itching continued, cyclosporine was combined with her medication a few days after the delivery. Prednisolone was then slowly tapered. While pruritus and blistering continued and the BP180 levels remained above 150 IU/ml, the cyclosporine dose was increased. After 3 weeks on the higher cyclosporine dose her skin symptoms relieved, and due to mildly elevated creatinine levels (96  $\mu\text{mol/l}$ ) the dose was decreased and prednisolone was continued. Due to provoking symptoms her prednisolone medication could not be tapered, and 8 months after the delivery methotrexate was added to her medication, simultaneously with start of combined oral contraceptives (ethinyl estradiol with drospirenone). Two months after the initiation of this combination no new blisters had appeared, but she still had mild erythema on her chest and scalp. She was symptom-free one year after the delivery, and cyclosporine was discontinued, prednisolone dose tapered and she continued with methotrexate. A relapse with pruritic papules occurred rapidly, and cyclosporine and prednisolone were re-initiated. Two weeks after the relapse cyclosporine was successfully discontinued and she continued on prednisolone and methotrexate. Tapering of the prednisolone dose 15 months after the delivery led to an immediate activation of her symptoms. Methotrexate was increased to 15 mg/week for 3 months, and prednisolone was finally slowly discontinued 19 months postpartum with no signs of cortisol deficiency. Her methotrexate medication was discontinued successfully 22 months postpartum, and 2 years after the delivery, she is finally symptom-free (Table S1<sup>1</sup>).

**Case 3.** A 32-year-old healthy woman presented at 26+6 in her 4<sup>th</sup> pregnancy with a pruritic eruption spreading over the body and extremities. PG was confirmed at gw 27+2 by DIF analysis. Oral prednisolone combined with hydroxyzine and a topical glucocorticoids was started. After a week the prednisolone dose was increased since blistering continued, and at gw 29+5 she was hospitalised with cyclosporine medication. Disease control was achieved and after 5 weeks without flaring (34+3), cyclosporine and prednisolone were tapered, but due to a non-blistering eruption the prednisolone dose was slightly increased to control the disease.

Antenatal foetal monitoring tests were normal during the obstetric follow-up. At gw 35+4 she was hospitalised due to decreased foetal movements, proceeded to spontaneous preterm delivery, and delivered a healthy girl (2,870g, 63<sup>th</sup> growth percentile). The patient decided to discontinue the cyclosporine therapy immediately after the delivery and remained on prednisolone monotherapy. A flare-up blistering occurred rapidly, but subsided within 6 weeks, and prednisolone was tapered during the following 2 months. Two months after the delivery BP180 antibodies were still elevated, but she has had no flare-ups for 4 years and uses non-hormonal contraception. Her BP180 antibody levels have not been evaluated later (Table S1<sup>1</sup>). This pregnancy is included in our earlier study (10), without giving any details about her cyclosporine therapy.

## DISCUSSION

Most PG patients can be successfully treated with topical and oral glucocorticoids, which are considered relatively safe during pregnancy (14, 15). Data on severe PG cases with immunosuppressive medication are sparse, and the benefit to the mother needs to be weighed against possible risks to the foetus and the newborn. Cyclosporine down-regulates T-cell function, and it has been used during pregnancy in organ transplant patients and in various autoimmune diseases with no association with increased risk of congenital malformations (16). As a lipophilic agent, cyclosporine diffuses across the placenta and enters the foetal circulation and tissues (16), and can increase foetal exposure to other drugs (17). In previous reports maternal and foetal risks have mostly been associated with maternal comorbidities and multiple immunosuppressive drugs (16).

Maternal BP180 antibody levels were highly elevated already at the time of PG diagnosis in all cases (Table S1<sup>1</sup>). Cyclosporine treatment was started according to clinical symptoms, but BP180 antibody levels were above 110 IU/ml in all cases at the beginning of the treatment. In our previous series, BP180 levels varied between 27–50 IU/ml in patients who were successfully treated with systemic glucocorticoids (10). In the present study, maternal BP180 antibody levels correlated well with disease activity, as described earlier (6), and decreased before cyclosporine was weaned off (Table S1<sup>1</sup>), strengthening the suggestion that BP180 antibody levels can guide treatment decisions (18).

Previously, cyclosporine has been used postnatally in combination with prednisolone after intravenous immunoglobulin treatment in one severe persistent PG case lasting for 1.5 years (13) and antenatally in one case, in which 100 mg/day cyclosporine was combined with prednisolone 25 mg/day (12). Our patients were treated with higher cyclosporine (100–400 mg/day; 1.5–2.7 mg/kg/day) and prednisolone (40–60 mg/day; 0.55–0.67 mg/kg/day) doses. These doses are in line with previously reported medications used in severe psoriasis during pregnancy (19, 20). Cyclosporine was well tolerated by the present patients. In case 2 the dose was reduced due to mildly elevated maternal serum creatinine level, but none of our patients developed hypertensive disorders or

systemic infections. However, close maternal and foetal follow-up is warranted due to risks of infection (1–71%), premature delivery (21%), foetal growth restriction (21%) and maternal kidney changes becoming irreversible (16).

Two of our patients with antenatal cyclosporine therapy proceeded to spontaneous preterm delivery at 35–36 weeks and 2 neonates were growth-restricted (one with antenatal cyclosporine therapy) with no haemodynamic signs of foetal blood flow redistribution or maternal hypertensive disorders. Prematurity and low birth weight are associated with both PG and cyclosporine medication (9, 10, 16). Among 19 psoriatic patients, both foetal growth restriction and premature delivery occurred in 21% of the pregnancies treated with cyclosporine (16). Systemic glucocorticoid therapy can also increase the risk of maternal hypertension and low birth weight (21). It is difficult to estimate whether the adverse perinatal outcomes in this study are solely due to severe PG or whether the medication played a role. However, we underline that these patients should be closely monitored by their dermatologists as well as their obstetricians.

Cyclosporine is excreted to breast milk and the American Association of Pediatrics advises against breastfeeding during the medication (22). However, among 15 cumulative breastfed cases, cyclosporine was detected in the neonatal circulation only in one case and normal growth and development has been reported in all cases (23–27). Due to the relatively small amount of drug transferred and the lack of reported adverse effects, we let the mothers breastfeed their babies. In case 2, the cyclosporine levels in the infant's circulation were evaluated, and no cyclosporine was detected. The infants in the present study developed normally during the first 6 months–2 years, which is in line with previous follow-up reports of the offspring up to 15 years of age (28).

In conclusion, cyclosporine treatment can be considered antenatally when treating severe and persistent PG unresponsive to topical and systemic glucocorticoids. In addition to dermatologic follow-up, close obstetric follow-up is warranted due to the risks of premature delivery and fetal growth restriction.

## REFERENCES

- Ambros-Rudolph CM, Mullegger RR, Vaughan-Jones SA, Kerl H, Black MM. The specific dermatoses of pregnancy revisited and reclassified: results of a retrospective two-center study on 505 pregnant patients. *J Am Acad Dermatol* 2006; 54: 395–404.
- Roth MM. Pregnancy dermatoses: diagnosis, management, and controversies. *Am J Clin Dermatol* 2011; 12: 25–41.
- Kelly SE, Black MM, Fleming S. Pemphigoid gestationis: a unique mechanism of initiation of an autoimmune response by MHC class II molecules? *J Pathol* 1989; 158: 81–82.
- Kelly SE, Black MM, Fleming S. Antigen-presenting cells in the skin and placenta in pemphigoid gestationis. *Br J Dermatol* 1990; 122: 593–599.
- Semkova K, Black M. Pemphigoid gestationis: current insights into pathogenesis and treatment. *Eur J Obstet Gynecol Reprod Biol* 2009; 145: 138–144.
- Sitaru C, Powell J, Messer G, Brocker EB, Wojnarowska F, Zillikens D. Immunoblotting and enzyme-linked immunosorbent assay for the diagnosis of pemphigoid gestationis. *Obstet Gynecol* 2004; 103: 757–763.
- Lipozencic J, Ljubojevic S, Bukvic-Mokos Z. Pemphigoid gestationis. *Clin Dermatol* 2012; 30: 51–55.
- Huilaja L, Makikallio K, Tasanen K. Gestational pemphigoid. *Orphanet J Rare Dis* 2014; 9: 136.
- Chi CC, Wang SH, Charles-Holmes R, Ambros-Rudolph C, Powell J, Jenkins R, et al. Pemphigoid gestationis: early onset and blister formation are associated with adverse pregnancy outcomes. *Br J Dermatol* 2009; 160: 1222–1228.
- Huilaja L, Makikallio K, Sormunen R, Lohi J, Hurskainen T, Tasanen K. Gestational pemphigoid: placental morphology and function. *Acta Derm Venereol* 2013; 93: 33–38.
- Intong LR, Murrell DF. Pemphigoid gestationis: current management. *Dermatol Clin* 2011; 29: 621–628.
- Paternoster DM, Bruno G, Grella PV. New observations on herpes gestationis therapy. *Int J Gynaecol Obstet* 1997; 56: 277–278.
- Hern S, Harman K, Bhogal BS, Black MM. A severe persistent case of pemphigoid gestationis treated with intravenous immunoglobulins and cyclosporin. *Clin Exp Dermatol* 1998; 23: 185–188.
- Tyler KH, Zirwas MJ. Pregnancy and dermatologic therapy. *J Am Acad Dermatol* 2013; 68: 663–671.
- Murase JE, Heller MM, Butler DC. Safety of dermatologic medications in pregnancy and lactation: Part I. Pregnancy. *J Am Acad Dermatol* 2014; 70: 401.e1–e14; quiz 415.
- Paziana K, Del Monaco M, Cardonick E, Moritz M, Keller M, Smith B, et al. Cyclosporin use during pregnancy. *Drug Saf* 2013; 36: 279–294.
- Molsa M, Heikkinen T, Hakkola J, Hakala K, Wallerman O, Wadelius M, et al. Functional role of P-glycoprotein in the human blood-placental barrier. *Clin Pharmacol Ther* 2005; 78: 123–131.
- Sitaru C, Dahnrich C, Probst C, Komorowski L, Blocker I, Schmidt E, et al. Enzyme-linked immunosorbent assay using multimers of the 16th non-collagenous domain of the BP180 antigen for sensitive and specific detection of pemphigoid autoantibodies. *Exp Dermatol* 2007; 16: 770–777.
- Finch TM, Tan CY. Pustular psoriasis exacerbated by pregnancy and controlled by cyclosporin A. *Br J Dermatol* 2000; 142: 582–584.
- Edmonds EV, Morris SD, Short K, Bewley SJ, Eady RA. Pustular psoriasis of pregnancy treated with cyclosporin and high-dose prednisolone. *Clin Exp Dermatol* 2005; 30: 709–710.
- Jackson S, Gilchrist H, Nesbitt LT, Jr. Update on the dermatologic use of systemic glucocorticosteroids. *Dermatol Ther* 2007; 20: 187–205.
- American Academy of Pediatrics Committee on Drugs. Transfer of drugs and other chemicals into human milk. *Pediatrics* 2001; 108: 776–789.
- Munoz-Flores-Thiagarajan KD, Easterling T, Davis C, Bond EF. Breast-feeding by a cyclosporine-treated mother. *Obstet Gynecol* 2001; 97: 816–818.
- Nyberg G, Haljamae U, Frisenette-Fich C, Wennergren M, Kjellmer I. Breast-feeding during treatment with cyclosporine. *Transplantation* 1998; 65: 253–255.
- Thiru Y, Bateman DN, Coulthard MG. Successful breast feeding while mother was taking cyclosporin. *BMJ* 1997; 315: 463.
- Morton A. Cyclosporine and lactation. *Nephrology (Carlton)* 2011; 16: 249.
- Moretti ME, Sgro M, Johnson DW, Sauve RS, Woolgar MJ, Taddio A, et al. Cyclosporine excretion into breast milk. *Transplantation* 2003; 75: 2144–2146.
- Nulman I, Sgro M, Barrera M, Chitayat D, Cairney J, Koren G. Long-term neurodevelopment of children exposed in utero to cyclosporin after maternal renal transplant. *Paediatr Drugs* 2010; 12: 113–122.