

Department of Ophthalmology
University of Helsinki
Head: Professor Leila Laatikainen, MD
Helsinki, Finland

**RETINAL DETACHMENT
AFTER
NEODYMIUM:YTTRIUM-ALUMINUM-GARNET
LASER POSTERIOR CAPSULOTOMY**

by

Päivi Ranta

Academic dissertation
To be publicly discussed, by permission of
the Medical Faculty of the University of Helsinki,
in the Auditorium of the Department of Ophthalmology,
Haartmaninkatu 4, Helsinki,
on November 1st, 2002, at 12 o'clock noon

Supervised by:

Tero Kivelä, M.D.
Docent
Department of Ophthalmology
Helsinki University Central Hospital
Helsinki, Finland

Reviewed by:

Ulf Stenevi, M.D.
Docent
Department of Ophthalmology
Sahlgren University Hospital
Molndal, Sweden

Markku Teräsvirta, M.D.
Docent
Department of Ophthalmology
Kuopio University Hospital
Kuopio, Finland

Opponent:

Charlotta Zetterström, M.D.
Professor
St. Erik's Eye Hospital
Karolinska Institute
Stockholm, Sweden

ISBN 952-91-5180-2 (nid.)
ISBN 952-10-0745-1 (PDF)
<http://ethesis.helsinki.fi>
Yliopistopaino
Helsinki 2002

To Petri, Pauli and Tanja

TABLE OF CONTENTS

ABSTRACT	7
1 LIST OF ORIGINAL PUBLICATIONS	9
2 INTRODUCTION	10
3 REVIEW OF LITERATURE	12
3.1 CATARACT SURGERY	12
3.1.1 <i>Epidemiology of cataract</i>	12
3.1.2 <i>General development of cataract surgery</i>	12
3.1.3 <i>Complications</i>	13
3.1.4 <i>Evaluation of outcome</i>	15
3.2 POSTERIOR CAPSULE OPACIFICATION (PCO)	15
3.2.1 <i>Pathogenesis</i>	15
3.2.2 <i>Incidence</i>	18
3.2.3 <i>Prevention</i>	18
3.2.4 <i>Treatment</i>	20
3.3 ND:YAG LASER POSTERIOR CAPSULOTOMY (LCT)	20
3.3.1 <i>Principles of Nd:YAG laser</i>	20
3.3.2 <i>Complications</i>	22
3.3.3 <i>Effects on vitreoretinal structures</i>	24
3.4 RHEGMATOGENOUS RETINAL DETACHMENT (RD)	25
3.4.1 <i>Pathogenesis</i>	25
3.4.2 <i>Predisposing factors</i>	26
3.4.3 <i>Prevention</i>	27
3.4.4 <i>Treatment</i>	28
3.4.5 <i>Outcome</i>	28
3.5 PSEUDOPHAKIC RETINAL DETACHMENT.....	30
3.5.1 <i>Special risk factors</i>	30
3.5.2 <i>Special characteristics</i>	31
3.5.3 <i>Retinal detachment after LCT</i>	31
3.5.4 <i>Treatment</i>	32
3.5.5 <i>Outcome</i>	32

4	AIMS OF THE STUDY	33
5	PATIENTS AND METHODS	34
5.1	PATIENTS.....	34
5.1.1	<i>Retrospective cohort study (I)</i>	34
5.1.2	<i>Prospective studies (II, III)</i>	34
5.1.3	<i>Cross-sectional study (III)</i>	35
5.2	METHODS	35
5.2.1	<i>Collection of retrospective data (I-IV)</i>	35
5.2.2	<i>Clinical examination (II-IV)</i>	38
5.2.3	<i>Nd:YAG laser posterior capsulotomy (II)</i>	38
5.2.4	<i>Patient satisfaction and quality of life (IV)</i>	38
5.2.5	<i>Statistical analysis (I-IV)</i>	41
6	RESULTS AND DISCUSSION.....	43
6.1	CHARACTERISTICS OF RD AFTER LCT.....	43
6.1.1	<i>Time intervals between cataract extraction, LCT and RD (I, IV)</i>	43
6.1.2	<i>Risk factors for RD</i>	43
6.1.3	<i>Type and extent of RD (I, IV)</i>	43
6.1.4	<i>Type, number and location of retinal breaks (I)</i>	44
6.2	RETINAL BREAKS ASSOCIATED WITH LCT	45
6.2.1	<i>Asymptomatic retinal breaks and RD before LCT (II)</i>	45
6.2.2	<i>Retinal breaks after LCT (II)</i>	46
6.2.3	<i>Later retinal breaks (III)</i>	47
6.2.4	<i>Prospective study of RD after LCT (III)</i>	48
6.3	LONG-TERM OUTCOME OF PSEUDOPHAKIC RETINAL DETACHMENT AFTER LCT	49
6.3.1	<i>Anatomic outcome (IV)</i>	49
6.3.2	<i>Objective visual outcome (IV)</i>	50
6.3.3	<i>Patient-rated functional outcome (IV)</i>	50
7	SUMMARY AND CONCLUSIONS	53
8	ACKNOWLEDGEMENTS.....	55
9	REFERENCES.....	56

ABSTRACT

The purpose of this clinical study was to gain better understanding about the etiology, pathogenesis, characteristics and outcome of pseudophakic retinal detachment (RD) after Nd:YAG laser posterior capsulotomy (LCT). The main principle was to compare RD of eyes with an intact posterior capsule with RD in eyes that had undergone LCT at the time of RD after uncomplicated cataract surgery. The hypothesis was that a significant number of asymptomatic retinal breaks might exist in eyes scheduled for LCT, possibly later causing RD.

First, to identify possible differences in the type of RD and retinal breaks, a retrospective cohort study of 129 eyes (61 with LCT and 68 with an intact posterior capsule) with pseudophakic RD was carried out (I). The mean number of peripheral retinal breaks was higher in the LCT group (1.7 vs. 1.1, $P=0.05$, Mann-Whitney U test). The breaks were located preferentially in the upper quadrants in the LCT group (82 of 103 vs. 48 of 77; $P=0.024$, Fisher's exact test with Bonferroni correction) and they tended to be more frequently atrophic holes than horseshoe breaks (34 of 103 vs. 15 of 77; $P=0.062$, Fisher's exact test) in eyes with LCT.

Secondly, to find out the frequency of asymptomatic retinal breaks before LCT and to determine whether this procedure causes new breaks, a two-stage prospective study (II,III) was designed. At Stage I, 211 of 350 eligible patients scheduled for LCT (220 eyes) completed three outpatient visits: before LCT, immediately after it and after 1 month of follow-up. An untreated, asymptomatic retinal break was found (and photocoagulated) in 4 of the 235 eyes (1.7%, 95%CI 0-4) before LCT. Furthermore, in 2 additional eyes (0.9%, 95% CI 0-3) an undiagnosed RD was found. One month after LCT a new asymptomatic horseshoe tear was found (and photocoagulated) in 1 of 220 eyes (0.4%, 95% CI 0-3). In spite of PCO, the visualization of the peripheral retina was possible in 75% of eyes before LCT, and this proportion increased to 89% after LCT.

At Stage II of the prospective study, patient charts of the primary inception cohort (350 eyes) were reviewed for retinal events. Furthermore, the 211 patients enrolled at Stage I were reinvited to one outpatient visit; 106 patients participated. In 8 of 350 eyes (2.3%, 95%CI 1-4) a RD had occurred during the five-year follow up: 2 in eyes studied at Stage I and 6 in eyes with unknown retinal status at the time of LCT. By univariate Cox regression, axial length, whether modelled as a continuous variable (HR 1.51 for each mm of increase) or categorized by using 25 mm as a cut-off (HR 11.1) showed a statistically significant association between RD after LCT ($P=0.0002$ and 0.0016 , respectively).

Finally, to assess differences in outcome of pseudophakic RD between eyes with or without LCT, a cross-sectional analysis was done (IV). Of 138 patients invited to participate, 101 (73%) attended an outpatient visit (46 eyes with LCT and 55 with an intact capsule). A structured interview to determine patient-rated satisfaction was undertaken. The retina remained attached long-term in 92 eyes (91%, 95% CI 84-96). The median BCVA (in Snellen equivalents) was 0.08 before RD surgery and 0.4 at re-examination (-logMAR, 1.1 and 0.4, respectively). No statistically significant difference was observed between LCT and control groups ($P=0.86$ Mann-Whitney U test). 80% of patients were satisfied or very satisfied with their binocular vision, and 62% reported no or just a little trouble with binocular vision. The median modified Cataract Symptom Score was 3.0 (the less points, the less symptoms, maximum 18) and the median VF-14 score was 87.5 (the more points, the better, maximum 100) for both groups ($P=0.76$ and 0.81 respectively, Mann-Whitney U test).

The present series of studies, although based on relatively small numbers of patients, supports the concept that in some eyes, pre-existing retinal breaks may underlie pseudophakic RD after LCT. Especially when dealing with patients with pre-existing vitreoretinal pathology and risk factors for RD, such as high axial length, history of fellow RD and vitreous loss during cataract surgery, a careful retinal examination and follow-up before and after LCT may be recommended.

ABBREVIATIONS

AC	anterior chamber
AL	axial length of the eye
AMD	age-related macular degeneration
AV	anterior vitrectomy
BCVA	best corrected visual acuity
BMDP	a statistical software package
CI	confidence interval
CCC	continuous curvilinear capsulorhexis
CME	cystoid macular edema
D	diopetre
ECCE	extracapsular cataract extraction
ICCE	intracapsular cataract extraction
IOL	intraocular lens
IOP	intraocular pressure
logMAR	logarithm of the minimum angle of resolution
LCT	laser posterior capsulotomy
Nd:YAG	neodymium:yttrium-aluminum-garnet laser
PC	posterior chamber
PCO	posterior capsule opacification
PHACO	phacoemulsification
PMMA	poly(methyl methacrylate)
PPV	pars plana vitrectomy
PVD	posterior vitreous detachment
PVR	proliferative vitreoretinopathy
RD	retinal detachment
SD	standard deviation
SE	standard error
SPSS	a statistical software package
VA	visual acuity

1 LIST OF ORIGINAL PUBLICATIONS

This thesis is based on the following original publications, which are referred to in the text by their Roman numerals (I-IV):

- I Ranta P, Kivelä T. Retinal detachment in pseudophakic eyes with and without Nd:YAG laser posterior capsulotomy. *Ophthalmology* 1998;105:2127-2133.
- II Ranta P, Tommila P, Immonen I, Summanen P, Kivelä T. Retinal breaks before and after neodymium:YAG posterior capsulotomy. *J Cataract Refract Surg* 2000;26:1190-1197.
- III Ranta P, Tommila P, Kivelä T. Retinal breaks and detachment after Nd:YAG laser posterior capsulotomy: follow-up of a prospective cohort, submitted.
- IV Ranta P, Kivelä T. Functional and anatomic outcome of retinal detachment surgery in pseudophakic eyes. *Ophthalmology* 2002;109,1432-1440.

2 INTRODUCTION

Cataract is defined as any opacity in the crystalline lens of the eye that impairs vision. It is by far the most common curable cause of low vision and blindness worldwide. Because of cataract, 25 million individuals were blind and 110 million visually impaired at the beginning of year 2000.¹ Cataract extraction is the most frequently performed surgical procedure in patients over 65 years of age. In the United States, about 1.6 million cataract operations are done every year.² In Finland over 31 000 cataract extractions are performed annually, and 98% of them are done by phacoemulsification, the most modern method of cataract surgery.³

The development of cataract surgery has led the world from the uncertain time of 'couching the lens' to the modern era of refractive surgery with a high success rate and regain of useful functional vision, although the speed of progress has varied in different parts of the world. The visual results of cataract surgery are at present very good, and serious complications, such as endophthalmitis and suprachoroidal hemorrhage are fortunately very rare, affecting less than 1 in 1000 patients in many series.⁴⁻⁷ The risk of retinal detachment (RD), which is nowadays the most common potentially blinding postoperative complication, is about 1.0% even after modern cataract surgery.⁸ In developing countries the situation is totally different. The modern extracapsular surgery may even become a problem compared with intracapsular surgery, because of lack of intraocular lenses and the means to treat posterior capsule opacification.

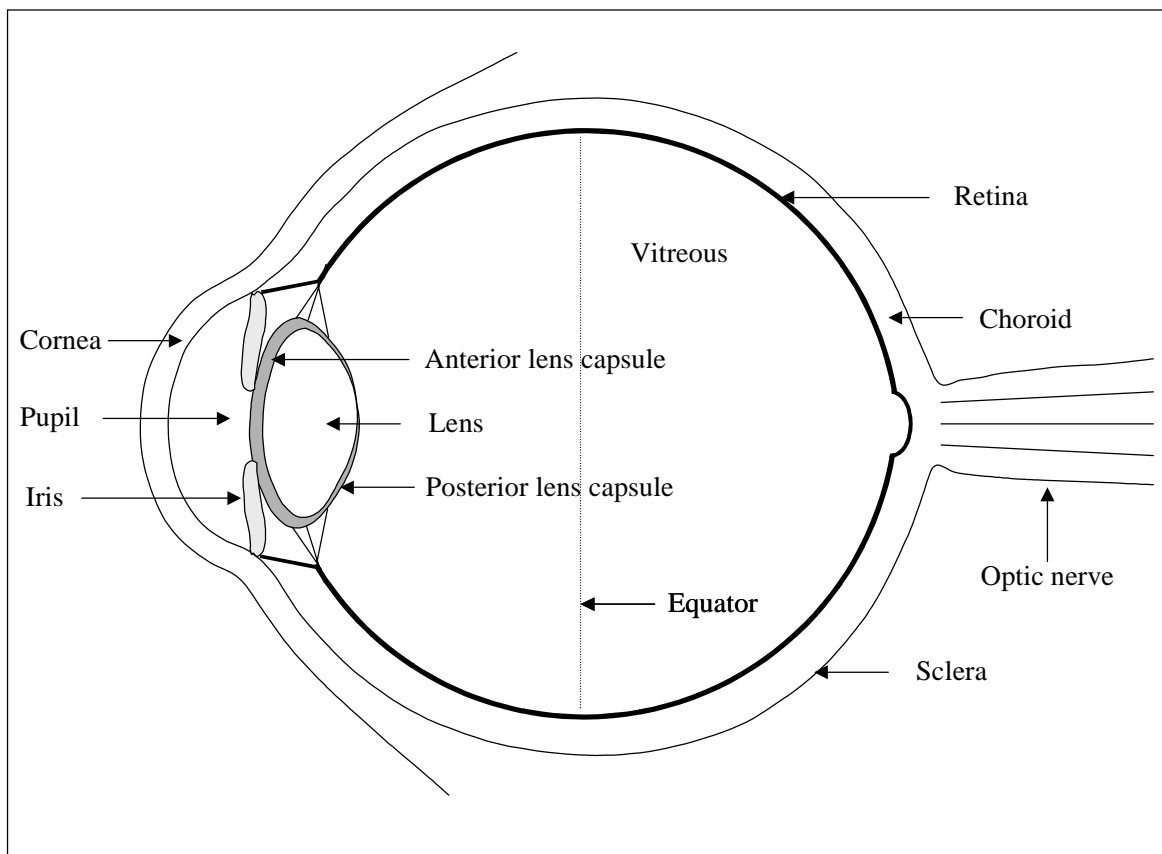
Posterior capsule opacification (PCO) is a very frequent problem after cataract surgery, which currently necessitates a posterior capsulotomy (LCT) with neodymium:yttrium-aluminum-garnet (Nd:YAG) laser in one fourth to fifth of eyes that have undergone cataract extraction and intraocular lens (IOL) implantation.⁹ Even though laser capsulotomy is easy to perform, it carries risks. In addition to intraocular lens pitting, cystic macular edema and intraocular pressure rise, it is thought to increase the risk of RD four times compared with uncomplicated extracapsular cataract extraction only.^{4:10-12}

The exact mechanisms leading to RD after LCT are not known, even though several theories are proposed. It is commonly believed that Nd:YAG laser treatment initiates structural changes in the anterior vitreous, resulting in vitreous liquefaction, posterior vitreous

detachment and, if any abnormal vitreoretinal attachments exist, in retinal breaks and detachment.¹³⁻¹⁹

The basic type and general outcome of pseudophakic RD have been reported but many details remain unanswered and unexplored. The present series of studies was designed to get more information especially of eyes that have undergone capsulotomy before RD, and to be able to manage this group of patients in an increasingly rational way.

Figure 1. The cross section of the eye



3 REVIEW OF LITERATURE

3.1 CATARACT SURGERY

3.1.1 Epidemiology of cataract

Any opacity in the lens that impairs vision is called a cataract. It is estimated, that almost two thirds of 65-74 year-old people lens opacities of some degree are present, and about one-fourth of individuals in this age group have decreased vision because of lens opacities.^{20:21} The main risk factor for lens opacification is aging, although other etiologies for cataract, i.e. trauma, radiation, use of corticosteroids, systemic disorders like diabetes mellitus and atopic dermatitis, and ocular conditions such as uveitis, retinis pigmentosa, degenerative myopia and glaucoma surgery are also known.^{20:21} Although usually thought to affect equally men and women, it have also been reported, that cataract extractions are performed more frequently in female patients.⁵ This difference have been explained only by the fact that females live longer. The suggested reasons for the difference have been a higher prevalence of cataract in females, and social reasons, such as tendency to experience more functional impairment and request surgery with higher visual acuities than males. Although primarily a disease of the elderly, cataract can occur at any age. About one third of all congenital cataracts are hereditary.²⁰ Infantile cataracts are of particular importance as a cause of amblyopia, strabismus and nystagmus, and they sometimes have to be operated on even in very young children. Age-related cataract is a multifactorial disease in which genetic, environmental, socioeconomic and biochemical factors may have an additive effect.^{20:22} Because of this diversity, no method of preventing the development of cataract has yet been successful.

3.1.2 General development of cataract surgery

Although primitive types of cataract surgery have been performed for thousands of years, the history of sophisticated cataract surgery is relatively short. Up to the 18th century the purpose of the operation was to couch or to displace the opaque lens from the visual pathway. This was done with a sharp needle with the patient sitting in a chair. After a temporal paracentesis the lens was dropped down 'into the depths of the eye'.^{20:23} In 1745 Daviel was probably the first surgeon to operate through the cornea to extract the cataract.⁴ However, with the extracapsular technique, in which the lens is removed from the lens capsule, it was necessary

to wait until the cataract was nearly mature, because nonopaque parts of the lens were difficult to remove. Therefore, when the intracapsular method (ICCE), enabling total removal of the lens, was introduced some years later, it quickly and almost completely replaced the extracapsular techniques for a considerable period of time.

Even when performed successfully, cataract extraction resulted in disturbing visual handicap, aphakia. The traditional method of correcting aphakia by spectacles created visual problems such as magnification and reduced peripheral vision. The next solution, contact lenses, magnified objects significantly less without severe peripheral distortions. However, they were useful only to patients, who could handle them adequately and wear them comfortably, which was often difficult, if not impossible, for elderly people with several systemic diseases.

The idea of intraocular lenses emerged from the difficulties in providing good visual rehabilitation for aphakic patients. Sir Harold Ridley implanted the first IOL on February 8, 1950, after a planned extracapsular cataract extraction (ECCE) in a 45-year old female. The very first idea of an intraocular lens, however, came from a medical student.^{2;4}

Due to optical advantages, the intraocular lens quickly became the standard method for correcting aphakia once appropriate lenses and instruments were made widely available in the late 1980's.^{2;20;23;24} The method of disintegrating the lens with phacoemulsification, introduced by Charles Kelman, and the development of viscoelastics and IOLs have made it possible to remove the lens and to implant a foldable IOL through very small incisions. Also modern instruments minimizing surgical injury, advantages of in-the-bag fixation, continuous curvilinear capsulorhexis (CCC) and hydrodissection techniques have resulted in safer and more rapid rehabilitation, but also differences in complications.^{4;20;24}

3.1.3 Complications

The intra- and postoperative complications of cataract surgery are nowadays less severe than at the time of ICCE. However, concurrently with extracapsular technique, a new problem with posterior capsule opacification arose. Comparing posterior segment complications after planned extracapsular cataract extraction and phacoemulsification, no significant differences have been found between these two techniques.^{25;26} The most serious perioperative

complications of cataract extraction, which have influence on the posterior segment of the eye, are listed here.

Posterior capsule rupture, which precedes vitreous loss, is the most common of these complications, and is reported to occur in 0.2%-16% of operated eyes.²⁶⁻³⁴ It is more likely to happen in eyes with small pupils, hard nuclei, or exfoliation syndrome. If posterior capsule ruptures and vitreous loss occurs, the risk for RD and other posterior segment complications is increased.^{8:35:36}

The expulsive suprachoroidal hemorrhage, which is due to rupture of a ciliary artery, is fortunately a rare complication occurring in 0.03-0.06% of patients after phacoemulsification and IOL implantation.^{4:37:38}

Purulent endophthalmitis can occur within the first postoperative days or later as a chronic intraocular infection. The incidence of infectious endophthalmitis after cataract surgery has been estimated to be 0.07%-0.13%.^{4-7:37} It is usually managed with intraocular, topical and systemic antibiotics combined with corticosteroid therapy and, if BCVA is light perception, vitrectomy.³⁹ The visual prognosis in endophthalmitis is dependent on time of onset of the endophthalmitis and the virulence of the pathogen.⁷

Following cataract surgery, cystoid macular edema (CME) is the most common cause of unexpected visual loss. It has been estimated, that fluorescein angiographic CME can occur in up to 50% of patients 4-8 weeks postoperatively but clinical CME occurs in less than 3% of patients.^{4:40} It is assumed to be caused by postoperative inflammatory reaction or vitreous traction. Intraoperative complications, such as posterior capsule rupture and vitreous loss predispose to CME.^{35:41}

Retinal detachment, which is the most common potentially blinding complication of cataract extraction, occurs nowadays in 0.05-1.7% of persons after phacoemulsification and posterior chamber IOL implantation (See 3.5).

Other intraoperative complications of cataract surgery include wound complications, detachment of Descemet's membrane, thermal injury from the phaco tip, tears in

capsulorhexis, iris prolapse, problems with IOL insertion, anterior segment hemorrhage and dropped nucleus. Postoperatively the most common are astigmatism, corneal edema, hyphema, intraocular pressure elevation, sterile inflammatory reactions and IOL decentration.^{4;20} Because not directly related to the scope of this study, they are only briefly mentioned here.

3.1.4 Evaluation of outcome

As a result of the transition from intracapsular cataract surgery to small incision surgery, advertising of and expectations relating to cataract surgery have increased dramatically. The associated needs for accurate methods for evaluating the outcome of cataract surgery have brought new methods of analysis.

The outcome of cataract surgery can be classified according to subjective and objective findings. Subjective findings of functional vision are evaluated best with interviews or questionnaires, and several of them are available.^{5;26;42-50} Perhaps the most widespread is the visual functioning index, VF-14, introduced in 1994 to measure visual impairment caused by cataract.⁴² Recently, it has also been used in other settings as well.⁵¹⁻⁵³ Objective measures of functional vision include also other parameters besides best corrected visual acuity (BCVA) - such as uncorrected visual acuity, contrast sensitivity, glare disability, visual field and color vision. They all measure different aspects of visual performance providing a general view of the functional vision. Evaluation of this kind is also valuable because of the still long waiting lists and consequent economic pressure.

3.2 POSTERIOR CAPSULE OPACIFICATION (PCO)

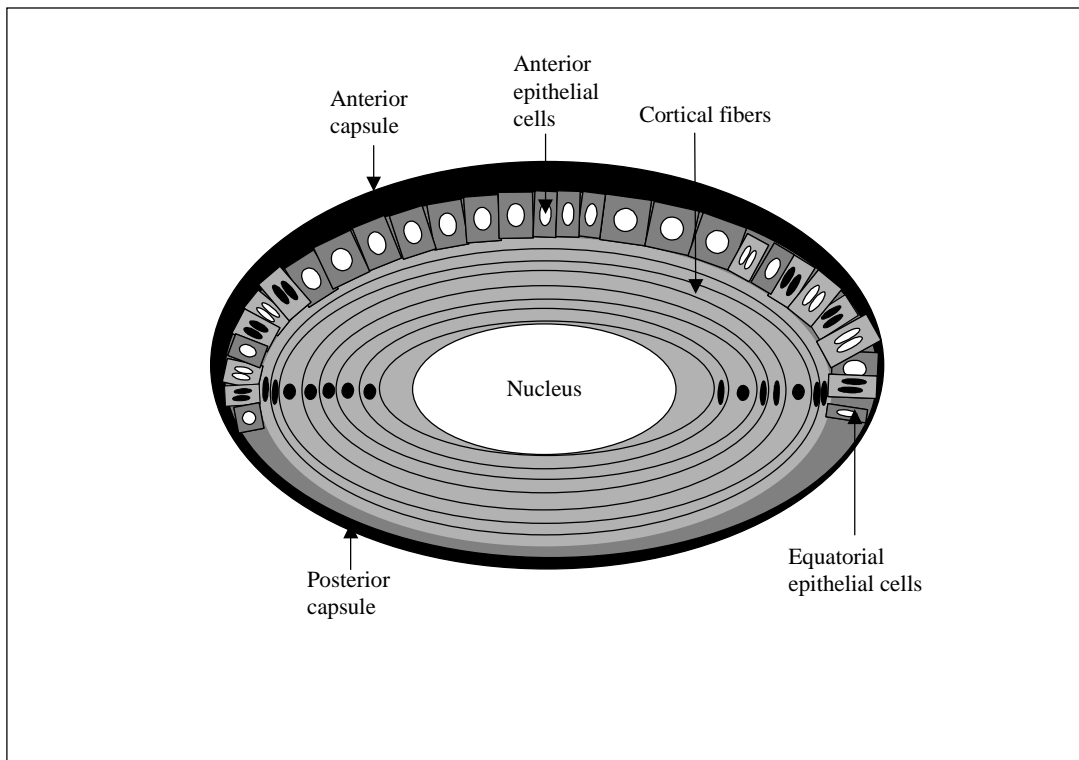
3.2.1 Pathogenesis

The posterior capsule is a basement membrane forming a complete sheath around the lens. It is thickest anteriorly, 14-20 μ m, and much thinner posteriorly, only 3-4 μ m, because the lens epithelium stops at the equator of the adult lens.^{20;54}

The pathogenesis of PCO has been well documented in the literature. Most cases of clinically significant PCO are caused by proliferation and migration of residual lens epithelial cells and their derivatives after cataract surgery.⁵⁵⁻⁶² In the normal lens, the epithelium consists of

cuboidal anterior epithelial cells, which are continuous with the cells of the equatorial lens bow (Figure 2).⁵⁸ These two types of lens epithelial cells react in different ways following external stimuli.

Figure 2. A schematic drawing of the lens and the epithelial cells



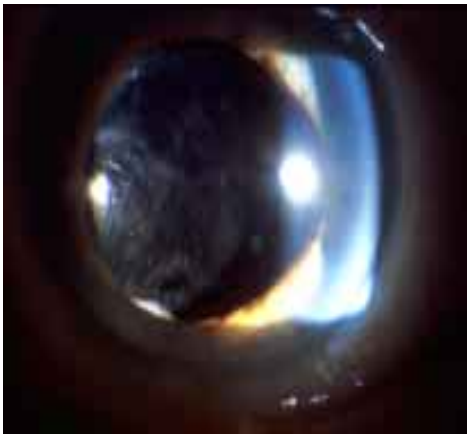
The **anterior epithelial cells** primarily differentiate into spindle-shaped, fibroblast-like myofibroblastic cells, which are able to contract.^{58;63} The contraction may cause folds and wrinkles of the posterior capsule similar to those seen in anterior polar cataracts.⁵⁵ In more advanced stages, white fibrotic opacities develop, leading to increasing capsular wrinkling and decreasing best corrected visual acuity (BCVA).^{58;63}

The **equatorial epithelial cells** comprise the germinal cells, which are the primary cells in the origin of PCO. They normally migrate centrally from the lens equator and contribute to the formation of nucleus, epinucleus, and cortex throughout life. Instead of undergoing a fibrotic transformation, they tend to migrate backward and form large, balloon-like clusters called pearls. They were first noticed by Hirschberg in 1901, and then by Elschnig in 1911, and are nowadays referred to Elschnig's pearls.¹ The diameter of these cells is in the range of 5-120 μ m.


Each pearl probably represents the aberrant attempt of one epithelial cell to differentiate into a new lens fiber.^{58;62;63}

As epithelial cells proliferate and migrate onto the posterior capsule, two main types of opacities are often clinically differentiated. It is thought that anterior epithelial cells play a major role in the pathogenesis of **the fibrosis-type of PCO** (Figure 3A), and equatorial epithelial cells account for **the pearl-type of PCO** (Figure 3B).^{1;58;62-64} The equatorial cells are also responsible for the formation of **Soemmerring's ring**, which is a doughnut-shaped lesion composed of retained or regenerated lens cortex and cells, and which may form after any type of disruption of the anterior lens capsule.^{63;65} Clinically significant PCO decreases visual acuity, impairs contrast sensitivity, increases glare and can cause monocular diplopia.^{58;66}

Figure 3. A Fibrosis – type of posterior capsule opacification



B Pearl – type of posterior capsule opacification



3.2.2 Incidence

Clinical studies of PCO differ considerably in many ways. In many studies, a clear definition of significant PCO is lacking, the methodology is inaccurate and different surgical techniques and IOL styles are used.^{9;37;67} Also the follow-up times are very different, which makes comparisons difficult. However, it is clearly shown, that an inverse age-related tendency toward PCO formation exists. In general, the older the patient at the time of cataract surgery, the lower the incidence of PCO.^{58;68-70} It is estimated that nearly all pediatric patients will develop PCO within two years of surgery unless a primary capsulotomy or other preventive measures are implemented.^{22;58} The incidence of PCO also increases with time after cataract surgery, and studies with very short follow-up times are thus inaccurate.

In a review of 90 studies related to complications following cataract extraction with IOL implantation, the pooled percentage of eyes experiencing PCO was 20%.³⁷ In a meta-analysis of 49 studies, published in 1998, the overall pooled estimate of the incidence of PCO was 12% at 1 year, 21% at 3 years and 28% at 5 years after surgery.⁹ It was concluded that visually significant PCO develops during the first 5 years after surgery in more than 25% of patients undergoing standard extracapsular cataract extraction and phacoemulsification with posterior chamber IOL implantation.

The incidence of PCO has also been shown to be dependent on the shape and material of the IOL. When comparing PMMA, silicone and acrylic IOLs, the PMMA lenses have the highest PCO rates (9-50%), and the acrylic lenses the lowest (0-14%).^{1;40;65;67;69;71-84}

3.2.3 Prevention

Based on the pathogenetic factors, the principles of prevention of PCO are to minimize the amount of retained epithelial cells and lens cortex and, if some cells do remain, to provide a secondary line of defense to prevent them from migrating centrally over the visual axis.^{58;62-65;67;70;85;86} No generally accepted method of preventing PCO is yet available, but the main principles are summarized here.

3.2.3.1 Intraoperative techniques

It has been noticed that, in addition to ensuring the overall safety of the operation, careful, subcapsular hydrodissection of the nucleus and cortical layers in association with a continuous curvilinear capsulorhexis (CCC) may be more successful than previously assumed in decreasing the frequency of PCO.^{62;63;65;71;87-91} Creating a CCC slightly smaller in diameter than that of the IOL optic places the edge of the capsulorhexis on the anterior surface of the optic. This helps to provide a tight fit of the capsule around the optic and also seals the optic from the surrounding aqueous humor, which contains macromolecules and inflammatory mediators.^{1;65;71;92}

Optimal positioning of the IOL is thought to be important in reducing PCO.^{58;63;71;87} In the late 1980s, in-the-bag fixation was achieved in 30% of cases.^{84;90} With modern methods of surgery, the IOL is positioned in the bag in over 90% of eyes.^{65;84;90} The barrier effect against lens epithelial cells is maximal, when the lens optic is fully in-the-bag and in direct contact with the posterior capsule. When one or both haptics are out of the bag, a potential space exists that allows a route for ingrowth of cells toward the visual axis.

3.2.3.2 IOL design

The IOL design, including choice of lens material, has been noticed to be an important factor influencing the development of PCO.^{86;91;93-96} The bioactivity of the IOL (its ability to regulate epithelial cellular proliferation) is postulated to explain the difference in PCO rates with different IOL materials.^{65;97;98} When the IOL allows a single layer of lens epithelial cells to adhere simultaneously to both posterior capsule and the IOL, producing a sandwich-like pattern, this will probably reduce the amount of epithelial cells inside the posterior capsule resulting in smaller amounts of PCO.^{97;98}

The influence of IOL lens design on PCO, especially posterior angulation of the haptic and posterior convexity of the optic, has been recognized for many years.^{64;99;100} Virtually all IOLs are manufactured now in a posterior convex or biconvex format so that the posterior capsule and optic surface are apposed. As a result, capsular surface is stretched radially and flattened, so there should be no room for the cells to pass this mechanical barrier and migrate onto the center of the posterior capsule.^{70;86;95;99-104}

3.2.3.3 Pharmacological agents

To prevent PCO, instillation of several drugs on the posterior capsule during cataract surgery has been tried. The main aim is to kill the remaining lens epithelial cells, to inhibit their proliferation and migration and to minimize intraocular inflammatory reaction after surgery. Antimetabolites, cytotoxic drugs, immunotoxins and antiprostaglandins have all been used effectively *in vitro* and *in vivo* in experimental animal studies.¹⁰⁵⁻¹¹³ The problem is limiting the effect to the lens epithelium and protecting the rest of the eye. Animal experiments have documented toxic effects on corneal endothelial, iris, ciliary pigment epithelium and retinal cells.^{86;93} A practical, effective and safe method of preventing PCO with pharmacological agents is not yet available.

3.2.4 Treatment

Before the era of Nd:YAG laser posterior capsulotomy, there were two possibilities to treat PCO; primary or secondary surgical capsulotomy and surgical polishing of the posterior capsule.¹¹⁴⁻¹²⁰ Soon it was noticed that to minimize postoperative complications such as CME or RD, it is important to keep the posterior capsule intact if possible.¹²¹ Aspiration of Elschnig's pearls and polishing of the posterior capsule may be performed especially in highly myopic eyes that may benefit from preservation of an intact posterior capsule. However, it is often a temporary solution because recurrence of Elschnig's pearls is very common.

After the introduction of the Nd:YAG laser, LCT became the method of choice in treating PCO with good results as regarding visual acuity, contrast sensitivity and lack of glare.^{40;66;117;122-125} Alternatives to LCT are also studied, e.g. polishing with a neodymium:yttrium-lithium-fluoride picosecond laser. A polishing effect in an artificial latex posterior capsule was achieved, but with higher energy settings the IOL was damaged.¹²⁶

3.3 Nd:YAG LASER POSTERIOR CAPSULOTOMY (LCT)

3.3.1 Principles of Nd:YAG laser

The introduction of Nd:YAG laser (neodymium:yttrium-aluminum-garnet) to eye surgery took place in 1973, when Beckman used it for thermal cyclodestruction.¹²⁷ In the same year, Krasnov showed that optical breakdown of transparent non-absorbing tissue by high power

pulsed laser was possible.¹²⁸ The use of the Nd:YAG laser was permanently established in ophthalmology independently by Fankhauser in Switzerland¹²⁹ and Aron-Rosa in France (Figure 4A and B).^{130;131}

The active element of a neodymium laser consists of neodymium atoms embedded in a crystal structure. The most successful host for neodymium lasers is the yttrium-aluminum-garnet crystal- $Y_3Al_5O_{12}$, known as YAG. The Nd:YAG laser is pumped by a gas discharge lamp. The pump energy is absorbed by the neodymium atoms, which are then excited into a higher energy level. Finally a highly irradiating light pulse at a wavelength of 1064 μm is emitted. The laser beam is invisible but is focused to the target tissue with a helium-neon guiding laser beam. When focusing the emitted laser energy into a very small region, a sudden temperature rise of approximately 10 000°C is generated.¹³¹⁻¹³⁵ In such a temperature all matter is transformed into a gaseous state. All atoms of this gas become ionized, releasing free electrons. The neutral atoms, emerged ions and free electrons all move at high velocity and collide with each other. This state of matter is referred to as plasma, because it differs in its physical properties from normal gas. The phenomenon itself is designated optical breakdown.^{131-133;135}

Two main types of Nd:YAG laser devices exist: Q-switched and mode-locked. In a Q-switched laser, the laser pulse is typically 8 to 15 nsec in duration. A mode-locked laser pulse train is composed of seven to eight individual pulses, each of which has a duration of 10 to 15 psec; the total pulse train lasts for 30 nsec. In both models, the intention is to create very brief pulses of energy.¹³³

The Nd:YAG laser causes an ionizing, photodisruptive effect. The instantaneous high temperature rise generates an acoustic and hydrodynamic shock wave that results in tissue disintegration. It is thought, that several physical phenomena are responsible for the photodisruptive damage observed clinically; ionization, high temperature, generation of UV light-induced photochemical processes, acoustic transients, electrical field stress and cavitation.¹³¹⁻¹³⁵

Figure 4. A A schematic drawing of LCT

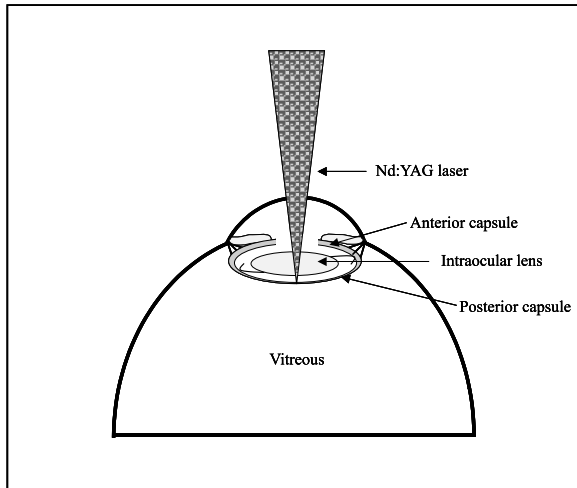
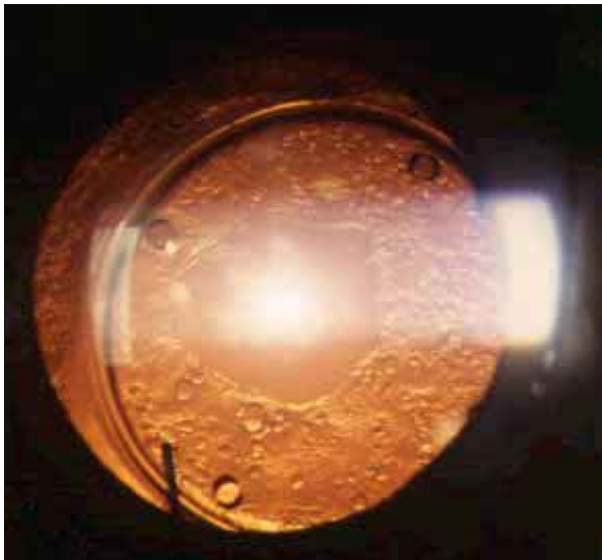


Figure 4. B Posterior capsule after LCT



3.3.2 Complications

Even though LCT was first thought to be a very safe, non-invasive method to treat PCO, several complications of LCT have been reported.¹³⁶ Indeed, because of the abruptness of the plasma formation and the acoustic and hydrodynamic shock wave that it produces, the Nd:YAG laser can cause severe complications, especially if used incorrectly.

A frequent complication is damage to the intraocular lens (IOL), which occurs even in 20-40% of cases.¹³⁶⁻¹⁴³ It is more likely to occur if the lens is in close proximity to the posterior capsule and if the membrane is thick.¹³⁶ There appears to be a direct correlation between IOL damage and the total laser power used, the number of laser pulses, and the number of pulse trains used.¹³⁶ The resulting pitting or marking of the IOL is thought to be mostly harmless, but some evidence of inducing glare and contrast vision has been published.¹⁴⁴

Another frequently reported complication is rupture of the anterior hyaloid face, which occurs in 10-30% of cases.^{13;136;141;143} Instead of a usual consequence, it is thought to be a complication, because it allows the vitreous to move anteriorly. In aphakic eyes this anterior movement may cause a pupillary block and induce CME, RD and late-onset corneal edema.

Another major complication of Nd:YAG capsulotomy is increased intraocular pressure, which can occur in up to 30% of cases.^{13;136;137;139;140;142;143;145-150} The IOP rise is usually transient but can also be permanent. It is seen in eyes with pre-existing glaucoma as well as in normotensive eyes. Because antiglaucoma therapy (e.g. topical apraclonidine) is now used routinely, is it a rare complication, but nevertheless glaucoma patients are recommended to have careful follow-up for persistent pressure elevations.^{136;137;146;147}

It is believed that the incidence of CME following LCT ranges from 0.4% to 3%. When evaluated with fluorescein angiography, the frequency increases up to 13%.^{136;139;141-143;145;147-153} It is less likely to occur if the interval between cataract surgery and Nd:YAG laser capsulotomy is long, at least 3 months.^{136;154;155}

Intraocular infection has been reported to occur after LCT in rare cases. It is thought to be due to release of pre-existing bacteria encapsulated between the IOL and posterior capsule.^{156;157} Other less frequently encountered complications include corneal edema, bleeding, iris damage, IOL luxation into the vitreous cavity, pupillary block, iritis, vitreous opacification, vitritis, retinal hemorrhage and prolapse of vitreous, intraocular gas or silicone into the anterior chamber.^{136-140;142;143;147;148;158;159}

3.3.3 Effects on vitreoretinal structures

The effects of Nd:YAG laser on vitreoretinal structures have been studied both in experimental animals and in clinical practice. The transmitted light, thermal energy, shock waves, and re-emitted light all have to be considered as potential hazards to vitreoretinal structures.^{132-135;160;161}

It is thought that the laser light transmitted beyond the focus is divergent and will thus spread over a large area of the retina, unless coming too close to it.^{135;160;162;163} In an experimental study of vitreous membranes in rabbit eyes, Q-switched Nd:YAG was able to cut vitreous membranes up to 4 mm from the retinal surface with single pulse energies of up to 4 mJ without fluorescein angiographic evidence of retinal injury. When treating strands closer to the retinal surface, injury was documented in five of seven cases¹⁶⁴. In another animal study, laser pulses could not be focused within 2 mm of the retina without substantial risk of retinal damage.¹⁶²

In human eyes, accidental retinal injuries of the macular area have also been reported. In those cases rupture of a retinal vein, hemorrhage, macular or paramacular hole and damage to small areas of pigment epithelium were recorded.¹⁶⁵⁻¹⁶⁷

The temperature in the plasma becomes very high for a short period of time. Tissues at or near the zone of optical breakdown are subject to extremely high temperatures with vaporization and damage.¹³³⁻¹³⁵ This heat is localized and is thought not to cause damage more than 200 microns from the center of the focal zone. The shock wave effect (acoustic transient) of the ultrasonic frequencies can be seen most easily, when breakdown occurs near a vitreous strand, which will vibrate strongly.¹³⁵ The re-emitted light flash observed at the optical breakdown zone contains a broad band of visible and ultraviolet radiation. This light has little energy and is not known to have deleterious effects in the eye.^{133-135;168}

Animal studies have shown diffuse changes in the vitreous body when optical breakdown occurs in the anterior vitreous near the posterior capsule. In a study with monkey eyes a decrease in viscosity of vitreous gel after Nd:YAG laser treatment of either the posterior capsule or the mid-vitreous was detected.¹⁶⁹ It was thought that these changes represented increased vitreous liquefaction and probably resulted from a depolymerization process caused

by acoustic transients accompanying the laser irradiation.¹⁶⁹ However, in another study in rabbits no direct deleterious effects on the structural integrity of the normal vitreous body were noticed.¹⁷⁰

3.4 RHEGMATOGENOUS RETINAL DETACHMENT (RD)

3.4.1 Pathogenesis

In rhegmatogenous RD, the neuroretina separates from the pigment epithelium, because fluid from vitreous cavity passes under the neuroretina through a retinal break. The series of events usually begins from vitreous liquefaction, which induces posterior vitreous detachment (PVD). The latter causes a retinal break at the site of former vitreoretinal adhesion. The normal retinal attachment is maintained by adhesive-like mucopolysaccharides in the subretinal space, oncotic pressure differences between the choroid and subretinal space, hydrostatic forces related to intraocular pressure, and metabolic transfer of ions and fluid by the retinal pigment epithelium.^{8;40;171;172} Retinal detachment occurs when the combination of factors that promote retinal detachment overwhelms the normal attachment forces.

3.4.1.1 Retinal breaks

Retinal breaks are classified as holes and tears.^{8;40} Retinal hole is a full-thickness retinal defect that is not thought to be associated with persistent vitreoretinal traction. It occurs usually as a result of localized atrophy of the retina especially in association with retinal lattice degeneration in myopic or otherwise elongated eyes. Retinal tears are usually produced by PVD and subsequent vitreoretinal traction at the site of a significant vitreoretinal adhesion such as the posterior borders of vitreoretinal degenerations or scars. Vitreous traction usually persists at the edge of a tear, resulting in progression of RD. The incidence of retinal breaks in autopsied individuals over 20 years of age ranges from 4 to 11%.^{8;40;173}

3.4.1.2 Posterior vitreous detachment

The vitreous is a gel-like structure, about 4 ml in volume, that fills the posterior cavity of the eye. It consists mainly of water (99%), but contains also a meshwork of fine collagen fibrils and spheroid hyaluronic acid molecules.^{8;20;40} With aging, several structural changes occur in the

vitreous. The central parts become liquefied and the configuration of hyaluronic acid molecules changes. These changes lead gradually to PVD, a separation between the posterior vitreous cortex and the internal limiting membrane of the retina.^{8;20;40}

The time point of PVD is individual. In an autopsy study PVD was present in less than 10% of patients under the age of 50, and in 63% of patients above the age of 70.¹⁷⁴ In a clinical survey, however, only 11% of eyes among 65 to 69 year-old patients exhibited a complete PVD. In the age group of 80 to 89 years, 46% had a complete PVD.¹⁷⁵

In association with acute, symptomatic PVD, 4-46% of eyes have been reported to develop a peripheral retinal break.¹⁷⁶⁻¹⁸³ The average risk for these breaks of progressing to retinal detachment is reported to be 35%.⁸ Therefore, any retinal break associated with acute symptoms is often prophylactically photocoagulated.^{8;40;179;184-186} Asymptomatic retinal breaks in phakic eyes with no RD in the fellow eye do not usually progress to RD even after PVD, and prophylactic treatment is recommended only if subretinal fluid accumulates.^{40;184;187-193}

3.4.2 Predisposing factors

In the general population, the annual incidence of RD is approximately 1:10 000.^{8;194} However, a variety of ocular conditions are associated with increased prevalence of vitreous liquefaction and PVD, and with increased number and extent of vitreoretinal adhesions. These conditions, based on the pathogenetic factors, also are associated with increased risk for RD. Particularly important risk factors for RD in phakic eyes are high myopia, lattice degeneration, history of RD in the fellow eye, and blunt or penetrating ocular trauma.^{8;40;195}

In a case-control study 253 patients with idiopathic RD were compared with 1,138 controls.¹⁹⁶ It was found that an eye with a refractive error of -1 to -3 D had a fourfold risk of RD, and if the refractive error was greater than -3 D, the risk increased 10-fold compared with a nonmyopic eye.¹⁹⁶ Degenerative changes in the peripheral retina and vitreous are thought to predispose the myopic eye to RD.⁸ Retinal breaks and lattice degeneration, important risk factors for RD, are also reportedly more common in myopic eyes.^{8;197} Finally, liquefaction of vitreous, resulting in PVD, occurs earlier than average in myopic eyes.^{8;40}

Lattice degeneration of the peripheral retina is a condition in which retinal thinning is associated with a pocket-like liquefaction and separation of overlying vitreous. A condensed vitreoretinal adhesion also occurs at the margin of lattice lesions. Lattice degeneration is present in 11% of autopsy eyes, occurring equally in men and women, and increases in incidence with age and AL.⁸ Up to 25% of areas of lattice degeneration include a retinal break.⁸ In eyes with a rhegmatogenous RD, lattice degeneration is present in up to 30%.⁸ However, the great majority of eyes with lattice degeneration are not at a particularly high risk of RD. The risk for developing RD in an otherwise normal eye is estimated to be small.¹⁹⁸ Prospective randomized trials of prophylactic therapy to prevent RD have not been performed, but routine laser treatment of lattice degeneration and asymptomatic retinal holes in otherwise normal eyes is not recommended.^{8;184;198-200}

Of patients with RD, up to 20% are reported to have asymptomatic retinal breaks in the fellow eye.^{8;201;202} The recommendations about prophylactic therapy of lattice degeneration and retinal breaks in fellow eyes are controversial.^{8;184;187;188;201-206} It has been noticed that RD can frequently develop from a new retinal break in previously healthy retinal areas.^{179;180;203;204;207} Risk factors of RD may also be additive. Blunt trauma in a myopic eye with degenerative changes of peripheral retina is more likely to be complicated with RD than in a normal eye without pathologic conditions.

3.4.3 Prevention

Although prevention of RD is an important goal, so far there have not been prospective, double-blinded clinical trials reported to test the true value of preventive treatment.¹⁹⁹ According to its pathophysiology, RD could be avoided by preventing vitreous liquefaction and associated PVD, relieving vitreoretinal traction or creating a chorioretinal adhesion around vitreoretinal adhesions and retinal breaks. For practical reasons, the last of these three ways is the only one used, created by laser photocoagulation or cryocoagulation. It is generally accepted, that symptomatic patients with a horseshoe-shaped tear should be treated prophylactically because of increased risk of RD. However, other indications of preventive treatment remain controversial. It is often recommended that in patients with rhegmatogenous RD, degenerative retinal lesions of fellow eyes, such as lattice degeneration, round holes or flap tears should be treated even in asymptomatic patients. Laser

photocoagulation is preferred over cryopexy because chorioretinal adhesion appears more quickly, it causes less breakdown of the blood-retina barrier, and it may have a lower incidence of epiretinal membrane formation. No generally accepted guidelines exist of prophylactic treatment of retinal breaks in eyes planned to undergo cataract surgery or LCT.^{8;40;184;199;200;206;208-210}

3.4.4 Treatment

The main goal in managing RD is closing every retinal break to re-establish the physiologic conditions that normally maintain the contact between the neural retina and pigment epithelium. Long-term closure of retinal breaks may also require permanent reduction or elimination of vitreoretinal traction. The minimal procedure to safely achieve the goal is recommended.^{211;212} The main options for the management of primary rhegmatogenous RD are laser demarcation, cryocoagulation, pneumatic retinopexy, scleral buckling (segmental or encircling), and vitrectomy. The scleral buckling and creation of a chorioretinal adhesion around each break is nowadays the most frequent technique. Vitrectomy and combinations of both techniques are performed if failure of scleral buckling is likely, such as in eyes with a very large tear, no visible breaks, posteriorly located tears and dense vitreous hemorrhage.

3.4.5 Outcome

Nearly all symptomatic rhegmatogenous retinal detachments progress to total blindness unless they are repaired. Until 70 years ago, rhegmatogenous RD was an essentially incurable disorder. Nowadays recent technical advances and better understanding of the pathogenesis of RD have lead to excellent results especially anatomically.²¹³⁻²¹⁶ The best results are achieved, when primary RD is operated on before the development of macular detachment.^{215;217-221} The outcome of RD surgery can be expressed in several ways; anatomical, visual and functional.

3.4.5.1 Anatomical outcome

The result is anatomically good, when the retina returns to its normal position with no residual subretinal fluid, and remains attached. With recent surgical techniques the final anatomical success rate (with one or more operations) is 90-98%.^{211;215;216;222-228} The two most common reasons for failure are proliferative vitreoretinopathy (PVR) and a failure to close all

retinal breaks.^{8;211;215;220;222;223} In PVR, primarily retinal pigment epithelial and glial cells grow on both the inner and outer retinal surfaces and on the vitreous face, forming membranes. Contraction of these membranes causes fixed retinal folds, traction and generalized retinal shrinkage. As a result, the primary retinal breaks may reopen, new breaks may occur, or a tractional detachment may develop.^{40;229}

3.4.5.2 Visual outcome

The visual outcome after RD surgery is generally considered good, if BCVA is 0.5 or better in Snellen fractions. Visual and anatomical outcome are often somewhat different; the retina may remain attached, but the retinal function may not be well preserved. The visual results depend on the extent of damage to the macula caused by the RD. If the macula becomes detached by subretinal fluid, some degree of permanent damage to vision usually occurs in spite of surgical reattachment, however early. The most important predictors of visual recovery after RD surgery are preoperative BCVA and the duration of macular detachment.^{215;216;218;219;221;223;228;230-236} However, visual function may reimprove in the long term especially in younger patients and after macular detachment of short duration.²¹⁸

If the macula is detached, only 50% of patients gain a BCVA of 0.5 or better.^{8;216;217;221} In eyes with attached macula, up to 80-90 % can gain a better BCVA than 0.5. It must also be remembered though that about 10% of eyes with almost normal vision preoperatively undergo some degree of visual loss after a successful repair of a macula-sparing detachment. Among others the reason for this is gradually developing PVR in the form of epiretinal membranes.⁸

3.4.5.3 Functional outcome

The functional outcome has been measured more often after cataract than after vitreoretinal surgery with several questionnaires, such as VF-14, Cataract Symptom Score and others.^{10;26;32;42-46;48-50;237-239} Only a few reports of vitreoretinal surgery have been published so far, and none of them was related solely to RD surgery.^{53;240-242} The first study, published in 1993, comprised patients with RD, diabetic retinopathy, retinal vein occlusion, and other vitreoretinal diseases. It was based on a five-item questionnaire answered by 123 patients.²⁴² In 1997 and 1998, binocular visual function was evaluated in 187 patients after vitrectomy for uncomplicated and complicated RD and macular pucker. The conclusion was that visual

function improved after surgery even among those who had normal vision in the fellow eye.^{240;241} The VF-14 was recently tested with 546 patients with vitreoretinal disease, 14% of whom had RD. The median VF-14 score was 92, but the score after RD surgery was not separately reported.⁵³

3.5 PSEUDOPHAKIC RETINAL DETACHMENT

3.5.1 Special risk factors

The baseline risk factors for pseudophakic RD are the same as mentioned before, i.e. myopia, lattice degeneration, and history of RD in the fellow eye.^{10;210;243-252} However, the cataract surgery itself by changing intraocular circumstances, is also a risk factor for RD. A physiologic barrier composed of anterior hyaloid, posterior capsule, zonules, and posterior chamber IOL, exists between the anterior and posterior parts of the eye after uncomplicated extracapsular cataract surgery. After extracapsular cataract surgery, the risk of pseudophakic RD is reported to be 0.05-1.7%.^{6;249;253-260} The risk associated with modern phacoemulsification is thought to be even smaller, but no prospective randomized studies comparing these procedures have been published.

The barrier effect of the lens diaphragm is lost at least to some extent after posterior capsule rupture or capsulotomy, and even more after ICCE, and the eye is then subject to changes in the vitreous and vitreoretinal interface and thus to an increased risk for RD.^{121;155;246;253;257;261-271} After ICCE, the risk of RD is reported to be 0.8 - 5.7%.^{249;256;272-280} If the posterior capsule ruptures, vitreous loss occurs, or secondary capsulotomy is performed, the risk of RD is reported to be fourfold as compared with uncomplicated cataract extraction only.^{10-12;253}

In a study of 201 postmortem eyes, posterior vitreous detachment was present in 84% of eyes following ICCE as compared with 40% after ECCE with an intact posterior capsule. If a surgical capsulotomy had been done, the frequency of PVD was found to be nearly equal to ICCE (76%).²⁸¹ It is thought that the high incidence of retinal tears in aphakic eyes is probably due to the greater freedom of movement of the vitreous, when the lens no longer supports it. This increased movement results in greater pull on the peripheral retina, if the vitreous is still attached to it.^{268;269;271;282;283}

In one post-mortem study the amount of hyaluronic acid in vitreous was significantly decreased in aphakic eyes compared with phakic ones.²⁸⁴ The loss of hyaluronic acid, a structural stabilizer of the vitreous, seems to predispose the vitreous to liquefaction and PVD. The exact clinical effect of this fact on the risk of RD is uncertain.

3.5.2 Special characteristics

The pseudophakic RD differs somewhat from a phakic one. Many retinal breaks are more anterior and smaller than in phakic RD and apparently created by zonular pull. In 15-20% no breaks are found even preoperatively.^{8;40;285-292} The visibility of peripheral retina is often more difficult because of semi-dilated pupil, rim of IOL and remnants of PCO even after LCT.^{285;293} Sometimes LCT must be done preoperatively to get better visualization of retinal periphery.

3.5.3 Retinal detachment after LCT

The most common potentially blinding complication of LCT is RD, which reportedly occurs in 0.17% to 4.2% of treated eyes.^{12-15;36;139;140;142;143;145;147-150;153;249;252;271;294-302} The exact mechanism, which leads to RD is unclear, although several theories have been proposed.

When LCT is done, a physiological barrier that persists after uncomplicated extracapsular cataract surgery is broken and the incidence of RD and CME increases.^{155;257;270} When examining the distribution of fluorescein in human eyes, it was found that the fluorescein diffused into the vitreous similarly after ICCE or capsulotomy, and significantly less in eyes with an intact posterior capsule.²⁶³ In another study, the in-the-bag fixated IOL best protected the barrier of the eye.²⁷⁰ Altered barrier effect may be related to the decreased hyaluronic acid content of the vitreous and thus to vitreous liquefaction. In experimental studies, loss of hyaluronic acid after capsulotomy occurs, leading first to vitreous degeneration and then via PVD to RD.^{281;284} It remains unclear whether Nd:YAG laser treatment is more likely to cause vitreous changes and retinal damage when used in an eye with pre-existing disturbance of the vitreous, for example in highly myopic eyes.

3.5.4 Treatment

The treatment of pseudophakic RD differs somewhat from that of phakic eyes, mainly because of problems with visibility and characteristics of pseudophakic RD. There are several reports advocating the superiority of scleral buckling or vitrectomy as a primary procedure in pseudophakic RD, but this question remains controversial.³⁰³⁻³⁰⁸ To compare anatomic and functional results of these procedures, a randomized prospective study is recommended.

3.5.5 Outcome

The main factors related to the outcome of pseudophakic RD are the same as in phakic RD, i.e. preoperative BCVA and the duration of macular detachment.^{234;235} Lower anatomic success rates have been reported in eyes with anterior chamber IOLs.³⁰⁹⁻³¹¹ In other studies, however, it has been reported that the anatomic and visual results of reattachment surgery were much more influenced by characteristics of the detachment and by PVR than by techniques and complications of cataract surgery.^{285;286;312-314} With modern surgical techniques the anatomic success rate of pseudophakic RDs is reported to vary from 76% to 99%.^{221;285-289;291;304-306;309-320}

4 AIMS OF THE STUDY

The purpose of this study was to better clarify the etiology, pathogenesis, characteristics and outcome of pseudophakic RD after Nd:YAG laser posterior capsulotomy. The main principle was to look for any differences between RDs that occur after cataract extraction in eyes with an intact posterior capsule as compared with those having undergone LCT (I). To identify clinically important features of RDs and to determine relative frequency of retinal holes or breaks, a retrospective study of the type and characteristics of RD after LCT was designed (I).

A prospective follow-up study (II, III) was designed to find out whether there are significant numbers of asymptomatic retinal breaks in eyes scheduled for LCT, and if there will be some, at what stage they will develop. At the second stage of the study, it was important to find out whether fewer RDs took place in the subgroup, which had been closely followed and in which asymptomatic retinal breaks had been prophylactically photocoagulated.

To compare the long-term outcome of pseudophakic RD in eyes with an intact posterior capsule and LCT, a cross-sectional analysis was done (IV).

5 PATIENTS AND METHODS

5.1 PATIENTS

Each study protocol was accepted by the Institutional Review Board of The Helsinki University Central Hospital, Department of Ophthalmology. All enrolled patients gave their written informed consent.

5.1.1 Retrospective cohort study (I)

The inclusion criteria into this retrospective cohort study were that an uncomplicated cataract extraction had been done to an eye that later developed a RD. From 1034 patients who had been operated on for primary rhegmatogenous RD in the Helsinki University Eye Hospital in years 1992-1996, 129 patients (eyes) fulfilled the inclusion criteria and were enrolled into the study. LCT had been performed on 61 of these eyes before RD (capsulotomy group), and in 68 eyes the posterior capsule was intact (control group).

5.1.2 Prospective studies (II, III)

The inception cohort to the first stage of the prospective study (II) were 350 consecutive patients referred to a primary Nd:YAG LCT of a particular eye to Helsinki University Eye Hospital since October 1994.

When determining the number of patients needed in the study, the null hypothesis was that no untreated retinal breaks are present in eyes referred for LCT and that no new breaks develop during this procedure. The alternative hypothesis was that the frequency of such retinal breaks would be at least 2%, based on the lowest frequency of retinal breaks in the general population. This was considered to be the minimum clinically significant frequency, given the 0.5% lower limit of the incidence of RD after LCT and presuming that not more than every fourth break might lead to RD in a capsulotomized eye. Setting alpha to 0.05 and beta to 0.1, the minimum sample size required to discard the null hypothesis with 90% power was 189 eyes. To allow for 10% loss to follow-up, the projected sample size was set at 210 eyes. A prospective follow-up of 5 years was planned.

The Stage I of the study was closed in February 1996. Inclusion criteria for this study were the patient's written informed consent, a need for LCT, and visibility of the retinal circumference at least to the equator. 211 of 350 eligible patients (220 eyes) completed all three outpatient visits (inclusion rate, 60%). It was allowed that the patient could be enrolled later for LCT of his or her second eye. According to the Institutional Review Board, the patient was advised about the possibility of prophylactic treatment, and all patients in this study chose to have the asymptomatic retinal break treated.

In Stage II (III), the 211 patients were invited to an outpatient visit. During the interim 52 of them had deceased, and 53 elected not to participate because of ill health, difficulties with traveling, or other social reasons. Thus 113 study eyes of 106 enrolled patients were re-examined (inclusion ratio, 50%). In addition, patient charts of the primary inception cohort (350 eyes) were reviewed for retinal events.

5.1.3 Cross-sectional study (III)

The inclusion criteria in this retrospective, non-comparative, interventional series, were a pseudophakic RD after a strictly uncomplicated extracapsular cataract surgery and implantation of a posterior chamber IOL and a written informed consent. Those patients, who had had vitreous or posterior capsule complications during cataract surgery, were ineligible. 138 of 1127 patients, who had been operated on for a primary rhegmatogenous RD in the Helsinki University Eye Hospital in 1990-1995 fulfilled the inclusion criteria and were invited to an outpatient visit. Of the 138 patients, 101 (73%) were enrolled. In addition to a retrospective chart review, clinical examination and a structured interview to determine patient satisfaction and quality of life were undertaken.

5.2 METHODS

5.2.1 Collection of retrospective data (I-IV)

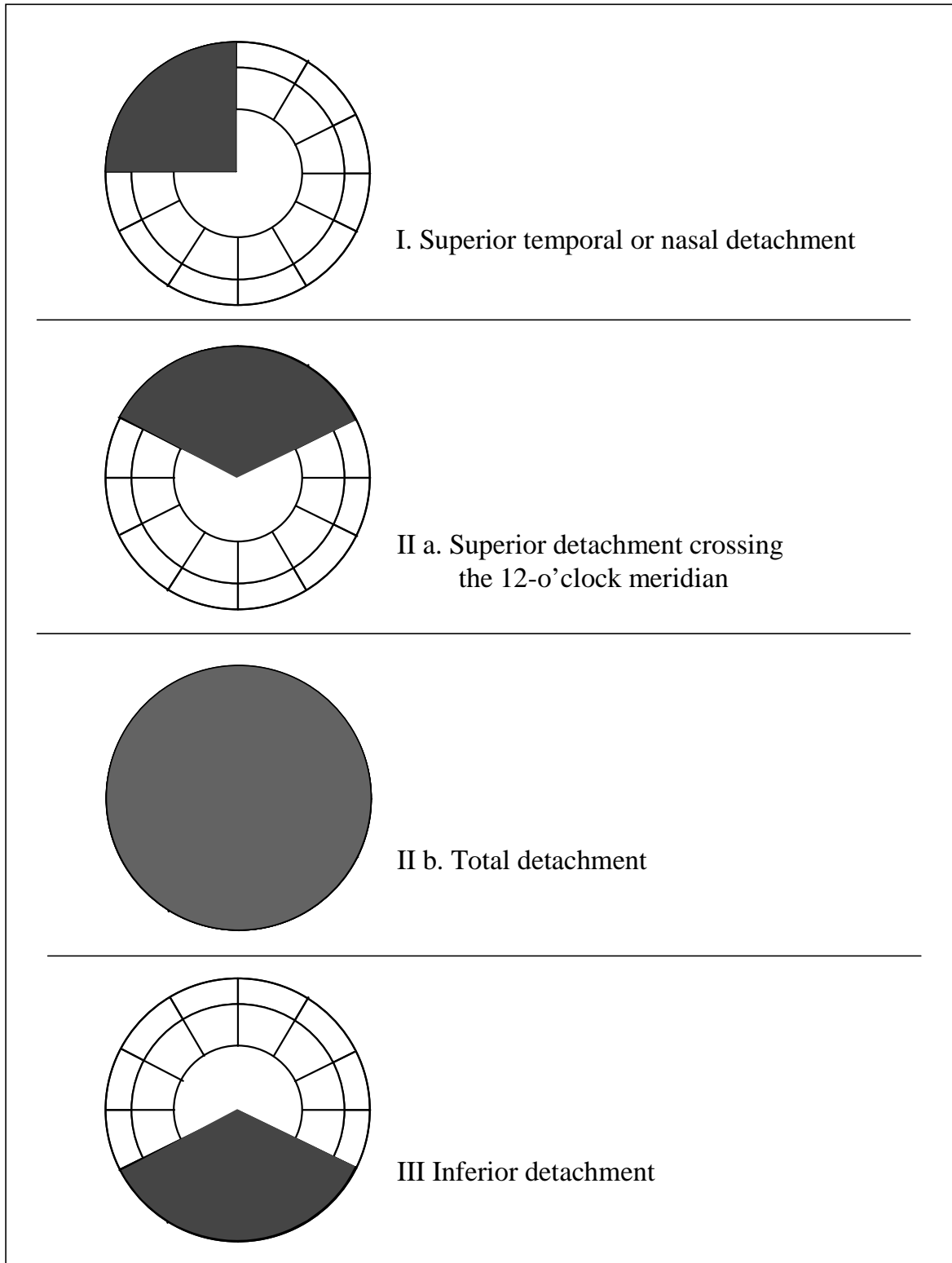
Most of the cataract extractions and Nd:YAG laser capsulotomies and all RD surgeries had been performed in the Helsinki University Eye Hospital. In this hospital, generally, cataract patients are operated on based on their residence, and only less than 5% of them are referred because more complicated surgery is anticipated. Half of the LCTs are done in this hospital,

and the other half are performed in private practices. If RD occurs, more than 90% of the catchment population will be operated on in this hospital. In the study population, all the RDs have been operated on at Helsinki University Eye Hospital by any of four vitreoretinal surgeons in charge. Missing clinical information was collected from other central, regional, and private hospitals where these patients had been treated and from private ophthalmologists responsible for the referral and follow-up.

The age and gender of the patient, the axial length (AL), and the presence of other eye diseases, especially lattice degeneration, previous retinal breaks and RD were recorded. The type and course of cataract surgery, dates of LCT, cataract and RD surgeries, and the number and energy of laser applications were recorded. The characteristics of RD and the number, type and meridional location of retinal breaks were compiled from data registered in patient charts, the preoperative fundus drawings, and the findings made during detachment surgery.

The type of retinal detachments was classified according to the scheme of Lincoff and Gieser³²¹: type I included superior temporal or superior nasal detachments. For the purpose of this study, type II was divided into superior detachments that crossed the 12-o'clock meridian at least half an hour (type IIa) and into total detachments (type IIb). (Figure 5.) Type III included inferior detachments. Proliferative vitreoretinopathy (PVR) was graded according to the classification of the Retina Society.²²⁹ The type of retinal breaks was recorded as no visible break, a horseshoe tear, a round hole or group of adjacent holes related to one peripheral degenerative patch, or both types of breaks.

Figure 5. a-d The Modified Lincoff Scheme



5.2.2 Clinical examination (II-IV)

The best corrected visual acuity (BCVA) was determined using a test-type projector (Rodavist 2, Rodenstock). The anterior segment was evaluated with a standard biomicroscope (Haag-Streit, Köniz, Switzerland) and intraocular pressure was measured with a standard Goldmann applanation tonometer (Haag-Streit, Köniz, Switzerland). Pupils were dilated with tropicamide 0.5%, phenylephrine hydrochloride 10%, and cyclopentolate hydrochloride 1% drops, instilled twice.

The central fundus was examined with a +90 D convex lens (Volk Optical Inc., Mentor, Ohio, USA). The peripheral retina was evaluated using a binocular indirect ophthalmoscope, a +20D lens and scleral indentation, a Goldmann 3-mirror lens (Haag-Streit, Köniz, Switzerland) or a wide-field contact lens (QuadrAspheric, Volk Optical Inc., Mentor, Ohio, USA), whichever provided better visualization. Abnormal findings were recorded on a fundus chart.

5.2.3 Nd:YAG laser posterior capsulotomy (II)

The LCT was done by the surgeon in charge with a Q-switched Nd:YAG laser (Visulas YAG FL, Carl Zeiss). The type and shape of LCT was chosen according to the surgeon's preference. The number of laser applications and their energies were recorded. Medication after capsulotomy was prescribed by the surgeon in charge on an individual basis. Generally before and after the LCT, a 1% apraclonidine drop was instilled to prevent IOP peaks. Fluorometolon eye drops were prescribed four times a day for one week. A photograph of the posterior capsule was taken (Zeiss 75 SL, Carl Zeiss) from which the largest diameter of the LCT was measured based on the magnification provided by the camera.

5.2.4 Patient satisfaction and quality of life (IV)

Patient satisfaction and quality of life were assessed by a structured interview that included 26 questions (Figure 6.). These included two general questions, the first of which queried overall problems with vision and the second overall satisfaction with vision. In the third part, a set of 6 questions originally designed for capturing symptoms potentially related to cataract (Cataract Symptom Score) ^{26;42;43;237} was asked in a way adapted to retinal symptoms. Patients who reported any of these symptoms were asked to which degree they bothered them.

Finally, the standard VF-14 test ⁴² was administered. The interviews were performed by the author, not by any of the vitreoretinal surgeons.

Figure 6. Questionnaires used to evaluate functional vision

<p>OVERALL PROBLEMS WITH VISION</p> <p>1. Do you think you have difficulties with vision?</p> <ol style="list-style-type: none"> 1. None 2. A little 3. A moderate amount 4. A great deal 	<p>OVERALL SATISFACTION WITH VISION</p> <p>2. How satisfied are you with your vision?</p> <ol style="list-style-type: none"> 1. Very unsatisfied 2. Moderately unsatisfied 3. Moderately satisfied 4. Very satisfied
--	---

<p>CATARACT SYMPTOM SCORE</p> <p>3. Are you bothered by double vision?</p> <p style="padding-left: 20px;">Yes No</p> <p style="padding-left: 20px;">If yes, how much it bothers?</p> <ol style="list-style-type: none"> 1. A little 2. A moderate amount 3. A great deal <p>4. Are you bothered by glare?</p> <p style="padding-left: 20px;">Yes No</p> <p style="padding-left: 20px;">If yes, how much it bothers?</p> <ol style="list-style-type: none"> 1. A little 2. A moderate amount 3. A great deal <p>5. Are you bothered by seeing halo or rings around light?</p> <p style="padding-left: 20px;">Yes No</p> <p style="padding-left: 20px;">If yes, how much it bothers?</p> <ol style="list-style-type: none"> 1. A little 2. A moderate amount 3. A great deal 	<p>6. Are you bothered by blurry vision?</p> <p style="padding-left: 20px;">Yes No</p> <p style="padding-left: 20px;">If yes, how much it bothers?</p> <ol style="list-style-type: none"> 1. A little 2. A moderate amount 3. A great deal <p>7. Are you bothered by colors looking different than they used to in a way that is disturbing?</p> <p style="padding-left: 20px;">Yes No</p> <p style="padding-left: 20px;">If yes, how much it bothers?</p> <ol style="list-style-type: none"> 1. A little 2. A moderate amount 3. A great deal <p>8. Are you bothered by distortion of pictures or straight lines?</p> <p style="padding-left: 20px;">Yes No</p> <p style="padding-left: 20px;">If yes, how much it bothers?</p> <ol style="list-style-type: none"> 1. A little 2. A moderate amount 3. A great deal
---	--

VF-14

9. Do you have any difficulty, even with glasses, reading small print, such as labels on medicine bottles, a telephone book, food labels?

- Yes No Not applicable
 If yes, how much difficulty do you currently have?
 1. A little
 2. A moderate amount
 3. A great deal
 4. Are you unable to do the activity?

10. Do you have any difficulty, even with glasses, reading a newspaper?

- Yes No Not applicable
 If yes, how much difficulty do you currently have?
 1. A little
 2. A moderate amount
 3. A great deal
 4. Are you unable to do the activity?

11. Do you have any difficulty, even with glasses, reading a large-print book or large-print newspaper or numbers on a telephone?

- Yes No Not applicable
 If yes, how much difficulty do you currently have?
 1. A little
 2. A moderate amount
 3. A great deal
 4. Are you unable to do the activity?

12. Do you have any difficulty, even with glasses, recognizing people when they are close to you?

- Yes No Not applicable
 If yes, how much difficulty do you currently have?
 1. A little
 2. A moderate amount
 3. A great deal
 4. Are you unable to do the activity?

13. Do you have any difficulty, even with glasses, seeing steps, stairs, or curbs?

- Yes No Not applicable
 If yes, how much difficulty do you currently have?
 1. A little
 2. A moderate amount
 3. A great deal
 4. Are you unable to do the activity?

14. Do you have any difficulty, even with glasses, reading traffic signs, street signs, or store signs?

- Yes No Not applicable
 If yes, how much difficulty do you currently have?
 1. A little
 2. A moderate amount
 3. A great deal
 4. Are you unable to do the activity?

15. Do you have any difficulty, even with glasses, doing fine handwork like sewing, knitting, crocheting, carpentry?

- Yes No Not applicable
 If yes, how much difficulty do you currently have?
 1. A little
 2. A moderate amount
 3. A great deal
 4. Are you unable to do the activity?

16. Do you have any difficulty, even with glasses, writing checks or filling out forms?

- Yes No Not applicable
 If yes, how much difficulty do you currently have?
 1. A little
 2. A moderate amount
 3. A great deal
 4. Are you unable to do the activity?

17. Do you have any difficulty, even with glasses, playing games such as bingo, dominos, card games, mahjong?

- Yes No Not applicable
 If yes, how much difficulty do you currently have?
 1. A little
 2. A moderate amount
 3. A great deal
 4. Are you unable to do the activity?

18. Do you have any difficulty, even with glasses, taking part in sports like bowling, handball, tennis, golf?

- Yes No Not applicable
 If yes, how much difficulty do you currently have?
 1. A little
 2. A moderate amount
 3. A great deal
 4. Are you unable to do the activity?

19. Do you have any difficulty, even with glasses, cooking?

- Yes No Not applicable
 If yes, how much difficulty do you currently have?
 1. A little
 2. A moderate amount
 3. A great deal
 4. Are you unable to do the activity?

20. Do you have any difficulty, even with glasses, watching television?

- Yes No Not applicable
 If yes, how much difficulty do you currently have?
 1. A little
 2. A moderate amount
 3. A great deal
 4. Are you unable to do the activity?

21. Do you currently drive a car?

- Yes (go to 22) No (go to 24)

22. How much difficulty do you have driving during the day because of your vision? Do you have:

1. No difficulty
 2. A little difficulty
 3. A moderate amount of difficulty
 4. A great deal of difficulty?

23. How much difficulty do you have driving at night because of your vision? Do you have:

1. No difficulty
 2. A little difficulty
 3. A moderate amount of difficulty
 4. A great deal of difficulty?

24. Have you ever driven a car?

- Yes (go to 25) No (stop)

25. When did you stop driving?

- Less than 6 months ago
 6-12 months ago
 More than 12 months ago

26. Why did you stop driving?

- Vision
 Other illness
 Other reason

5.2.5 Statistical analysis (I-IV)

Statistical analyses were performed using the BMDP PC-90 Statistical Software package (BMDP Statistical Software, Cork, Ireland), the SPSS for Windows 9.0.1 (SPSS Inc., Chicago, Illinois, USA) and the STATA Statistics/Data Analysis Software Version 7.0 (Stata Co, Texas, USA). Descriptive statistics are given as a mean and standard deviation (SD) for normally distributed variables and as a median and range for other continuous variables. Confidence intervals (95%) were calculated for proportions.

Fisher's exact test and Pearson's chi-square test with Yates' continuity correction were used to compare proportions in 2x2 and larger unordered contingency tables, respectively.³²² Singly ordered contingency tables were compared with the Kruskal-Wallis test. Means of continuous variables that did not follow normal distribution were compared with the nonparametric Mann-Whitney *U*-test.³²² All tests were 2-tailed, and a *P* value less than 0.05 was considered significant. Multiple comparisons were adjusted for by the Bonferroni correction.³²²

Calculation of the number of patients needed to discard the null hypothesis with 90% power (II) was done with StatMate (GraphPad Software, St. Diego, California). For calculating mean and median visual acuity (IV), the Snellen fractions were transformed to -logMAR (logarithm of the minimum angle of resolution) units. The results were transformed back to Snellen equivalents.

Survival analysis (III, IV) was based on the Kaplan-Meier product-limit method.^{322;323} The time intervals from cataract surgery and LCT to RD were calculated and the cumulative proportions of patients with RD were compared between different groups using the log-rank test. Patients who died were censored from the analysis at the time of death and patients who did not develop RD were censored at the time of re-examination or chart review (III).

Cox proportional hazards multiple regression^{322;323} was used to identify independent predictors of RD after LCT (III). Age at LCT and AL were analyzed as continuous variables. Alternatively, AL was arbitrarily dichotomized into two categories (≤ 25 mm vs. > 25 mm). Categorical variables included gender, history of vitreous complication at the time of cataract surgery and enrollment status at Stage I of this study. Variables for which the Wald chi-square test gave a *P* value of < 0.20 were considered for multivariate modeling, because of the small

number of events, so as not to discard potentially significant variables at an early stage. Moreover, only two variables at a time could legitimately be included in the multivariate model (III).

Multiple logistic regression was used to model functional and patient-related visual outcomes (IV).^{322,323} Because logistic regression demands a two-category dependent variable, patient-reported overall satisfaction with vision was dichotomized to satisfied and dissatisfied and overall problems with vision to those who had and did not have problems. The VF-14 score was also dichotomized so that scores below 90 were classified as low and scores of 90 or more as high scores. Likewise, the modified cataract symptom score was dichotomized to a low score (less than 3) and high score (3 or more). The cut points were chosen to correspond roughly with the median scores.

The initial BCVA was modeled as a confounding variable, i.e. as a variable that theory dictates must always be included in the model. Each outcome variable was assessed as an independent variable in turn, i.e. statistical analysis was used to look for evidence of its association with the other variables: initial and final visual acuity, type of surgery, and number of RD procedures. As regards the independent variables analyzed, the type of RD surgery was dichotomized in two categories: scleral buckle only and vitrectomy with or without scleral buckle. Independent variables were allowed in the model if $P < .10$, and confounding variables were kept in the model irrespective of statistical significance. Different models were compared with the likelihood ratio test.

6 RESULTS AND DISCUSSION

6.1 Characteristics of RD after LCT

6.1.1 Time intervals between cataract extraction, LCT and RD (I, IV)

In the retrospective study (I) and in the cross-sectional study (IV) the eyes with LCT were compared with those with an intact posterior capsule before RD. The median time interval from cataract extraction to RD was longer in the capsulotomy group (4.1 vs. 1.5 years, 3.2 vs. 1.2 years, respectively, $P < 0.001$, Mann-Whitney U -test), as was to be expected because secondary cataract takes time to develop. The median time from LCT to RD was 2 years (range 0.03-8.8). 28% of RDs occurred within 6 months after LCT (I).

Frequently, most of the detachments occur within one year of LCT.^{271;285;293;294} The longer time in our study can be due to the fact that our patients had undergone a strictly uncomplicated cataract surgery. In many other studies the rate of vitreous complications varies or is not reported.

6.1.2 Risk factors for RD

At least one of the well-known risk factors for RD (lattice degeneration, high axial length, RD in the fellow eye) was present in 44% of pseudophakic eyes. No significant difference was detected between eyes with and without LCT ($P = 0.86$, Fisher's exact test). More than one risk factor was present in 10% of the eyes (I).

6.1.3 Type and extent of RD (I, IV)

The type of RD as classified according to Lincoff types ($P = 0.17$, Pearson's chi-square test), by meridional locations ($P = 0.25$, Mann-Whitney U -test), by the presence of macular detachment ($P = 0.47$, Fisher's exact test) and by proliferative vitreoretinopathy (PVR) ($P = 0.45$, Pearson's chi-square test) did not differ significantly between eyes with an intact posterior capsule and

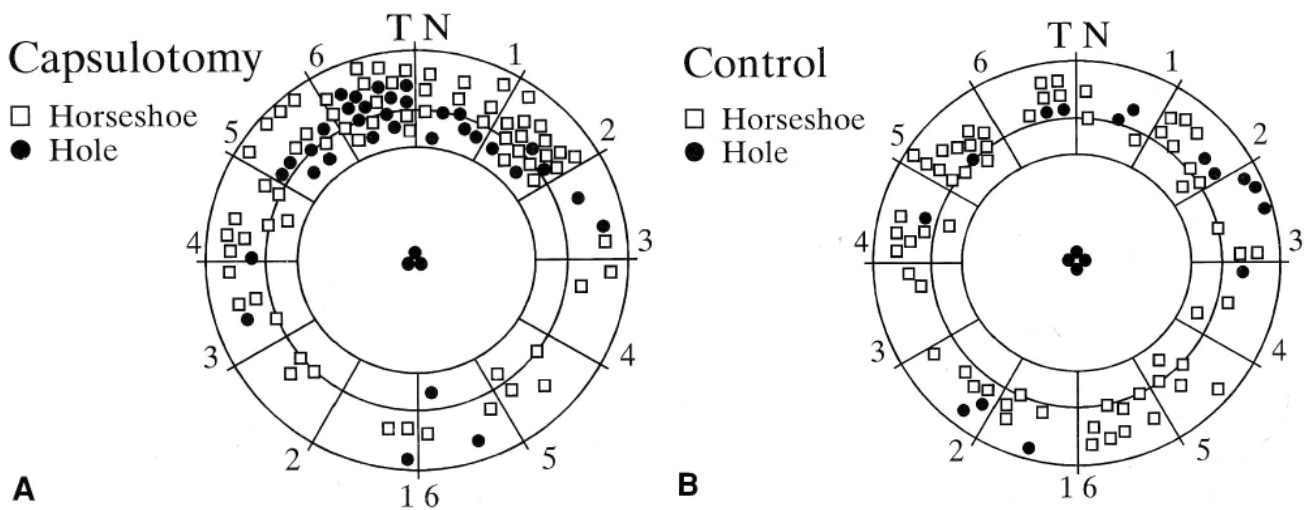
LCT. Of the RD 14-16% were total ($P = 0.16$, Fisher's exact test) and the macula was detached in 64-65% of eyes (I, IV).

In previous studies, the types of post-capsulotomy RD have not differed notably from the present study.³²⁰ Such reports, however, which would have evaluated the type of RD in eyes with strictly uncomplicated cataract surgery, have not been published.

6.1.4 Type, number and location of retinal breaks (I)

The mean number of peripheral retinal breaks was higher in the capsulotomy group (1.7 vs. 1.1, $P=0.05$, Mann-Whitney U test). The type and distribution of breaks also differed between the two study groups. The breaks were located especially in the upper quadrants in the capsulotomized eyes (82 of 103 vs. 48 of 77; $P = 0.024$, Fisher's exact test with Bonferroni correction) and they tended to be more frequently atrophic holes than horseshoe breaks in these eyes (34 of 103 vs. 15 of 77; $P = 0.062$, Fisher's exact test)(Figure 7.).

Figure 7 A and B Number, type and distribution of retinal breaks in the capsulotomy and control group



This is the first report, in which the type and number of retinal breaks in eyes operated on for pseudophakic RD after strictly uncomplicated cataract extraction and LCT was analyzed, and so far the best controlled analysis of RD after LCT. The strict inclusion criteria were used to ensure that these two groups would not differ in other aspects than the status of the posterior capsule, which helps to spot differences. The difference in the number and the type of retinal breaks between the two groups could possibly be related to the increased risk of RD after LCT. Assuming this hypothesis is right, not only the horseshoe breaks, but also the atrophic holes could have a significant relation to RD, when alterations in vitreous structure happen after LCT.

6.2 Retinal breaks associated with LCT

6.2.1 Asymptomatic retinal breaks and RD before LCT (II)

When examined before LCT, the retina could be visualized up to ora serrata in 177 of 235 eyes (75%). An untreated, asymptomatic retinal break was noticed in 4 of the 235 enrolled eyes (1.7%, 95% CI 0-4)(Figure 8, white symbols). Furthermore, in 2 additional eyes (0.9%, 95% CI 0-3) an undiagnosed RD (a chronic inferonasal RD without visible breaks and a total redetachment in a previously operated eye) was noticed. In 4 fellow eyes, an asymptomatic retinal break was detected. These breaks were not noticed by the private ophthalmologists who referred the patients to LCT. A previously treated break was detected in 2 study and 1 fellow eye.

It is well known, that PCO often disturbs the retinal visibility. However, the visualization of peripheral retina was successful in the majority of eyes; the main problems were PCO and poorly dilated pupils.

The incidence of asymptomatic retinal breaks in the general population is reported to be about 6%.⁸ The observed frequency of asymptomatic retinal breaks in this study was smaller but corresponds with the 0.5-2.0% frequency of RD after LCT. If we take into account all breaks, previously treated and asymptomatic ones now detected, the frequency was roughly the same. The proportion of breaks, which finally will lead to RD is not well established. No prospective study of the progression of a symptomatic retinal break in pseudophakic and

capsulotomized eyes have been published.¹⁹⁹ However, we can conclude that a significant proportion of eyes scheduled for LCT have an asymptomatic retinal break.

When there are recognized risk factors, which predispose the eye to premature PVD and to subsequent RD, such as high myopia, history of RD in the fellow eye and vitreous loss during cataract surgery, most ophthalmologists would consider it reasonable to treat such breaks prophylactically before LCT.

6.2.2 Retinal breaks after LCT (II)

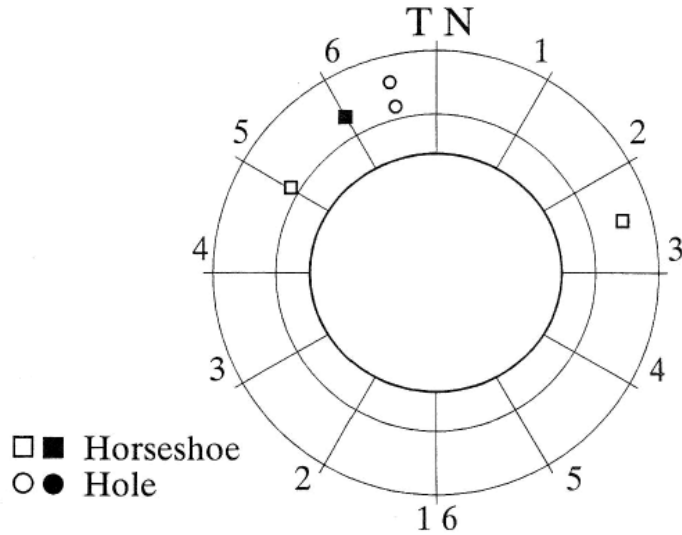
The median single and total energy used in LCT were 2.3 mJ and 51 mJ, respectively, which were moderate as compared with the literature (range of means of total energy, 13-118 mJ). The amount of energy (single or total) have not been shown to correlate the risk of RD.^{16;17;147;252;266;295;300;324-326} The median largest diameter of the capsulotomy was 3.4 mm (range, 2.0 to 4.6 mm).

When examined a median of 60 minutes after LCT, no new breaks, retinal hemorrhages or other adverse effects from the LCT were noted. The ora serrata was visualized in 160 of 223 eyes (72%). In addition to remnants of PCO, poorly dilating pupils, also some corneal edema and dry epithelium were noticed to deteriorate the visibility.

One month after LCT a new break was found and photocoagulated in 1 of 220 (0.4%, 95% CI 0-3) eyes: an asymptomatic superotemporal horseshoe tear bordering a previously seen lattice degeneration adjacent to a previously treated break (Figure 8, black symbol). The axial length of this eye was 24.8 mm. No new RDs were detected, nor was vitreous prolapse through the LCT found in any eye. The ora serrata could be visualized in 196 of 220 eyes (89%).

In some eyes, previously uncertain findings in the very anterior retina could be visualized better after LCT. Some of the findings were confirmed as retinal breaks, but others as harmless atrophic degenerations. It is possible that the horseshoe break detected one month after LCT may have existed even before LCT, even though the lattice degeneration and the previously treated break nearby were detected before LCT.

Figure 8. Type and location of asymptomatic, previously untreated retinal breaks in eyes scheduled for LCT



6.2.3 Later retinal breaks (III)

Later, 113 eyes of 106 patients were re-examined after a median follow-up time of 4.9 years. The ora serrata was visible in 76 of 113 eyes (67%). The reasons to poor visibility were again poorly dilating pupil (20% of eyes), corneal opacities, remnants of secondary cataract, poor cooperation and vitreous opacities in the minority of cases. In one patient with floaters in the study eye, an operculated superotemporal break associated with retinal pigmentation was found and sealed with argon laser photocoagulation. No new asymptomatic breaks were noticed, and the retina was attached in all eyes.

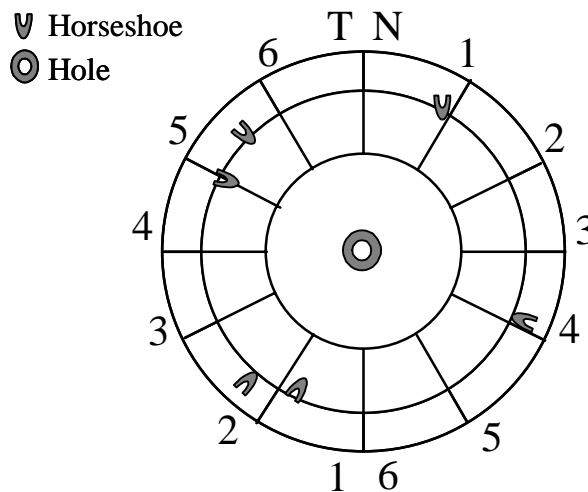
At Stage II, 3 of 5 study eyes with a treated break and 2 of the 4 fellow eyes with an untreated break, (none of which had had LCT), were re-examined. No new breaks nor subretinal fluid around the previously detected breaks were detected.

6.2.4 Prospective study of RD after LCT (III)

In the prospective study (III), 8 of 350 eyes developed a RD within the five-year follow-up. Two of these RDs occurred in previously examined eyes that had asymptomatic retinal breaks photocoagulated, and six in eyes with unknown retinal status at the time of LCT. In four eyes a new horseshoe tear was found. In one eye a typical macular hole was detected, and in three other eyes no peripheral retinal breaks were found even peroperatively (Figure 9.).

In 7 patients, at least one of the risk factors for RD was present (III). By Cox regression analysis, the axial length showed statistically significant association with RD after LCT, whether modeled as a continuous variable (HR 1.51 for each mm increase, $P=0.0002$) or categorized by using 25 mm as a cutoff (HR 11.1 $P=0.0016$). RD was also associated with male gender (HR 3.61), younger age at LCT (HR 1.45 for each 10-year decrease in age), and non-enrollment to Stage I of this study (HR 4.95). However, with bivariate Cox regression models vitreous complications at cataract surgery showed to be a statistically significant predictor of RD (HR 11.9, $P=0.036$), as did the enrollment status.

Figure 9. Type and location of retinal breaks in eyes with retinal detachment after LCT



This kind of prospective study in eyes undergoing LCT has not been previously reported. In the group of prophylactically treated eyes, the incidence of RD was lower than among other eyes. This study was not randomized nor controlled. However, fellow eyes of enrolled patients had RD equally often as non-participating eyes. No RD developed in non-

capsulotomized fellow eyes. It is suggestive of potential benefit as regards non-horseshoe, non-PVD-related breaks developing. A larger study of patients randomized to undergo thorough fundus examination or no such examination, is needed to confirm these results. It seems probable that also other risk factors than LCT such as high axial length have an effect on the RD after LCT. Therefore it seems reasonable to advice patients with high risk eyes to attend ophthalmologic controls to detect existing retinal degenerations in advance and especially contact their ophthalmologist if they have any visual symptoms. The randomized study also might be focused on patients at high risk of RD.

6.3 Long-term outcome of pseudophakic retinal detachment after LCT

6.3.1 Anatomic outcome (IV)

In the cross-sectional study after RD surgery, the retina was reattached in 75 eyes with a single procedure (74%, 95% CI 65-82). In 98 eyes (97%, 95 CI 92-99) two procedures were needed to reattach the retina. In all 101 eyes (95 CI 96-100) retina was attached with 3 to 5 procedures.

The presence of LCT was not statistically significantly associated with primary redetachment (20% vs. 31%, $P=0.25$, Fisher's exact test). During a median follow-up of 4.3 years, a later detachment had occurred in 8 eyes (8%, 95% CI 3-15), and at the re-examination, one asymptomatic redetachment was diagnosed. Thus the retina remained attached long-term in 92% of pseudophakic eyes (95 CI 84-96), which corresponds to the reported rate of success in literature.⁸ The presence of LCT was not associated with later redetachment (9% vs. 9%, $P = 1.0$, Fisher's exact test). The number of eyes in which retinal breaks were not found even peroperatively (22%), was comparable to other studies, especially as regards pseudophakic eyes.^{8;40}

It is good to know, that the presence of LCT does not compromise later RD surgery. Moreover, if the opacified posterior capsule is opened, improvement in visibility of peripheral retina can be expected, thus making the closure of retinal breaks easier.

6.3.2 Objective visual outcome (IV)

In eyes with pseudophakic RD the median BCVA in Snellen symbols was 0.08 before RD surgery and 0.4 at re-examination, a median of 4.9 years after last vitreoretinal surgery. There was no statistically significant difference in BCVA between eyes with an intact posterior capsule or LCT. The BCVA at re-examination was 0.5 or better in Snellen symbols in 39% of all eyes. The median BCVA in the fellow eyes was 0.7 in both groups.

The median diameter of the Goldmann visual field of the operated eye was 100° horizontally and 90° vertically for eyes with and without LCT. This is somewhat less than the normal range in the same age group of healthy eyes³²⁷ due to indentation of scleral buckle, scars of cryocoagulation and the IOL. No statistically significant difference between the two groups was observed.

The final BCVA depends mainly on the presence and duration of macular detachment.⁸ It has been reported, that if RD is repaired within one week of the macular detachment, the visual results in long-term may be as good as if it is operated within 24 hours, as an emergency.⁸

6.3.3 Patient-rated functional outcome (IV)

The functional outcome of RD surgery in the cross-section study was good and no statistically significant differences existed between patients with and without LCT in any of the questionnaires.

The median VF 14-score was 87.5 for both groups (the more points, the less difficulties in performing the activities, score 0-100, $P = 0.81$, Mann-Whitney U -test). The median modified cataract symptom score was 3.0 for both groups (the less points, the less symptoms, score 0-18, $P = 0.76$, Mann-Whitney U -test). Of 100 patients who answered the questionnaire, 80 (80%) were satisfied or very satisfied with their binocular vision ($P = 0.40$, Pearson's chi-square test), and 62 (62%) reported no or just a little trouble with binocular vision ($P = 0.64$, Pearson's chi-square test).

By a multiple logistic regression analysis the final best corrected visual acuity (BCVA) was independently associated with initial BCVA (modeled as a confounding factor), type of RD surgery and number of procedures. Poor initial BCVA, vitrectomy with or without scleral buckling and more than one procedure predicted poor final visual acuity. The final BCVA was also statistically significantly associated with overall satisfaction and problems of vision.

It is known from previous reports, that a poorer initial VA predicts a poor final BCVA.⁸ As mentioned, the final BCVA depends largely on the status of the macula, which corresponds to preoperative BCVA. The association between final BCVA and vitrectomy is explained by the common practice using primarily scleral buckling, and reverting to vitrectomy only in more complicated eyes and as a secondary procedure. Vitrectomy is an efficient and safe procedure and does not compromise VA by itself. Several reports have been published of using vitrectomy as the primary procedure in pseudophakic RD repair with good results, but in most countries like Finland, scleral buckling remains the predominating procedure. In the present series, 70% of eyes were operated on with a scleral buckle, and 29% required vitreous surgery with or without scleral buckling. The presence of LCT was not associated with the type of surgery required ($P = 0.26$, Pearson's chi-square test).

Previously questionnaires have been widely used to assess cataract surgery, and gradually some results regarding other eye diseases have been published.^{51-53;238;240-242;328-330} From the viewpoint of the patient, it is easier to compare the pre- and postoperative vision after cataract surgery, because cataract takes time to develop. Because RD must be operated very soon, within days, the situations are changing more quickly. This may explain lack of this kind of studies in the acute phase. On the other hand, they are probably valid in reflecting later visual performance. Compared to the previous analyses of functional outcome of vitreoretinal procedures, the level of VF-14 and other scores were very similar.^{53;240-242;331}

It is known that the visual acuity gradually improves after RD surgery, and small changes may happen during the first postoperative year.⁸ The risk for redetachment is also at its greatest during the first postoperative year. Thus when estimating the final results of RD surgery, it should not be done too soon after the surgery.

When estimating how much the visual problems influence the every-day life of the patient, it must be remembered that the bilateral visual acuity and the extent of visual fields are of particular importance. In this analysis, the median BCVA of the fellow eyes was 0.7 in Snellen fractions, which may have a beneficial influence on the results of the questionnaires. Also the status of the dominant eye is important. In our study, the dominance of either eye was not recorded.

The functional way of measuring the outcome of the surgery is coming more and more important. VF-14 is a widely used questionnaire originally planned for cataract surgery. However, using just one questionnaire for young and old people, for different eye diseases and surgeries and for patients in different countries and with lifestyles of their own, has also limitations. The ideal way to measure the functional vision could be one basic questionnaire with additional questions or modules aimed at specific targets such as vitreoretinal diseases.

7 SUMMARY AND CONCLUSIONS

Retinal detachment is the most common potentially blinding complication after cataract surgery. When Nd:YAG laser posterior capsulotomy (LCT) is performed to open an opacified, but previously intact posterior capsule, the risk of RD is thought to increase four times.¹⁰⁻¹² Because cataract surgery is the most frequent surgical procedure in the world, and visually significant posterior capsule opacification develops nowadays in 20-25% of pseudophakic eyes, the risk of RD is notable.

Although unknown, the exact pathogenetic mechanisms of RD after LCT are supposed to relate to secondary vitreous changes. This clinically orientated study was designed to find out more of the properties of RD after LCT. To exclude bias from vitreous complications, one of the main principles throughout the study was to not enroll eyes with a posterior capsule rupture to retrospective analysis and to use prospective approach when possible.

In the first part of the study it was noticed that the number and distribution of retinal breaks were different between eyes with and without LCT. The LCT group had significantly more retinal breaks, particularly more atrophic holes located in the superior quadrants. Otherwise the characteristics of RD were equal in both groups. Data on the presence of asymptomatic retinal breaks before LCT and their possible progression to RD afterward could not be achieved from this retrospective chart analysis, but the results were used to design the second part of the study.

At Stage I of the second, prospective study 235 eyes were examined before and after LCT, and an asymptomatic, untreated retinal break was found in 1.7% of eyes. A previously treated break was detected in 2 eyes. Furthermore, one month after LCT, a new asymptomatic break in one eye was noticed. All patients with an untreated retinal break in the eye scheduled for LCT chose to have prophylactic photocoagulation.

At Stage II of the prospective study, the overall cumulative proportion of patients with RD at 5 years was significantly less among the enrolled eyes as compared with eyes, which were not prospectively followed and prophylactically treated, in spite of relatively small amount of

patients (proportion of RD 1.2% vs. 5.8%, respectively, Kaplan-Meier). In these eyes, known risk factors such as high axial length seemed decisive as regards the development of RD. I am unaware of other prospective studies of retinal breaks and detachment after LCT.

In the third part of the study the final anatomic, visual and functional outcome of pseudophakic RD was equal in eyes with and without LCT. The retina had remained attached in 91% of eyes, and BCVA better than 0.5 in Snellen symbols was acquired in 39% of eyes. These anatomical and visual results are comparable to other reports of the outcome of pseudophakic RD.

Only preliminary studies about the patient-related functional results of vitreoretinal surgery have been published and in them patients with RD (phakic, aphakic or pseudophakic) have been but a small subgroup. If RD occurs, the anatomic and functional results seem to be equal in eyes with and without a LCT. When performing vitreoretinal surgery because of RD, the LCT is even advantageous in improving the visibility of peripheral retina.

In conclusion, this series of studies showed that in eyes scheduled for LCT, risk factors, such high axial length, have to be taken into account. It may be important to examine the peripheral retina carefully perioperatively and to continue follow-up after LCT. A prospective study of a much larger population of patients would be required to document statistically a benefit from treatment of the break and to quantitate the probable risk of RD from leaving it untreated. Until that time, if asymptomatic retinal breaks are found, prophylactic photocoagulation is worth considering because of the known and potentially additive risk of LCT on RD.

To minimize the time from symptoms to diagnosis and treatment of RD, it is important to inform the LCT patient of such symptoms, and advice a prompt ophthalmological examination. On the other hand, in spite of increased risk of RD, there is no reason to defer LCT, when it is otherwise indicated and appropriately done. In eyes with several, often additive risk factors, the cautious ophthalmologist will have a higher threshold in performing LCT, and he or she will pay close attention to preoperative assessment and follow-up. To prevent this type of RD from developing in the future, it is also important to further identify and minimize any controllable factors contributing to opacification of the posterior capsule.

8 ACKNOWLEDGEMENTS

This study was carried out in the department of Ophthalmology, Helsinki University Central Hospital, Finland. I am sincerely grateful for Professor (emer.) Ahti Tarkkanen, for presenting the idea for this thesis, and for strong encouragement during these years. I also thank Professor Leila Laatikainen, the current Head of the Eye Hospital, for providing the good working and researching facilities. The greatest thanks belong to my supervisor, Docent Tero Kivelä, MD, for his incredible, untiring help in all kinds of problems concerning the thesis.

I also wish to express my gratitude for my senior colleagues, Docent Ilkka Immonen, MD, Docent Paula Summanen, MD, and Petri Tommila, MD, PhD, for their kind help in examining the study patients, and guiding me in the clinical world of vitreoretinal diseases. I am also grateful to other colleagues at the Department of Ophthalmology, Helsinki, for giving me useful advice and support during this work. I want to thank Mrs. Marja-Leena Yli-Vakkuri, MA, for helping with the references, Mr. Seppo Lemberg for his help with photographs, Mr. Teo Hämäläinen, for flexible technical advice during these years, and Pekka Rikkonen, MD, MA, for the revision of the English language of this thesis.

From all the people concerning this thesis, the warmest gratitude goes to my nearest people. I want to warmly thank my parents Sisko and Unto, who have encouraged and helped me in many ways whenever needed. Without my husband, Petri, who have supported and patiently helped me with figures, tables and data processing and taken good care of our children, I would never had the opportunity to finish this thesis. I also thank my captivating children Pauli (8) and Tanja (6) for their patience with this 'longlasting paperwork'.

This study was financially supported by grants from the Eye Foundation, the Eye and Tissue Bank Foundation, the Friends of the Blind, The Emil Aaltonen Foundation and Väinö and Hilikka Kiltti Foundation, Finland.

Helsinki, October 2002


Päivi Ranta

9 REFERENCES

1. Apple D.J., Ram J, Foster A, Peng Q. Posterior capsule opacification (secondary cataract). *Surv Ophthalmol* 2000;45:S100-S130.
2. Apple D.J., Ram J, Foster A, Peng Q. Evolution of cataract surgery and intraocular lenses (IOLs): IOL quality. *Surv Ophthalmol* 2000;45:S53-S69.
3. Pharmacia Ophthalmology MC Finland. Cataract surgery in Finland, year 2000. 2001.
4. Jaffe NS, Jaffe MS, Jaffe GF. Cataract surgery and its complications., 6. ed. Toronto: The C.V.Mosby Company, 1997.
5. Lundstrom M, Stenevi U, Thorburn W. The Swedish national cataract register: A 9-year review. *Acta Ophthalmol* 2002;80:248-57.
6. Javitt JC, Street DA, Tielsch JM, Wang Q, Kolb MM, Schien O, Sommer A, Bergner M, Steinberg EP. National outcomes of cataract extraction. Retinal detachment and endophthalmitis after outpatient cataract surgery. Cataract Patient Outcomes Research Team. *Ophthalmology* 1994;101:100-5.
7. Kresloff MS, Castellarin AA, Zarbin M. Endophthalmitis. *Surv Ophthalmol* 1998;43:193-224.
8. Wilkinson CP, Rice TA. Michels retinal detachment., 2. ed. St. Louis: Mosby-Year Book, 1997.
9. Schaumberg DA, Dana MR, Christen WG, Glynn RJ. A systematic overview of the incidence of posterior capsule opacification. *Ophthalmology* 1998;105:1213-21.
10. Tielsch JM, Legro MW, Cassard SD, Schein OD, Javitt JC, Singer AE, Bass EB, Steinberg EP. Risk factors for retinal detachment after cataract surgery. A population-based case-control study. *Ophthalmology* 1996;103:1537-45.
11. Ninn-Pedersen K, Bauer B. Cataract patients in a defined Swedish population, 1986 to 1990. V. Postoperative retinal detachments. *Arch Ophthalmol* 1996;114:382-6.
12. Javitt JC, Tielsch JM, Canner JK, Kolb MM, Sommer A, Steinberg EP. National outcomes of cataract extraction. Increased risk of retinal complications associated with Nd:YAG laser capsulotomy. The Cataract Patient Outcomes Research Team. *Ophthalmology* 1992;99:1487-97.
13. Ficker LA, Steele AD. Complications of Nd:YAG laser posterior capsulotomy. *Trans Am Ophthalmol Soc* 1985;104:529-32.
14. Ficker LA, Vickers S, Capon MR, Mellerio J, Cooling RJ. Retinal detachment following Nd:YAG posterior capsulotomy. *Eye* 1987;1:86-9.
15. Leff SR, Welch JC, Tasman W. Rhegmatogenous retinal detachment after YAG laser posterior capsulotomy. *Ophthalmology* 1987;94:1222-5.
16. Ober RR, Wilkinson CP, Fiore JVJ, Maggiano JM. Rhegmatogenous retinal detachment after neodymium-YAG laser capsulotomy in phakic and pseudophakic eyes. *Am J Ophthalmol* 1986;101:81-9.
17. MacEwen CJ, Baines PS. Retinal detachment following YAG laser capsulotomy. *Eye* 1989;3:759-63.
18. Fastenberg DM, Schwartz PL, Lin HZ. Retinal detachment following neodymium-YAG laser capsulotomy. *Am J Ophthalmol* 1984;97:288-91.
19. Tasman W. Pseudophakic retinal detachment after YAG laser capsulotomy. *Aust N Z J Ophthalmol* 1989;17:277-9.
20. Yanoff M, Duker JS. *Ophthalmology.*, 1. ed. London: Mosby, 1999.
21. Hirvelä H, Luukinen H, Laatikainen L. Prevalence and risk factors of lens opacities in the elderly in Finland: A population-based study. *Ophthalmology* 1995;102:108-17.
22. Apple D.J., Ram J, Foster A, Peng Q. Pediatric cataract. *Surv Ophthalmol* 2000;45:S150-S168.
23. Apple D.J., Ram J, Foster A, Peng Q. Cataract surgery with intracapsular cataract extraction and spectacles. *Surv Ophthalmol* 2000;45:S45-S52.

24. Apple D.J., Ram J, Foster A, Peng Q. Cataract surgery with rigid and foldable posterior chamber IOLs, ECCE and phacoemulsification. *Surv Ophthalmol* 2000;45:S70-S99.
25. Minassian D, Rosen PH, Dart JKG, Reidy A, Desai P, Sidhu M. Extracapsular cataract extraction compared with small incision surgery by phacoemulsification: a randomised trial. *Br J Ophthalmol* 2001;85:822-9.
26. Schein OD, Steinberg EP, Javitt JC, Cassard SD, Tielsch JM, Steinwachs DM, Legro MW, Diener-West M, Sommer A. Variation in cataract surgery practice and clinical outcomes. *Ophthalmology* 1994;101:1142-52.
27. Lundström M, Barry P, Leite E, Seward H, Stenevi U. 1998 European cataract outcome study: report from the European cataract outcome study group. *J Cataract Refract Surg* 2001;27:1176-84.
28. Vajpayee RB, Sharma N, Dada T, Gupta V, Kumar A, Dada VK. Managing of posterior capsule tears. *Surv Ophthalmol* 2001;45:473-88.
29. Ng D.T., Rowe N.A., Francis I.C., Kappagoda M.B., Haylen M.J., Schumacher R.S., Alexander S.L., Boytell K.A., Lee B.B. Intraoperative complications of 1000 phacoemulsification procedures: a prospective study. *J Cataract Refract Surg* 1998;24:1390-5.
30. Blomquist PH, Rugwani RM. Visual outcomes after vitreous loss during cataract surgery performed by residents. *J Cataract Refract Surg* 2002;28:847-52.
31. Chitkara DK, Smerdon DL. Risk factors, complications, and results in extracapsular cataract extraction. *J Cataract Refract Surg* 1997;23:570-4.
32. Lum F, Schein O, Schachat AP, Abbott RL, Hoskins HDJ, Steinberg EP. Initial two years of experience with the AAO National Eyecare Outcomes Network (NEON) cataract surgery database. *Ophthalmology* 2000;107:691-7.
33. Goodman DF, Stark WJ, Gottsch JD. Complications of cataract extraction with intraocular lens implantation. *Ophthalmic Surg* 1989;20:132-40.
34. Norregaard JC, Bernth-Petersen P, Bellan L, Alonso J, Black C, Dunn E, Andersen TF, Espallargues M, Anderson GF. Intraoperative clinical practice and risk of early complications after cataract extraction in the United States, Canada, Denmark, and Spain. *Ophthalmology* 1999;106:42-8.
35. Frost NA, Sparrow JM, Strong NP, Rosenthal AR. Vitreous loss in planned extracapsular cataract extraction does lead to a poorer visual outcome. *Eye* 1995;9:446-51.
36. Powell SK, Olson RJ. Incidence of retinal detachment after cataract surgery and neodymium: YAG laser capsulotomy. *J Cataract Refract Surg* 1995;21:132-5.
37. Powe NR, Schein OD, Gieser SC, Tielsch JM, Luthra R, Javitt J, Steinberg EP. Synthesis of the literature on visual acuity and complications following cataract extraction with intraocular lens implantation. Cataract Patient Outcome Research Team. *Arch Ophthalmol* 1994;112:239-52.
38. Chu KM, Green RL. Suprachoroidal Hemorrhage. *Surv Ophthalmol* 1999;43:471-86.
39. Endophthalmitis Vitrectomy Study Group. Results of the Endophthalmitis Vitrectomy Study. A randomized trial of immediate vitrectomy and of intravenous antibiotics for the treatment of postoperative bacterial endophthalmitis. *Arch Ophthalmol* 1995;113:1479-96.
40. Ryan SJ. *Retina.*, 3 ed. St. Louis: Mosby, 2001.
41. Jaffe NS, Clayman HM, Jaffe MS. Cystoid macular edema after intracapsular and extracapsular cataract extraction with and without an intraocular lens. *Ophthalmology* 1982;89:25-9.
42. Steinberg EP, Tielsch JM, Schein OD, Javitt JC, Sharkey P, Cassard SD, Legro MW, Diener-West M, Bass EB, Damiano AM, et al. The VF-14. An index of functional impairment in patients with cataract. *Arch Ophthalmol* 1994;112:630-8.
43. Steinberg EP, Tielsch JM, Schein OD, Javitt JC, Sharkey P, Cassard SD, Legro MW, Diener-West M, Bass EB, Damiano AM, et al. National study of cataract surgery outcomes. Variation in 4-month postoperative outcomes as reflected in multiple outcome measures. *Ophthalmology* 1994;101:1131-40discussion.
44. Alonso J, Espallargues M, Andersen TF, Cassard SD, Dunn E, Bernth-Petersen P, Norregaard JC, Black C, Steinberg EP, Anderson GF. International applicability of the VF-14. An index of visual function in patients with cataracts. *Ophthalmology* 1997;104:799-807.

45. Cassard SD, Patrick DL, Damiano AM, Legro MW, Tielsch JM, Diener-West M, Schein OD, Javitt JC, Bass EB, Steinberg EP. Reproducibility and responsiveness of the VF-14. An index of functional impairment in patients with cataracts. *Arch Ophthalmol* 1995;113:1508-13.
46. Lundstrom M, Brege KG, Floren I, Stenevi U, Thorburn W. Impaired visual function after cataract surgery assessed using the Catquest questionnaire. *J Cataract Refract Surg* 2000;26:101-8.
47. Lundstrom M, Stenevi U, Thorburn W, Roos P. Catquest questionnaire for use in cataract surgery care: assessment of surgical outcomes. *J Cataract Refract Surg* 1998;24:968-74.
48. Lundstrom M, Roos P, Jensen S, Fregell G. Catquest questionnaire for use in cataract surgery care: description, validity, and reliability. *J Cataract Refract Surg* 1997;23:1226-36.
49. Crabtree HL, Hildreth AJ, O'Connell JE, Phelan PS, Allen D, Gray CS. Measuring visual symptoms in British cataract patients: the cataract symptom scale. *Br J Ophthalmol* 1999;83:519-23.
50. Uusitalo RJ, Brans T, Pessi T, Tarkkanen A. Evaluating cataract surgery gains by assessing patients' quality of life using the VF-7. *J Cataract Refract Surg* 1999;25:989-94.
51. Brunette I, Gresset J, Boivin JF, Boisjoly H, Makni H. Functional outcome and satisfaction after photorefractive keratectomy. Part 1: development and validation of a survey questionnaire. *Ophthalmology* 2000;107:1783-9.
52. Brahma A, Ennis F, Harper R, Ridgway A, Tullo A. Visual function after penetrating keratoplasty for keratoconus: a prospective longitudinal evaluation. *Br J Ophthalmol* 2000;84:60-6.
53. Linder M, Chang TS, Scott IU, Hay D, Chambers K, Sibley LM, Weis E. Validity of the visual function index (VF-14) in patients with retinal disease. *Arch Ophthalmol* 1999;117:1611-6.
54. Ruotsalainen J, Tarkkanen A. Capsule thickness of cataractous lenses with and without exfoliation syndrome. *Acta Ophthalmol* 1987;65:444-9.
55. McDonnell PJ, Zarbin MA, Green WR. Posterior capsule opacification in pseudophakic eyes. *Ophthalmology* 1983;90:1548-53.
56. McDonnell PJ, Stark WJ, Green WR. Posterior capsule opacification: a specular microscopic study. *Ophthalmology* 1984;91:853-6.
57. Cobo LM, Ohsawa E, Chandler D., Arguello R., George G. Pathogenesis of capsular opacification after extracapsular cataract extraction: an animal model. *Ophthalmology* 1984;91:857-63.
58. Apple DJ, Solomon KD, Tetz MR, Assia EI, Holland EY, Legler UF, Tsai JC, Castaneda VE, Hoggatt JP, Kostick AM. Posterior capsule opacification. *Surv Ophthalmol* 1992;37:73-116.
59. Uusitalo M, Kivela T. Cell types of secondary cataract: an immunohistochemical analysis with antibodies to cytoskeletal elements and macrophages. *Graefes Arch Clin Exp Ophthalmol* 1997;235:506-11.
60. Marcantonio JM, Vrensen GF. Cell biology of posterior capsular opacification. *Eye* 1999;13:484-8.
61. Wormstone IM. Posterior capsule opacification: a cell biological perspective. *Exp Eye Res* 2002;74:337-47.
62. Trivedi RH, Werner L, Apple D.J., Pandey SK, Izak AM. Post cataract-intraocular lens (IOL) surgery opacification. *Eye* 2002;16:217-41.
63. Schmidbauer JM, Vargas L.G., Peng Q, Escobar-Gomez M, Werner L, Arthur S.N., Apple D.J. Posterior capsule opacification. *Int Ophthalmol Clin* 2001;41:109-31.
64. Spalton DJ. Posterior capsular opacification after cataract surgery. *Eye* 1999;13:489-92.
65. Apple DJ, Peng Q, Visessook N, Werner L, Pandey SK, Escobar-Gomez M, Ram J, Auffarth GU. Eradication of posterior capsule opacification; documentation of a marked decrease in Nd:YAG laser posterior capsulotomy rates noted in an analysis of 5416 pseudophakic human eyes obtained postmortem. *Ophthalmology* 2001;108:505-18.
66. Claesson M, Klaren L, Beckman C, Sjostrand J. Glare and contrast sensitivity before and after Nd:YAG laser capsulotomy. *Acta Ophthalmol* 1994;72:27-32.

67. Clark DS. Posterior capsule opacification. *Curr Opin Ophthalmol* 2000;11:56-64.
68. Maltzman BA, Haupt E, Notis C. Relationship between age at time of cataract extraction and time interval before capsulotomy for opacification. *Ophthalmic Surg* 1989;20:321-4.
69. Baratz KH, Cook B.E., Hodge DO. Probability of Nd:YAG laser capsulotomy after cataract surgery in Olmsted County, Minnesota. *Am J Ophthalmol* 2001;131:161-6.
70. Tetz MR, Nimsgern C. Posterior capsule opacification. Part 2: Clinical findings. *J Cataract Refract Surg* 1999;25:1662-74.
71. Schmidbauer JM, Vargas L.G., Apple D.J., Escobar-Gomez M, Izak AM, Arthur S.N., Golescu A, Peng Q. Evaluation of neodymium:yttrium-aluminum-garnet capsulotomies in eyes implanted with Acrysof intraocular lenses. *Ophthalmology* 2002;109:1421-6.
72. Pradella SP, Täumer R. Frequenz der Nd:YAG-Kapsulotomie nach Implantation von Intraokularlinsen aus PMMA und Silikon. *Ophthalmologie* 1998;95:482-5.
73. Ursell PG, Spalton DJ, Pande MV, Hollick EJ, Barman S, Boyce J, Tilling K. Relationship between intraocular lens biomaterials and posterior capsule opacification. *J Cataract Refract Surg* 1998;24:352-60.
74. Hayashi K, Hayashi H, Nakao F, Hayashi F. Changes in posterior capsule opacification after poly(methylmethacrylate), silicone, and acrylic intraocular lens implantation. *J Cataract Refract Surg* 2001;27:817-24.
75. Hayashi H, Hayashi K, Nakao F, Hayashi F. Quantitative comparison of posterior capsule opacification after polymethylmethacrylate, silicone, and soft acrylic intraocular lens implantation. *Arch Ophthalmol* 1998;116:1579-82.
76. Hollick EJ, Spalton DJ, Ursell PG, Pande MV, Barman SA, Boyce JF, Tilling K. The effect of polymethylmethacrylate, silicone, and polyacrylic intraocular lenses on posterior capsular opacification 3 years after cataract surgery. *Ophthalmology* 1999;106:49-54.
77. Hollick EJ, Spalton DJ, Ursell PG, Pande M. Lens epithelial cell regression on the posterior capsule with different intraocular lens materials. *Br J Ophthalmol* 1998;82:1182-8.
78. Hollick EJ, Spalton DJ, Ursell PG, Meacock WR, Barman S, Boyce J. Posterior capsule opacification with hydrogel, polymethylmethacrylate, and silicone intraocular lenses: two-year results of a randomized prospective trial. *Am J Ophthalmol* 2000;129:577-84.
79. Sundelin K, Friberg-Riad Y, Östberg A, Sjöstrand J. Posterior capsule opacification with AcrySof and poly(methyl methacrylate) intraocular lenses. *J Cataract Refract Surg* 2001;27:1586-90.
80. Halpern MT, Covert D, Battista C, Weinstein AJ, Levinson RD, Yan L. Relationship of AcrySof acrylic and PhacoFlex silicone intraocular lenses to visual acuity and posterior capsule opacification. *J Cataract Refract Surg* 2002;28:662-9.
81. Olson RJ, Crandall A. Silicone versus polymethylmethacrylate intraocular lenses with regard to capsular opacification. *Ophthalmic Surg Lasers* 1998;29:55-8.
82. Milazzo S, Turut P, Artin B, Charlin JF. Long-term follow-up of three-piece, looped, silicone intraocular lenses. *J Cataract Refract Surg* 1996;22 Suppl 2:1259-62.
83. Mamalis N, Phillips B, Kopp CH, Crandall AS, Olson RJ. Neodymium: YAG capsulotomy rates after phacoemulsification with silicone posterior chamber intraocular lenses. *J Cataract Refract Surg* 1996;22 Suppl 2:1296-302.
84. Ram J, Kaushik S, Brar GS, Gupta A. Neodymium:YAG capsulotomy rates following phacoemulsification with implantation of PMMA, silicone, and acrylic intraocular lenses. *Ophthalmic Surg Lasers* 2001;32:375-82.
85. Emery JM. Capsular opacification after cataract surgery. *Curr Opin Ophthalmol* 1999;10:73-80.
86. Nishi O, Nishi K. Preventing posterior capsule opacification by creating a discontinuous sharp bend in the capsule. *J Cataract Refract Surg* 1999;25:521-6.
87. Peng Q, Visessook N, Apple DJ, Pandey SK, Werner L, Escobar-Gomez M, Schoderbek R, Solomon KD, Guindi A. Surgical prevention of posterior capsule opacification. Part 3: Intraocular lens optic barrier effect as a second line of defense. *J Cataract Refract Surg* 2000;26:198-213.

88. Peng Q, Apple DJ, Visessook N, Werner L, Pandey SK, Escobar-Gomez M, Schoderbek R, Guindi A. Surgical prevention of posterior capsule opacification. Part 2: Enhancement of cortical cleanup by focusing on hydrodissection. *J Cataract Refract Surg* 2000;26:188-97.
89. Apple DJ, Peng Q, Visessook N, Werner L, Pandey SK, Escobar-Gomez M, Ram J, Whiteside SB, Schoderbeck R, Ready EL, Guindi A. Surgical prevention of posterior capsule opacification. Part 1: Progress in eliminating this complication of cataract surgery. *J Cataract Refract Surg* 2000;26:180-7.
90. Ram J, Pandey SK, Apple DJ, Werner L, Brar GS, Singh R, Chaudhary KP, Gupta A. Effect of in-the-bag intraocular lens fixation on the prevention of posterior capsule opacification. *J Cataract Refract Surg* 2001;27:1039-46.
91. Birinci H, Kuruoglu S, Oge I, Oge F, Acar E. Effect of intraocular lens and anterior capsule opening type on posterior capsule opacification. *J Cataract Refract Surg* 1999;25:1140-6.
92. Ravalico G, Tognetto D, Palomba M, Busatto P, Baccara F. Capsulorhexis size and posterior capsule opacification. *J Cataract Refract Surg* 1996;22:98-103.
93. Nishi O. Posterior capsule opacification. Part 1: Experimental investigations. *J Cataract Refract Surg* 1999;25:106-17.
94. Nishi O, Nishi K, Menapace R, Akura J. Capsular bending ring to prevent posterior capsule opacification: 2 year follow-up. *J Cataract Refract Surg* 2001;27:1359-65.
95. Nishi O, Nishi K, Akura J, Nagata T. Effect of round-edged acrylic intraocular lenses on preventing posterior capsule opacification. *J Cataract Refract Surg* 2001;27:608-13.
96. Versura P, Torreggiani A, Cellini M, Caramazza R. Adhesion mechanisms of human lens epithelial cells on 4 intraocular lens materials. *J Cataract Refract Surg* 1999;25:527-33.
97. Linnola RJ, Werner L, Pandey SK, Escobar-Gomez M, Znoiko SL, Apple DJ. Adhesion of fibronectin, vitronectin, laminin, and collagen type IV to intraocular lens materials in pseudophakic human autopsy eyes - Part 1: Histological sections. *J Cataract Refract Surg* 2000;26:1792-806.
98. Linnola RJ. Sandwich theory: bioactivity-based explanation for posterior capsule opacification. *J Cataract Refract Surg* 1997;23:1539-42.
99. Sterling S, Wood TO. Effect of intraocular lens convexity on posterior capsule opacification. *J Cataract Refract Surg* 1986;12:655-7.
100. Downing JE. Long-term discission rate after placing posterior chamber lenses with the convex surface posterior. *J Cataract Refract Surg* 1986;12:651-4.
101. Buehl W, Findl O, Menapace R, Rainer G, Sacu S, Kiss B, Petternel V, Georgopoulos M. Effect of an acrylic intraocular lens with a sharp posterior optic edge on posterior capsule opacification. *J Cataract Refract Surg* 2002;28:1105-11.
102. Nishi O, Nishi K, Akura J. Speed of capsular bend formation at the optic edge of acrylic, silicone, and poly(methyl methacrylate) lenses. *J Cataract Refract Surg* 2002;28:431-7.
103. Nishi O, Nishi K, Wickstrom K. Preventing lens epithelial cell migration using intraocular lenses with sharp rectangular edges. *J Cataract Refract Surg* 2000;26:1543-9.
104. Hansen SO, Solomon KD, McKnight GT, Wilbrandt TH, Gwin TD, O'Morchoe DJ, Tetz MR, Apple DJ. Posterior capsular opacification and intraocular lens decentration. Part I: Comparison of various posterior chamber lens designs implanted in the rabbit model. *J Cataract Refract Surg* 1988;14:605-13.
105. Nishi O, Nishi K, Wada K, Ohmoto Y, Akura J. Inhibition of lens epithelial cells by Fas-specific antibody activating Fas-Fas ligand system. *Curr Eye Res* 2001;23:192-8.
106. Nishi O, Nishi K, Saitoh I, Sakanishi K. Inhibition of migrating lens epithelial cells by sustained release of ethylenediaminetetraacetic acid. *J Cataract Refract Surg* 1996;22 Suppl 1:863-8.
107. Nishi O, Nishi K, Morita T, Tada Y, Shirasawa E, Sakanishi K. Effect of intraocular sustained release of indomethacin on postoperative inflammation and posterior capsule opacification. *J Cataract Refract Surg* 1996;22 Suppl 1:806-10.
108. Nishi O, Nishi K, Fujiwara T, Shirasawa E, Ohmoto Y. Effects of the cytokines on the proliferation of and collagen synthesis by human cataract lens epithelial cells. *Br J Ophthalmol* 1996;80:63-8.

109. Wallentin N, Lundgren B, Lundberg C. Lack of correlation between intraocular inflammation and after-cataract formation in the rabbit eye. *J Cataract Refract Surg* 2000;26:1389-97.
110. Pandey SK, Cochener B, Apple D.J., Colin J, Werner L, Bougaran R, Trivedi RH, Macky TA, Izak AM. Intracapsular ring sustained 5-fluorouracil delivery system for the prevention of posterior capsule opacification in rabbits; A histological study. *J Cataract Refract Surg* 2002;28:139-48.
111. Hepsten IF, Bayramlar H, Gultek A, Ozen S, Tilgen F, Evereklioglu C. Caffeic acid phenethyl ester to inhibit posterior capsule opacification in rabbits. *J Cataract Refract Surg* 1997;23:1572-6.
112. Biswas NR, Mongre PK, Das GK, Sen S, Angra SK, Vajpayee RB. Animal study on the effects of catalin on aftercataract and posterior capsule opacification. *Ophthalmic Research* 1999;31:140-2.
113. Shin DH, Kim YY, Ren J, Weatherwax AL, Pearlman RB, Kim C, Glover KB, Muenk SB. Decrease of capsular opacification with adjunctive mitomycin C in combined glaucoma and cataract surgery. *Ophthalmology* 1998;105:1222-6.
114. Janknecht P, Funk J. Die chirurgische Nachstarabsaugung, erfolgsquote und Komplikationen. *Ophthalmologe* 1992;89:291-4.
115. Wilhelmus KR, Emery JM. Posterior capsule opacification following phacoemulsification. *Ophthalmic Surg* 1980;11:264-7.
116. Mashhoudi N, Pearce JL. Retrospective study of 67 cases of secondary pars plana posterior capsulotomy. *Br J Ophthalmol* 1985;69:364-7.
117. Braig R.F., Neuhann T. Management of the posterior capsule. *Curr Opin Ophthalmol* 1994;5:79-84.
118. Harris WS, Herman WK, Fagadau WR. Management of the posterior capsule before and after the YAG laser. *Trans Ophthalmol Soc U K* 1985;104:533-5.
119. Kammann J, Douvas N. Alternativtherapie zum YAG-Laser bei proliferativer Nachstarbildung. *Fortschr Ophthalmol* 1986;83:453-5.
120. Knolle GEJ. Knife versus neodymium:YAG laser posterior capsulotomy: a one-year follow-up. *J Am Intraocul Impl Soc* 1985;11:448-55.
121. Kraff MC, Sanders DR, Jampol LM, Lieberman HL. Effect of primary capsulotomy with extracapsular surgery on the incidence of pseudophakic cystoid macular edema. *Am J Ophthalmol* 1984;98:166-70.
122. Tan JC, Spalton DJ, Arden GB. The effect of neodymium: YAG capsulotomy on contrast sensitivity and the evaluation of methods for its assessment. *Ophthalmology* 1999;106:703-9.
123. Knighton RW, Slomovic AR, Parrish RK. Glare measurements before and after neodymium-YAG laser posterior capsulotomy. *Am J Ophthalmol* 1985;100:708-13.
124. Liesegang TJ, Bourne WM, Ilstrup DM. Secondary surgical and neodymium-YAG laser discissions. *Am J Ophthalmol* 1985;100:510-9.
125. Magno BV, Datiles MB, Lasa MS, Fajardo MR, Caruso RC, Kaiser-Kupfer MI. Evaluation of visual function following neodymium:YAG laser posterior capsulotomy. *Ophthalmology* 1997;104:1287-93.
126. Hanuch OE, Agrawal VB, Papernov S, del C, Aquavella JV. Posterior capsule polishing with the neodymium:YLF picosecond laser: model eye study. *J Cataract Refract Surg* 1997;23:1561-71.
127. Beckman H, Sugar HS. Neodymium Laser Cyclocoagulation. *Arch Ophthalmol* 1973;90:27-8.
128. Krasnov MM. Laseropuncture of anterior chamber angle in glaucoma. *Am J Ophthalmol* 1973;75:674-8.
129. Fankhauser F, Lörtscher H, van der Zypen E. Clinical studies on high and low power laser radiation upon some structures of the anterior and posterior segments of the eye. *Int Ophthalmol* 1982;5:15-32.
130. Aron-Rosa D, Aron JJ, Griesemann M, Thyzel R. Use of the neodymium-YAG laser to open the posterior capsule after lens implant surgery: a preliminary report. *Am Intra-ocular Implant Soc J* 1980;6:352-4.

131. Aron-Rosa D, Griesemann JC, Aron JJ. Applications ophtalmologiques des lasers Néodymium Yag pulsés - Ouvertures préopératoires des cristallins avant implants et des cataractes secundaries derreieré implants cristallinieres. *J Fr Ophtalmol* 1981;4:61-6.
132. L'Esperance FAJ. *Ophthalmic Lasers.*, 3 ed. St Louis: C V Mosby, 1989.
133. Klapper RM. Neodymium:YAG laser microsurgery: Fundamental principles and clinical applications. *Int Ophthalmol Clin* 1985;25:1-195.
134. American Academy of Ophthalmology. Nd: YAG photodisruptors. *Ophthalmology, instrument and book issue* 1989;Pt 2:46-51.
135. American Academy of Ophthalmology. Nd:YAG photodisruptors. *Ophthalmology* 1993;100:1736-42.
136. Stark W.J., Worthen D., Holladay JT, Murray G. Neodymium:YAG lasers; an FDA report. *Ophthalmology* 1985;92:209-12.
137. Flohr MJ, Robin AL, Kelley JS. Early complications following Q-switched neodymium: YAG laser posterior capsulotomy. *Ophthalmology* 1985;92:360-3.
138. Nirankari WS, Richards RD. Complications associated with the use of the neodymium YAG laser. *Ophthalmology* 1985;92:1371-5.
139. Shah GR, Gills JP, Durham DG, Ausmus WH. Three thousand YAG lasers in posterior capsulotomies: an analysis of complications and comparison to polishing and surgical discission. *Ophthalmic Surg* 1986;17:473-7.
140. Durham DG, Gills JP. Three thousand YAG lasers in posterior caspsulotomies: an analysis of complications and comparison to polishing and surgical discissions. *Trans Am Ophthalmol Soc* 1985;LXXXIII:218-35.
141. Terry AC, Stark WJ, Maumenee AE, Fagadau W. Neodymium-YAG laser for posterior capsulotomy. *Am J Ophthalmol* 1983;96:716-20.
142. Aron-Rosa DS. Use of a pulsed picosecond Nd:YAG laser in 6,664 cases. *Am Intra-ocular Implant Soc J* 1984;10:35-40.
143. Bath PE, Fankhauser F. Long-term results of Nd:YAG laser posterior capsulotomy with the Swiss laser. *J Cataract Refract Surg* 1986;12:150-3.
144. Bath PE, Hoffer KJ, Aron-Rosa D, Dang Y. Glare disability secondary to YAG laser intraocular lens damage. *J Cataract Refract Surg* 1987;13:309-12.
145. Johnson SH, Kratz RP, Olson PF. Clinical experience with the Nd:YAG laser. *J Am Intraocul Impl Soc* 1984;10:452-60.
146. Ge J, Wand M, Chiang R, Paranhos A, Shields MB. Long-term effect of Nd:YAG laser posterior capsulotomy on intraocular pressure. *Arch Ophthalmol* 2000;118:1334-7.
147. Steinert RF, Puliafito CA, Kumar SR, Dudak SD, Patel S. Cystoid macular edema, retinal detachment, and glaucoma after Nd:YAG laser posterior capsulotomy. *Am J Ophthalmol* 1991;112:373-80.
148. Curtis W.J., Javitt J. Complications of neodymium:yttrium-aluminum-garnet laser capsulotomy. *Curr Opin Ophthalmol* 1994;5:30-4.
149. Chofflet J, Amar JP, Deidier D. Retrospektive Studie über die Komplikationen von 329 YAG-Laserkapsulotomien. *Fortschr Ophthalmol* 1991;88:806-8.
150. Altamirano D, Guex-Crosier Y, Bovey E. Complications dela capsulotomie postérieure au Nd:YAG laser. *Etude de 226 cas. Klin Monatsbl Augenheilkd* 1994;204:286-7.
151. Gardner KM, Straatsma BR, Pettit TH. Neodymium: YAG laser posterior capsulotomy: the first 100 cases at UCLA. *Ophthalmic Surg* 1985;16:24-8.
152. Keates RH, Steinert RF, Puliafito CA, Maxwell SK. Long-term follow-up of Nd:YAG laser posterior capsulotomy. *J Am Intraocul Impl Soc* 1984;10:164-8.
153. Winslow RL, Taylor BC. Retinal complications following YAG laser capsulotomy. *Ophthalmology* 1985;92:785-9.

154. Alpar JJ. Experiences with the Neodymium: YAG laser: interruption of anterior hyaloid membrane of the vitreous and cystoid macular edema. *Ophthalmic Surg* 1986;17:157-65.
155. Lewis H, Singer TR, Hanscom TA, Straatsma BR. A prospective study of cystoid macular edema after neodymium: YAG laser posterior capsulotomy. *Ophthalmology* 1987;94:478-82.
156. Carlson AN, Koch DD. Endophthalmitis following Nd:YAG laser posterior capsulotomy. *Ophthalmic Surg* 1988;19:168-70.
157. Tetz MR, Apple DJ, Price FWJ, Piest KL, Kincaid MC, Bath PE. A newly described complication of neodymium-YAG laser capsulotomy: exacerbation of an intraocular infection. Case report. *Arch Ophthalmol* 1987;105:1324-5.
158. Kumagai K, Ogino N, Shinjo U, Demizu S, Shioya M, Ueda K. Vitreous opacification after neodymium:YAG posterior capsulotomy. *J Cataract Refract Surg* 1999;25:981-4.
159. Skolnick KA, Perlman JI, Long DM, Kernan JM. Neodymium : YAG laser posterior capsulotomies performed by residents at a Veterans Administration hospital. *J Cataract Refract Surg* 2000;26:597-601.
160. Mainster MA, Sliney DH, Belcher CD, Buzney SM. Laser photodisruptors: damage mechanisms, instrument design and safety. *Ophthalmology* 1983;90:973-91.
161. Blankenstein MF, Zuclich J, Allen RG, Davis H, Thomas SJ, Harrison RF. Retinal hemorrhage thresholds for Q-switched Neodymium-YAG laser exposures. *Invest Ophthalmol* 1986;27:1176-9.
162. Bonner R.F., Gaasterland DE. Threshold for retinal damage associated with the use of high-power neodymium-YAG lasers in the vitreous. *Am J Ophthalmol* 1983;96:153-9.
163. Little HL, Jack RL. Q-switched neodymium: YAG laser surgery of the vitreous. *Graefes Arch Clin Exp Ophthalmol* 1986;224:240-6.
164. Pulifiato C.A., Wasson P, Steinert R.F., Gragoudas ES. Neodymium-YAG laser surgery on experimental vitreous membranes. *Arch Ophthalmol* 1984;102:843-7.
165. Jampol LM, Goldberg MF, Jednock N. Retinal damage from a Q-switched YAG laser. *Am J Ophthalmol* 1983;96:326-9.
166. Thach AB, Lopez MC, Snady-McCoy L, Golub BM, Frambach DA. Accidental Nd:YAG laser injuries to the macula. *Am J Ophthalmol* 1995;119:767-73.
167. Lam T.T., Tso M.O. Retinal injury by neodymium:YAG laser. *Retina* 1996;16:42-6.
168. WuDunn D, Parrish RK, Inana G. Genetic heterogeneity in Hispanic families with autosomal dominant juvenile glaucoma. *Ophthalmic Genet* 1996;17:87-94.
169. Lerman S, Thrasher B, Moran M. Vitreous changes after Nd:YAG laser irradiation of the posterior lens capsule or mid-vitreous. *Am J Ophthalmol* 1984;97:470-5.
170. Krauss J.M., Pulifiato C.A., Miglior S., Steinert R.F., Cheng H.M. Vitreous changes after neodymium-YAG laser photodisruption. *Arch Ophthalmol* 1986;104:592-7.
171. Faude F, Wiedemann P. Rhegmatogene amotio retinae. *Ophthalmologie* 1995;1995:229-46.
172. Chaine G, Sebag J, Coscas G. The induction of retinal detachment. *Trans Ophthalmol Soc U K* 1983;103:480-5.
173. Foos RY. Retinal holes. *Am J Ophthalmol* 1978;86:354-8.
174. Foos RY. Posterior vitreous detachment. *Trans Am Acad Ophthalmol Otolaryngol* 1972;76:480-97.
175. Weber-Krause B, Eckardt C. Häufigkeit einer Hinteren Glaskörperabhebung im Alter. *Ophthalmologie* 1997;94:619-23.
176. Dayan MR, Jayamanne DG, Andrews RM, Griffiths PG. Flashes and floaters as predictors of vitreoretinal pathology: is follow-up necessary for posterior vitreous detachment? *Eye* 1996;10:456-8.
177. Richardson PS, Benson MT, Kirkby GR. The posterior vitreous detachment clinic: do new retinal breaks develop in the six weeks following an isolated symptomatic posterior vitreous detachment? *Eye* 1999;13:237-40.
178. Kanski JJ. Complications of acute posterior vitreous detachment. *Am J Ophthalmol* 1975;44-6.

179. Byer NE. Natural history of posterior vitreous detachment with early management as the premier line of defense against retinal detachment. *Ophthalmology* 1994;101:1503-13.
180. Byer NE. What happens to untreated asymptomatic retinal breaks, and are they affected by posterior vitreous detachment? *Ophthalmology* 1998;105:1045-50.
181. Novak MA, Welch RB. Complications of acute symptomatic posterior vitreous detachment. *Am J Ophthalmol* 1984;97:308-14.
182. Hikichi T, Trempe CL, Schepens CL. Posterior vitreous detachment as a risk factor for retinal detachment. *Ophthalmology* 1995;102:527-8.
183. Hikichi T, Trempe CL. Relationship between floaters, light flashes, or both, and complications of posterior vitreous detachment. *Am J Ophthalmol* 1994;117:593-8.
184. Folk JC, Pulido JS. Miscellaneous Chorioretinal Disorders. In: Weingeist TA, Kass MA, eds. *Laser Photocoagulation of the Retina and Choroid*. San Francisco: American Academy of Ophthalmology, 1997; chap. 7.
185. Davis MD. The natural history of retinal breaks without detachment. *Trans Am Ophthalmol Soc* 1973;71:343-72.
186. Davis M.D. Natural history of retinal breaks without detachment. *Arch Ophthalmol* 1974;92:183-94.
187. Folk JC, Bennett SR, Klugman M.R, Arrindell E.L., Boldt H.C. Prophylactic treatment to the fellow eye of patients with phakic lattice retinal detachment: Analysis of failures and risks of treatment. *Retina* 1990;10:165-9.
188. Folk JC, Arrindell E.L., Klugman M.R. The fellow eye of patients with phakic lattice retinal detachment. *Ophthalmology* 1989;96:72-9.
189. Folk JC, Boldt H.C. Asymptomatic retinal breaks and effects of posterior vitreous detachment; discussion. *Ophthalmology* 1998;105:1049-50.
190. Byer NE. Subclinical retinal detachment resulting from asymptomatic retinal breaks; prognosis for progression and regression. *Ophthalmology* 2001;108:1499-504.
191. Byer NE. The natural history of asymptomatic retinal breaks. *Ophthalmology* 1982;89:1033-9.
192. Byer NE. Spontaneous regression and disappearance of subclinical rhegmatogenous retinal detachment. *Am J Ophthalmol* 2001;131:269-70.
193. Combs JL, Welch RB. Retinal breaks without detachment: natural history, management and long term follow-up. *Trans Am Ophthalmol Soc* 1982;80:64-97.
194. Haimann MH, Burton TC, Brown CK. Epidemiology of retinal detachment. *Arch Ophthalmol* 1982;100:289-92.
195. Laatikainen L, Tolppanen E.M., Harju H. Epidemiology of rhegmatogenous retinal detachment in a Finnish population. *Acta Ophthalmol* 1985;63:59-64.
196. The Eye Disease Case-Control Study Group. Risk factors for idiopathic rhegmatogenous retinal detachment. *Am J Epidemiol* 1993;137:749-57.
197. Celorio J.M., Pruett RC. Prevalence of lattice degeneration and its relation to axial length in severe myopia. *Am J Ophthalmol* 1991;111:20-3.
198. Byer NE. Long-term natural history of lattice degeneration of the retina. *Ophthalmology* 1989;96:1396-402.
199. Wilkinson CP. Evidence-based analysis of prophylactic treatment of asymptomatic retinal breaks and lattice degeneration. *Ophthalmology* 2000;107:12-5.
200. Wilkinson CP. Interventions for asymptomatic retinal breaks and lattice degeneration for preventing retinal detachment. *The Cochrane Database of Systematic Reviews* 2001.
201. Laatikainen L. The fellow eye in patients with unilateral retinal detachment: findings and prophylactic treatment. *Acta Ophthalmol* 1985;63:546-51.

202. Lorentzen SE. Frequency of lattice degeneration and retinal breaks in the fellow eye in retinal detachment. *Acta Ophthalmol* 1988;66:157-60.
203. Mastropasqua L, Carpineto P, Ciancaglini M, Falconio G, Gallenga PE. Treatment of retinal tears and lattice degenerations in fellow eyes in high risk patients suffering retinal detachment: a prospective study. *Br J Ophthalmol* 1999;83:1046-9.
204. Carpineto P, Ciancaglini M, Mastropasqua L. Retinal detachment prophylaxis. *Ophthalmology* 2002;109:217.
205. McPherson AR, O'Malley RE, Beltangady SS. Management of the fellow eyes of patients with rhegmatogenous retinal detachment. *Ophthalmology* 1981;88:922-34.
206. Smiddy WE, Flynn HWJ, Nicholson DH, Clarkson JG, Gass JD, Olsen KR, Feuer W. Results and complications in treated retinal breaks [see comments]. *Am J Ophthalmol* 1991;112:623-31.
207. Schroeder W, Baden H. Netzhautablosung trotz vorbeugender Koagulation. *Ophthalmologe* 1996;93:144-8.
208. Wilkinson CP. Retinal detachment prophylaxis. *Ophthalmology* 2002;109:217-8.
209. Byer NE. Kann die rhegmatogene Netzhautablösung verhindert werden? Überlegungen zur Geschichte der "prophylaktischen" Behandlung der Netzhautablösung. *Ophthalmologe* 2000;97:696-702.
210. Fan DS, Lam DS, Li KK. Retinal complications after cataract extraction in patients with high myopia. *Ophthalmology* 1999;106:688-91.
211. Kreissig I, Rose D, Jost B. Minimized surgery for retinal detachments with segmental buckling and nondrainage. An 11-year follow-up. *Retina* 1992;12:224-31.
212. Kreissig I. Die Behandlung der primären Ablatio retinae - Minimal extraokular oder intraokular? *Ophthalmologe* 2002;99:474-84.
213. Lincoff H, Kreissig I. Changing patterns in the surgery for retinal detachment: 1929 to 2000. *Klin Monatsbl Augenheilkd* 2000;216:352-9.
214. Faude F, Meier P, Wiedemann P. Eindellende Operationen bei rhegmatogener Amotio retinae. *Ophthalmologe* 2002;99:308-23.
215. American Academy of Ophthalmology. The repair of rhegmatogenous retinal detachments. *Ophthalmology* 1990;97:1562-72.
216. Ah-Fat FG, Sharma MC, Majid MA, McGalliard JN. Trends in vitreoretinal surgery at a tertiary referral centre: 1987 to 1996. *Br J Ophthalmol* 1999;83:396-8.
217. Ross WH, Kozy DW. Visual recovery in macula-off rhegmatogenous retinal detachments. *Ophthalmology* 1998;105:2149-53.
218. Ross WH, Stockl F.A. Visual recovery after retinal detachment. *Curr Opin Ophthalmol* 2000;11:191-4.
219. Anonymous. The repair of rhegmatogenous retinal detachments. American Academy of Ophthalmology [see comments]. *Ophthalmology* 1996;103:1313-24.
220. Laatikainen L, Harju H, Tolppanen E.M. Post-operative outcome in rhegmatogenous retinal detachment. *Acta Ophthalmol* 1985;63:647-55.
221. Girard P, Karpouzas I. Visual acuity after scleral buckling surgery. *Ophthalmologica* 1995;209:323-8.
222. Sullivan PM, Luff AJ, Aylward GW. Results of primary retinal reattachment surgery: a prospective audit. *Eye* 1997;11:869-71.
223. Sharma T, Challa JK, Ravishankar KV, Murugesan R. Scleral buckling for retinal detachment. Predictors for anatomic failure. *Retina* 1994;14:338-43.
224. Minihan M, Tanner V., Williamson TH. Primary rhegmatogenous retinal detachment: 20 years of change. *Br J Ophthalmol* 2001;85:546-8.

225. Mangouritsas G, Rothbacher HH, Heidenkummer HP, Ulbig M, Kampik A. Risikofaktoren für operative Misserfolge bei rhegmatogener Netzhautablösung. *Klin Monatsbl Augenheilkd* 1995;206:20-8.
226. Tornambe PE, Poliner LS, Hilton GF, Grizzard WS. Comparison of pneumatic retinopexy and scleral buckling in the management of primary rhegmatogenous retinal detachment. *Am J Ophthalmol* 1999;127:741-3.
227. Han DP, Mohsin NC, Guse CE, Hartz A, Tarkanian CN. Comparison of pneumatic retinopexy and scleral buckling in the management of primary rhegmatogenous retinal detachment. Southern Wisconsin Pneumatic Retinopexy Study Group. *Am J Ophthalmol* 1998;126:658-68.
228. Heinrich T, Balogh T, Kalman A, Messmer EP. Ergebnisse nach konventioneller Ablatiochirurgie. I Studieplanung, Patienten und Visusergebnisse. *Klin Monatsbl Augenheilkd* 1992;200:454-6.
229. The Retina Society Terminology Committee. The classification of retinal detachment with proliferative vitreoretinopathy. *Ophthalmology* 1983;90:121-5.
230. Grizzard WS, Hilton GF, Hammer ME, Taren D. A multivariate analysis of anatomic success of retinal detachments treated with scleral buckling. *Graefes Arch Clin Exp Ophthalmol* 1994;32:1-7.
231. Tani P., Robertson D.M., Langworthy A. Prognosis for central vision and anatomic reattachment in rhegmatogenous retinal detachment with macula detached. *Am J Ophthalmol* 1981;1981:611-20.
232. Friberg TR, Eller AW. Prediction of visual recovery after scleral buckling of macula-off retinal detachments. *Am J Ophthalmol* 1992;114:715-22.
233. Kreissig I. Prognosis of return of macular function after retinal detachment. *Mod Probl Ophthalmol* 1977;18:415-29.
234. Isernhagen RD, Wilkinson CP. Visual acuity after the repair of pseudophakic retinal detachments involving the macula. *Retina* 1989;9:15-21.
235. Isernhagen RD, Wilkinson CP. Recovery of visual acuity following the repair of pseudophakic retinal detachment. *Trans Am Ophthalmol Soc* 1988;86:291-306.
236. Törnquist R., Bodin L, Törnquist P. Retinal detachment: A study of population-based patient material in Sweden 1971-1981. IV Prediction of surgical outcome. *Acta Ophthalmol* 1988;66:637-42.
237. Schein OD, Steinberg EP, Cassard SD, Tielsch JM, Javitt JC, Sommer A. Predictors of outcome in patients who underwent cataract surgery. *Ophthalmology* 1995;102:817-23.
238. Scott IU, Schein OD, West S, Bandeen-Roche K, Enger C, Folstein MF. Functional status and quality of life measurement among ophthalmic patients. *Arch Ophthalmol* 1994;112:329-35.
239. Uusitalo RJ, Tarkkanen A. Outcomes of small incision cataract surgery. *J Cataract Refract Surg* 1998;24:212-21.
240. Scott IU, Smiddy WE, Feuer W, Merikansky A. Vitreoretinal surgery outcomes: results of a patient satisfaction/functional status survey. *Ophthalmology* 1998;105:795-803.
241. Scott IU, Smiddy WE, Merikansky A, Feuer W. Vitreoretinal surgery outcomes. Impact on bilateral visual function. *Ophthalmology* 1997;104:1041-8.
242. Sullivan PM, Luff AJ, Julious SA, Canning CR. Patient satisfaction following vitreoretinal surgery. *Eye* 1993;7:433-5.
243. Liesenhoff O, Kampik A. Risiko der Ablatio Retinae bei Pseudophakie in axialer Myopie. *Ophthalmologie* 1994;91:807-10.
244. Colin J, Robinet A, Cochener B. Retinal detachment after clear lens extraction for high myopia: seven-year follow-up. *Ophthalmology* 1999;106:2281-5.
245. Fritch CD. Risk of retinal detachment in myopic eyes after intraocular lens implantation: a 7 year study. *J Cataract Refract Surg* 1998;24:1357-60.
246. Kraff MC, Sanders DR. Incidence of retinal detachment following posterior chamber intraocular lens surgery. *J Cataract Refract Surg* 1990;16:477-80.
247. Malbran E, Dodds R, Hulsbus R, Dodd CL, Charles D., Caride F. Myopic and nonmyopic aphakic retinal detachment: time interval and location of breaks. *Ann Ophthalmol* 1989;1989:296-9.

248. Alldredge CD, Elkins B, Alldredge OCJ. Retinal detachment following phacoemulsification in highly myopic cataract patients. *J Cataract Refract Surg* 1998;24:777-80.
249. Olsen G, Olson RJ. Update on a long-term, prospective study of capsulotomy and retinal detachment rates after cataract surgery. *J Cataract Refract Surg* 2000;26:1017-21.
250. Jacobi FK, Hessemer V. Pseudophakic retinal detachment in high axial myopia. *J Cataract Refract Surg* 1997;23:1095-102.
251. Nissen KR, Fuchs J, Goldschmidt E, Andersen CU, Bjerrum K, Corydon L, Degn T, Eisgart F, Henning V, Jensen JE, Krogh E, Lowes M, Mortensen K, Nielsen CH, Olsen T, Storr-Paulsen A, Sorensen TB, Winther-Nielsen A. Retinal detachment after cataract extraction in myopic eyes. *J Cataract Refract Surg* 1998;24:772-6.
252. Koch DD, Liu JF, Gill EP, Parke DW. Axial myopia increases the risk of retinal complications after neodymium-YAG laser posterior capsulotomy. *Arch Ophthalmol* 1989;107:986-90.
253. Javitt JC, Vitale S, Canner JK, Krakauer H, McBean AM, Sommer A. National outcomes of cataract extraction. I. Retinal detachment after inpatient surgery. *Ophthalmology* 1991;98:895-902.
254. Wollensak J, Zeisberg B., Duy T.P. Netzhautablösung nach implantation einer hinterkammerlinse. *Klin Monatsbl Augenheilkd* 1988;192:1-5.
255. Kraff M, Sanders DR. Incidence of retinal detachment following posterior chamber intraocular lens surgery. *J Cataract Refract Surg* 1990;16:477-80.
256. Norregaard JC, Thoning H, Andersen TF, Bernth-Petersen P, Javitt JC, Anderson GF. Risk of retinal detachment following cataract extraction: results from the International Cataract Surgery Outcomes Study. *Br J Ophthalmol* 1996;80:689-93.
257. Coonan P, Fung WE, Webster RGJ, Allen AWJ, Abbott RL. The incidence of retinal detachment following extracapsular cataract extraction. A ten-year study. *Ophthalmology* 1985;92:1096-101.
258. Smith PW, Stark WJ, Maumenee AE, Enger CL, Michels RG, Glaser BM, Bonham RD. Retinal detachment after extracapsular cataract extraction with posterior chamber intraocular lens. *Ophthalmology* 1987;94:495-504.
259. Davison JA. Retinal tears and detachments after extracapsular cataract surgery. *J Cataract Refract Surg* 1988;14:624-32.
260. Lyle WA, Jin GJ. Phacoemulsification with intraocular lens implantation in high myopia. *J Cataract Refract Surg* 1996;22:238-42.
261. Smith RT, Moscoso WE, Trokel S, Auran J. The barrier function in neodymium-YAG laser capsulotomy. *Arch Ophthalmol* 1995;113:645-52.
262. Smith RT, Campbell CJ, Koester CJ, Trokel S, Anderson A. The barrier function in extracapsular cataract surgery. *Ophthalmology* 1990;97:90-5.
263. Ohrloff C, Schalnus R, Rothe R, Spitznas M. Role of the posterior capsule in the aqueous-vitreous barrier in aphakic and pseudophakic eyes. *J Cataract Refract Surg* 1990;16:198-201.
264. Ohrloff C. Die Bedeutung der intakten Hinterkapseln für den Glaskörper. Komplikationen nach hinterer kapsulotomie. *Klin Monatsbl Augenheilkd* 1994;205:181-6.
265. Schrader WF, Bellmann C, Hansen LL. Risikofaktoren der Pseudophakieamotio. *Ophthalmologie* 1994;91:801-6.
266. Nielsen NE, Naeser K. Epidemiology of retinal detachment following extracapsular cataract extraction: a follow-up study with an analysis of risk factors. *J Cataract Refract Surg* 1993;19:675-80.
267. Lahav M, Schneider F. The decreased incidence of retinal detachment after cataract surgery. *Trans Am Ophthalmol Soc* 1988;86:321-9.
268. Binkhorst CD. Corneal and retinal complications after cataract extraction: The mechanical aspect of endophthalmodonesis. *Ophthalmology* 1980;87:609-17.
269. Buzney SM, Thomas JV. Effect of aphakia upon the vitreous. *Bull Soc Belg Ophthalmol* 1987;223 Pt 1:197-210.
270. Schalnus RW, Ohrloff C, Magone T. Die Kammerwasser-Glaskörper-Barriere und die Blut-Kammerwasser-Schranke nach YAG-Laser-kapsulotomie bei Kapselsack- vs. Sulcus- Ciliaris-Fixierung der IOL. *Ophthalmologie* 1995;92:289-92.

271. Arnott EJ, Grindle CF, Krolman GM. Four and one-half year study of the relationship between one-piece encircling loop polymethylmethacrylate lenses and retinal detachment. *J Cataract Refract Surg* 1988;14:387-92.
272. Jaffe NS, Clayman HM, Jaffe MS. Retinal detachment in myopic eyes after intracapsular and extracapsular cataract extraction. *Am J Ophthalmol* 1984;97:48-52.
273. Sorensen KE, Baggesen K. Retinal detachment following intracapsular cataract extraction. *Acta Ophthalmol* 1990;68:549-53.
274. Vogel M, Behrens-Baumann W, Petersen J, Quentin CD, Hilgers R, Kron R, Hauptvogel A. Vergleich der Komplikationen nach intra- und extrakapsulärer Kataraktextraktion mit Linsennimplantation. *Klin Monatsbl Augenheilkd* 1993;203:43-52.
275. Urbak SF, Naeser K. Retinal detachment following intracapsular and extracapsular cataract extraction. A comparative, retrospective follow-up study. *Acta Ophthalmol (Copenh)* 1993;71:782-6.
276. Naeser K, Baggesen K, Knudsen EB. Retinal detachment following intracapsular cataract extraction. A 10-year follow-up study. *Acta Ophthalmol Scand* 1998;76:727-30.
277. Naeser K, Nielsen NE. Retinal detachment following intracapsular and extracapsular cataract extraction. *J Cataract Refract Surg* 1995;21:127-31.
278. Naeser K, Kobayashi C. Epidemiology of aphakic retinal detachment following intracapsular cataract extraction: a follow-up study with an analysis of risk factors. *J Cataract Refract Surg* 1988;14:303-8.
279. Spiegel D, Sachse KD, Lund OE. Zur Häufigkeit der Aphakieablatio nach intra- bzw. extrakapsulärer Operation. *Fortschritte der Ophthalmologie* 1987;84:190-2.
280. Gray RH, Evans AR, Constable IJ, McAllister IL. Retinal detachment and its relation to cataract surgery. *Br J Ophthalmol* 1989;73:775-80.
281. McDonnell PJ, Patel A, Green WR. Comparison of intracapsular and extracapsular cataract surgery, a histopathologic study. *Ophthalmology* 1985;92:1208-25.
282. Friedman Z, Neumann E. Posterior vitreous detachment after cataract extraction in non-myopic eyes and the resulting retinal lesions. *Br J Ophthalmol* 1975;59:451-4.
283. Hovland KR. Vitreous findings in fellow eyes of aphakic retinal detachment. *Am J Ophthalmol* 1978;86:350-3.
284. Österlin S. On the molecular biology of the vitreous in the aphakic eye. *Acta Ophthalmol* 1977;55:353-61.
285. Yoshida A, Ogasawara H, Jalkh AE, Sanders RJ, McMeel JW, Schepens CL. Retinal detachment after cataract surgery. Surgical results. *Ophthalmology* 1992;99:460-5.
286. Girard P, Karpouzas I. Pseudophakic retinal detachment: anatomic and visual results. *Graefes Arch Clin Exp Ophthalmol* 1995;233:324-30.
287. McHugh D, Wong D, Chignell A, Leaver P, Cooling R. Pseudophakic retinal detachment. *Graefes Arch Clin Exp Ophthalmol* 1991;229:521-5.
288. Gassmann FA. Aphakieamotiones versus Pseudophakieamotiones. *Klin Monatsbl Augenheilkd* 1988;192:444-7.
289. Ross WH. Pseudophakic retinal detachment. *Can J Ophthalmol* 1984;19:119-21.
290. Desai UR, Strassman IB. Combined pars plana vitrectomy and scleral buckling for pseudophakic and aphakic retinal detachments in which a break is not seen preoperatively. *Ophthalmic Surg Lasers* 1997;28:718-22.
291. Wilkinson CP. Retinal detachment following intraocular lens implantation. *Graefes Arch Clin Exp Ophthalmol* 1986;224:64-6.
292. Bradford JD, Wilkinson CP, Fransen SR. Pseudophakic retinal detachments. The relationships between retinal tears and the time following cataract surgery at which they occur. *Retina* 1989;9:181-6.
293. Yoshida A, Ogasawara H, Jalkh AE, Sanders RJ, McMeel JW, Schepens CL. Retinal detachment after cataract surgery. Predisposing factors. *Ophthalmology* 1992;99:453-9.

294. Ambler JS, Constable IJ. Retinal detachment following Nd:YAG capsulotomy. *Aust N Z J Ophthalmol* 1988;16:337-41.
295. Dardenne MU, Gerten GJ, Kokkas K, Kermani O. Retrospective study of retinal detachment following neodymium:YAG laser posterior capsulotomy. *J Cataract Refract Surg* 1989;15:676-80.
296. Glacet-Bernard A, Brahim R, Mokhtari O, Quentel G, Coscas G. Decollement de retine apres capsulotomie posterieure au laser Nd:YAG. Etude retrospective de 144 capsulotomies. *Journal Francais d Ophtalmologie* 1993;16:87-94.
297. Herzeel R, Tassignon MJ, Brihaye-Van G, Kennis J. Decollement de la retine et Q-switched Nd:YAG laser capsulotomie. *Bull Soc Belg Ophthalmol* 1986;218:77-82.
298. Barraquer C, Cavelier C, Mejia LF. Incidence of retinal detachment following clear-lens extraction in myopic patients. Retrospective analysis. *Arch Ophthalmol* 1994;112:336-9.
299. Van Westenbrugge JA, Gimbel HV, Soucek J, Chow D. Incidence of retinal detachment following Nd:YAG capsulotomy after cataract surgery. *J Cataract Refract Surg* 1992;18:352-5.
300. Rickman-Barger L, Florine CW, Larson RS, Lindstrom RL. Retinal detachment after neodymium:YAG laser posterior capsulotomy. *Am J Ophthalmol* 1989;107:531-6.
301. Salvesen S, Eide N, Syrdalen P. Retinal detachment after YAG-laser capsulotomy. *Acta Ophthalmol* 1991;69:61-4.
302. Vester CA, Bienfait MF, de J, Pameijer JH. Retinal detachment following neodymium-YAG laser capsulotomy. *Fortschr Ophthalmol* 1986;83:441-3.
303. Bovey E, Gonvers M, Sahli O. Traitement chirurgical du decollement de retine chez le pseudophaque: comparaison entre la vitrectomie et la compression episclerale. *Klin Monatsbl Augenheilkd* 1998;212:314-7.
304. Speicher MA, Fu AD, Martin JP, von Fricken M.A. Primary vitrectomy alone for repair of retinal detachments following cataract surgery. *Retina* 2000;20:459-64.
305. Campo RV, Sipperley JO, Sneed SR, Park DW, Dugel PU, Jacobsen J, Flindall RJ. Pars plana vitrectomy without scleral buckle for pseudophakic retinal detachments. *Ophthalmology* 1999;106:1811-5.
306. Bartz-Schmidt KU, Kirchof B, Heimann K. Primary vitrectomy for pseudophakic retinal detachment. *Br J Ophthalmol* 1996;80:346-9.
307. Brazitikos PD, D'Amico DJ, Tsinopoulos IT, Stangos NT. Primary vitrectomy with perfluoro-n-octane use in the treatment of pseudophakic retinal detachment with undetected retinal breaks. *Retina* 1999;19:103-9.
308. Framme C, Roider J, Hoerauf H, Laqua H. Komplikationen nach externer Nezhthautchirurgie bei Pseudophakieablatio - Sind eindellende Operationsverfahren noch aktuell? *Klin Monatsbl Augenheilkd* 2000;216:25-32.
309. Ho PC, Tolentino FI. Pseudophakic retinal detachment. Surgical success rate with various types of IOLs. *Ophthalmology* 1984;91:847-52.
310. Ho PC, Tolentino FI. Retinal detachment following extracapsular cataract extraction and posterior chamber intraocular lens implantation. *Br J Ophthalmol* 1985;69:650-3.
311. Cousins S, Boniuk I, Okun E, Johnston GP, Arribas NP, Escoffery RF, Burgess DB, Grand MG, Olk RJ, Schoch LH. Pseudophakic retinal detachments in the presence of various IOL types. *Ophthalmology* 1986;93:1198-208.
312. Berrod JP, Sautiere B, Rozot P, Raspiller A. Retinal detachment after cataract surgery. *Int Ophthalmol* 1997;20:301-8.
313. Greven CM, Sanders RJ, Brown GC, Annesley WH, Sarin LK, Tasman W, Morgan TM. Pseudophakic retinal detachments. Anatomic and visual results. *Ophthalmology* 1992;99:257-62.
314. Grüterich M, Clemente C, Mueller AJ, Ulbig MW, Kampik A. Multifaktorielle Analyse des Therapieerfolges der Pseudophakieablatio. *Ophthalmologie* 2000;97:609-14.
315. Newman DK, Burton RL. Primary vitrectomy for pseudophakic and aphakic retinal detachments. *Eye* 1999;13:635-9.
316. Bartz-Schmidt KU, Kirchof B, Heimann K. Risiko-Faktoren der Reablatio retinae durch proliferative Vitreoretinopathie nach episkleraler Chirurgie wegen Pseudophakie-Ablatio. *Klin Monatsbl Augenheilkd* 1996;208:82-6.

317. Bossung C, Müller K, Heiland E, Richard G. Erfolge nach Netzhautoperationen linsenhaltiger und pseudophaker Augen im Vergleich unter Berücksichtigung von präoperativem Befund und Art des Linsenimplantats. *Klin Monatsbl Augenheilkd* 1992;201:79-82.
318. Ramsay RC, Cantrill HL, Knobloch WH. Pseudophakic retinal detachment. *Can J Ophthalmol* 1983;18:262-5.
319. Girard P, Gaudric A, Lequoy O, Chauvaud D, Chaîne G. Pseudophakic retinal detachment. *Ophthalmologica* 1991;203:30-7.
320. Haddad WM, Monin C, Morel C, Larricart P, Quesnot S, Ameline B, Loison K, Belghiti A, Laroche L. Retinal detachment after phacoemulsification: A study of 114 cases. *Am J Ophthalmol* 2002;133:630-8.
321. Lincoff H, Gieser R. Finding the retinal hole. *Mod Probl Ophthalmol* 1972;10:78-87.
322. Altman DG. *Practical Statistics for Medical Research.*, 1 ed. London: Chapman & Hall, 1991.
323. Parmar MKB, Machin D. *Survival analysis - A practical approach.*, 1 ed. Chichester, England: John Wiley & Sons, 1995.
324. Auffarth GU, Nimsgern C, Tetz MR, Volcker HE. Cataracta secundaria. Analyse der Energiemengen zur Nd:YAG-Laserkapsulotomie. *Ophthalmologie* 2000;97:1-4.
325. Oldendoerf J. Netzhautablösung nach Neodym-YAG-Laser-Kapsulotomie in aphaken und pseudophaken Augen. *Klin Monatsbl Augenheilkd* 1989;194:234-40.
326. MacEwen CJ, Dutton GN. Neodymium-YAG laser in the management of posterior capsular opacification--complications and current trends. *Trans Ophthalmol Soc U K* 1986;105:337-44.
327. Werner EB. *Manual of visual fields.*, 1 ed. New York, USA: Churchill Livingstone Inc., 1991.
328. Brunette I, Gresset J, Boivin JF, Pop M, Thompson P, Lafond GP, Makni H. Functional outcome and satisfaction after photorefractive keratectomy. Part 2: survey of 690 patients. *Ophthalmology* 2000;107:1790-6.
329. Rose K, Harper R, Tromans C, Waterman C, Goldberg D, Haggerty C, Tullo A. Quality of life in myopia. *British Journal of Ophthalmology* 2000;84:1031-4.
330. Parrish RK. Visual impairment, visual functioning, and quality of life assessments in patients with glaucoma. *Trans Am Ophthalmol Soc* 1996;94:919-1028.
331. Snead MP, Scott JD. Results of primary retinal detachment surgery: a prospective audit. *Eye* 1998;12 (Pt 4):750-1.