

<https://helda.helsinki.fi>

---

"Dirty coagulation" technique as an alternative to microclips for control of bleeding from deep feeders during brain arteriovenous malformation surgery

Kozyrev, Danil

2017-05

---

Kozyrev , D , Thiarawat , P , Rezai Jahromi , B , Intarakhao , P , Choque-Velasquez , J , Hijaz , F , Teo , M K & Hernesniemi , J 2017 , ' "Dirty coagulation" technique as an alternative to microclips for control of bleeding from deep feeders during brain arteriovenous malformation surgery ' , Acta Neurochirurgica , vol. 159 , no. 5 , pp. 855-859 . <https://doi.org/10.1007/s00701-017-3138-8>

---

<http://hdl.handle.net/10138/234742>

<https://doi.org/10.1007/s00701-017-3138-8>

---

unspecified

publishedVersion

---

*Downloaded from Helda, University of Helsinki institutional repository.*

*This is an electronic reprint of the original article.*

*This reprint may differ from the original in pagination and typographic detail.*

*Please cite the original version.*

# “Dirty coagulation” technique as an alternative to microclips for control of bleeding from deep feeders during brain arteriovenous malformation surgery

Danil A. Kozyrev<sup>1,2</sup> · Peeraphong Thiarawat<sup>1</sup> · Behnam Rezai Jahromi<sup>1</sup> · Patcharin Intarakhao<sup>1</sup> · Joham Choque-Velasquez<sup>1</sup> · Ferzat Hijazy<sup>1</sup> · Mario K. Teo<sup>1,3</sup> · Juha Hernesniemi<sup>1</sup>

Received: 14 September 2016 / Accepted: 27 February 2017 / Published online: 11 March 2017  
© Springer-Verlag Wien 2017

## Abstract

**Background** Meticulous haemostasis is one of the most important factors during microneurosurgical resection of brain arteriovenous malformation (AVM). Controlling major arterial feeders and draining veins with clips and bipolar coagulation are well-established techniques, while managing with bleeding from deep tiny vessels still proves to be challenging. This technical note describes a technique used by the senior author in AVM surgery for last 20 years in dealing with the issue highlighted.

**Method** “Dirty coagulation” is a technique of bipolar coagulation of small feeders carried out together with a thin layer of brain tissue that surrounds these fragile vessels. The senior author uses this technique for achieving permanent haemostasis predominantly in large and/or deep-seated AVMs. To illustrate the efficacy of this technique, we retrospectively reviewed the outcome of Spetzler-Martin (SM) grade III-V AVMs resected by the senior author over the last 5 years (2010–2015).

**Results** Thirty-five cases of AVM surgeries (14 SM grade III, 15 SM grade IV and 6 SM grade V) in this 5-year period were

analysed. No postoperative intracranial haemorrhage was encountered as a result of bleeding from the deep feeders. Postoperative angiograms showed complete resection of all AVMs, except in two cases (SM grade V and grade III).

**Conclusions** “Dirty coagulation” provides an effective way to secure haemostasis from deep tiny feeders. This cost-effective method could be successfully used for achieving permanent haemostasis and thereby decreasing postoperative haemorrhage in AVM surgery.

**Keywords** Arteriovenous malformation · Bipolar coagulation · Microneurosurgery · Neurosurgical trick

## Background

Resection of high-grade cerebral arteriovenous malformations (AVMs) is considered amongst the most complex and difficult in neurovascular surgeries. Some of the major problems are caused by not achieving permanent haemostasis in large and/or deep-seated lesions, commonly due to the small fragile feeders with a tendency to retract and hide inside white matter, and therefore resistant to simple coagulation. Furthermore, due to the very irregular elastic lamina, bipolar coagulation of these small fragile feeder vessels has proved ineffective, as they commonly stick to the bipolar forceps. One of the strategies described was the application of miniclips or microclips to manage these fragile vessels. However, if many microclips are used, orientation in the surgical field becomes more difficult and the risk of accidentally tearing the vessels increases due to inadvertent manipulation of the clips. Different strategies have been developed, including the “dirty coagulation” technique, to deal with this problem when resecting brain AVM. Even though the technique might not seem elegant, it has proved to be effective.

**Electronic supplementary material** The online version of this article (doi:10.1007/s00701-017-3138-8) contains supplementary material, which is available to authorised users.

✉ Danil A. Kozyrev  
danilkozyrev@gmail.com

<sup>1</sup> Department of Neurosurgery, Helsinki University Hospital, Topeliuksenkatu 5, 00260 Helsinki, Finland

<sup>2</sup> Department of Paediatric Neurology and Neurosurgery, North-Western State Medical University, St. Petersburg, Russia

<sup>3</sup> Department of Neurosurgery, Bristol Institute of Clinical Neuroscience, North Bristol University Hospital, Bristol, UK

This article describes the “dirty coagulation” technique in the microneurosurgical management of AVM and reviews the results of complex AVM resection by the senior author in the last 5 years to illustrate the efficacy based on intraoperative videos, radiological reports and clinical outcomes.

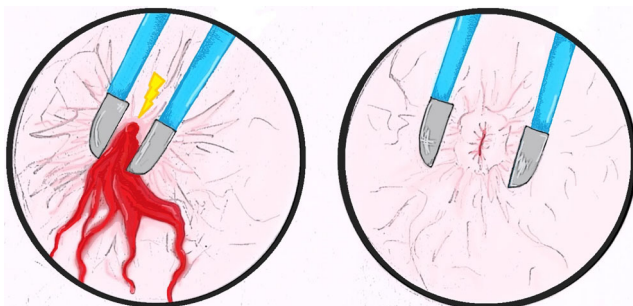
## Methods

### Clinical material

From an extensive database of more than 1,200 AVMs treated in Helsinki and Kuopio, Finland, we retrospectively analysed AVM resections over a 5-year period (from September 2010 to June 2015) in view of the availability of high-definition quality videos. During this time, the senior author operated on 62 patients harbouring supratentorial and infratentorial AVMs. All the cases were categorised according to the Spetzler-Martin grading system (SM) [11]. We then selected 35 cases of SM grade III–V AVMs with intraoperative videos available for review. These high-grade cases were selected as they were most challenging in eliminating these tiny but extremely fragile feeder vessels. The data were collected under the approval of a local university hospital ethics committee (469/E0/04 HUCH).

### Surgical technique

During dissection of the AVM nidus, often in the deeper part, a neurosurgeon encounters the tiny fragile feeder vessels that are not amenable to the conventional method of coagulation. At this stage, we would apply the “dirty coagulation” technique. The basic idea of this technique is to use coagulum from the surrounding brain tissue with the vessel for stabilising bleeding. The “dirty coagulation” technique is executed through grabbing a small amount of tissue by bipolar tips and performing slow coagulation. This process takes some time, but if it is done too quickly the tiny feeders may shrink and retract back into the white matter. Thereby, the coagulum of tissue occludes the vessel lumen (Fig. 1). This helps to control bleeding and achieve permanent haemostasis.



**Fig. 1** Illustrations on the principle of the “dirty coagulation” technique to control deep arterial feeders using coagulum from the surrounding brain tissue with the vessel to achieve haemostasis

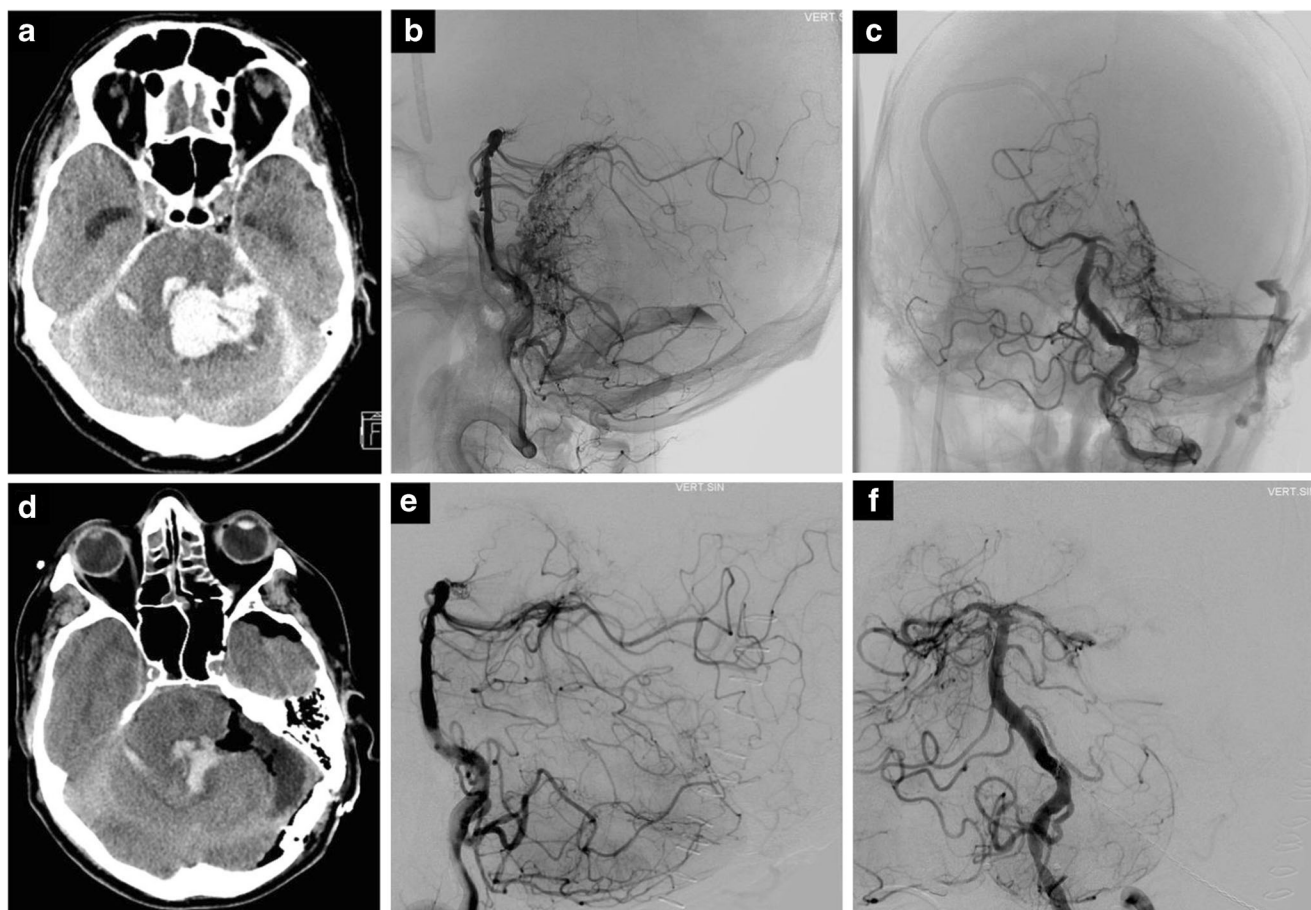
To perform this, we prefer the Malis bipolar system (Codman, Raynham, MA, USA), usually using blunt forceps, with 2.0-mm tips and a bipolar setting of 25; and occasionally sharp forceps with a bipolar setting of 15–20. Generally, the blunt bipolar forceps are less susceptible to sticking of the fragile feeder vessels in comparison to the sharp forceps. In our practice, we use regular bipolar forceps. The special features to prevent stickiness include using extremely clean and cold forceps. To achieve this, cold saline can be used to clean the forceps. Additionally, several pairs of similar forceps are available on the operating table, to increase operative efficacy by ensuring at least a pair of clean forceps are available at all times. The “dirty coagulation” is also executed in a gentle manner under extreme concentration to eliminate damaging the surrounding tissue.

### Some features of intraoperative and postoperative care

Generally, during AVM resections, we typically positioned the head 15–20 cm above the heart, ensuring no impairment of cerebral venous return. Mainly, semi-sitting or sitting positions are preferred, if feasible, according to localisation of the lesion. Systolic blood pressure (sBP) is maintained usually at the level of 100 mmHg. In some cases, when we encountered difficulties to coagulate the bleeding vessel, careful decrease of sBP to 60–70 mmHg for a short interval can help to achieve stable coagulation. This period can be prolonged up to 20–25 min if sBP is maintained around 80 mmHg. If during surgery we encountered a huge number of deep fragile vessels and dirty coagulation is heavily used, postoperatively such patients are maintained in a controlled moderate hypotensive state (100–120 mmHg) for several days. In selective cases, even deep arterial hypotension (80–100 mmHg) can be used in the postoperative period for the same reason.

## Results

The “dirty coagulation” technique was utilised in all 35 patients with SM III–V grade AVMs (*see* Video, Supplemental Digital Content 1 and Fig. 2). Patient characteristics, radiological features and postoperative bleeding in the resection bed are presented in the Table 1. Two patients had residual AVMs after the first operation. One patient with giant central SM grade-V AVM underwent four microneurosurgical operations and four embolisations [6]. Another patient with posterior midbrain SM grade-III AVM showed a small remnant in the postoperative period. This patient subsequently underwent radiosurgical treatment of the AVM remnant. No postoperative intracranial haemorrhage was encountered as a result of bleeding from the deep feeders. One patient with angiographically proven complete resection of SM grade-IV callosal AVM had postoperative subarachnoid haemorrhage due to



**Fig. 2** *Illustrative case 1.* **a** Computed tomographic (CT) brain scan showed a large posterior fossa haematoma with hydrocephalus as evidenced by the enlarged temporal horns of the lateral ventricles, **b** and **c** Digital subtraction angiography (DSA), revealed a large left posterior fossa AVM with superior cerebellar artery and pontine arterial feeders, and early venous drainage to the left sigmoid sinus. **d** CT brain showed a

well-decompressed posterior fossa, evacuation of the cerebellar haematoma with resolution of hydrocephalus. **e** and **f** DSA. Complete resection of the AVM was also achieved incorporating the “dirty coagulation” techniques to deal with small deep fragile feeders, and no AVM nidus or early venous drainage seen in the postoperative DSA

rupture of a proximal pericallosal aneurysm. Another patient, after removal of an SM grade-V giant frontal AVM, had thin bilateral subdural haematomas. This patient did not need reoperation and was treated conservatively. No operative mortality related to the described technique was encountered.

## Discussion

In selective cases, microsurgical resection of the AVM remains the “gold standard” treatment modality that offers immediate AVM obliteration and a high curative rate [8, 10, 13]. We believe that surgical management of AVM remains one of the most challenging operations for the neurosurgeons, particularly when intraoperative AVM ruptures [16]. Tome et al. [14] classified causes of intraoperative AVM rupture in three categories: torn feeders, nidus penetration and premature venous occlusion.

From the senior author’s experience, the torn feeders are the most difficult bleeding cause to control, particularly from the small fragile feeder vessels [3], and tamponade with small cotton balls is usually inadequate to control the bleeding. In many cases, these feeders arise from the deep part of the brain parenchyma and in close proximity to the ventricular systems [2]. Application of the “dirty coagulation” technique for small paraventricular vessels is difficult and usually ineffective as the ependymal layer fails to stabilise coagulation.

Morgan [7] proposed an elegant strategy of early access to the deep component of AVM to occlude the deep arterial feeders. When practical, this reduces the inflow to the nidus, and therefore circumferential spiral dissection of the AVM becomes less challenging as the nidus is softened. Alternatively, the large deep arterial feeders can also be occluded by endovascular methods to achieve the same purpose, and reduce the haemorrhagic risk of AVM surgery when resecting high-grade lesions. However, these techniques do not address the haemorrhagic risk from small tiny arterial



**Table 1** The characteristics and radiological features of 35 patients with AVMs of SM grades III–V with application of the “dirty coagulation” technique

Mean age (range), years	40.2 (11–68)
Males:females, <i>n</i>	22:13
Grades of AVMs, <i>n</i>	
III	14
IV	15
V	6
Ruptured:unruptured, <i>n</i>	14:21
Final-check angiogram (DSA, MRI, CT), <i>n</i>	
Complete occlusion	33
Residual	2 <sup>a</sup>
Postoperative haemorrhage in resection bed, <i>n</i>	0 <sup>b</sup>

<sup>a</sup> One patient underwent multistage treatment (published elsewhere); another patient, with posterior midbrain AVM, had a small residual and underwent radiosurgery

<sup>b</sup> One patient had postoperative bleed due to ruptured of an unrecognised pericallosal aneurysm; another patient showed bilateral thin subdural haematomas after resection of a giant AVM

feeder vessels. As a result, the management of tiny fragile feeding vessels at depth remained problematic.

Perinidal capillaries and tiny arterial feeders that surround the nidus have irregular elastic lamina [9]. Therefore, managing such vessels with direct bipolar coagulation is usually ineffective in stopping bleeding. Some authors proposed to control bleeding from these tiny fragile feeder vessels using microclips and microclips [1, 12]. However, employment of this technique is difficult. For example, in large AVM surgery, application of many microclips might impair the visualisation of the nidus margin and render further resection problematic. Potentially the clips can be displaced during manipulation and caused shearing of the fragile feeder vessels. In addition, the use of microclips might pose the long-term risk of clip migration as previously reported [1]. Additional to microclips, tiny balls of oxidised cellulose covered by cottonoids could be used to tamponade the bleeding point, and occasionally the cotton balls held in place using self-retracting brain retractors. Combination of various strategies might be required in selective cases. Sometimes lower-grade AVMs also have these tiny vessels. In our opinion, the “dirty coagulation” technique described here using bipolar coagulation is sufficient and effective in dealing with such problems of controlling bleeding from these tiny fragile feeders. These small feeders, if not handled appropriately, can lead to the most devastating complication of AVM surgery: postoperative haematoma that could cause high morbidity and mortality. The application of the “dirty coagulation” technique can also be employed for removal of highly vascularised tumours (for example, malignant gliomas). Despite the fact that we did not encounter haemorrhagic complications related to the application of “dirty coagulation” technique, our series is relatively small

and does not allow us to make an unambiguous statement about the effectiveness of the method. Perioperative bleeding complications after surgical treatment vary from 0 to 12.8% in different series [4, 5, 15]. As we analysed only cases with available high-definition quality videos, our series included only 35 cases that were performed during the last 5 years. Thereby, due to the relatively small number of cases in our series, we could not make a conclusion of a general nature about the bleeding risks. For comprehensive analysis, further investigation is needed.

This article describes the “dirty coagulation” technique in the microneurosurgical management of AVM and review of results of complex AVM resection by the senior author in the last 5 years proved its efficacy as no postoperative haematoma was encountered as a result of bleeding from the deep feeders.

## Conclusions

The “dirty coagulation” technique has proved to be reliable, effective and safe in dealing with the tiny fragile deep feeders, and thereby to achieve permanent haemostasis in complex AVM surgery.

**Acknowledgments** We would like to thank Yaroslava A. Kozyreva for the drawings in this article.

## Compliance with ethical standards

**Funding** No funding was received for this research.

**Conflict of interest** Professor Juha Hernesniemi is an Aesculap counsellor. All other authors certify that they have no affiliations with or involvement in any organisation or entity with any financial interest (such as honoraria; educational grants; participation in speakers’ bureaus; membership, employment, consultancies, stock ownership, or other equity interest; and expert testimony or patent-licensing arrangements), or non-financial interest (such as personal or professional relationships, affiliations, knowledge or beliefs) in the subject matter or materials discussed in this manuscript.

For this type of study formal consent is not required.

**Informed consent** Informed consent was obtained from all individual participants included in the study.

This article does not contain any studies with human participants performed by any of the authors.

## References

- Chen CC, Zinn PO, Kasper EM, Ogilvy CS (2010) Cranio-spinal migration of a metallic clip placed during arteriovenous malformation resection—a case report, review of the literature, and management strategies. *BMC Neurol* 10:109
- Du R, Keyoung HM, Dowd CF, Young WL, Lawton MT (2007) The effects of diffuseness and deep perforating artery supply on

- outcomes after microsurgical resection of brain arteriovenous malformations. *Neurosurgery* 60:638–646, discussion 646–638
3. Hernesniemi J, Romani R, Lehecka M, Isarakul P, Dashti R, Celik O, Navratil O, Niemela M, Laakso A (2010) Present state of microneurosurgery of cerebral arteriovenous malformations. *Acta Neurochir Suppl* 107:71–76
  4. Javadpour M, Al-Mahfoudh R, Mitchell PS, Kirillos R (2016) Outcome of microsurgical excision of unruptured brain arteriovenous malformations in ARUBA-eligible patients. *Br J Neurosurg* 30:619–622
  5. Korja M, Bervini D, Assaad N, Morgan MK (2014) Role of surgery in the management of brain arteriovenous malformations: prospective cohort study. *Stroke* 45:3549–3555
  6. Kozyrev DA, Jahromi BR, Hernesniemi J (2016) Total temporary occlusion of blood flow for several hours to treat a giant deep arteriovenous malformation: a series of multiple operations to save a young life. *Surg Neurol Int* 7:79
  7. Morgan MK (2014) Surgical strategies for Brain AVM. In: Misra BK, Laws ER, Kaye AH (eds) *Current progress in neurosurgery*. Three Life Media, Mumbai, pp 212–213
  8. Potts MB, Lau D, Abla AA, Kim H, Young WL, Lawton MT, Project UBAS (2015) Current surgical results with low-grade brain arteriovenous malformations. *J Neurosurg* 122:912–920
  9. Sato S, Kodama N, Sasaki T, Matsumoto M, Ishikawa T (2004) Perinidal dilated capillary networks in cerebral arteriovenous malformations. *Neurosurgery* 54:163–168, discussion 168–170
  10. Schramm J, Schaller K, Esche J, Bostrom A (2016) Microsurgery for cerebral arteriovenous malformations: subgroup outcomes in a consecutive series of 288 cases. *J Neurosurg*. doi:10.3171/2016.4.JNS153017
  11. Spetzler RF, Martin NA (1986) A proposed grading system for arteriovenous malformations. *J Neurosurg* 65:476–483
  12. Sundt TM Jr, Kees G Jr (1986) Miniclips and microclips for surgical hemostasis. Technical note. *J Neurosurg* 64:824–825
  13. Teo MK, Young AM, St George EJ (2016) Comparative surgical outcome associated with the management of brain arteriovenous malformation in a regional neurosurgical centre. *Br J Neurosurg* 1–8
  14. Torne R, Rodriguez-Hernandez A, Lawton MT (2014) Intraoperative arteriovenous malformation rupture: causes, management techniques, outcomes, and the effect of neurosurgeon experience. *Neurosurg Focus* 37:E12
  15. Wong J, Slomovic A, Ibrahim G, Radovanovic I, Tymianski M (2017) Microsurgery for ARUBA Trial (a randomized trial of unruptured brain arteriovenous malformation)—eligible unruptured brain arteriovenous malformations. *Stroke* 48:136–144
  16. Yaşargil MG (1988) *Microneurosurgery*, vol IIIB. Thieme, New York

Michael Kerin Morgan  
Australia

I think this is a helpful contribution because it shows the way to a very useful, albeit counterintuitive technique for coagulating tiny vessels. I have used this technique for decades and never bothered to write about it because it is so obviously the only technique that works in the deep white matter around AVMs. I am sure that this technique has been used by many other AVM surgeons also because it is a logical development. As it has been demonstrated, the intuitive decision to use fine-tipped forceps for fine vessels is wrong for fine vessels in the white matter around AVM, just as many other spontaneous intuitive decisions made by medical doctors.

Microclips are a good alternative method, but I can confirm many of the observations the authors have made: too many microclips soon turn out to be in the way when dealing with other small feeders. These difficult feeders in deep become more common the closer one is to the ependyma of the ventricle. The microclips produce short-cuts when bipolar is used close to them and they can shear off. This reviewer also confirms that the use of broader bipolar tips is very useful, because the current flow is not so focused as in finely tipped bipolar forceps. Thus, sticking to the coagulated vessel is less frequent when using broader tipped forceps. This somehow automatically leads to the technique that these authors have named “dirty coagulation”. A major part of the trick of “dirty coagulation” is to include some tissue around the vessel between the two forceps tips (as described) but also to use a not too high current and take some time with a low flow of electric current in order to allow the tissue to shrink slowly and desiccate slowly. The speed of shrinking and desiccation is an important feature, because if this happens too quickly these fragile feeders may tear 2–3 mm away from the coagulation forceps because they are torn away.

The apparently logical step of using very fine forceps and only enclosing the tiny vessel just does not work in the deep white matter around AVM. This reviewer has used blunt forceps 95% of the time during his own large AVM series [10]. The counterintuitive step of using broad-tipped forceps turns out to be more effective and better suited.

Johannes Schramm,  
Bonn, Germany

## Comments

This is a technique that Dr. Hernesniemi is known to have pioneered and promoted. When introduced it defied the conventional wisdom, at the time, of fine bipolar technique applied to the vessel with no collateral damage to be inflicted on surrounding tissue. However, for AVM this technique often fails for reasons presented in this paper and this “dirty coagulation” technique is necessary. It is important for those charged with the care of AVM to be aware of this technique and who first promoted its use. I have seen Dr. Hernesniemi use this and have adopted this technique, where appropriate, for my own AVM cases.