

<https://helda.helsinki.fi>

Treatment of Aneurysmal Bone Cysts with Bioactive Glass in Children

Syvänen, J.

2018-03

Syvänen , J , Nietosvaara , Y , Kohonen , I , Koskimies , E , Haara , M , Korhonen , J , Pajulo , O & Helenius , I 2018 , ' Treatment of Aneurysmal Bone Cysts with Bioactive Glass in Children ' , Scandinavian Journal of Surgery , vol. 107 , no. 1 , pp. 76-81 . <https://doi.org/10.1177/1457496917731185>

<http://hdl.handle.net/10138/234834>

<https://doi.org/10.1177/1457496917731185>

publishedVersion

Downloaded from Helda, University of Helsinki institutional repository.

This is an electronic reprint of the original article.

This reprint may differ from the original in pagination and typographic detail.

Please cite the original version.

TREATMENT OF ANEURYSMAL BONE CYSTS WITH BIOACTIVE GLASS IN CHILDREN

J. Syvänen¹, Y. Nietosvaara², I. Kohonen³, E. Koskimies¹, M. Haara², J. Korhonen⁴,
O. Pajulo¹, I. Helenius¹

¹ Department of Paediatric Orthopaedic Surgery, Turku University Hospital, Turku, Finland

² Department of Paediatric Orthopaedic Surgery, Helsinki University Hospital, Helsinki, Finland

³ Medical Imaging Centre of Southwest Finland, Turku University Hospital, Turku, Finland

⁴ Department of Paediatric Surgery, Oulu University Hospital, Oulu, Finland

ABSTRACT

Background and Aims: Aneurysmal bone cysts represent about 1% of primary bone tumors. The standard treatment is curettage, followed by local adjuvant treatments and bone grafting. The problem is the high recurrence rate. The purpose of this study was to evaluate retrospectively the use of bioactive glass as a filling material in the treatment of aneurysmal bone cysts in children.

Material and Methods: A total of 18 consecutive children (mean 11.3 years at surgery; 10 males; 11 lower, 6 upper limb, 1 pelvis; 15 with primary surgery) with histologically proven primary aneurysmal bone cysts operated with curettage and bioactive glass filling between 2008 and 2013 were evaluated after a mean follow-up of 2.0 years (range, 0.7–5.1 years).

Results: Two (11%) patients showed evidence of aneurysmal bone cyst recurrence and both have been re-operated for recurrence. Bone remodeling was noted in all patients with remaining growth and no growth plate disturbances were recorded. Two patients needed allogeneic blood transfusion. No intraoperative or postoperative complications were recorded.

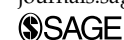
Conclusion: We conclude that bioactive glass is a suitable filling material for children with primary aneurysmal bone cyst. Bioactive glass did not affect bone growth and no side effects were reported.

Key words: Cyst; aneurysmal bone cyst; curettage; bone grafting; bioactive glass; recurrence

Correspondence:

Johanna Syvänen, M.D.
Department of Paediatric Orthopaedic Surgery
Turku University Hospital
Kiinamylynkatu 4-8
20521 Turku Finland
Email: johanna.syvanen@fimnet.fi

Scandinavian Journal of Surgery
2018, Vol. 107(1) 76–81
© The Finnish Surgical Society 2017
Reprints and permissions:
sagepub.co.uk/journalsPermissions.nav
DOI: 10.1177/1457496917731185
journals.sagepub.com/home/sjs



INTRODUCTION

Primary aneurysmal bone cyst (ABC) is a rare lesion with an incidence of 1.4 per 10⁵ individuals and represents about 1% of primary bone tumors (1). The standard treatment is to remove the lesion by curettage, followed by local adjuvant treatment and bone grafting. The rate of local recurrence has varied widely (2). Recurrences are more likely in younger children, with open growth plates and within the first 2 years postoperatively (3).

A number of adjunctive therapies are used to decrease the rate of recurrence. The local recurrence can be kept to a minimum if curettage is thorough and is performed with a high-speed burr (3). Phenol is a nonselective cytotoxic agent, which destroys the remaining residual tumor and normal cells (4) and has been used in the treatment of ABCs (5).

Bioactive glasses (BG) are bone bonding, osteoconductive bone substitutes with bone-stimulative and antibacterial and angiogenesis-promoting properties (6). Bioactive glass BG-S53P4 gained European approval as a bone graft substitute in 2006. BG-S53P4 has been reported to be safe and well-tolerated and suitable for benign bone tumor surgery with good long-term results in adults (6). In one case report of a 4-year-old girl with phalangeal ABC, BG-S53P4 did not disturb the growth of bone (7). BGs dissolve slowly and the graft area remodels to bone over time. This phenomenon may be beneficial, especially in the treatment of ABCs, which are prone to recur (7).

The aim of this study was to evaluate BG as a filling material in children's ABCs. We also aimed to describe the effect of BG on further growth and bone remodeling.

MATERIALS AND METHODS

After Institutional Review Board and Ethics committee approval, the patients with aneurysmal bone cyst were identified from three University Central Hospital databases. The medical records and radiographs of children presenting with a bone lesion treated with bioactive glass between 2008 and 2013 (40 cases) were reviewed retrospectively. Other than ABC lesions were excluded. We found 18 patients with histologically proven primary ABCs treated with curettage and bioactive glass filling.

Variables reviewed were date of birth, gender, age at presentation, pre- and postoperative imaging studies, the affected bone, cyst location versus physis, size of cyst, possible pathologic fracture, type and date of surgical procedure, the use of possible preoperative embolization or injection treatment, possible intraoperative adjuvant treatments, histology, recurrence, and other possible complications during treatment.

Preoperative and postoperative radiographs were available for all patients. In all, 17 of 18 patients had magnetic resonance imaging (MRI) of the lesion preoperatively; the remaining patient had computer tomography (CT) imaging. Three patients had both CT and MRI before treatment. Postoperatively, two patients had CT during follow-up and one patient had MRI and one both MRI and CT during follow-up to evaluate possible recurring cyst suspicion on plain radiographs. One of these patients was symptomatic (pain). The

volumes of the lesions on MR and CT images were measured using Aycan Workstation OsiriX^{PRO} (version 1.04; Wurzburg, Germany) (8). CT and MR images as well as radiographs were analyzed by radiologist with special experience and interest in musculoskeletal radiology. Cysts were classified according to Capanna's and Enneking's classification systems (9,10).

Four patients underwent biopsy before surgical treatment. In all, 11 patients had frozen section during surgery before filling the cavity with bioactive glass. In all patients, the final histologic examination confirmed the presence of an ABC.

The operation included curettage of the lesion with high-speed burr and filling the cavity with bioactive glass, BG-S53P4 (BonAlive Biomaterials Ltd). Phenol was used as a cytotoxic agent in 12 patients.

ETHICS

The study has Institutional Review Board (5 September 2012) and Ethics committee approval (19 June 2012).

RESULTS

The mean age at the time of surgery was 11.3 years (range, 4–16 years). There were 10 male patients (mean age of 10.8 years; range, 4–16 years) and 8 female patients (mean age, 11.9; range, 7–15 years). The mean follow-up was 2.0 years (range, 0.7–5.1 years) from the date of initial surgery. Eight ABCs were type 1 (44%) in Capanna's classification system, six were type 2 (33%), and four (22%) were type 3 cysts. Two of the cysts (11%) were inactive in Enneking's classification system, 12 (66%) were active, and four (22%) were aggressive lesions (Tables 1 and 2).

The locations of the cysts are shown in Table 1. The most commonly involved bone was femur (six cases). One patient had massive aneurysmal bone cyst of the pelvis (Fig. 1A to C). The lower limbs were involved more frequently (11 cases) than upper limbs (6 cases). Eight patients had a pathologic fracture before operation. Seven of these fractures had healed before surgery using conservative treatment. None of the patients underwent preoperative embolization. One patient had had sclerotherapy twice before operation.

Three patients had been operated previously for the cyst. In two patients, the index operation was a second and in one a third. In all three patients, allogeneic bone grafting had been used in previous operations.

Plate fixation was used in eight patients. Phenol was used in 12 patients. Bone autograft was applied in addition to bioactive glass in one patient with cuneiforme mediale and another with third metatarsal ABC. Two patients were given allogeneic red blood cell transfusion postoperatively. No perioperative complications were recorded.

In the study period, two patients developed a recurrent lesion (Tables 1 and 2):

1. Patient No. 1 was 16 years at the time of the operation. The index operation was the third for the aneurysmal bone cyst in the proximal femur. Phenol was used as adjunctive therapy. The presenting symptom was pain. A recurrence was

TABLE 1
Patients with aneurysmal cyst filled with bioactive glass.

Patient	Age	Primary/ secondary operation	Cyst's location	Size (cm ³)	Distance from physis	Enneking classification	Capanna classification	Pathologic fracture yes/no/ healed +/-	Phenolization +/-	Osteosynthesis +/-
1	16	Secondary (third operation)	Femur, collum	26.769	Physis closed	2	1	No	+	+
2	15	Primary	Femur, collum	1.6706	Physis closed	1	3	No	-	+
3	12	Primary	Femur, collum	8.449	6 mm from caput, 3 mm from trochanter	2	1	Yes/+	+	+
4	11	Primary	Proximal ulna	22.435	-	3	2	No	+	+
5	11	Primary	Proximal fibula	3.096	19 mm	2	2	No	-	-
6	13	Primary	Calcaneus	8.222	11 mm	2	1	No	-	-
7	7	Primary	Proximal ulna	3.832	19 mm	2	1	Yes/+	+	+
8	13	Primary	Femur, collum	4.6203	0 mm	1	3	No	+	+
9	11	Primary	Proximal humerus	25.23	0 mm, cyst also in epiphysis	3	2	Yes/+	+	+
10	10	Secondary	Proximal humerus	18.055	3 mm	2	1	No	+	-
11	10	Primary	Proximal diaphysis humerus	39.607	0 mm	2	2	Yes/+	-	-
12	13	Primary	Pelvis	70.937	Physis closed	2	3	No	+	-
13	9	Primary	III metatarsal diaphysis	2.059	0 mm	2	2	Yes/+	-	-
14	15	Primary	Distal tibia	5.978	5 mm	2	1	Yes/+	+	-
15	15	Primary	Med. cuneiforme	7.811		3	2	No	+	-
16	11	Primary	Femur diaphysis	27.951	59 mm from collum femoris	2	2	Yes/-	+	+
17	4	Secondary	Distal femur	7.287	2.7 mm	2	3	No	+	-
18	7	Primary	Fifth metacarpal	3.202	0 mm	2	2	Yes/+	-	-

TABLE 2
Patients with aneurysmatic cyst and complications.

Patient	Complication in surgery +/-	Hospital days	Follow-up (years)	Complications during follow-up	Residue size (cm ³)
1	-		5.1	I Residue/residual, 1 year 2 months after operation, new operation (BG + phenol + pediatric hip plate) II Residue 3 years 4 months after operation, aethoxysklerol	1.920 (I) 1.899 (II)
2	-	6	2.4	-	
3	-	5	3.0	-	
4	-	1	1.4	-	
5	-	3	1.6	-	
6	-	1	1.4	-	
7	-	2	4.7	-	
8	-	6	1.0	-	
9	-	2	1.6	-	
10	-	1	0.7	-	
11	-	2	2.0	-	
12	Bleeding	6	2.0	-	
13	-	1	1.2	Block from crista, bioactive glass around it, stress fracture 7 months after operation	
14	-	3	2.9	-	
15	-	1	1.4	Block from crista, bioactive glass around it. During follow-up arthrosis between cuneiforme bones and tarsometatarsal I and II. Medial cuneiforme sclerotic and deform. Patient asymptomatic	
16	Bleeding, possible not enough curettage	8	0.8	Possible residual 4 months postoperatively in X-ray. Later area fulfilled	
17	-	2	1.2	In first operation, cyst was filled with allograft, 8 months postoperatively residue, filled with bioactive glass, II residue/residual in MRI 8 months postoperatively	6.5385/0.4474
18	-	2	1.4	Sclerotherapy twice before bioactive glass filling. Minimal residual after operation, not expansive in follow-up	

suspected on plain radiographs and confirmed with MR and CT imaging.

- Patient No. 17 was a 4-year-old boy who had revision surgery after filling with allograft. MR images confirmed the recurrence. When allograft was used, the curettage was not total because the cyst grew to the distal femur physis.

Both patients had active lesions according to Enneking's classification system. Patient No. 1 had type 1 lesion in Capanna's classification system and patient No. 17 had type 3 lesion.

There were no side effects to BG reported in patient's files. All 14 patients with open growth plates continued to grow normally without any disturbances. Additionally, these patients showed bone remodeling with increased density on radiographs in the operation area. In all patients, some ill-defined glass granules were still visible among new bone at the end of follow-up.

DISCUSSION

ABC's origin is controversial. Over the past few years, many different genetic translocations have been described in ABC, all resulting in oncogenic activation of the USP6 gene. USP6 is an ubiquitin-specific protease that was identified as an oncogene in transfection experiments with Ewing sarcoma DNA. Recently,

structurally similar *USP6* fusion genes were identified in both ABC and nodular fasciitis. This suggests that these conditions are clonal neoplastic disorders that may belong to the same biologic spectrum (11).

Because of ABC's controversial origin, no universal treatment method has been adopted. Opinion varies as to which method should be used, especially in children. Only few pediatric studies exist, the biggest ones being the study of Dormans et al. (5) and Ramirez and Stanton (12). To the best of the authors' knowledge, there is only one case report using BG to treat a recurrent ABC in a child (7).

En-bloc resection is not a common procedure and must be considered only when there is no other alternative (2). Intralesional excision with bone grafting is usually the standard cure. However, curettage with or without bone grafting has been associated with high recurrence rates (2, 13, 14).

A number of adjunctive therapies are used to decrease the rate of recurrence (5, 15, 16). Varshney et al. (17) analyzed the literature regarding the treatment of ABCs, founding recurrence rate of approximately 29.2% when curettage and bone grafting are used. This decreased to 15.4% using high-speed burr (3, 5, 17).

Sclerotherapy is a newer treatment method. An alcoholic solution of zein (Ethibloc) has been used with good healing rates (18). Polidocanol has been used as a sclerosant with 3% recurrence rate (19). It is

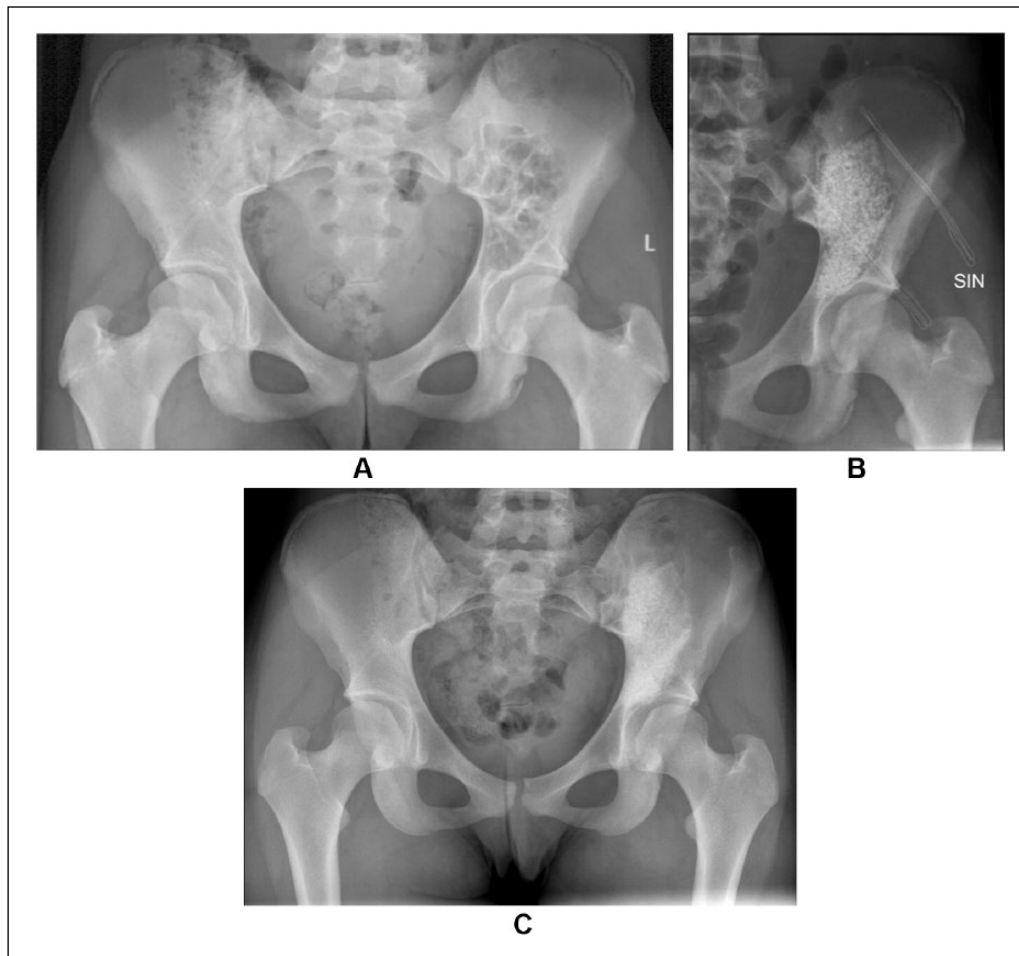


Fig. 1. A) Preoperative radiograph from the patient who had massive aneurysmatic bone cyst of the pelvis. B) Immediate radiograph after curettage and bioactive glass filling. C) Three years from the curettage and bioactive glass filling.

reported that repetitive sclerotherapy is safer method than intralesional excision and bone grafting with similar recurrence rates (17). However, there are also problems with this treatment method. Complications (pulmonary embolism, aseptic fistulae, infection, osteomyelitis, and abscess) have been reported in the literature (18, 20). Fatal brain stem and cerebellar infarction have also been described (21). Repetitive injections are usually needed and general anesthesia is required for children (17, 22). Brosjö et al. (22) found no growth disturbances in their series. When there is large ABC in weight-bearing bone, it is impossible to stabilize the bone to reduce the risk of pathologic fracture when using sclerotherapy as a sole treatment method. Therefore, the current authors would not use sclerotherapy as a sole treatment in high risk locations for pathological fractures such as proximal femoral area. In our study, internal fixation was commonly used for large cysts, especially in lower extremities, to prevent early pathologic fractures and to allow early weight bearing and motion.

Selective arterial embolization of the nutrient vessels is an alternative method in difficult locations such as spine and pelvis. Ischemia to neural and vital structures remains the main concern (15). In spine repeated

embolization, when feasible, can be considered the first treatment option (23, 24), but this leads into high radiation doses.

Recurrence rates after curettage vary widely from 9% (5) to 71% (25). In a literature review, the recurrence rate of the 690 ABCs treated with curettage with or without bone graft was 31% (2). In our small series of 18 patients treated with bioactive glass, two patients developed recurrence (11%). Both were male and had active and large lesions nearby growth plates of the proximal and distal femur, respectively, and previously surgically treated using allograft bone. Additionally, phenol as an adjuvant had not been used in the first patient. Because of the retrospective nature of this study, there was no routine schema for radiographic controls. The potential recurrences were evaluated from plain radiographs. When recurrence was suspected, MR imaging was done (also CT in one patient). Only four patients had MR or CT imaging postoperatively. Patients with recurrent cysts had active cyst in Enneking's classification and type 1 and 3 lesions in Capanna's classification.

In our series, there were no growth arrests when evaluating the growth plate on radiographs. Other

studies have reported growth problems (4%/12.5%/14.3%) (15, 17, 26). Physeal growth arrest appears to be related more to the location of the cyst and surgical technique than the filling material itself and the role of filling material in this respect is not clearly known. Juxtaphyseal ABC involvement has been reported to have growth disturbance in 55% following surgical treatment (27, 28). Appositional growth seems not to be affected by filling using bioactive glass (7). All patients in our study showed bone remodeling with dense, more sclerotic appearance in the operation area. However, limitation is that we made remodeling observations only on radiographs which may lead to an impression of a more sclerotic area than it actually is (6).

Bioactive glass proved to be a safe filling material of bone cavity after curettage of primary ABC. Its resistance to mechanical compression might be beneficial in cases of recurrent ABC. These properties may limit the expansion of the lesion as all our recurrences were small. In previous studies, the size of the recurrence has not been studied. Bioactive glass also allowed bone remodeling in all patients with remaining growth and did not disturb further growth even in small children. In conclusion, bioactive glass is a suitable filling material for children with primary ABC. Bioactive glass did not affect bone growth and no side effects were reported. The recurrence rate of primary ABC after operation appears acceptable.

DECLARATION OF CONFLICTING INTERESTS

I.H. has received research grants from Medtronic, Bonalive, and Baxter Healthcare Corporation and is a consultant in Medtronic. Other authors received no financial support for the research, authorship, and/or publication of this article.

ETHICAL APPROVAL

The study has Institutional Review Board (5 September 2012) and Ethics committee approval (19 June 2012).

FUNDING

J.S. has been supported by the Turku University Central Hospital Foundation and the Finnish Paediatric Research Foundation. J.S. is a Research Fellow, O.P. is a Member, and I.H. is a leader of the Finnish Pediatric Orthopaedic Study Group, which has received funding from the Finnish Pediatric Research Foundation, Baxter, Bonalive, and Medtronic International.

REFERENCES

- Leithner A, Windhager R, Lang S et al: Aneurysmal bone cyst. A population based epidemiologic study and literature review. *Clin Orthop Relat Res* 1999;363:176–179.
- Cottalorda J, Bourelle S: Current treatments of primary aneurysmal bone cysts. *J Pediatr Orthop B* 2006;15:155–167.
- Gibbs CP Jr, Hefele MC, Peabody TD et al: Aneurysmal bone cyst of the extremities. Factors related to local recurrence after curettage with a high-speed burr. *J Bone Joint Surg Am* 1999;81:1671–1678.
- Capanna R, Sudanese A, Baldini N et al: Phenol as an adjuvant in the control of local recurrence of benign neoplasms of bone treated by curettage. *Ital J Orthop Traumatol* 1985;11:381–388.

- Dormans JP, Hanna BG, Johnston DR et al: Surgical treatment and recurrence rate of aneurysmal bone cysts in children. *Clin Orthop Relat Res* 2004;421:205–211.
- Lindfors NC, Koski I, Heikkilä JT et al: A prospective randomized 14 year follow-up study of bioactive glass and autogenous bone as bone graft substitutes in benign bone tumors. *J Biomed Mater Res B Appl Biomater* 2010;94:157–164.
- Lindfors NC: Treatment of a recurrent aneurysmal bone cyst with bioactive glass in a child allows for good bone remodelling and growth. *Bone* 2009;45:398–400.
- Rosset A, Spadola L, Ratib O: OsiriX: An open-source software for navigating in multidimensional DICOM images. *J Digit Imaging* 2004;17:205–216.
- Capanna R, Bettelli G, Biagini R et al: Aneurysmal cysts of long bones. *Ital J Orthop Traumatol* 1985;11:409–417.
- Enneking WF: A system of staging musculoskeletal neoplasms. *Clin Orthop Relat Res* 1986;204:9–24.
- Oliveira AM, Chou MM: USP6-induced neoplasms: The biologic spectrum of aneurysmal bone cyst and nodular fasciitis. *Hum Pathol* 2014;45:1–11.
- Ramirez AR, Stanton RP: Aneurysmal bone cyst in 29 children. *J Pediatr Orthop* 2002;22:533–539.
- Vergel de Dios AM, Bond JR, Shives TC et al: Aneurysmal bone cyst. A clinicopathologic study of 238 cases. *Cancer* 1992;69:2921–2931.
- Marcove RC, Sheth DS, Takemoto S et al: The treatment of aneurysmal bone cyst. *Clin Orthop Relat Res* 1995;311:157–163.
- Green JA, Bellemore MC, Marsden FW: Embolization in the treatment of aneurysmal bone cysts. *J Pediatr Orthop* 1997;17:440–443.
- Ozaki T, Hillmann A, Lindner N et al: Cementation of primary aneurysmal bone cysts. *Clin Orthop Relat Res* 1997;337:240–248.
- Varshney MK, Rastogi S, Khan SA et al: Is sclerotherapy better than intralesional excision for treating aneurysmal bone cysts? *Clin Orthop Relat Res* 2010;468:1649–1659.
- Adamsbaum C, Mascard E, Guinebretière JM et al: Intralesional ethibloc injections in primary aneurysmal bone cysts: An efficient and safe treatment. *Skeletal Radiol* 2000;32:559–566.
- Rastogi S, Varshney MK, Tripathi V et al: Treatment of aneurysmal bone cysts with percutaneous sclerotherapy using polidocanol. A review of 72 cases with long-term follow-up. *J Bone Joint Surg Br* 2006;88:1212–1216.
- Topouchian V, Mazda K, Hamze B et al: Aneurysmal bone cysts in children: Complications of fibrosing agent injection. *Radiology* 2004;232:522–526.
- Peraud A, Drake JM, Armstrong D et al: Fatal ethibloc embolization of vertebrobasilar system following percutaneous injection into aneurysmal bone cyst of the second cervical vertebra. *AJNR Am J Neuroradiol* 2004;25:1116–1120.
- Brosjö O, Pechon P, Hesla A et al: Sclerotherapy with polidocanol for treatment of aneurysmal bone cysts. *Acta Orthop* 2013;84:502–505.
- Amendola L, Simonetti L, Simoes CE et al: Aneurysmal bone cyst of the mobile spine: The therapeutic role of embolization. *Eur Spine J* 2013;22:533–541.
- Boriani S, De Lure F, Campanacci L et al: Aneurysmal bone cyst of the mobile spine: Report on 41 cases. *Spine* 2001;26:27–35.
- Freiberg AA, Loder RT, Heidelberger KP et al: Aneurysmal bone cysts in young children. *J Pediatr Orthop* 1994;14:86–91.
- Lampasi M, Magnani M, Donzelli O: Aneurysmal bone cysts of the distal fibula in children: Long-term results of curettage and resection in nine patients. *J Bone Joint Surg Br* 2007;89:1356–1362.
- Capanna R, Springfield DS, Biagini R et al: Juxtaepiphyseal aneurysmal bone cyst. *Skeletal Radiol* 1985;13:21–25.
- Shiels WE II, Beebe AC, Mayerson JL: Percutaneous doxycycline treatment of juxtaphyseal aneurysmal bone cysts. *J Pediatr Orthop* 2016;36:205–212.

Received: September 23, 2016

Accepted: August 8, 2017