

BIODEGRADABLE SELF-REINFORCED POLYGLYCOLIC ACID SPIRAL STENT IN PREVENTION OF POSTOPERATIVE URINARY RETENTION AFTER VISUAL LASER ABLATION OF THE PROSTATE-LASER PROSTATECTOMY

MARTTI TALJA, TEUVO TAMMELA, ANSSI PETAS, TERO VÄLIMAA, KIMMO TAARI,
ESA VIHHERKOSKI AND PERTTI TÖRMÄLÄ

From the Department of Surgery, Päijät-Häme Central Hospital, Lahti, Division of Urology, Tampere University Hospital, Department of Clinical Medicine, University of Tampere and Institute of Plastics Technology, Tampere University of Technology, Tampere, and Department of Urology, Helsinki University Central Hospital and Institute of Industrial Management, Helsinki University of Technology, Helsinki, Finland

ABSTRACT

Purpose: The efficacy and safety of a new biodegradable (self-reinforced polyglycolic acid) spiral stent in securing free voiding despite edema after visual laser ablation of the prostate were studied.

Materials and Methods: A biodegradable spiral stent was inserted into the prostatic urethra in 22 patients immediately after visual laser ablation of the prostate. Uroflowmetry, measurement of residual urine volume, urine culture, cystoscopy and assessment of symptomatic improvement were done before, and 1, 3 and 6 months after visual laser ablation of the prostate.

Results: All 22 patients voided freely on day 1 or 2 after visual laser ablation of the prostate. However, 4 patients later had urinary retention due to a short spiral or too rapid spiral degradation. Half of the patients experienced a transient decrease in flow with some obstructive symptoms at 3 weeks that lasted 1 to 2 weeks. At 4 weeks all spirals were degraded and 3 patients had a positive urine culture. The maximum flow rate increased and the residual urine volume decreased significantly concomitantly with significant symptomatic improvement.

Conclusions: The self-reinforced polyglycolic acid spiral stent can effectively and safely prevent postoperative urinary retention after visual laser ablation of the prostate.

KEY WORDS: prostate, prostatic hypertrophy, therapy, urinary catheterization

Benign prostatic hypertrophy (BPH) is one of the most common diseases in men. According to Garraway et al, 25% of men 40 to 79 years old have BPH induced urinary dysfunction involving a decreased flow rate (less than 15 ml. per second) and increased prostatic weight (more than 20 gm.).¹ For more than 50 years the gold standard of surgical therapy for this disease has been transurethral electroresection of the prostate. However, this procedure requires much experience and still the immediate postoperative morbidity rate has been reported to be as high as 18% with a perioperative mortality rate of 0.2%.²

Visual laser ablation of the prostate is a recently introduced, less demanding therapy for BPH that was first performed by Johnson et al with favorable results in dogs.³ Costello et al described the first experiences in humans.⁴ Visual laser ablation of the prostate is based on photothermal coagulation of the prostate tissue with a neodymium:YAG laser and a right-angle side-firing delivery system. There are still several problems associated with visual laser ablation of the prostate, including postoperative urinary retention due to burn edema and requiring prolonged urinary catheterization in up to 40% of the patients.⁵

In the early 1980s Fabian introduced a urological spiral stent to keep the enlarged prostatic lobes from compressing the urethra, thus allowing for spontaneous voiding.⁶ Several investigators have reported good results with similar spirals for transient or definitive therapy of prostatic obstruction.^{7,8} In the early 1980s, ultra-high strength, self-reinforced, biodegradable, polymeric composites were developed for tissue management.⁹ Self-reinforced poly-L-lactide spirals were shown to have good biocompatibility in the anterior ure-

thra.¹⁰ Self-reinforced biodegradable polyglycolic acid and polylactic acid rods have also been used for 10 years for the fixation of bone fractures with favorable results.¹¹ We investigated the efficacy and safety of biodegradable self-reinforced polyglycolic acid spiral stents in the prevention of urinary retention after visual laser ablation of the prostate.

MATERIALS AND METHODS

Self-reinforced polyglycolic acid spiral stent. The spiral stents were manufactured of polyglycolic acid wires by extrusion and die-drawing,⁹ with a wire diameter of 1.1 mm. and a draw ratio of 4. In configuration, the urospring resembled that of the stent described by Fabian. The spiral was 8 mm. in diameter and the prostatic portion was 45 mm. long (fig. 1). While stored in phosphate buffer solution (pH 6.1) at 37C in vitro, the spirals maintained their configuration but the wire tended to straighten so that the outer diameter increased 64% during incubation for 14 days. The material is biocompatible and in vitro it degrades into glycolic acid, mainly by hydrolysis.¹² Some enzymes have been found to accelerate degradation.^{13,14} The mechanical properties of polyglycolic acid and the degradation time depend on the degree of polymerization, internal arrangement of the mate-



FIG. 1. Spiral stent made of 1.1 mm. self-reinforced polyglycolic acid wire. Outer diameter is 8 mm., prostatic portion is 45 mm. long and total length is 75 mm.

Accepted for publication June 9, 1995.

rial components, site of implantation and shape of the implant.^{15, 16}

Patients and followup procedures. The series consisted of 22 patients 55 to 81 years old (mean age 68.5 years) with symptomatic BPH. Peak urinary flow rate was less than 15 ml. per second with a voided volume of more than 150 ml. Three patients had urinary retention. Ultrasound-guided biopsies were obtained if the serum prostate specific antigen (PSA) concentration was greater than 4.0 $\mu\text{g./l.}$, digital rectal examination was abnormal or transrectal ultrasound revealed an abnormality. Mean prostatic volume was 43 cc (range 26 to 92).

Followup studies consisted of uroflowmetry; ultrasonic estimation of post-void residual urine volume; analysis of serum creatinine, c-reactive protein and urine culture; a patient weighted symptom score questionnaire (DAN-PSS-1, including sexual scoring),¹⁷ and urethroscopy. The studies were performed preoperatively and at 4 weeks, 3 months and 6 months following visual laser ablation of the prostate. At 6 months transrectal ultrasound examination of the prostate was also performed.

Visual laser ablation of the prostate and application of the self-reinforced polyglycolic acid spiral stent. A standard technique for visual laser ablation of the prostate was used. The bladder was filled with saline during cystoscopy and a 12 Ch. suprapubic balloon catheter was inserted. The catheter was connected to a suction machine to promote bladder emptying during laser therapy. Visual laser ablation of the prostate was performed with a 600 $\mu\text{m.}$ polytetrafluorethylene (Teflon) coated laser fiber with a side-firing tip. Continuous irrigation with 37C saline cooled the laser fiber tip and kept the prostatic lobes apart. Standard laser safety precautions were applied in the operating room in all cases.

Neodymium:YAG generators were used to deliver photothermal energy. The power setting was 40 watts in a continuous wave mode. The lasing time was 90 seconds for the lateral lobes and 45 seconds for the median lobe. Laser energy was delivered to the lateral lobes in 4 quadrants circumferentially at the 2, 4, 8 and 10 o'clock positions, and in 2 planes when the prostatic urethra was longer than 2.5 cm. Extra laser sites were used, if necessary, to ensure complete treatment of the adenoma tissue.

After removal of the laser fiber, a 3 to 5 Ch. ureteral catheter was inserted through the cystoscope into the bladder and the cystoscope was removed. Using the tip of the cystoscope, a self-reinforced polyglycolic acid spiral stent was pushed into the prostatic urethra along the ureteral catheter, which functioned as a guide wire. The correct location of the spiral was verified endoscopically. The patient was allowed to void immediately or on postoperative day 1. When the patient was able to urinate freely, the suprapubic catheter was removed and the patient was discharged from the hospital.

Statistics. The paired t test was used to evaluate differences among the time points. A p value <0.05 was considered statistically significant.

RESULTS

All patients completed the 6-month followup. Median dose of laser energy used was 656 J/cc (range 273 to 1,083). All

patients voided freely on postoperative day 1 or 2 (3 patients). Four patients experienced late retention due to early degradation of the spiral at 3 or 4 weeks postoperatively (2) or insufficient spiral length (2). Transurethral electroresection of the prostate was required in 1 of the latter patients.

The peak urinary flow rates increased highly significantly during the 6-month followup (p <0.002, see table). Also, post-void residual urine decreased highly significantly (p <0.001). The patient weighted prostatic symptom score decreased significantly at 3 and 6 months (p <0.001, fig. 2). There was no significant change in the sexual symptom score. On ultrasound prostatic size decreased by 24% during 6 months.

The patients stated that voiding was unobstructed during the first 3 weeks postoperatively. Thereafter, half of the patients believed that the force of the stream diminished and that the obstructive symptoms increased for some weeks. This deterioration in symptoms fits well with the degradation time of the polyglycolic acid spiral stent as evaluated by urethroscopy. At 4 weeks few patients still had some spiral fragments in the posterior urethra. No foreign bodies or urinary stones were noted in the bladder at 3 months.

The entire prostatic urethra was lined with necrotic tissue 4 weeks postoperatively in all patients. At 3 months half of the prostatic surface was still covered with white necrotic tissue. A third of the patients had a few small necrotic areas in the prostatic urethra at 6 months after visual laser ablation of the prostate.

No blood transfusions were required. A urine culture was positive 4 weeks postoperatively in 3 patients and remained positive at 3 months in 1. Five patients experienced prolonged irritative symptoms 3 months postoperatively. The symptoms diminished or ceased along with epithelialization of the prostatic urethra.

DISCUSSION

During visual laser ablation of the prostate tissue necrosis is caused by converting light energy into thermal energy. After laser therapy there is acute tissue swelling due to burn edema. Because the surgical capsule of the prostate prevents its peripheral enlargement, the edema tends to obstruct the prostatic urethra and cause transient urinary retention. This retention is conventionally prevented by use of an indwelling urinary catheter. There is no consensus as to when the catheter should be removed. Intervals of 24 hours to 7 days have been recommended.^{5, 18, 19} Prolonged indwelling or suprapubic catheterization after visual laser ablation of the prostate is inconvenient for the patient. The catheter also provides a route for bacterial infection of the bladder.²⁰ Bacterial contamination of the necrotic prostatic tissue may even lead to prolonged urinary infection. The incidence of postoperative urinary infections after visual laser ablation of the prostate is poorly documented. Nevertheless, infection rates of up to 30% after laser prostatectomy have been reported,^{21, 22} which is higher than our infection rate.

We introduced a new mechanical device, the spiral stent, with which urinary retention after visual laser ablation of the prostate can be prevented without side effects. There is no need to remove the device later because the spiral stent

Peak urinary flow rate (flow) and post-void residual urine volume during followup

	Preop.	Mean (range)		
		1 Mo.	3 Mos.	6 Mos.
Flow (ml./sec.):	8.1 (2.8-12.9)	9.6 (1.7-17.6)	13.6 (7.0-22.1)	14.1 (5.3-30.9)
p Value*		Not significant	<0.002	<0.002
Post-void residual vol. (ml.):	176 (10-490)	106 (6-300)	55 (10-380)	75 (15-400)
p Value*		<0.05	<0.001	<0.001

* Significance of differences from the preoperative value.

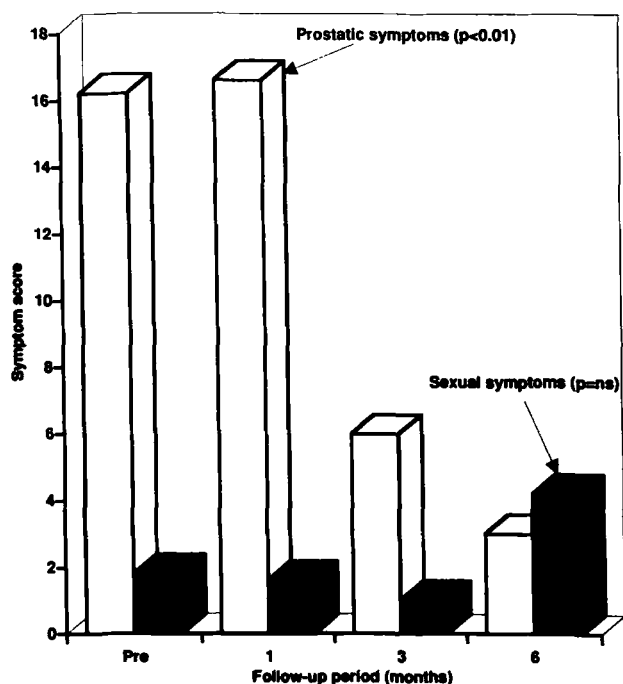


FIG. 2. Mean patient weighted symptom scores. Prostatic and sexual scores are presented separately. *p* Values indicate significance of differences at 3 and 6 months from preoperative (Pre) value. *ns*, not significant.

degrades into small fragments of polymer debris that are excreted with urine. In practice, most of our patients did not notice the softened debris in the urine. If polymer fragments remain in the bladder, they will degrade completely within a few weeks without stone formation. Self-reinforced polyglycolic acid rods have been used for 10 years to fix bone fractures with favorable results.^{23,24} In previous experimental studies, we have shown that biodegradable materials are biocompatible in the anterior urethra. Spirals made of self-reinforced polylactic acid induced less incrustation and inflammation in the urethra than did stainless steel spirals.¹⁰

Half of our patients noticed that voiding became more obstructed at 3 weeks postoperatively, which was probably due to degradation and sloughing of the spiral stent. At that time also, edema and necrotic debris still obstructed the prostatic urethra. The obstructive symptoms then gradually diminished within 1 to 2 weeks and urinary flow improved so that after 3 months there was no further increase in peak flow rate. The transient voiding problem might be avoided by using spiral stents with a longer degradation time. It is feasible to prolong degradation for up to 10 months by selecting more slowly degrading molecules.

The outcome of visual laser ablation of the prostate in our study was in line with the results reported by others.^{5,18,19} Overall, the decrease in voiding symptoms was highly significant. The patient weighted symptom score system¹⁷ was used in our study, since it includes a bother score in addition to the symptom score and, therefore, is considered to provide a more reliable estimate of symptoms than other score systems.²⁵ Although the changes in uroflowmetry and residual urine volume were similar to those reported previously,^{18,19} there was marked variation among the patients, which may have been due to the fact that the study group had little previous experience with visual laser ablation of the prostate. Other explanations may be the great variation in the energy used per cc of prostatic tissue and that the energy level was lower than that used by others.^{4,19} Prostatic tissue

energy levels up to 1,000 J/cc are recommended. Cystoscopic examination at 6 months showed the remains of adenoma in several patients.

Although visual laser ablation of the prostate offers some advantages over transurethral electroresection of the prostate, including a faster and safer procedure as well as a shorter hospitalization period, the burn-like edema produced after lasing means that a catheter or other device is required to prevent acute urinary retention. The biodegradable self-reinforced polyglycolic acid spiral stent is a new means to avoid urinary retention after visual laser ablation of the prostate. Further controlled studies are needed to compare the spiral stent to other methods of preventing urinary retention after lasing. Biodegradable spiral stents may also be used to prevent urinary retention after other BPH therapies that may induce edema, such as transurethral microwave therapy, transurethral needle ablation of the prostate, high intensity focused ultrasound, interstitial laser coagulation of the prostate and cryotherapy, as well as in the provisional treatment of patients with urinary retention who are awaiting surgery. These topics will be addressed in subsequent studies.

REFERENCES

- Garraway, W. M., Collins, G. N. and Lee, R. J.: High prevalence of benign prostatic hypertrophy in the community. *Lancet*, **338**: 469, 1991.
- Mebust, W. K., Holtgrewe, H. L., Cockett, A. T. K. and Peters, P. C.: Transurethral prostatectomy: immediate and postoperative complications. A cooperative study of 13 participating institutions in evaluating 3,885 patients. *J. Urol.*, **141**: 243, 1989.
- Johnson, D. E., Levinson, K. A., Greskovich, F. J., Cromeens, D. M., Ro, J. Y., Costello, A. J. and Wishnow, K. I.: Transurethral laser prostatectomy using a right-angle laser delivery system. *Lasers Urol. Laparosc. Gen. Surg.*, **1421**: 36, 1991.
- Costello, A. J., Bowsher, W. G., Bolton, D. M., Braslis, K. G. and Burt, J.: Laser ablation of the prostate in patients with benign prostatic hypertrophy. *Brit. J. Urol.*, **69**: 603, 1992.
- Norris, J. P., Norris, D. M., Lee, R. D. and Rubenstein, M. A.: Visual laser ablation of the prostate: clinical experience in 108 patients. *J. Urol.*, part 2, **150**: 1612, 1993.
- Fabian, K. M.: Der intraprostatiche "partielle katheter" (urologische Spirale). *Urologe A*, **19**: 236, 1980.
- Nordling, J., Holm, H. H., Klarskov, P., Nielsen, K. K. and Andersen, J. T.: The intraprostatic spiral: a new device for insertion with the patient under local anesthesia and with ultrasonic guidance with 3 months of followup. *J. Urol.*, **142**: 756, 1989.
- Ala-Opas, M., Talja, M., Tütinen, J., Hellström, P., Heikkinen, A. and Nurmi, M.: Prostatakth in urinary outflow obstruction. *Ann. Chir. Gynec.*, suppl., **206**: 14, 1993.
- Törmälä, P.: Biodegradable self-reinforced composite materials; manufacturing structure and mechanical properties. *Clin. Mater.*, **10**: 29, 1992.
- Kemppainen, E., Talja, M., Riihelä, M., Pohjonen, T., Törmälä, P. and Alftan, O.: A bioresorbable urethral stent. An experimental study. *Urol. Res.*, **21**: 235, 1993.
- Rokkanen, P., Böstman, O., Hirvensalo, E., Partio, E., Vihtonen, K., Vainionpää, S., Mäkelä, A. and Törmälä, P.: The use of absorbable internal fracture fixation devices. *Adv. Biomater.*, **10**: 447, 1992.
- Chu, C. C.: Hydrolytic degradation of polyglycolic acid: tensile strength and crystallinity study. *J. Appl. Polym. Sci.*, **28**: 1727, 1981.
- Williams, D. F. and Mort, E.: Enzyme-accelerated hydrolysis of polyglycolic acid. *J. Bioeng.*, **1**: 231, 1977.
- Chu, C. C. and Williams, D. F.: The effect of gamma irradiation on the enzymatic degradation of polyglycolic acid absorbable sutures. *J. Biomed. Mater. Res.*, **17**: 1029, 1983.
- Vert, M., Li, S. and Garreau, H.: New insights on the degradation of bioresorbable polymeric devices based on lactic and glycolic acids. *Clin. Mater.*, **10**: 29, 1992.
- Chu, C. C.: Differential scanning calorimetric study of the crystallization kinetics of polyglycolic acid at high undercooling.

- Polymer, **20**: 1480, 1980.
17. Meyhoff, H. H., Hald, T., Nordling, J., Andersen, J. T., Bilde, T. and Walter, S.: A new patient weighed symptom score system (DAN-PSS-1). Clinical assessment of indications and outcomes of transurethral prostatectomy for uncomplicated benign prostatic hyperplasia. *Scand. J. Urol. Nephrol.*, **27**: 493, 1993.
 18. Kabalin, J. N.: Laser prostatectomy performed with a right angle firing neodymium:YAG laser fiber at 40 watts power setting. *J. Urol.*, **150**: 95, 1993.
 19. Costello, A. J., Shaffer, B. S. and Crowe, H. R.: Second-generation delivery systems for laser prostatic ablation. *Urology*, **43**: 262, 1994.
 20. Nickel, J. C., Grant, S. K. and Costerton, J. W.: Catheter-associated bacteriuria. *Urology*, **26**: 369, 1985.
 21. Boon, T. A., de Gier, R. P. E., van Venrooij, G. E. P. M., van Swol, C. F. P. and Verdaasdonk, R. M.: Clinical and urodynamic results six months after "TULIP" laser prostatectomy. In: Proceedings of the XIth Congress of the European Association of Urology, abstract 149, July 13-16, 1994.
 22. le Rolland, B., Barthelemy, Y., Colombel, M., Chopin, D. and Abbou, C. C.: TULIP laser in the treatment of benign hypertrophy of the prostate (BPH). In: Proceedings of the XIth Congress of the European Association of Urology, abstract 152, July 13-16, 1994.
 23. Vainionpää, S., Vihtonen, K., Mero, M., Pätiälä, H., Rokkanen, P., Kilpikari, J. and Törmälä, P.: Fixation of experimental osteotomies of the distal femur of rabbits with biodegradable material. *Arch. Orthop. Trauma Surg.*, **106**: 1, 1986.
 24. Rokkanen, P., Böstman, O., Vainionpää, S., Vihtonen, K., Törmälä, P., Laiho, J., Kilpikari, J. and Tamminmäki, M.: Biodegradable implants in fracture fixation: early results of treatment of fractures of the ankle. *Lancet*, **1**: 1422, 1985.
 25. Schou, J., Poulsen, A. L. and Nordling, J.: The value of a new symptom score (DAN-PSS) in diagnosing uro-dynamic infravesical obstruction in BPH. *Scand. J. Urol. Nephrol.*, **27**: 489, 1993.