

<https://helda.helsinki.fi>

Inflammation des kératoses actiniques sous docétaxel

Kluger, Nicolas

2018-06

Kluger , N , Rentola , L , Hervonen , P & Lappalainen , K 2018 , ' Inflammation des kératoses actiniques sous docétaxel ' , La Presse Médicale , vol. 47 , no. 6 , pp. 598-599 . <https://doi.org/10.1016/j.lpm.2018.01.023>

<http://hdl.handle.net/10138/302392>

<https://doi.org/10.1016/j.lpm.2018.01.023>

publishedVersion

Downloaded from Helda, University of Helsinki institutional repository.

This is an electronic reprint of the original article.

This reprint may differ from the original in pagination and typographic detail.

Please cite the original version.

Inflammation of actinic keratoses after docetaxel



Inflammation des kératoses actiniques sous docétaxel

The occurrence of local inflammation at the side of actinic keratosis (AK) after systemic chemotherapy is not frequently reported [1]. It has mainly been described with 5-fluorouracil. We report on a case that occurred after docetaxel alone.

Observation

An 81 year-old man with advanced hormone-refractory prostate cancer was referred for an acute cutaneous eruption of the face and upper part of the body after initiation of docetaxel biweekly. In 2001, the patient was diagnosed with prostate adenocarcinoma (stage T2b, Gleason score 7) submitted to prostatectomy. He was then treated by bicalutamide and leuprorelin acetate. In May 2017, he was found metastatic lesions in the kidney and bones and initiated biweekly docetaxel 50 mg/m² with dexamethasone as premedication 7,5 mg as priorly reported [2] in association with denosumab. A rash appeared rapidly after the first docetaxel infusion with erythematous scaly lesions on the upper part of the body, the face and the upper trunk. Symptoms worsened after every session, so that after the 6th cycle, he was seen for diagnosis and management. At presentation, the patient presented with round and oval, 1 to 2 centimeters, macula and patches distributed on the forehead, cheeks, and nose (figure 1A) but also the upper trunk (figure 1B), shoulders and upper back (figure 1C). The lesions were asymptomatic, neither itchy, or painful, slightly scaly and rough to the touch. The underlying affected skin featured clear signs of chronic sun exposure (helioderma). The scalp was devoid of any lesion. The clinical presentation was evocative of inflamed AK. Differential diagnosis at consultation included subacute cutaneous lupus. The patient did not recall any skin lesions prior to this eruption. Physical examination was otherwise unremarkable. A 3-mm punch skin biopsy of a lesion of the upper back was performed and confirmed the diagnosis of AK (figure 2). Highly potent (betamethasone) and mild (desonide) corticosteroid ointments were applied on the trunk and the face respectively while docetaxel was maintained. At one month follow-up, the condition improved but without complete clearance. He developed nail onycholysis. The patient responded well to the chemotherapy with an improvement of the metastatic lesions and a drop of PSA levels but docetaxel had to be stopped because of the accumulation of side effects such as alopecia, onycholysis, edema of the lower limbs and peripheral neuropathy.

Discussion

The inflammation of AK from systemic chemotherapy is a long time known phenomenon [3], albeit not frequently reported

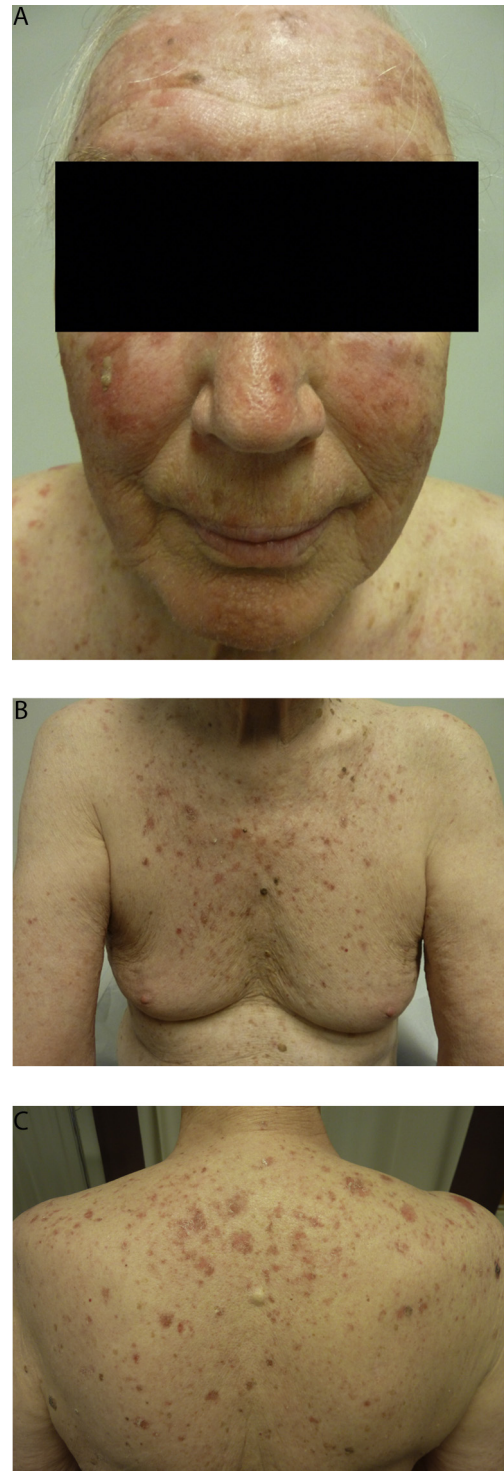


FIGURE 1

A. Erythematous scaly eruption consistent with inflamed actinic keratoses of the face. B. Upper trunk. C. Upper back

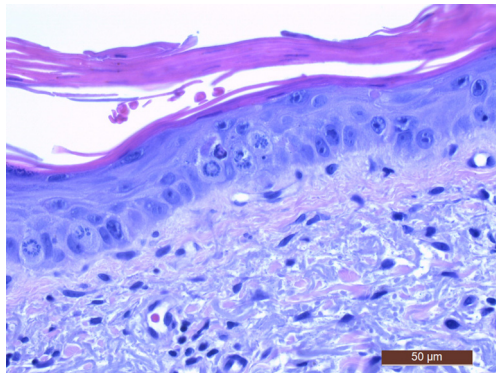


FIGURE 2

Biopsy specimen of the upper back showing showing parakeratosis, dyskeratotic keratinocytes with increased mitoses and solar elastosis in the dermis (hematoxylin-eosin, $\times 400$)

[1]. It has mainly been described with 5-fluorouracil or its prodrug (capecitabine) [4,5]. Other systemic drugs (cisplatin, dactinomycin, doxorubicin, vincristine, pemetrexed [6], bendamustine [7]) have been involved, even though in case of polychemotherapy, it can be challenging to assess which drug is the culprit. To our knowledge, docetaxel has been reported only on one prior occasion [8]. However, in this case, docetaxel was administrated with carboplatin. Inflammation of AK has been observed with targeted therapies such as sorafenib [9], erlotinib [10], and panitumumab [11]. As noted by Johnson et al. [1] and as illustrated in our case, AK are usually not clinically apparent before chemotherapy. The physiopathogeny of this local inflammation relies on the DNA synthesis abnormalities that characterize any AK [12]. Thus, they are more like to react to chemotherapy. However, not every patient, nor all chemotherapies are responsible for such reaction. 5-FU is the most frequently responsible and as a matter of fact topical 5-FU is still used in dermatology in the management of local AK [12]. It is not known whether such reaction can be seen as a favourable prognosis factor.

To the best of our knowledge, we report the first case of inflamed AK after docetaxel alone. The occurrence of inflamed AK is not an indicator of any drug allergy and should not be an indication for chemotherapy withdrawal.

Funding sources: none.

Disclosure of interest: the authors declare that they have no competing interest.

References

- [1] Johnson TM, Rapini RP, Duvic M. Inflammation of actinic keratoses from systemic chemotherapy. *J Am Acad Dermatol* 1987;17:192-7.
- [2] Hervonen P, Joensuu H, Joensuu T, Ginman C, McDermott R, Harmenberg U, et al. Biweekly docetaxel is better tolerated than conventional three-weekly dosing for advanced hormone-refractory prostate cancer. *Anticancer Res* 2012;32:953-6.
- [3] Falkson G, Schulz FA. Skin changes in patients treated with 5-fluorouracil. *Br J Dermatol* 1962;74:229-36.
- [4] Lewis KG, Lewis MD, Robinson-Bostom L, Pan TD. Inflammation of actinic keratoses during capecitabine therapy. *Arch Dermatol* 2004;140:367-8.
- [5] Peramiquel L, Dalmau J, Puig L, Roé E, Fernández-Figueras MT, Alomar A. Inflammation of actinic keratoses and acral erythrodysesthesia during capecitabine treatment. *J Am Acad Dermatol* 2006;55:S119-20.
- [6] Cameron MC, Suárez AL, Kris MG, Myskowski PL. Inflamed Actinic Keratoses After Pemetrexed. *Skinmed* 2016;14(6):473-4.
- [7] Philibert F, Arnault JP, Beaumont M, Lok C, Chaby G. Inflammation des kératoses actiniques sous bendamustine. *Ann Dermatol Venerol* 2017;144:S146-7.
- [8] Makdsi F, Deversa R. Inflammation of actinic keratosis with combination of alkylating and taxane agents: a case report. *Cases J* 2009;2:6946.
- [9] Lacouture ME, Desai A, Soltani K, Petronic-Rosic V, Laumann AE, Ratain MJ, et al. Inflammation of actinic keratoses subsequent to therapy with sorafenib, a multitargeted tyrosine-kinase inhibitor. *Clin Exp Dermatol* 2006;31:783-5.
- [10] Hermanns JF, Piérard GE, Quatresooz P. Erlotinib-responsive actinic keratoses. *Oncol Rep* 2007;18:581-4.
- [11] Escudero-Góngora MM, Del Pozo-Hernando LJ, Corral-Magaña O, Antón E. Inflammation of Actinic Keratosis During Panitumumab Therapy. *Actas Dermosifiliogr* 2017. <http://dx.doi.org/10.1016/j.ad.2017.08.015> [S0001-7310(17)30603-8].
- [12] Werner RN, Stockfleth E, Connolly SM, Correia O, Erdmann R, Foley P, et al. Evidence- and consensus-based (S3) Guidelines for the Treatment of Actinic Keratosis – International League of Dermatological Societies in cooperation with the European Dermatology Forum – Short version. *J Eur Acad Dermatol Venerol* 2015;29:2069-79.

Nicolas Kluger¹, Leena Rentola², Petteri Hervonen²,
Katriina Lappalainen¹

¹University of Helsinki, Helsinki University Central Hospital, Departments of dermatology, allergology and venereology, Meilahdentie 2, PO Box 160, 00029 Helsinki, Finland

²Department of Uro-Oncology, Helsinki Comprehensive Cancer Centre, Haartmaninkatu 4, 00029 Helsinki, Finland

Correspondence: Nicolas Kluger, University of Helsinki, Helsinki University Central Hospital, Departments of dermatology, allergology and venereology, Meilahdentie 2, PO Box 160, 00029 Helsinki, Finland
nicolas.kluger@hus.fi

Received 27 December 2017

Accepted 31 January 2018

Available online: 17 March 2018

<https://doi.org/10.1016/j.jlpm.2018.01.023>

© 2018 Elsevier Masson SAS. All rights reserved.