

Acute epiglottitis after COVID-19 infection

Andreas Renner^{1,2}  | Satu Lamminmäki³ | Taru Ilmarinen³ | Tamim Khawaja⁴ | Juuso Paajanen¹

¹Heart and Lung Center, Helsinki University Hospital, Helsinki, Finland

²Individualized Drug Therapy Research Program, Faculty of Medicine, University of Helsinki, Helsinki, Finland

³Department of Otorhinolaryngology – Head and Neck Surgery, Head and Neck Center, Helsinki University Hospital and University of Helsinki, Helsinki, Finland

⁴Inflammation Center, Helsinki University Hospital, Helsinki, Finland

Correspondence

Satu Lamminmäki, Department of Otorhinolaryngology – Head and Neck Surgery, Head and Neck Center, Helsinki University Hospital and University of Helsinki, Helsinki, Finland.
Email: satu.lamminmaki@hus.fi

Abstract

In patients with acute epiglottitis, the possibility of COVID-19 should be ruled out. Repeated nasofiberscopy examinations or a tracheostomy, which may produce infectious aerosols, may be required.

KEYWORDS

case report, COVID-19, epiglottitis, PPE measures, surgical tracheostomy

1 | INTRODUCTION

The coronavirus disease 2019 (COVID-19), first described in late 2019, is caused by the severe acute respiratory syndrome coronavirus 2 (SARS-CoV-2). In COVID-19, mortality is mainly caused by acute respiratory failure, whereas morbidity has been described for all major organ systems.¹ Verified secondary bacterial infections in COVID-19 are rare, although antimicrobials are commonly used empirically.²

A case report of a 60-year-old obese male patient with epiglottitis and subsequent positive SARS-CoV-2 RT-PCR was published by Fondaw et al³. This patient had initially presented with dyspnea and stridor and had to undergo emergency cricothyroidotomy for acute epiglottitis. The initial SARS-CoV-2 RT-PCR was negative, but on day two the chest X-ray showed signs consistent with COVID-19 pneumonitis and a repeat test confirmed COVID-19. The patient's condition improved, and he could be weaned off the ventilator on day seven.

Here, we present a second case of likely COVID-19-associated epiglottitis.

2 | CASE REPORT

A 29-year-old man without pre-existing medical conditions tested COVID-19 positive after having headache, fatigue, and mild rhinitis. Within a week, his COVID-19 symptoms improved. After an asymptomatic period of 12 days, the patient developed throat pain. He was referred to the Otorhinolaryngology—Head and Neck Surgery (ORL-HNS) Emergency Department at Helsinki University Hospital due to respiratory distress and muffled voice three weeks after the first symptoms associated with COVID-19 infection. His general health status was good, and vital signs were stable. Nasofiberscopy showed a hyperemic epiglottis that was swollen asymmetrically. Yellowish, pus-like fluid existed in

This is an open access article under the terms of the Creative Commons Attribution-NonCommercial-NoDerivs License, which permits use and distribution in any medium, provided the original work is properly cited, the use is non-commercial and no modifications or adaptations are made.

© 2021 The Authors. *Clinical Case Reports* published by John Wiley & Sons Ltd.

the vallecula and the pyriform sinuses, raising suspicion of a left-side internal abscess of the epiglottis. The epiglottis and the swollen arytenoids blocked the view into the vocal cords (Figure 1).

Laboratory workup at presentation showed an elevated C-reactive protein level (169 mg/L) and white blood cell count ($31.3 \times 10^9/L$) with 87% neutrophils. Within three hours, mild respiratory distress was followed by worsening airway obstruction with stridor, and urgent surgical tracheostomy was performed in local anesthesia. Nasopharyngeal swab still tested positive for SARS-CoV-2 by RT-PCR. The operating theatre personnel used standard personal protection with surgical gowns, gloves, type IIR surgical masks, and plastic eye shields. Empirical intravenous antibiotic treatment with a combination of cefuroxime and metronidazole was begun. Bacterial cultures of blood and throat swabs obtained at presentation were negative. In six days, the swelling of the epiglottis decreased, and the tracheostomy was decannulated successfully. The patient was discharged on the 8th postoperative day in good condition (for timeline see Figure 2). This case report did not meet the criteria to require IRB approval. Written informed consent was obtained from the patient.

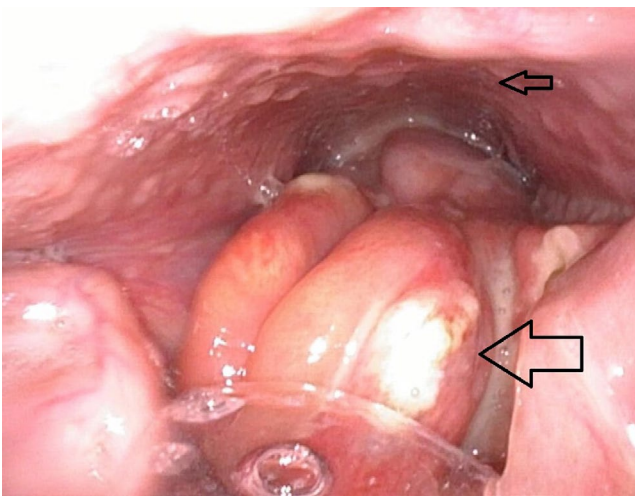


FIGURE 1 Endoscopic image of a swollen epiglottis (large arrow), blocking the view of the vocal folds. Posterior pharyngeal wall is indicated by a small arrow

3 | DISCUSSION

Epiglottitis is a rare, but potentially life-threatening infection that causes sudden inflammation and swelling of the epiglottis. It is usually caused by bacteria, although other etiologies have been reported. As with other viral infections, SARS-CoV-2 can predispose to secondary bacterial superinfections. A meta-analysis representing 3338 patients identified secondary bacterial infection in 6.9% of COVID-19 patients.²

Tracheostomy is an aerosol-generating procedure with an increased risk of transmission of airborne diseases to healthcare workers.⁴ Infectiousness of COVID-19 is considered to be highest around the time of onset of symptoms after which it rapidly decreases. Viral RNA can be detected by RT-PCR for weeks or even months after symptom onset, especially from lower airway tract samples, but that does not necessarily correlate well with infectiousness or even the presence of culturable virus.⁵ There have been a few reports of isolation of viable virus more than ten days after symptom onset but none after twenty.⁵ Our patient underwent surgical tracheostomy three weeks after COVID-19 symptom onset. The decision to use standard personal protection for the operating theatre personnel during the awake tracheostomy was justified in the light of the above. None of those that participated in the tracheostomy were subsequently diagnosed with COVID-19 infection. The duration of risk of transmission from patient to healthcare personnel during surgical tracheostomy is yet unclear. Thus, enhanced PPE measures may be justified when tracheostomy is performed after COVID-19 infection.

Both the case published by Fondaw et al³ and the one presented here had a life-threatening epiglottitis with severe upper airway obstruction and a positive COVID-19 swab test. However, in the case by Fondaw et al³ epiglottitis was the first symptom and lead to the COVID-19 diagnosis, while the patient described here presented with epiglottitis two weeks after recovering from the initial COVID-19 infection. The latter disease course is more in line with other secondary bacterial infections after COVID-19 such as secondary bacterial pneumonia. Based on these two cases,

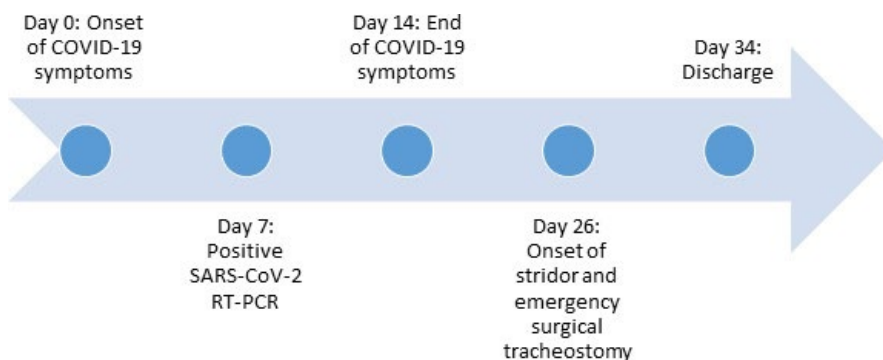


FIGURE 2 Timeline of COVID-19 disease and epiglottitis in the patient presented here

patients with epiglottitis should be tested for COVID-19, not only for the sake of the patient, but also to protect healthcare personnel.

4 | CONCLUSION

We present the case of a young man with likely COVID-19-associated epiglottitis. In COVID-19 patients with respiratory distress, physicians should also keep in mind other possible underlying disorders. On the other hand, in patients with acute epiglottitis, the possibility of COVID-19 should be ruled out. While RT-PCR is the gold standard for detecting SARS-CoV-2 RNA, detection of viral RNA does not necessarily mean that person is infectious and able to transmit the virus. However, enhanced PPE measures may be justified during tracheotomy since the risk of transmission to healthcare personnel is yet unclear.

ACKNOWLEDGMENTS

The authors wish to thank Mira Naukkarinen, MD for the medical image.

CONFLICTS OF INTEREST

The authors declare no conflicts of interest.

AUTHOR CONTRIBUTIONS

AR: wrote the first draft of the manuscript. SL, TI, TK and JP: critically reviewed and edited the manuscript.

DATA AVAILABILITY STATEMENT

All data for which the patient has provided informed consent to be published have been included in this article. No more data can be shared for privacy reasons.

IRB STATEMENT

This case report did not meet criteria to require IRB approval. Written informed consent was obtained from the patient.

ORCID

Andreas Renner  <https://orcid.org/0000-0002-1414-5433>

REFERENCES

1. Wang K, Qiu Z, Liu J, et al. Analysis of the clinical characteristics of 77 COVID-19 deaths. *Sci Rep.* 2020;10(1):16384. <https://doi.org/10.1038/s41598-020-73136-7>
2. Langford BJ, So M, Raybardhan S, et al. Bacterial co-infection and secondary infection in patients with COVID-19: a living rapid review and meta-analysis. *Clin Microbiol Infect.* 2020;26(12):1622-1629. <https://doi.org/10.1016/j.cmi.2020.07.016>
3. Fondaw A, Arshad M, Batool S, Robinson B, Patel T. COVID-19 infection presenting with acute epiglottitis. *J Surg Case Rep.* 2020;2020(9):1-3. <https://doi.org/10.1093/jscr/rjaa280>
4. McGrath BA, Brenner MJ, Warrillow SJ, et al. Tracheostomy in the COVID-19 era: global and multidisciplinary guidance. *Lancet Respir Med.* 2020;8(7):717-725. [https://doi.org/10.1016/S2213-2600\(20\)30230-7](https://doi.org/10.1016/S2213-2600(20)30230-7)
5. Fontana LM, Villamagna AH, Sikka MK, McGregor JC. Understanding viral shedding of severe acute respiratory coronavirus virus 2 (SARS-CoV-2): review of current literature. *Infect Control Hosp Epidemiol.* 2020;1-10. <https://doi.org/10.1017/ice.2020.1273>

How to cite this article: Renner A, Lamminmäki S, Ilmarinen T, Khawaja T, Paaianen J. Acute epiglottitis after COVID-19 infection. *Clin Case Rep.* 2021;9:e04419. <https://doi.org/10.1002/ccr3.4419>