



UNIVERSITY OF HELSINKI



<https://helda.helsinki.fi>

Helda

The Application of the Novel Grading Scale (Lawton-Young Grading System) to Predict the Outcome of Brain Arteriovenous Malformation

Hafez, Ahmad

Lippincott Williams and Wilkins

2019-02

Hafez, A, Koroknay-Pal, P, Oulasvirta, E, Abou Elseoud, A, Lawton, M T, Niemelä, M & Laakso, A 2019, 'The Application of the Novel Grading Scale (Lawton-Young Grading System) to Predict the Outcome of Brain Arteriovenous Malformation', *Neurosurgery* (Baltimore), vol. 84, no. 2, pp. 529-535. <https://doi.org/10.1093/neuros/nyy153>

<http://hdl.handle.net/10138/301120>
[10.1093/neuros/nyy153](https://doi.org/10.1093/neuros/nyy153)

cc_by_nc_nd
publishedVersion

Downloaded from Helda, University of Helsinki institutional repository.

This is an electronic reprint of the original article.

This reprint may differ from the original in pagination and typographic detail.

Please cite the original version.

The Application of the Novel Grading Scale (Lawton-Young Grading System) to Predict the Outcome of Brain Arteriovenous Malformation

Ahmad Hafez, MD*
 Päivi Koroknay-Pál, MD, PhD*
 Elias Oulasvirta, BM*
 Ahmed Abou Elseoud, MD,
 PhD[‡]
 Michael T. Lawton, MD[§]
 Mika Niemelä, MD, PhD*
 Aki Laakso, MD, PhD*

*Department of Neurosurgery, Helsinki University Hospital, Helsinki, Finland; [‡]Department of Diagnostic Radiology, Helsinki University Hospital, Helsinki, Finland; [§]Department of Neurosurgery, Barrow Neurological Institute, Phoenix, Arizona

Correspondence:

Ahmad Hafez, MD,
 Department of Neurosurgery,
 Helsinki University Central Hospital,
 Topeliuksenkatu 5,
 00260 Helsinki, Finland.
 E-mail: ext-ahmad.hafez@hus.fi

Received, October 6, 2017.

Accepted, March 28, 2018.

Published Online, May 4, 2018.

© Congress of Neurological Surgeons 2018.

This is an Open Access article distributed under the terms of the Creative Commons Attribution-NonCommercial-NoDerivs licence (<http://creativecommons.org/licenses/by-nc-nd/4.0/>), which permits non-commercial reproduction and distribution of the work, in any medium, provided the original work is not altered or transformed in any way, and that the work is properly cited. For commercial re-use, please contact journals.permissions@oup.com

BACKGROUND: A supplementary grading scale (Supplemented Spetzler-Martin grade, Supp-SM) was introduced in 2010 as a refinement of the SM system to improve preoperative risk prediction of brain arteriovenous malformations (AVMs).

OBJECTIVE: To determine the ability to predict surgical outcomes using the Supp-SM grading scale.

METHODS: This retrospective study was conducted on 200 patients admitted to the Helsinki University Hospital between 2000 and 2014. The validity of the Supp-SM and SM grading systems was compared using the area under the receiver operating characteristic (AUROC) curves, with respect to the change between preoperative and early (3-4 mo) as well as final postoperative modified Rankin Scale (mRS) scores.

RESULTS: The performance of the Supp-SM was superior to that of the SM grading scale in the early follow-up (3-4 mo): AUROC = 0.57 (95% confidence interval [CI]: 0.49-0.65) for SM and AUROC = 0.67 (95% CI: 0.60-0.75) for Supp-SM. The Supp-SM performance continued improving over SM at the late follow-up: AUROC = 0.63 (95% CI: 0.55-0.71) for SM and AUROC = 0.70 (95% CI: 0.62-0.77) for Supp-SM. The perforating artery supply, which is not part of either grading system, plays an important role in the early follow-up outcome ($P = .008$; odds ratio: 2.95; 95% CI: 1.32-6.55) and in the late follow-up outcome ($P < .001$; odds ratio: 5.89; 95% CI: 2.49-13.91).

CONCLUSION: The Supp-SM grading system improves the outcome prediction accuracy and is a feasible alternative to the SMS, even for series with higher proportion of high-grade AVMs. However, perforators play important role on the outcome.

KEY WORDS: Brain arteriovenous malformation, Spetzler-Martin grading system, Supplementary grading system, Modified Rankin Scale

Neurosurgery 84:529-536, 2019

DOI:10.1093/neuros/nyy153

www.neurosurgery-online.com

The Spetzler-Martin grading scale (SMS) has long been used to predict the surgical outcomes of patients with brain arteriovenous malformations (AVMs).¹ SMS categorizes AVMs into 5 grades based on size (small: 0-3 cm; medium: 3-6 cm; large: over 6 cm), existence of deep venous drainage, and eloquence of location. While SMS is certainly

useful in predicting surgical outcomes, it has its limitations and does not consider many factors that potentially influence outcome. In 2010, Lawton and colleagues² proposed a new grading scale to improve patient selection and to more accurately predict surgical risk. The Supplemented Spetzler-Martin grade (Supp-SM) adds patient age, history of hemorrhage, and nidus type in addition to the classical SMS factors.

Since the Supp-SM's introduction in 2010, few studies have compared the performance of SMS and Supp-SM in predicting surgical outcomes.^{3,4} We analyzed surgically treated patients with brain AVMs to compare the predictive value of Supp-SM to SMS alone.

ABBREVIATIONS: AUROC, area under the receiver operating characteristic; AVM, arteriovenous malformation; CI, confidence interval; mRS, modified Rankin Scale; OR, odds ratio; ROC, receiver operative characteristic; SM, Spetzler-Martin; SMS, Spetzler-Martin grading scale; Supp-SM, Supplemented Spetzler-Martin grade

To evaluate the predicting power of the new grading scale, we compared their individual performance; each grading scale was individually added to a clinical prognostic model, based on the modified Rankin Scale (mRS). We hypothesized that the Supp-SM performance would be higher than that of the SMS alone in predicting the surgical outcomes of brain AVM.

METHODS

Participants

We performed an open-cohort retrospective study including consecutive, surgically treated patients with AVM who were admitted to our neurosurgical department at Helsinki University Hospital (with a catchment area population of approximately 2 million, for whom our center is the sole neurosurgical service provider) between January 2000 and December 2014. An AVM diagnosis was based on angiography and histology. Patients with spinal AVMs, dural arteriovenous fistulae, and vein of Galen aneurysms were not included in the study. The study sample consisted of patients with AVMs treated with neurosurgical resection, of which 200 had complete demographic, radiological, and clinical data. The Helsinki University Hospital ethical committee approved the study. Informed consent was obtained from all individual participants included in the study.

Study Variables

Data were collected from 200 AVM patients who underwent microsurgical AVM resection to compare the predictive power of the SMS score and the Supp-SM score. Variables included the SMS components (AVM size, venous draining pattern, and eloquence) and the Supp-SM components (age at resection, hemorrhage before resection, and diffuseness of the AVM nidus).³ For outcome, preoperative mRS, 3- to 4-mo mRS, and late mRS in 2016 were used.

Statistical Analysis

The statistical analysis was performed using Statistical Package for the Social Sciences software, version 24 (SPSS, IBM Inc, Armonk, New York), except for comparison of ROC curves, which was performed using MedCalc software, version 18 (MedCalc Software, Ostend, Belgium). We used chi-square to assess differences between cohorts for categorical characteristics in univariate analyses, and logistic regression for multivariate analysis of factors affecting postoperative mRS. ROC curves were compared using the Hanley & McNeil method.⁵ A probability value $<.05$ was considered statistically significant. Difference in mRS scores before and after surgery was considered as an index for the outcome. Favorable outcome was considered when mRS remained unchanged or improved.

By comparing the area under the receiver operative characteristic (ROC) curves when using SMS and Supp-SM scores in relation to the difference between mRS pre- and postoperatively, we evaluated the power of prediction for both scales. For the area under ROC, 0.5 is considered indifferent, while 1 indicates full discrimination. SMS and Supp-SM coefficients were calculated for the 3- to 4-mo follow-up (early outcome) and for the final follow-up (2016, last outcome).

To derive a more accurate estimate for the model, we performed 10-fold cross-validation measures of fit and estimated the area under the ROC curve using data from the 10 validation sets.

RESULTS

Overall, 200 patients were included in this study. Patient demographics and AVM characteristics are summarized in Table 1. Of all patients, 38% had embolization and 3% had radio-surgery before microsurgical resection. Favorable outcomes after surgery were observed in 138 of the 200 patients (69% mRS scores 0-2). Unchanged or improved mRS scores were observed in 133 patients (67%). At the first (3-4 mo) follow-up, 7 patients (3%) had died, whereas at the final follow-up (2016) 23 (11%) had died, 16 from AVM-related causes. Nine of the patients who died had preoperative mRS scores of 5. Older patients, patients with unruptured AVMs, and patients with diffuse AVM nidus showed a higher tendency for unfavorable outcomes. However, deep perforating artery supply showed a significant relationship with unfavorable outcome ($P < .001$). There was no difference in the proportion of patients with large AVMs ($P = .470$).

Detailed distribution of the patient characteristics and the AVM-related factors were connected to the outcomes (Table 2). Neurological outcomes were arranged by SM and Supp-SM grades. Unfavorable outcome level increases with higher grades in both SM and Supp-SM grading systems, particularly at the long-term outcome. However, the high percentage (28%) of SM grades IV and V in our series (Table 1) led to an average correlation between the grades and the outcomes.

Univariate analysis identified age ($P < .001$), perforating artery supply ($P = .030$), and associated aneurysm (.046) as significant predictors for unfavorable mRS at the early outcome (3-4 mo follow-up). Eloquence of location was borderline significant ($P = .063$).

For late outcome, univariate analysis identified age (mean > 40 ; $P = .001$), eloquence ($P = .006$), diffuse nidus ($P = .001$), perforator supply ($P < .001$), deep venous drainage ($P = .014$), and nonhemorrhage presentation ($P = .049$) as significant predictors for unfavorable outcome (Table 3).

To identify independent predictors of dichotomized outcomes (favorable vs unfavorable), defined as improvement or no change vs worsening in mRS scores between mRS before surgery and early mRS (< 4 mo), as well as mRS before surgery and late mRS outcome, a binary logistic regression model was constructed using the Wald method (first entering variables into the model and then using stepwise backward elimination). For early unfavorable outcome, the significant factors were age > 40 ($P < .001$; odds ratio [OR] = 5.9) and perforator supply ($P = .008$; OR = 2.9; Table 4). For unfavorable late outcome, the significant factors were age > 40 ($P = .002$; OR = 3.2), AVM size > 30 mm ($P = .047$; OR = 0.4), diffuseness of the nidus ($P = .001$; OR = 5.7), deep perforator supply ($P < .001$; OR = 5.9), and nonhemorrhagic presentation ($P = .045$; OR = 0.4; Table 5).

The area under the ROC curve, indicating the predictive accuracy of the SMS and Supp-SM models for early outcome, was higher for the Supp-SM compared to SMS (0.67 and

TABLE 1. Patient Demographics, AVM Characteristics, and Outcomes.

	No.	%	P Value*
Age, yr			.000
<20	33	17%	
20-40	64	32%	
>40	103	51%	
AVM size (cm)			.470
<3	108	54%	
3-6	78	39%	
>6	14	7%	
Eloquence	127	63%	.000
Deep venous draining	84	42%	.056
Diffuse nidus	33	16%	.003
Hemorrhagic presentation	125	63%	.060
Perforating artery supply ^a	44	22%	.000
Spetzler-Martin grade			.008
1	47	23%	
2	55	28%	
3	42	21%	
4	46	23%	
5	10	5%	
Supplemented Spetzler-Martin grade			.000
2	3	2%	
3	22	11%	
4	33	17%	
5	54	27%	
6	35	18%	
7	27	14%	
8	15	7%	
9	10	5%	
10	1	1%	
Preop mRS			
0	21	11%	mRS ^b (0, 1, 2) before surgery (69%)
1	80	40%	
2	36	18%	
3	28	14%	
4	2	1%	
5	33	16%	
4-mo mRS			
0	4	2%	Absolute favorable outcome (58%)
1	81	41%	
2	31	15%	
3	43	22%	
4	14	7%	
5	18	9%	
6 (dead)	7	3%	
missing	2	1%	
Last follow-up mRS			
0	42	21%	Absolute favorable outcome (69%)

TABLE 1 continued

	No.	%	P Value*
1	52	26%	
2	44	22%	
3	17	9%	
4	18	9%	
5	4	2%	
6 (dead)	23	11%	
Interval (surgery to last follow-up) years			6.02 ± 4.95

*P correlation with last mRS (2016). P-values are derived from a Chi-square test or ANOVA.

^aPerforating arteries include the medial lenticulostriates from the M1 middle cerebral artery (MCA), the insular perforators from the M2 (MCA), thalamoperforators from posterior communicating artery and the P1 posterior cerebral artery, and brain stem perforator.

^bmRS, modified Rankin Scale.

0.57, respectively, $P < .0001$). For late outcome, the area under the ROC curve was also higher for the Supp-SM compared to SMS (0.70 and 0.63, respectively, $P = .0072$; Figure).

DISCUSSION

In this study, we provide further evidence for the predictive power of the Supp-SM. After the introduction of the Supp-SM in 2010,² few published articles have shown its superiority over classical SMS.^{3,4,6}

To minimize the risk of surgical resection, we need to study preoperative relative factors. With the wide spectrum of AVM pathology, individual context, the team's surgical ability and technical support, and finally and most importantly, patient selection for surgery is the key for a good outcome.

Previous AVM grading systems are familiar to neurosurgeons, and these systems helped in predicting the surgical risk and in developing the management decision process. The SM grading system is the most known, practical system, and it has the following variables: size of the AVM (<3, 3-6, and >6 cm), venous draining (deep or superficial), and whether there is eloquence of location. We receive 5 different grades from that collection of variables. Recently, the SM grade system has been modified and renamed the Spetzler-Ponce grading system,⁷ which is simplified as three difference classes. Class A includes SM grades I and II, class B includes SM grade III, and class C includes SM grades IV and V. This classification is aimed at improving the treatment decision process.

Surgery is recommended for grades I and II, and no treatment is recommended for grades IV and V. However, there is a high degree of ambiguity in class B management recommendation,⁸⁻¹¹ and multimodal treatment is often recommended for cases deemed eligible for treatment. Multimodality could mean embolization

TABLE 2. Detailed Distribution of Factors and Neurological Outcomes Associated With Spetzler-Martin Grades and Supplemented Spetzler-Martin Grades.

Neurological outcomes (200 patients)									
	Outcome (4-mo follow-up) ^a				Outcome (last follow-up)				
	Favorable		Unfavorable		Favorable		Unfavorable		
	n (116)	58%	n (82)	41%	n (133)	67%	n (67)	33%	
Sex									
Female	56	62%	34	38%	64	70%	28	30%	
Male	57	53%	51	47%	69	64%	39	36%	
Age group									
0-20	23	70%	10	30%	27	82%	6	18%	
20-40	39	62%	24	38%	47	73%	17	27%	
>40	51	50%	51	50%	59	57%	44	43%	
AVM size (cm)									
<3	65	61%	42	39%	77	71%	31	29%	
3-6	42	54%	36	46%	49	63%	29	37%	
>6	6	46%	7	54%	7	50%	7	50%	
Eloquence location									
Non-E	48	66%	25	34%	60	82%	13	18%	
E	65	52%	60	48%	73	58%	54	42%	
Nidus									
Compact	98	59%	68	41%	118	71%	49	29%	
Diffuse	15	47%	17	53%	15	45%	18	55%	
Perforating artery supply									
No	92	59%	63	41%	112	72%	44	28%	
Yes	21	49%	22	51%	21	48%	23	52%	
Deep venous draining									
No	69	60%	46	40%	83	72%	33	28%	
Yes	44	53%	39	47%	50	60%	34	40%	
Rupture									
Yes	90	73%	33	27%	86	69%	39	31%	
No	23	31%	52	69%	47	63%	28	37%	
Embolization before surgery									
No	73	59%	51	41%	86	69%	38	31%	
Yes	40	54%	34	46%	47	62%	29	38%	
Spetzler-Martin grade									
I	31	66%	16	34%	40	85%	7	15%	
II	31	57%	23	43%	37	67%	18	33%	
III	25	60%	17	40%	25	60%	17	40%	
IV	22	48%	24	52%	25	54%	21	46%	
V	4	44%	5	56%	6	60%	4	40%	
Supplemented Spetzler-Martin grade									
2	3	100%	0	0%	3	100%	0	0%	
3	17	77%	5	23%	19	86%	3	14%	
4	24	73%	9	27%	29	88%	4	12%	
5	31	59%	22	41%	37	69%	17	31%	
6	20	57%	15	43%	21	60%	14	40%	
7	10	37%	17	63%	13	48%	14	52%	
8	5	36%	9	64%	4	27%	11	73%	
9	2	20%	8	80%	6	60%	4	40%	
10	1	100%	0	0%	1	100%	0	0%	

^aTwo missing cases from early follow-up.

TABLE 3. Univariate Analysis of Variables Associated With Worse 2- to 4-mo mRS (Early Outcome) and Last mRS Follow-up 2016 (Last Outcome).

Factor	Associated with worse (early outcome), <i>P</i> value*	Associated with worse (late outcome), <i>P</i> value*
Age (yr)	.000	.001
AVM size in mm	.931	.447
Eloquent location	.063	.006
Nidus diffuseness	.496	.001
Perforating artery supply	.030	.000
Deep vein draining	.178	.014
Nonhemorrhagic	.365	.049
Embolization	.320	.164
Associated aneurysm	.046	.558

**P* values are derived from a Chi-square test.

TABLE 4. Factors Significantly Associated With Worse Early Outcome in Multiple Logistic Regression Model (Wald Stepwise Backward Model).

Factor	<i>P</i> value	OR	95% CI
Age > 40 yr	.000	5.99	3.06-11.75
Perforating arterial supply	.008	2.95	1.32-6.55

OR = odds ratio, CI = confidence interval.

and surgery, surgery and radiosurgery, embolization and radiosurgery, or even a combination of all 3 modalities.

To enhance the grading system for AVM treatment, the Toronto group's grading system added a new factor.¹² This factor is the compactness of the AVM nidus. This system has replaced the size of the AVM with the nidus type. Deep venous drainage scores 2 points, the diffuseness of the nidus scores 3 points, and the eloquent location scores 4 points. The system did not achieve the popularity of the SM system. However, the diffuseness concept proved to be an important factor from a surgical point of view and significantly impacts the outcome.

Hemorrhagic presentation of the AVM is an important predictor risk for the natural history.¹³⁻¹⁵ The highest risk of bleeding is in those who had previously bled.¹⁶ However, hemorrhage widens the dead space around the AVM and facilitates surgical resection, particularly in low-grade AVM.^{17,18} At the same time, patients with unruptured AVMs typically do not have pretreatment neurological deficits, and are therefore more susceptible to develop new deficits after surgery, compared to patient with ruptured lesions presenting already with neurological deficits due to hemorrhagic stroke. Lawton et al² put together 3 new factors: age, bleeding, and compactness.² The new system has an analogous property with the SM system. Age

TABLE 5. Factors Significantly Associated With Worse Late Outcome in Multiple Logistic Regression Model (Wald Stepwise Backward Model).

Factor	<i>P</i> value	OR	95% CI
Age > 40 yr	.002	3.25	1.54-6.86
Size > 30 mm	.047	0.41	0.17-0.99
Nidus diffuseness	.001	5.74	1.98-16.66
Perforating arterial supply	.000	5.89	2.49-13.91
Nonhemorrhagic	.045	0.44	0.20-0.98

OR = odds ratio, CI = confidence interval.

has 3 groups: less than 20 achieves 1 point, between 20 and 40 achieves 2 points, and over 40 yr achieve 3 points. There is 1 point for unruptured presentation, and 1 point for diffuseness of the nidus.

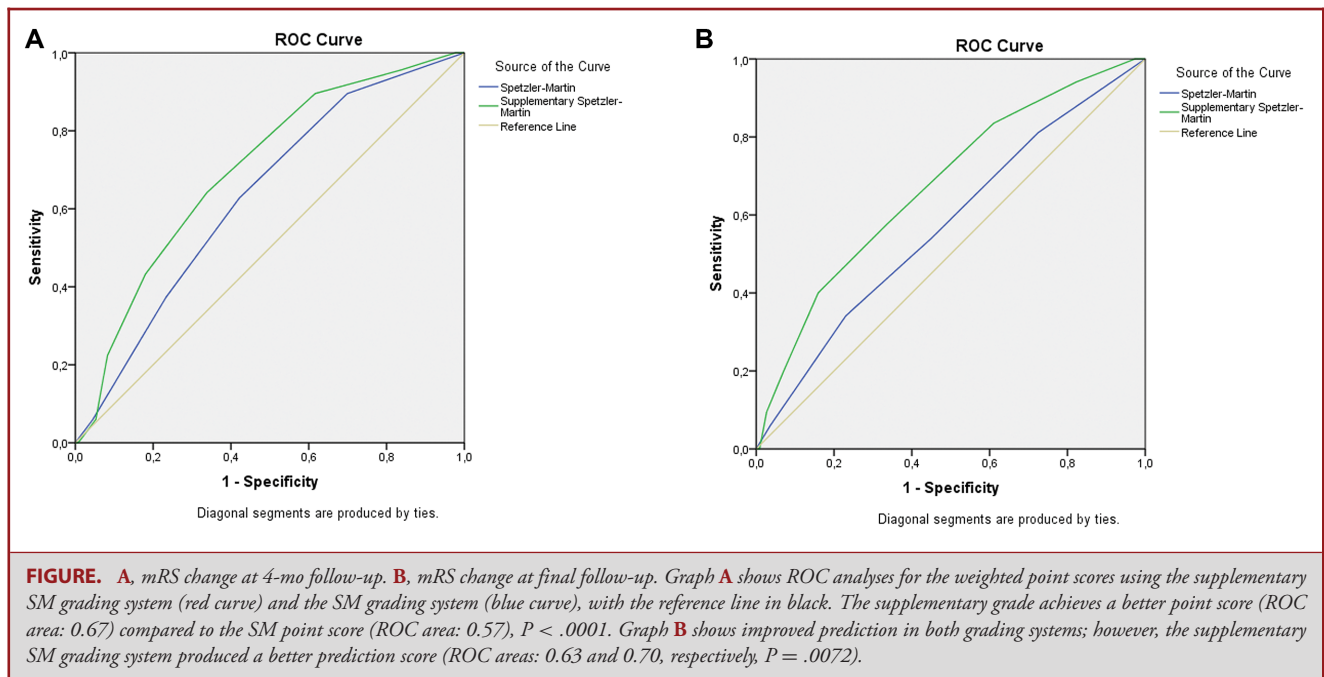
The Supp-SM grading system has 9 different grades (2-10). In this system, grade 6 is considered the cutoff point for acceptable surgical risk.³

The new system has the flexibility of changing over time. Age and bleeding status are changeable factors. Furthermore, nidus shape and AVM size could be changed by radiotherapy and embolization. For that reason, Supp-SM proved to be a dynamic scale system and may be modified by other treatment modalities, particularly endovascular treatment.

Within SM grade III, there are different subtypes with varying mortality and morbidity, depending on the AVM subtype. Therefore, Lawton et al² have subdivided it to grade III+, grade III, grade III-, and grade III*, which is a rare case of large AVM with a superficial draining vein and a noneloquent location, like the right frontal pole. Eloquent location advances grade III to III+, which was also proven in our experience.

Age, which scores 1 to 3 in the supplementary scale, has a certain propriety.¹⁹⁻²¹ High-risk AVM features (aneurysm association and venous abnormalities) are found more often in adults. Furthermore, children are more likely to a hemorrhage.¹⁵ Therefore, young age, which has a lower scoring by itself, is often combined with hemorrhagic presentation, which has a null score in the supplementary scale, further explaining the better outcome in young cohorts.

Deep perforator arterial supply proved to have a significant influence on the outcome in our study but not in the Lawton et al study.² The increased risk caused by deep perforators is quite easy to understand. While resecting the AVM, these fragile small vessels are notoriously difficult to coagulate, and often retract deeper into white matter—containing potentially eloquent long fiber tracts. The deep perforating supply is also more common in large, complex AVMs which by themselves are associated with higher risk of surgery. One possible explanation for this factor being significant in our series is that we have a higher percentage of SM grades IV and V in this study (28%), whereas in Lawton et al,² it was 11%. This means that we have more cases with



large and deeply drained AVMs, which hold a higher possibility of having perforators as supply feeders. The rather high portion of SM grades IV and V reflects both the population responsibility of our center (all AVM patients within the catchment area are treated by us) and the treatment policies of the study period—today, we prefer a more conservative approach for grades IV and V AVMs, particularly in cases of unruptured lesions.

Study Limitations

Our strategy with the results of this study could empower the validation of the Supp-SM grading scale, as we included a reasonable number of all grades, and the new scale achieves the same result shown by the scale's inventors.

Judging the diffuseness of the nidus is still somewhat subjective. However, advanced radiological technologies allowed discriminating the many subtypes of diffuse nidus.

There are many other factors that could play important roles in the surgical outcome, such as associated aneurysm, time elapsed before surgery for ruptured cases, and perforators.

Eleven of the cases with rupture before surgery had received some other treatment modality (embolization in 10 cases, stereotactic radiosurgery in 1 case) than microsurgery for their originally unruptured AVM. Since the surgery was performed after the rupture, these cases were classified as being ruptured for the purpose of Supp-SM grading, even though they might have somewhat different properties than AVM cases experiencing rupture without any prior treatment. However, this should not affect the comparison of these 2 scales. Moreover, since multimodal treatment is so common nowadays, we believe that

including also these cases to our series for completeness adds certain “real-life” value.

CONCLUSION

The new grading system helps in understanding and predicting surgical outcomes. Selection according to the available optimal scale is the key for success in AVM surgery, and most importantly, the Supp-SM grading scale helps decide when not to operate. Other scales could be invented in the future that include extra factors such as deep perforators, according to the development of treatment modalities and available knowledge. With a challenging pathology like AVM, the surgeon's judgment and skill are critical.

Disclosures

Finnish government provided financial support (Finnish government grant for academic health research #TYH2017235). First author (A.H.) was awarded a scholarship for his PhD program from C. Ehmrooth Fellowship (Fondation de Luxembourg). The sponsors had no role in the design or conduct of this research. The authors have no personal, financial, or institutional interest in any of the drugs, materials, or devices described in this article.

REFERENCES

- Spetzler RF, Martin NA. A proposed grading system for arteriovenous malformations. *J Neurosurg.* 1986;65(4):476-483.
- Lawton MT, Kim H, McCulloch CE, Mikhak B, Young WL. A supplementary grading scale for selecting patients with brain arteriovenous malformations for surgery. *Neurosurgery.* 2010;66(4):702-713.
- Abla AA, Rutledge WC, Seymour ZA, et al. A treatment paradigm for high-grade brain arteriovenous malformations: volume-staged radiosurgical downgrading followed by microsurgical resection. *J Neurosurg.* 2015;122(2):419-432.

4. Ding D, Liu KC. Predictive capability of the Spetzler-Martin versus supplementary grading scale for microsurgical outcomes of cerebellar arteriovenous malformations. *J Cerebrovasc Endovasc Neurosurg*. 2013;15(4):307-310.
5. Hanley JA, McNeil BJ. A method of comparing the areas under receiver operating characteristic curves derived from the same cases. *Radiology*. 1983;148(3):839-843.
6. Neidert MC, Lawton MT, Mader M, et al. The AVICH Score: A novel grading system to predict clinical outcome in Arteriovenous Malformation-Related intracerebral hemorrhage. *World Neurosurg*. 2016;92:292-297.
7. Spetzler RF, Ponce FA. A 3-tier classification of cerebral arteriovenous malformations. *J Neurosurg*. 2011;114(3):842-849.
8. Jeon HJ, Park KY, Kim SY, Lee JW, Huh SK, Lee KC. Surgical outcomes after classifying Grade III arteriovenous malformations according to Lawton's modified Spetzler-Martin grading system. *Clin Neurol Neurosurg*. 2014;124:72-80.
9. Lawton MT, Project UBAMS. Spetzler-Martin Grade III arteriovenous malformations: surgical results and a modification of the grading scale. *Neurosurgery*. 2003;52(4):740-749.
10. Ryu B, Ishikawa T, Kawamata T. Multimodal treatment strategy for Spetzler-Martin grade III arteriovenous malformations of the brain. *Neurol Med Chir (Tokyo)*. 2017;57(2):73-81.
11. Pandey P, Marks MP, Harraher CD, et al. Multimodality management of Spetzler-Martin grade III arteriovenous malformations. *J Neurosurg*. 2012;116(6):1279-1288.
12. Spears J, Terbrugge KG, Moosavian M, et al. A discriminative prediction model of neurological outcome for patients undergoing surgery of brain arteriovenous malformations. *Stroke*. 2006;37(6):1457-1464.
13. Laakso A, Hernesniemi J. Arteriovenous malformations: epidemiology and clinical presentation. *Neurosurg Clin N Am*. 2012;23(1):1-6.
14. Majumdar M, Tan LA, Chen M. Critical assessment of the morbidity associated with ruptured cerebral arteriovenous malformations. *J NeuroIntervent Surg*. 2016;8(2):163-167.
15. Morgan MK, Davidson AS, Assaad NNA, Stoodley MA. Critical review of brain AVM surgery, surgical results and natural history in 2017. *Acta Neurochir*. 2017;159(8):1457-1478.
16. Laakso A, Dashti R, Juvela S, Niemela M, Hernesniemi J. Natural history of arteriovenous malformations: presentation, risk of hemorrhage and mortality. *Acta Neurochir Suppl*. 2010;107:1457-1478.
17. Pavasi G, Rustemi O, Berlucchi S, Frigo AC, Gerunda V, Scienza R. Acute surgical removal of low-grade (Spetzler-Martin I-II) bleeding arteriovenous malformations. *Surg Neurol*. 2009;72(6):662-667.
18. Morgan MK, Hermann Wiedmann MK, Stoodley MA, Heller GZ. Microsurgery for Spetzler-Ponce Class A and B arteriovenous malformations utilizing an outcome score adopted from Gamma Knife radiosurgery: a prospective cohort study. *J Neurosurg*. 2017;127(5):1105-1116.
19. Hettis SW, Cooke DL, Nelson J, et al. Influence of patient age on angioarchitecture of brain arteriovenous malformations. *AJNR Am J Neuroradiol*. 2014;35(7):1376-1380.
20. Sanchez-Mejia RO, Chennupati SK, Gupta N, Fullerton H, Young WL, Lawton MT. Superior outcomes in children compared with adults after microsurgical resection of brain arteriovenous malformations. *J Neurosurg*. 2006;105(2 Suppl):82-87.
21. Gross BA, Storey A, Orbach DB, Scott RM, Smith ER. Microsurgical treatment of arteriovenous malformations in pediatric patients: the Boston Children's Hospital experience. *J Neurosurg Pediatr*. 2015;15(1):71-77.

COMMENTS

This retrospective, open cohort of surgically treated AVMs at a single center from 2000–2014 furthers and updates the utility of the supplementary Spetzler-Martin AVM grading scale in predicting operative outcomes. The authors provide updated evidence that a grading scale that adds age, hemorrhage status, and nidus type to the Spetzler-Martin scale can more accurately predict surgical outcome than the classical Spetzler-Martin scale. They also demonstrate the importance of an un-ruptured status and deep perforator supply in predicting outcome. These factors should be particularly helpful in making decision on Grade

III lesions, which remain a point of clinical controversy. Also, this cohort confirms the Toronto data that a “diffuse” nidus is a harbinger of a dangerous surgical lesion; going forward we should work to more rigorously define the somewhat nebulous classification.

Dennis J. Rivet II
Richmond, Virginia

Treating patients with arteriovenous malformation (AVM) is still considered one of the most challenging entities in neurosurgery. The available treatment options are surgical resection, endovascular embolization, and stereotactic radiosurgery, alone or in any combination. Although the never-ending discussion on the best treatment modality of AVM continues, surgical resection remains the gold standard for definitive treatment of AVMs. For the past 3 decades, the Spetzler-Martin grading scale (SMS) has been used in preoperative risk prediction and patient selection for surgery.¹ Although SMS did not include some fundamental features of the AVM or of the patient, its simplicity and practicality ensured wide acceptance.² Spetzler further simplified his 5-tier grading system and condensed it into a 3-tier classification³ in order to provide simpler treatment recommendations.

Attempts were made to modify SMS by expanding the included variables, which in return brought complexity and therefore less popularity. As shown by this study, the new supplementary grading system proposed by Lawton et al⁴ (Supp-SM) offers more accuracy in predicting surgical risk. However, it increases the number of grades to 9 (2 to 10) by combining patient age, hemorrhagic presentation, and nidus diffuseness to the 3 factors (nidus size, deep venous drainage, and eloquence of location) of SMS. These additions seem to be reasonable because all these factors have significant influence on the outcome. However, besides these 3 new variables it is possible to add some more to the list. For example, in our experience, involvement of deep perforator arteries (such as medial lenticulostriate arteries from A1, lateral lenticulostriate arteries from M1, thalamoperforating arteries from P1, etc) is the most critical factor in the fate of an AVM surgery. Coagulating these arteries is difficult due to the weaker vessel wall architecture, thus proximal control should be obtained whenever possible to facilitate coagulation. Another imperative factor that should be considered before deciding a conservative approach is the condition of the straight sinus which was mentioned by Yasargil.^{5,6} If it is stenotic or occluded and compromising the venous outflow of the AVM, this might lead to a higher incidence of intracranial hemorrhage for AVMs. Therefore, absence or decreased flow through the straight sinus should direct the surgeon towards surgical resection. In our experience these 2 factors are as important as others in Supp-SM. Certainly, there may be other crucial surgical considerations that deserve to be marked during patient selection for surgery. But rather than adding all these factors to create new complicated grading systems, neurosurgeons should assess these variables for each patient in their individualized risk analysis.

We would like to congratulate the authors for their good surgical results in such a large series of patients with AVM. This study will certainly help neurosurgeons with patient selection and achieving better outcomes. Our goal should be searching for ways to help our patients before they develop deficits due to whatever illness they have instead of abandoning them to their fate without forgetting our limits. Grading systems are helpful in that manner but we should know that there are limitations to every grading system and avoid exaggerating the usefulness of these classifications. Labeling any given lesion as inoperable is something that should be thoroughly thought upon to avoid creating

barriers impeding the development of neurosurgery in the hands of young generations.

**Mehmet Volkan Harput
Uğur Türe**
Istanbul, Turkey

1. Spetzler RF, Martin NA. A proposed grading system for arteriovenous malformations. *J Neurosurg.* 1986;65(4):476-483.
2. Ponce FA, Spetzler RF. Arteriovenous malformations: classification to cure. *Clin Neurosurg.* 2011;58:10-12.
3. Spetzler RF, Ponce FA. A 3-tier classification of cerebral arteriovenous malformations. *Clinical article. J Neurosurg.* 2011;114(3):842-849.
4. Lawton MT, Kim H, McCulloch CE, Mikhak B, Young WL. A supplementary grading scale for selecting patients with brain arteriovenous malformations for surgery. *Neurosurgery.* 2010;66(4):702-713.
5. Yaşargil MG. *Microneurosurgery IIIA - AVM of the Brain: History, Embryology, Pathological Considerations, Hemodynamics, Diagnostic Studies, Microsurgical Anatomy.* Thieme; 1987, 193-195.
6. Yaşargil MG. *Microneurosurgery IIIB AVM of the Brain, Clinical Considerations, General and Special Operative Techniques, Surgical Results, Non-operated Cases, Cavernous and Venous Angiomas, Neuro-anesthesia.* New York: Thieme; 1988, 204-368.

This is a very thoughtful retrospective study that aims to validate the ability of the Lawton-Young Grading System (also known as the Supplementary Spetzler-Martin Grading Scale) to predict outcomes in patients with brain AVM who undergo surgical treatment. While the methodology is similar to those outlined by Lawton et al in 2010,¹ this study does provide a meaningful validation of the value of the Lawton-Young Grading System, particularly in a relatively even distribution of cases from Spetzler-Martin Grade 1 through 5 in the cohort.

In addition to factors such as age at surgery, diffuseness of nidus, and hemorrhagic presentation as suggested by Lawton et al 2010,¹ the one significant factor influencing surgical outcome found in this study is the presence of deep perforating arterial feeders. Many experienced surgeons would agree with the technical importance of these arterial feeders. Older age may imply higher overall surgical risk and lower ability for recovery. A diffuse nidus makes identification of the AVM margin challenging, thus increasing the likelihood of injury to adjacent eloquent brain tissue. Because patients without a history of hemorrhage are typically intact

functionally, neurological deficits become more apparent if they occur postoperatively. Deep perforating feeders are often not accessible for preoperative embolization given their tiny size and tortuous anatomy. They are not only routinely found in the deep part of surgical field and often the last to be visualized during the operation, but they are also difficult to be coagulated. The outcome is often additional injury to deep white matter, as the authors mention.

The challenges of conducting a prospective randomized trial in cases of brain AVM therapy are apparent. This retrospective study offers insights into which supplemental factors should be considered in addition to the original Spetzler-Martin predicting factors to guide decision making during AVM surgical treatment. Thus, I strongly support the authors' view that these supplemental factors be used in addition to the original Spetzler-Martin predicting factors during AVM surgery to achieve the best outcome.

Peng Roc Chen
Houston, Texas

1. Lawton MT, Kim H, McCulloch CE, Mikhak B, Young WL. A supplementary grading scale for selecting patients with brain arteriovenous malformations for surgery. *Neurosurgery.* 2010;66(4):702-713; discussion 713.

The authors examine the predictive accuracy of the Spetzler-Martin grading scheme versus the supplementary SM grading scheme (proposed by Lawton et al in 2010¹) in a cohort of 200 AVMs treated surgically. The main new finding, not incorporated in either SM or supplementary SM grades, is that presence of deep perforator supply is significantly correlated with unfavorable postoperative outcomes. It is therefore possible that future work may incorporate this into a unified grading scheme, further improving accuracy of predicting postoperative results in these challenging patients.

Babak S. Jahromi
Chicago, Illinois

1. Lawton MT, Kim H, McCulloch CE, Mikhak B, Young WL. A supplementary grading scale for selecting patients with brain arteriovenous malformations for surgery. *Neurosurgery.* 2010;66(4):702-713; discussion 713.