Department of Otorhinolaryngology – Head and Neck Surgery
University of Helsinki
Finland

Injection laryngoplasty with autologous fascia for treatment of unilateral vocal fold paralysis

Petri Reijonen

ACADEMIC DISSERTATION

To be publicly discussed, by permission of the Medical Faculty of the University of Helsinki, for public examination in the auditorium 3 of the Biomedicum Research Center, Haartmaninkatu 8, Helsinki,
on 14 August 2009, at 12 noon.

Helsinki 2009

Supervised by

Docent Heikki Rihkanen
Department of Otorhinolaryngology – Head and Neck Surgery
University of Helsinki
Helsinki, Finland

Docent Leena-Maija Aaltonen
Department of Otorhinolaryngology – Head and Neck Surgery
University of Helsinki
Helsinki, Finland

Reviewed by

Professor Marc Remacle
Department of Otorhinolaryngology – Head and Neck Surgery
University Hospital of Louvain at Mont-Godinne
Yvoir, Belgium

Docent Jussi Laranne
Department of Otorhinolaryngology – Head and Neck Surgery
University of Tampere
Tampere, Finland

Opponent

Professor Gerhard Friedrich
Department of Phoniatrics, Speech and Swallowing
Medical University of Graz
Graz, Austria

ISBN 978-952-92-5589-4 (pbk.)
ISBN 978-952-10-5592-8 (PDF)

Helsinki University Printing House
Helsinki 2009

Contents

Abstract 4
List of original publications 6
Abbreviations 7
1 Introduction 8
2 Review of the literature 10
2.1. Transplantation of autologous fascia 10
2.1.1. Fascia grafts in the head and neck surgery 10
2.1.2. Histology of the transplanted autologous fascia 11
2.1.3. Fascia grafts in the larynx 11
2.2. Unilateral vocal fold paralysis 12
2.2.1. Definitions and terminology 12
2.2.2. Laryngeal anatomy and biomechanics 13
2.2.3. Incidence, etiology and prognosis 14
2.2.4. Symptoms and laryngologic findings 14
2.3. Role of voice therapy in treatment of UVFP 15
2.4. Surgical treatment of UVFP 16
2.4.1. Injection laryngoplasty 16
2.4.2. Laryngeal framework surgery 22
2.4.3. Laryngeal reinnervation 23
2.4.4. Future perspectives 23
2.5. Outcome evaluation of voice surgery 24
2.5.1. Videostroboscopy 25
2.5.2. Perceptual evaluation 26
2.5.3. Acoustic analysis 26
2.5.4. Aerodynamic measures 27
2.5.5. Other physiologic measures 27
2.5.6. Subjective evaluation of voice quality 27
3 Aims of the study 28
4 Patients and methods 29
4.1. Surgical technique 29
4.2. Animal study (I) 33
4.3. Initial clinical trial with patients (II) 33
4.4. Intermediate term clinical trial (III and IV) 33
4.5. Long term clinical trial (V) 34
4.6. Statistical methods 35
4.7. Ethics 35
5 Results 36
5.1. Histomorphology of the fascia graft, animal study (I) 36
5.2. Voice quality, initial results (II) 38
5.3. Voice quality, intermediate term trial (III) 38
5.4. Videostroboscopy, intermediate term trial (IV) 39
5.5. Voice quality and videostroboscopy, long term trial (V) 40
6 Discussion 41
7 Conclusions 46
Acknowledgements 47
References 49

Abstract

Unilateral vocal fold paralysis (UVFP) results from an injury to the recurrent or the vagal nerve. The main symptom of UVFP is a breathy, weak voice. Surgery is warranted for patients in whom spontaneous reinnervation and a course of voice therapy fails to improve the voice. Three surgical methods are available. Laryngeal framework surgery and injection laryngoplasty offer static approaches, which aim to improve glottal closure by repositioning the paralyzed vocal fold permanently to the adducted position. Reinnervation procedures succeed to restore vocal fold muscle tone without dynamic movement, but being technically demanding, they have not been universally accepted. Laryngeal framework surgery is regarded as the gold standard, but injection laryngoplasty is also widespread. The technique of injection was introduced a century ago, but the search for an ideal injection material is ongoing. Currently, there exists a great diversity of synthetic, xenologous, homologous, and autologous substances available for vocal fold augmentation by injection. An autologous graft is perfect in terms of biocompatibility. High reabsorption rate and subsequent transient treatment outcome have imposed a major problem with fat, the first widely used injectable autologous graft.

Free fascia grafts have been successfully used in the head and neck surgery for decades. The purpose of this work was to study the applicability of minced autologous fascia graft for the injection laryngoplasty of UVFP by experimental animal study and series of clinical trials. Permanence of augmentation and host versus graft tissue reactions were of special interest.

In the animal study of 9 canines, histological analysis of the graft and surrounding vocal fold tissue revealed mild to moderate inflammation initially. No chronic inflammatory response was present at 6 and 12 months. No extensive oedema, areas of necrosis, or granuloma formation was found at any time. At 12 months the graft had integrated into the vocal fold tissue forming a firm tissue mass with viable fibrocytes, remodelled collagen bundles with parallel orientation, and blood supply with arterioles and venules. Scarring was mild around the graft. A foreign-body reaction was found around small polyamide particles, which originated from the polymer plate on which the graft was minced with a scalpel. The finding of polyamide crystals in the graft at 12 months was important. It was an affirmation to the pathologist, that the collagen-rich bundle found in the vocal fold of the dogs was man-made. It also led to a modification of the surgical technique; we began to mince the fascia with scissors on a glass plate after this finding.

Three series of clinical trials of injection laryngoplasty with autologous fascia (ILAF) during a period of ten years were conducted to document the possible morbidity related to graft harvesting and vocal fold injection. Improvement of voice quality was measured by multiple objective parameters of voice evaluation. Surgery was performed only on patients in whom several sessions of voice therapy had failed to improve the voice sufficiently. The preliminary results were studied in a prospective trial of 18 patients. Mean follow-up was 9 months (range 4-25). The maximal phonation time (MPT) and parameters of acoustic analysis indicated better voice quality after intervention. The second trial with 14 patients documented the intermediate term results with a mean follow-up of 13 months (range 5-32). Voice quality measured by perceptual evaluation and acoustic analysis was improved significantly and the integrity of vocal fold closure was enhanced as measured by MPT. Improved glottal closure and return of mucosal wave phase symmetry were also

evident in videostroboscopy. No immediate complications related to graft harvesting or injection procedure occurred. The postoperative inflammatory reaction in the vocal fold was mild without a need for antibiotics or corticosteroids. At the donor site, two prolapses of the vastus lateralis muscle occurred later, one of which was surgically corrected. No complaints were made of an aesthetically disturbing scar on the thigh. No over-correction of the vocal fold was seen postoperatively; the graft had been molded to appropriate size by the dynamic forces exerted on the vocal fold. The retrospective third trial consisted of 43 patients with a median follow-up of 5.8 years (range 3-10). Voice quality was rated improved in perceptual evaluation. In acoustic analysis, statistically significant improvement was measured in jitter. Postoperative videostroboscopy demonstrated complete or partial glottal closure in 83% of patients and mucosal wave phase symmetry in every cycle or most cycles in 74% and amplitude symmetry in 58%. The mean voice handicap index (VHI) postoperatively was 35 (median 29). The VHI was below 30 (normal or near normal voice) in 56%. Length of follow-up or delay from onset of paralysis to injection had no significant effect on the results. Neither was the age of the patient relevant. Poor preoperative voice measured by perceptual evaluation and paralysis caused by an intrathoracic lesion correlated with poor outcome.

Our results indicate that autologous fascia is a feasible injection material for UVFP patients. Harvesting of the graft on the lateral thigh and injection into the vocal fold is met with minor morbidity. Fascia is well tolerated by the vocal fold. When injected deep and laterally into the TA muscle, the fascia graft allows normal vibration of the vocal fold mucosa. Voice quality is significantly improved provided that sufficient augmentation and glottal closure is achieved. Although some resorption or compaction of the graft during the first months is evident, graft volume is maintained well. This stability is reflected by the satisfactory voice results after long follow-up.

List of original publications

This study is based on the following publications referred to in the text by their roman numerals.

I Reijonen P, Leivo I, Nevalainen T, Rihkanen H. Histology of injected autologous fascia in the paralyzed canine vocal fold. Laryngoscope 111:1068-1074, 2001.

II Rihkanen H, Lehikoinen-Söderlund S, Reijonen P. Voice acoustics after autologous fascia injection for vocal fold paralysis. Laryngoscope 109:1854-1858, 1999.

III Reijonen P, Lehikoinen-Söderlund S, Rihkanen H. Results of fascial augmentation in unilateral vocal fold paralysis. Ann Otol Rhinol Laryngol 111: 523-529, 2002

IV Rihkanen H, Reijonen P, Lehikoinen-Söderlund S, Lauri ER. Videostroboscopic assessment of unilateral vocal fold paralysis after augmentation with autologous fascia. Eur Arch Otorhinolaryngol 261:177-183, 2004

V Reijonen P, Tervonen H, Harinen K, Rihkanen H, Aaltonen L-M. Long-term results of autologous fascia in unilateral vocal fold paralysis. Eur Arch Otorhinolaryngol Epub 2009 Feb 25.

Abbreviations

ANOVA	analysis of variance
CNS	central nervous system
CT	computerized tomography
ECM	extracellular matrix
EMG	electromyography
ENT	Ear, Nose and Throat- speciality of medicine
FDA	Food and Drug Administration of USA
GRBAS	scale for perceptual evaluation of voice
HA	hyaluronic acid
IA	interarytenoid muscle
IL	injection laryngoplasty
ILAF	injection laryngoplasty with autologous fascia
LCA	lateral cricoarytenoid muscle
MPT	maximal phonation time
MRI	magnetic resonance imaging
NHR	noise-to-harmonics ratio
PCA	posterior cricoarytenoid muscle
RLN	recurrent laryngeal nerve
SLN	superior laryngeal nerve
TA	thyroarytenoid muscle
UVFP	unilateral vocal fold paralysis
VAS	visual analogue scale
VHI	voice handicap index
VN	vagal nerve

1 Introduction

The main complaint of patients with unilateral vocal fold paralysis (UVFP) is a breathy, weak or even aphonic voice. Failure to close the glottis may also lead to dysphagia; inability to cough and shout; dyspnoea and fatigue related to lifting and straining. The disability and handicap in work performance and other daily tasks is rated by patients equivalent to conditions such as coronary heart disease, sciatica, and chronic sinusitis (Benninger, Ahuja et al. 1998).

UVFP is a relatively common finding in tertiary otolaryngological practice, although its exact incidence has not been established (Benninger, Crumley et al. 1994; Rubin and Sataloff 2007). The most common causes of UVFP are neoplasms (brain stem, neck, chest, mediastinum), surgical trauma (thyroid, neck, chest) and neurological disorders. UVFP may result from an injury to the vagal nerve (VN) or its laryngeal branch, the recurrent laryngeal nerve (RLN). Unilateral injury to the RLN is the most common and leads to paralysis or paresis of all intrinsic laryngeal muscles except the cricothyroid, which is innervated by the superior laryngeal nerve (SLN). In a high VN lesion, the functions of both laryngeal nerves are impaired resulting in aggravated symptoms. Paralysis of the RLN is characterized by ipsilateral flaccidity of the vocal fold and loss of movement (abduction and adduction). The vocal fold remains in different stages of abduction depending on the extent of injury and subsequent reinnervation (Crumley 1994). Prognosis varies greatly according to the etiology. In idiopathic paralysis, generally a period of one year is waited before irreversible treatment decisions are made (Sulica 2008).

The primary goal of treatment in UVFP is to eliminate aspiration and to improve voice. A course of voice therapy is commonly considered beneficial to the patient to prevent compensatory hyperfunctional phonatory behaviour (Benninger, Crumley et al. 1994). After failure of spontaneous recovery, accommodation or appropriate voice therapy, surgery may be considered. The percentage of UVFP patients requiring surgery is rarely reported. One article reported of a group of 160 patients with RLN paralysis of whom 20% were treated by surgery (Heuer, Sataloff et al. 1997). Surgical treatment modalities currently available for UVFP include injection laryngoplasty (Arnold 1962), laryngeal framework surgery (Isshiki, Morita et al. 1974) and laryngeal reinnervation (Tucker 1977; Crumley 1991). Experience of the surgeon and patient-related factors determine the method of choice to achieve optimal results. Laryngeal framework surgery is currently the gold standard against which other methods of surgical intervention are judged (Benninger, Crumley et al. 1994; Kwon and Buckmire 2004). However, injection laryngoplasty has several appealing qualities including relative technical ease, low cost and wide availability in many clinical settings, which have contributed to its widespread use in the general otolaryngological community (Kwon and Buckmire 2004).

The goal of injection laryngoplasty in UVFP is to medialize the paralyzed vocal fold by augmenting its mass, which enables the mobile, unaffected fold to close the glottis. The surgical technique was established long ago (Bruning 1911), but search for a suitable injebtable substance is ongoing. Teflon® injection (paste of polytetrafluoro-ethylene) was the mainstay of surgical treatment of patients with glottal insufficiency for decades (Dedo, Urrea et al. 1973). Due to many long-term side-effects (foreign-body reaction, migration of particles) related to Teflon®, it has been excluded from the practice of modern laryngology (Kwon and Buckmire 2004).

The ideal soft-tissue filler substance should be safe, biocompatible, nonmigratory, resistant to phagosytosis, pliable, and should persist and maintain its volume without being absorbed. Although a growing number of injectable substances have been developed and tested, no single substance has yet been able to fully meet all these criteria (Broder and Cohen 2006). The substances are categorized by the origin of material as synthetic material, xenograft, homograft (allograft) and autograft (Kwon and Buckmire 2004; Eppley and Dadvand 2006).

After the adverse foreign-body reactions related to Teflon® became apparent, research was directed to find a more biocompatible material. Autologous fat seemed to be attractive from many aspects. Initial clinical trials with humans reported good short-term outcome of autologous fat injection laryngoplasty (Mikaelian, Lowry et al. 1991; Brandenburg, Kirkham et al. 1992). However, a later study has shown an unpredictable rate of absorption of fat after three months (Shindo, Zaretsky et al. 1996). In many cases, repeat injections are necessary to maintain adequate vocal fold bulk (Kwon and Buckmire 2004). The unpredictable long-term outcome has advocated opinions that fat injection is not a preferable method of surgery in UVFP (McCulloch, Andrews et al. 2002; Laccourreye, Papon et al. 2003). Some authors still see the potential in the fat graft, once specific technical details are taken into consideration (Sataloff 2005).

Another autologous graft, free fascia, was proposed for injection laryngoplasty to address the poor persistence of fat in the larynx (Rihkanen 1998). Autologous free fascia transplantation has been used in plastic, reconstructive, and head and neck surgery for a century (Boyce, Nuss et al. 1994). Fascia has been proven to be a stable and predictable graft material for various head and neck indications and suitable for augmentation of small-volume soft-tissue defects (Miller 1988). Theoretically, fascia was thought to be more stable than fat in the larynx, while having the advantages of autologous grafts being safe, of low cost, readily available, biocompatible, and pliable.

After the initiation of this work in 1998, several new biomaterials have been introduced for injection laryngoplasty in humans including homologous collagen, Cymetra (Pearl, Woo et al. 2002), autologous collagen (Ford, Staskowski et al. 1995), and xenologous hyaluronic acid (Hertegard, Hallen et al. 2004). All have been reported to offer satisfactory vocal results in short-term studies, but long-term studies are lacking.

The aim of this work was to study the suitability of minced autologous fascia in the treatment of UVFP with injection laryngoplasty. The injectable substances available by 1998 had problems related either to poor biocompatibility (Teflon®, silicone) or unpredictable persistence in the larynx (fat, bovine collagen). Autologous fascia grafts had previously been well-tolerated and stable in the head and neck surgery, but had not been grafted in processed form into a host tissue exposed to mechanical strain.

2 Review of the literature

2.1. Transplantation of autologous fascia

2.1.1. Fascia grafts in the head and neck surgery

Otolaryngologic, plastic and reconstructive surgery of the head and neck region embraces a number of situations that may call for reconstruction or augmentation using a soft-tissue substitute. The perfect autologous graft should have the following characteristics: easily accessible and available in large quantities; little donor site morbidity; nonmutagenic; sustain a low infection rate; easily tailored and sculptured; and finally, sustain a low or at least predictable resorption rate (Boyce, Nuss et al. 1994).

Unfortunately, no single material universally satisfies these requirements, although fascia has some unique advantages. Results of fascia grafting are quite predictable and often gratifying (Boyce, Nuss et al. 1994). Therefore, fascia transplantation has been used over a century for a variety of indications in the head and neck surgery. Common clinical examples, which take advantage of fascia´s tensile strenght include tympanoplasty, correction of facial paralysis, replacement of dura after trauma or tumor surgery, and correction of ptosis. Fascia has also been employed as “filler” to augment small-volume soft-tissue defects in aesthetic applications such as the nasal dorsum, the nasal tip, the nasolabial angle, the thin lip and the underprojected chin.

Autologous fascia can be harvested from multiple donor sites: fascia lata in the lateral thigh; aponeurosis of the anterior abdominal wall, rectus abdominis sheath and the temporal region (superficial and deep temporal fascia). Fascia lata is perhaps the best site for augmentation purposes, because here the fascia is thick and can be harvested in large amounts without considerable donor site morbidity (Boyce, Nuss et al. 1994). Major disadvantage is a scar on the thigh, which can be sometimes aesthetically objectionable. In the head and neck surgery, the need for operating on a remote surgical site may also be considered time-consuming and adding to morbidity. Therefore, temporal fascia is favoured by some surgeons (Miller 1988).

In terms of recipient site characteristics (sterility, hemostasis, mobility of the recipient area, quality of the recipient bed) transplanted fascia seems to have modest demands. As a free tissue transplant, fascia requires some vascularity from the recipient bed in order to survive. However, this need seems to be less pronounced for fascia than for other graft types. Complications of fascia transplantation are uncommon. Single-layer fascia grafts are remarkably tolerant of local inflammation (Guerrerosantos 1991) and can be applied to contaminated and infected tissues. For example, fascia is used as a tympanic membrane graft after mastoidectomy for chronic ear infection. The risk of infection probably increases with growing thickness of the graft because of reduced vascularity to the central portion of the transplant (Boyce, Nuss et al. 1994). The main limitation of free fascia transplantation is the lack of three-dimensional bulk restricting its use to relatively small-volume defects.

2.1.2. Histology of the transplanted autologous fascia

Recipient site characteristics play a major role in the survival of tissue transplants. An animal model is often applied to study the tissue reactions between the host and the graft. Histological evaluation of harvested grafts usually includes assessment of the degree of inflammation, preservation of tissue structure, the presence of nuclei within the cells of the transplanted tissue and the degree of neovascularization. Examination of normal fascia shows a single cell type, the fibroblast, and an intercellular matrix composed of collagen. It is probably because of this simple basic structure, combined with low metabolic rate, that fascia can be transplanted without major alterations in its form and function (Peer 1959).

A controlled animal study compared how the form of the graft and the vascularity of the recipient site affect the fate of the fascia transplant. Single-layer and four-layer autologous grafts of thoracodorsal fascia were transplanted either on the cranial bone (nonvascularized) or the cranial periosteum (vascularized) of rabbits. From the histological examination it was evident that multi-layered fascia grafts or single-layer grafts placed directly on bone do not survive as viable tissue. The collagen structure appeared to be maintained without preservation of viable fibroblasts and any ingrowth of a new vascular supply. In contrast, in the single layer graft placed on the vascular periosteum, the tissue viability was maintained. The multi-layered graft maintained its bulk, and together with the lack of inflammatory infiltrate this indicates that the breakdown or turnover of collagen within this avascular matrix was extremely slow. This was interpreted to support the use of multi-layered grafts when only bulk is desired. In other words, the fascia graft survival was not dependent on the viability of its cellular elements (Das, Davidson et al. 1990).

In humans, temporal muscle fascia applied to augmentation of the nasal dorsum has been reported to undergo approximately a 20 % shrinkage of bulk in the first 4 to 6 weeks postoperatively based on a visual estimate and remain stable thereafter. It was deduced from the histological sections that the shrinkage was the result of compaction and condensation of the graft rather than resorption. No inflammation or encapsulation was seen clinically or histologically (Miller 1988).

The physical forces to which the graft is exposed to may challenge its survival in various ways. When used for tensile applications as a single-layer graft it is essential that a strong healing can occur between the fascia transplant and its bed in order for it to withstand the anticipated strain (Gallie 1948). A study with dogs demonstrated how grafted autologous fascia heart valves deteriorated in 8 weeks when exposed to the blood stream. Fascia lost the adhering layer of fibroblasts and surface compounds. The collagen scaffold of the graft was laid bare and liable to further breakdown by endothelialization and collagenase secretion of the invading cells (Bharadwaj, Kurylo et al. 1975).

2.1.3. Fascia grafts in the larynx

The vocal fold forms a unique physiological environment for any tissue transplant. It is a dynamic structure even when paralyzed. Changes in subglottal air pressure on coughing and phonation, and movement of the larynx during swallowing predisposes the graft to mechanical strain. Mobility of

the recipient area has been reported to affect the outcome with fat transplants by disturbing the formation of vascular anastomoses (Peer 1959). Studies with transplanted fascia have been conducted by placing the graft into relatively static areas of the body. Before our series of ILAF, extreme processing of the fascia graft before transplantation had not been studied. Most experiments had been conducted with fascia grafted in a single-layer or, at the most, rolled, bunched or layered. Mincing the fascia before injection disrupts its infrastructure, and theoretically, could have exposed collagen and other components of connective tissue to proteolytic activity. This might have had a negative effect on the outcome of ILAF.

Another phonosurgical technique taking advantage of autologous fascia has been developed to treat vocal fold sulcus and scarring (Tsunoda, Takanosawa et al. 1999). The graft is harvested from the temporal fascia. Under suspension microlaryngoscopy, an incision is made on the lateral aspect of the vocal fold and a pocket is undermined under the sulcus or scarred vocal fold mucosa. A single-layer fascia graft is dried and trimmed, and transplanted into the pocket. After extrusion of the graft during coughing, the authors recommended suturing the incision. Complete voice rest for two weeks after the procedure is recommended. Outcome measurements showed excellent results in nine patients with a follow-up between 1-3 years (Tsunoda, Baer et al. 2001). Temporal fascia appeared to be suitable for transplantation into the Reincke´s space with a low risk of infection. The authors even speculate that transplantation leads to regeneration of vocal fold tissue by a mechanism similar to stem cell transplantation, since the results in MPT and stroboscopy continued to improve beyond one year. Long-term results of ten patients treated for sulcus vocalis with a follow-up of at least 3 years has been reported. The improvement in MPT was significant ($p < .01$) at three years and “satisfactory glottal closure and excellent mucosal wave were observed for all cases” in stroboscopy at one year. The authors performed immunohistologic staining of an extruded fascia specimen with the anti Ki-67 antibody. High proliferative activity in the fibroblasts of transplanted fascia was recognized. This may indicate that autologous fascia graft in the superficial lamina propria of the vocal fold can induce production and proliferation of extracellular matrix (Tsunoda, Kondou et al. 2005).

2.2. Unilateral vocal fold paralysis

2.2.1. Definitions and terminology

Vocal fold paralysis implies vocal fold immobility due to neurologic injury. Vocal fold paresis implies vocal fold hypomobility due to neurologic injury (Rubin and Sataloff 2007). Signs and symptoms of vocal fold paralysis depend on which nerve has been injured; the RLN or both RLN and SLN. The therapeutic strategies are different in unilateral or bilateral nerve injury. In this work the focus is on UVFP caused by an injury of the RLN or of both RLN and SLN.

2.2.2. Laryngeal anatomy and biomechanics

The larynx has complex functional demands in respiration, phonation, stabilization of body core during physical activity, and airway protection during swallowing. A thorough understanding of vocal fold anatomy (histologic and gross) and physiology is required to optimize treatment outcome for patients with vocal complaints. Adequate respiratory support, appropriate glottal closure, normal vocal fold cover, and control of vocal fold length and tension are required for normal phonation (Noordzij and Ossoff 2006).

The larynx is innervated by the RLN and the SLN, which both are branches of the tenth cranial nerve, the VN. The motor branches of the VN originate from the nucleus ambiguus in the medulla of the brain stem. The VN exits the skull through the jugular foramen together with the glossopharyngeal (IX) and accessory (XI) cranial nerves. The SLN is divided from the VN just below the inferior (nodose) ganglion. The external motor branch of the SLN descends below the thyroid cartilage into the cricothyroid muscle. The sensory internal branch pierces the thyrohyoid membrane along with the superior laryngeal artery and supplies the sensation of the supraglottal larynx. The RLN axons travel with the VN down the neck until they branch off at the level of the subclavian artery on the on the right, and the aortic arch on the left. Both RLNs travel upwards (cranially) lateral to the tracheoesofageal groove and enter the larynx behind the cricothyroid joint. The RLN is the principal motor nerve of the intrinsic muscles of the larynx and responsible for sensation of trachea below the glottis and upper esofagus (Rubin and Sataloff 2007).
Embryology explains the difference in the course of the recurrent nerves. In the embryo, the left RLN curves around the ductus arteriosus, which is eventually located caudal to the arch of the aorta. On the right, the proximal part of the sixth aortic arch forms the right pulmonary artery, and the distal part of the sixth aortic arch loses its connection with the embryonic dorsal aorta, and disappears. The right RLN is then able to curve around the more cranial artery of the fourth aortic arch, the subclavian artery (Langman 1969). It is noteworthy, that 5 out of 1000 people have a nonrecurrent laryngeal nerve on the right (Rubin and Sataloff 2007).

The RLN contains from 500 to 1000 motor axons, most of which pass to the adductor muscles of phonation; the thyroarytenoid (TA), the interarytenoid (IA) and the lateral cricoarytenoid (LCA). About one fourth of the fibers are destined to the sole abductor muscle, the posterior cricoarytenoid (PCA), which opens the glottis for inspiration. The innervation of the intrinsic laryngeal muscles is unilateral except for the IA, which receives contributions from both RLNs. Each RLN is also thought to contain fusimotor efferent axons as well as vasomotor and secretomotor fibers of symphatetic and parasymphatetic origin (Crumley 1989). To a lesser degree, extrinsic laryngeal muscles also affect vocal fold shape and movement. The strap muscles, innervated by the ansa hypoglossi act as accessory muscles of forced inspiration (especially the sternothyroid muscle) while the thyrohyoid muscle is accessory to phonation and other adductive functions (Crumley 1985).

The cover-body theory and aerodynamics explain the vocal fold vibration. Vocal fold body, formed primarily by the TA muscle, is responsible for most of the transverse motion of the vocal fold. The looser mucosal cover forms the travelling mucosal wave (Hirano and Kakita 1985).
Aerodynamically, the conical shape of the larynx and adducted vocal folds increase air stream

velocity at the rima glottidis during phonation. Increased velocity in turn creates a negative air pressure on the medial edge of the vocal fold according to the law of Bernoulli. This suction effect combined with the myoelastic properties of the vocal fold and the constant air stream is the driving force of vibration. The mucosal wave is present only if there is a pliable mucous membrane covering the vocal fold, but active neuronal activity of the muscle is not a prerequisite of vocal fold vibration per se (Kokesh, Flint et al. 1993). Histologically, the vocal fold consists of five layers: the squamous epithelium, the superficial-, intermediate- and deep layer of lamina propria, and the TA muscle. The extracellular matrix of the lamina propria is mainly responsible for the elasticity of the vocal fold cover and its optimal vibratory characteristics (Noordzij and Ossoff 2006). Any surgical intervention to enhance voice production must retain this elasticity and avoid damage to the undulating cover.

2.2.3. Incidence, etiology and prognosis

The incidence of UVFP has not been established, although it is fairly often encountered by otolaryngologists (Benninger, Crumley et al. 1994; Rubin and Sataloff 2007). The most common causes of RLN injury are tumour infiltration or compression 40 % (brain stem, neck, chest, mediastinum), surgical trauma 35 % (thyroid, anterior cervical spine, chest), trauma (mostly intubation) 8%, and idiopathic 11 % (Terris, Arnstein et al. 1992). Others include cerebrovascular accidents, CNS tumours, bulbar lesions, neurodegenerative disease, infectious causes and several systemic diseases (Rubin and Sataloff 2007). When the cause of paralysis remains unclear, it is termed idiopathic; some suspect infection (Lyme disease, Epstein-Barr and herpes virus). Idiopathic causes are probably more common than reported because they may resolve spontaneously before patients seek medical attention (Benninger, Crumley et al. 1994).
The natural history of vocal fold paralysis depends on the mechanism and degree of injury to the nerve. The clinical course is determined by the degree of reinnervation and synkinesis. The Sunderland classification system describes five different degrees of neural injury (Sunderland 1978). Neurapraxia (1. degree) and axonotmesis (2nd degree) injuries should recover completely. Third-degree injury includes endoneural scarring, which can cause misdirected regeneration known as synkinesis. Synkinesis results from nonselective innervation of adductor and abductor muscles. As a result, muscles that perform opposite functions contract simultaneously, resulting in immobility or hypomobility of the vocal fold. A classification system for laryngeal synkinesis has been described (Crumley 2000). Fourth-degree injury involves scarring that blocks regenerating axons and fifth-degree injury signifies complete transection of the nerve.

With idiopathic paralysis the prognosis is difficult because of marked variation in degrees of neural injury and rates of spontaneous recovery. Generally, a period of one year is waited before irreversible surgical treatment decisions are made (Rubin and Sataloff 2007; Sulica 2008).

2.2.4. Symptoms and laryngologic findings

The main complaint of patients with UVFP is a breathy, weak or even aphonic voice. The open glottal gap constitutes the greatest physical factor that compromises voice quality. Failure to close the glottis may also lead to dysphagia with aspiration; inability to cough and shout; dyspnoea and

fatigue related to lifting and straining. Patients who have vocal fold paralysis deserve comprehensive evaluation, which begins with a thorough history and meticulous physical examination followed by adequate CT or MRI imaging to define the cause of the paralysis (Terris, Arnstein et al. 1992; Rubin and Sataloff 2007).

Videostrobolaryngoscopy provides invaluable visual information of the vocal fold motion and vibratory characteristics of the vocal fold mucosa in slow motion allowing meticulous analysis and a permanent document. The vocal fold movement and vibration is evaluated during various phonatory tasks at several frequencies and intensities. The laryngologist should look for asymmetric movement, vocal fold bowing, horizontal and vertical position of the vocal folds, and tilting of the posterior larynx (Rubin and Sataloff 2007). Depending on the site and extent of injury, degree of reinnervation, synkinesis, and compensation, findings vary among individual patients (Benninger, Crumley et al. 1994). In unilateral RLN injury, the vocal fold remains in different stages of lateral position (mostly a paramedian position) and only slight, if any, movement of the fold is detectable during phonation. Due to the loss of tone and mass of the body (TA muscle), the vocal fold is flaccid with concave bowing. The difference in length and tone of the vocal folds leads to asymmetry that alters the vibratory characteristics, and is seen under stroboscopic light as aperiodicity of frequency and asymmetric amplitude of the mucosal wave. A high vagal lesion combines the effects of SLN and RLN paralysis with enhanced flaccidity and bowing, and a wide glottal gap. A shift of the posterior glottis to the side of the SLN injury may be seen. Vagal paralysis also leads to a difference in the vertical position of the vocal processes of the arytenoid cartilages. Therefore, surgical procedures that address this vertical disparity are more effective in improving glottic closure and vocal quality (Isshiki, Tanabe et al. 1978; Benninger, Crumley et al. 1994).

Vocal fold position alone does not allow determining the site of the neurological lesion. In many cases, laryngeal EMG is considered helpful in confirming the clinical impressions. It is of special value in cases of arytenoid fixation, dislocation or subluxation, which are frequently mistaken for vocal fold paralysis (Woo 1998; Rubin and Sataloff 2007).

2.3. Role of voice therapy in treatment of UVFP

Minimal outcome and efficacy data on voice therapy for UVFP are available (Behrman 2004; Miller 2004). Only two nonrandomized retrospective studies comparing the efficacy of voice therapy with surgical treatment have been published (Heuer, Sataloff et al. 1997; Kelchner, Stemple et al. 1999). Heuer et al. studied 41 patients with UVFP of whom more than half elected to have voice therapy instead of surgery. Outcome measure data showed similar satisfaction in the therapy and surgery groups, though post treatment objective measures were not obtained. Kelchner et al. conducted a review of 25 patients. Post treatment stroboscopic examination and perceptual assessment of voice revealed comparable outcomes between surgery (N=13) and voice therapy (N=6). Both studies have been criticized for selection bias, since patients who elected voice therapy had less severe laryngeal dysfunction based on the pre-treatment evaluation. In cases where voice therapy yields improved voice, it is unclear whether it is a result of increased phonatory closure or improved compensatory techniques (Behrman 2004).

Even though the effect of voice therapy in the management of UVFP remains unclear, it is considered invaluable for several reasons (Benninger, Crumley et al. 1994; Miller 2004). Teamwork between the ENT-surgeon and the speech therapist is emphasized. A speech therapist can not only quantify and document vocal dysfunction preoperatively, but also explore useful compensatory vocal strategies for the patient. Educating the patient about laryngeal functions, his/her specific abnormality, environmental manipulation, and vocal hygiene, relieves the anxiety and exhaustion related to this disorder (Miller 2004). In addition, undesirable hyperfunctional phonation may be identified and corrected. It is common compensatory behaviour, and considered responsible for most of the voice strain, neck discomfort, and fatigue that often accompany UVFP. Also an estimate of how much the patient´s voice can be improved without surgery can be attained. Generally, several therapy sessions are needed to optimize the vocal function by progressive development of optimal breathing, abdominal support and intrinsic laryngeal strength and agility. In cases with mild to moderate glottal insufficiency, voice therapy alone may result in sufficient improvement of voice quality, avoiding the need for surgery (Benninger, Crumley et al. 1994; Miller 2004).

If surgery is eventually required, preoperative voice therapy helps the patient while surgical decision is pending, provides training for optimal postoperative phonation, and prepares the patient psychologically for surgery (Benninger, Crumley et al. 1994). Postoperatively, a few sessions of voice therapy beginning 1 to 2 months after successful surgery is advocated to help the patients adapt their manner of voice production to a new mechanical condition (Isshiki 1998).

2.4. Surgical treatment of UVFP

After failure of spontaneous recovery, compensation by accommodation, or appropriate voice therapy, surgical intervention may be considered. The timing and the method of surgery is based on the patients´ voice needs and desire for improvement to accomplish their vocational, occupational or social functions. The two main surgical options for UVFP are medialization and reinnervation. Medialization procedures include laryngeal framework surgery (thyroplasty type I and arytenoid adduction) and injection laryngoplasty (Rubin and Sataloff 2007). The percentage of patients requiring surgery for UVFP is rarely reported. In one series of 160 patients with RLN paralysis, 20 % of patients opted for surgery after unsatisfactory voice therapy outcome (Heuer, Sataloff et al. 1997).

2.4.1. Injection laryngoplasty

Injection laryngoplasty (IL) has long been an integral part of the therapeutic armamentarium for managing vocal fold paralysis. UVFP results in a glottal gap of variable width. Augmentation of the paralyzed fold by injection shifts it towards midline permanently and aims to improve glottal closure. Most ENT-surgeons prefer to inject materials into the vocal fold under general anesthesia with a rigid suspension endoscope and a specially designed syringe holder under microscopic control. Under local anesthesia a transcutaneous route through the thyroid cartilage or the cricothyroid membrane, with telescopic or flexible fiberoptic laryngoscopic control is possible.

Also transoral injection with indirect mirror guidance is an option in the out-patient setting (Sataloff 2005).

The potential advantages of IL include wide availability in many clinical settings, relative technical ease, low procedural cost and low morbidity. Avoidance of an open surgical procedure, as well as the option to the out-patient clinical setting makes it an appealing treatment modality to a wide spectrum of otolaryngologists (Kwon and Buckmire 2004).

IL was first introduced in 1911 using paraffin as injection material (Bruning 1911). Difficulties encountered with this synthetic material in other parts of the body (foreign-body reactions, extrusion, migration, and inflammation) led to abandonment of the technique also in the larynx for decades (Dedo, Urrea et al. 1973). Intracordal injection was revived in the 1950s by experiments with autogenous cartilage and bone dust (Arnold 1955). Since then several synthetic and biologic materials have been used for vocal fold augmentation and the search for an ideal injection substance still continues.

Appropriate patient selection is crucial for a successful outcome. The ideal patient presents with a complaint and is motivated to seek improvement. Patience may be required along the course of this treatment, since the major disadvantage of most injectable substances has been the resorption over time. This creates the necessity for either re-injection or calculated over-injection initially to account for the projected loss of augmentation volume. Consequently, the best voice result is temporarily delayed or, at worse, transient (Kwon and Buckmire 2004).

Another major limitation for IL is a large posterior glottal gap. Although some medialization of the affected arytenoid is possible by IL, it is not as precise as an open surgical approach such as arytenoid adduction. Medical comorbidities are generally not considered contraindications for IL. It is also suited for selected patients, such as vocal professionals in need of a temporary relief of symptoms, when a full functional recovery of paralysis is expected. Endoscopic injection techniques are also preferred to open surgery in patients with previous irradiation of the larynx, and active, or obstructing nonoperative disease (lymphoma, extensive fibrosis). IL can also be applied to other forms of glottal insufficiency such as vocal fold bowing or scarring (Kwon and Buckmire 2004).

The ideal injection material should be biocompatible; easily injectable; readily available with minimal preparation for optimal time efficiency and have the potential for application in outpatient office setting; comply with the biomechanical properties to the vocal fold; have a low resorption rate; be resistant to migration and easily removable. At the moment, there exists a great diversity of substances available for IL. They are categorized by the origin of material as synthetic materials, xenografts, homografts and autografts (Kwon and Buckmire 2004).

Synthetic materials

Synthetic substances are easily injected, readily available and provide permanent augmentation. After experiments with several substances Teflon® emerged as the material of choice (Arnold 1962) and it became the favoured injection substrate for decades (Dedo, Urrea et al. 1973). Its permanence, ease of preparation and injection made IL available to many otolaryngologists. However, several long-term side effects became apparent. Complications with Teflon® were

related to the operative technique, migration of particles and giant-cell foreign-body reaction with granuloma formation.(Rubin 1965b; Lewy 1983; Varvares, Montgomery et al. 1995). Removal of Teflon® at revision surgery proved to be difficult (Netterville, Coleman et al. 1998). Due to these problems, Teflon® has been excluded from the practise of modern laryngology (Kwon and Buckmire 2004).

Injectable silicone was first introduced in the early 1960s (Rubin 1965a). In a large series of 240 patients good vocal results with only one granuloma formation were reported using transcutaneous silicone injection through the cricothyroid space under local anaesthesia and monitoring the amount of augmentation by means of transnasal laryngeal fiberoscope (Hirano, Mori et al. 1995). However, findings of substantial foreign-body giant cell reactions have led the FDA to declare the use of silicone for IL illegal in the United States (Kwon and Buckmire 2004). Regardless of this, silicone is still widely used in many other countries.

During this decade, several new synthetic injectable materials have undergone trials in an effort to develop implants with improved biocompatibility and longevity. Injectable calcium hydroxylapatite (CaHA) particles have been studied in a canine model. CaHA was well-tolerated, no migration to the lymphatic system and no resorption of particles was noted (Chhetri, Jahan-Parwar et al. 2004). Short-term results with a small group of patients who underwent injection with CaHA particles showed improved voice quality in one study (Rosen and Thekdi 2004). A work with polydimethylsiloxane (PDMS) particles injected into the paraglottic space under microlaryngoscopy and general anaesthesia was conducted to study the morbidity and voice quality of patients. No complications attributable to PDMS particles occurred. Voice quality was comparable to other methods in a 4 month follow-up (Sittel, Echternach et al. 2006). Polyamide acryl hydrogel is widely used as permanent facial tissue filler in plastic surgery. A preliminary study shows that it is suitable also for injection laryngoplasty (Lee, Son et al. 2007). In conclusion, initial results with new synthetics are promising, but all of these studies share the same shortcomings of limited follow-up and small cohorts. Permanence of augmentation and possible foreign-body reactions need yet to be studied.

Xenologous grafts

Bovine collagen and hyaluronic acid are xenografts with similar theoretical advantages in this indication; both are readily available and viscoelastic properties are good. Bovine collagen (Zyderm®) was first introduced in the larynx in 1986 with good vocal results initially (Ford and Bless 1986). Since its introduction the use of bovine collagen has been controversial due to hypersensitivity reactions that have been encountered from 0% to 9.8% of patients ranging from local erythema and itching to occasional systemic reactions such as arthralgia, arthritis, fever, urticaria and generalized swelling (Anderson and Sataloff 2004). Skin testing 4 weeks prior to operation was recommended, but negative skin-test did not assure clinical non-reactivity (Courey 2001). High resorption rate of non-cross-linked collagen also became evident. The bovine collagen implant is sensitive to the collagenase secreted by host fibroblasts. To address this, the use of glutaraldehyde-cross-linked (GAX) collagen (Zyplast®) was developed. The cross-linking makes the implant practically insensitive to collagenase, improving the stability of augmentation, and hypersensitivity rate was also reduced to less than 1% (Remacle, Dujardin et al. 1995). Bovine collagen never received FDA approval for intralaryngeal use partly because of concerns about the delayed hypersensitivity reactions on the laryngeal airway (Anderson and Sataloff 2004). Another

concern with bovine collagen is the development of autoimmune collagen vascular diseases. A higher incidence of dermatomyositis and polymyositis in patients exposed to bovine collagen has been reported than would be expected in the general population (Anderson and Sataloff 2004). Bovine spongiform encephalopathy (mad cow disease), also became an issue of major concern in the 1990s.

Hyaluronic acid (HA) is a polysaccharide and a universal component of the extracellular matrix with two commercially available products. Hylan-b gel is an extract derived from rooster combs and therefore not recommended for patients allergic to avian products. Restylane is produced by microbiologic engineering techniques (Kwon and Buckmire 2004). Vocal results of Hylan-b gel compared well to bovine cross-linked collagen in one study (Hertegard, Hallen et al. 2004). Restylane-related granulomatous foreign-body reaction has been reported in plastic lip augmentation despite of its proposed nonantigenic properties (Fernandez-Acenero, Zamora et al. 2003).

Homologous grafts (allografts)
The adverse effects related to collagen particles from foreign species led the biomedical industry to search for human form of collagen for injection. Two homologous grafts, Dermalogen® (Collagenesis, Beverly, MA) and Cymetra® (LifeCell Corp., Palo Alto, Calif.), have been developed. Dermalogen is not presently available. Cymetra® is an injectable form of micronized Alloderm that is made of cadaveric dermal tissue processed to remove all the cellular components thereby reducing the risk of host versus graft reaction. Preliminary short-term follow-up studies support the biocompatibility of Alloderm (Pearl, Woo et al. 2002; Karpenko, Dworkin et al. 2003; Milstein, Akst et al. 2005). The permanence of augmentation with Alloderm was contradictory in two short-term studies (Pearl, Woo et al. 2002; Karpenko, Dworkin et al. 2003). A later study with an average of 11 month follow-up suggested that stability of medialization with Alloderm may last longer than previously reported (Milstein, Akst et al. 2005). A report of abscess formation in the vocal fold after injection of micronized Alloderm has been published (Zapanta and Bielamowicz 2004). Further long-term studies are warranted. Like bovine collagen, Cymetra can be administered in several ways through a thin needle: trancutaneously, transorally or through a rigid laryngoscope in the operating room. Disadvantages include high price and a theoretical disease transmission risk (HIV, hepatitis etc.).

Autologous grafts
Autograft is optimal in terms of biocompatibility, easy availability and low cost. Efforts with autologous cartilage and bone dust in the 1950s were not satisfactory (Dedo, Urrea et al. 1973). Hence, autografts were abandoned for decades until autologous fat was tested in an animal model (Hill, Meyers et al. 1991; Zaretsky, Shindo et al. 1995). Clinical trials in humans with fat injection in UVFP showed promising vocal results (Mikaelian, Lowry et al. 1991; Brandenburg, Kirkham et al. 1992). Fat is easily harvested from the abdominal skin, has feasible viscoelastic properties, is easily injected, and well tolerated by the vocal fold. The main disadvantage of fat is an unpredictable absorption after three months, which suggested fat as the ideal method for temporary vocal fold medialization in patients in whom return of vocal fold motion is expected (Shindo, Zaretsky et al. 1996). Although the rate of resorption expresses high variability between individuals, in many cases repeat injection procedures are necessary to maintain adequate vocal fold bulk (Kwon and Buckmire 2004). Efforts to enhance fat graft survival have been reported in animal

studies. A study with rabbits compared graft volume survival at 6 months using standard fat injection and injection of preadipocytes into the vocal fold. Preadipocytes are precursor cells that are capable of replication and differentiation into mature adipocytes. Injecting preadipocytes did not enhance graft survival. In rabbits, graft volumes obtained with standard fat injection were superior to the ones obtained by preadipocyte injection (Glatz, Kalkanis et al. 2003). The lack of stability has promoted opinions that fat is not optimal in the treatment of UVFP (McCulloch, Andrews et al. 2002; Laccourreye, Papon et al. 2003). However, the use of fat in UVFP is still widespread, and advocated in a recently published textbook of voice surgery, once specific technical details such as patient selection (small glottal gap), non-traumatic harvesting, site of injection and 30 % over-correction initially are carefully considered (Sataloff 2005).

Autologous collagen (Autologen®, Collagenesis, Beverly, Massachusettes) was introduced at first to treat patients with vocal fold scarring, atrophy, and focal defects (Ford, Staskowski et al. 1995). Autologous collagen-fiber injectate was prepared from a graft harvested under local anesthesia from the patient´s own abdominal skin and shipped to the biotechnical company for processing, which took 3-4 weeks. Autologen could then be stored in refrigerator temperatures for up to six months. Injection into the vocal fold in an out-patient setting transorally was performed later through a fine 27-gauge to 30-gauge needle. Autologous collagen is no longer commercially available (Remacle, Lawson et al. 2006).

The origin, composition, and permanency of different injection materials are summarized in Table 1

Table 1. Comparison of currently available materials for Injection Laryngoplasty

Material®	Composition	Origin	Permanency	Anaesthesia	Technique
Autologous					
Fascia	viable fibrocytes, collagen matrix	fascia lata, thigh	stable with some resorption	G	RE
Fat	fat tissue	abdominal fat	unpredictable resorption	G	RE
Homologous					
Cymetra	micronized acellular collagen	human cadaveric skin	stable?	G	RE
Xenologous					
Restylene	hyaluronic acid	fermentation in cultures of equine streptococci	resorbed in months		
Hylaform	hyaluronic acid	rooster combs	resorbed in months	G and L	TO, TC
Zyderm	collagen	bovines	resorbed in months	G and L	TO, TC
Zyplast	glutaraldehyde cross-linked collagen	bovines	stable	G and L	TO, TC
ArteFill, Artecoll	bovine collagen with PMMA beads	bovine calf skin	stable?	G and L	TO, TC
Synthetic					
Radiesse	CaHa spheres in a polysaccharide gel with glycerin	calcium hydroxylapatite (CaHa)	permanent	G	RE
Vox implants	PDMS particles in PVP hydrogel	polydimethylsiloxane (PDMS)	permanent	G	RE
Aquamid	PAAG hydrogel	cross-linked polyacrylamide (PAAG)	stable?	L	TC

PMMA, polymethylmethacrylate; PVP, polyvinylpyrrolidone

G=general
L=local

RE=rigid endoscope
TC=transcutaneous
TO=transoral

2.4.2. Laryngeal framework surgery

Laryngeal framework surgery is divided mainly into thyroplasty type I and arytenoid adduction/rotation. Both techniques were conceptualized and described in two landmark articles by the same author (Isshiki, Morita et al. 1974; Isshiki, Tanabe et al. 1978). However, the first description of laryngeal framework surgery dates back a century (Payr 1915). A number of subsequent authors described variations including a Finnish pioneer of otolaryngology (Meurman 1952). Meurman named his technique mediofixation of the vocal cord. He transplanted a piece of costal cartilage, which was inserted subperichondrially between the thyroid cartilage ala and the internal laryngeal muscles of the paralyzed side through an anterior laryngofissure under local anesthesia. Laryngeal framework surgery was popularized in the United States by Koufman, who also introduced the term medialization laryngoplasty to describe all types of surgical manipulations to medialize the vocal fold (Koufman 1986).

Thyroplasty type I with or without arytenoid adduction is currently considered as the gold standard against which all other methods of surgical treatment of UVFP are judged (Bielamowicz 2004; Kwon and Buckmire 2004). Thyroplasty type I essentially involves medialization of the vocal fold by its inward displacement with an implant placed through a window in the thyroid cartilage lamina. The procedure is performed under local anesthesia from an incision on the neck using the patients´s vocal feedback to determine the ideal size of the implant. Nasofiberoptic visual control can also be useful. This adjustability together with reversibility are quoted to be the greatest advantages of thyroplasty type I (Koufman 1986). Various modifications of the operative technique (Netterville, Stone et al. 1993; Montgomery and Montgomery 1997) and the implant material have been introduced over the years. Silicone (Koufman 1986), hydroxylapatite (Cummings, Purcell et al. 1993), expanded polytetrafluoroethylene or Gore-Tex® (McCulloch and Hoffman 1998) and titanium (Friedrich 1999) have all been reported as prosthesis materials with minor morbidity. Resorption is not a problem with artificial implants, and vocal results are long-lasting in the treatment of glottal insufficiency (Lu, Casiano et al. 1996; Lundy, Casiano et al. 2000; McCulloch, Hoffman et al. 2000; Laccourreye, El Sharkawy et al. 2005; Dursun, Boynukalin et al. 2008). Disadvantages of this method include the demand for advanced technical skill of the surgeon, postoperative oedema and haematoma with a possible airway compromise, wound infection, mucosal perforation and dislodgement or extrusion of the implant (Harries 1996). Many surgeons prefer to use steroids and antibiotics routinely to avoid immediate postoperative complications (Sataloff 2005).

The main methodical drawbacks of thyroplasty type I are inability to correct a wide posterior glottal gap and a difference in the horizontal plane of the two vocal folds. These can be best addressed with arytenoid adduction, which is also performed under local anesthesia through a skin incision at the level of the larynx (Isshiki, Tanabe et al. 1978). Two nylon sutures are placed in the muscle process of the arytenoid cartilage. The sutures are then passed through the thyroid lamina and tied on it. The sutures pull the muscle process anteriorly rotating the arytenoid to the adducted position thereby closing the gap between the vocal folds posteriorily. As the vocal fold is adducted, the vocal process of the arytenoid simultaneously moves downward correcting the horizontal plane as well (Isshiki, Tanabe et al. 1978). The voice can be fine-tuned by adjusting the tightness and direction of the sutures based on vocal feedback. Since atrophy of the TA muscle usually results

from recurrent nerve paralysis, thyroplasty type I or IL is added to arytenoid adduction to restore the volume of the vocal fold for optimal vocal performance (McCulloch, Hoffman et al. 2000). Cricothyroid subluxation and adduction arytenopexy (Zeitels 2000) are alternative techniques with a similar goal as arytenoid adduction.

2.4.3. Laryngeal reinnervation

The ideal goal of treatment should be the return of normal function. None of the previously described surgical techniques restore that. In theory, reinnervation of the paralyzed vocal fold would mend all malfunctions simultaneously with return of movement, mass, and tone. Laryngeal reinnervation, however, has proved to be difficult. The main purpose of a reinnervation procedure is to prevent denervation atrophy of laryngeal muscles. Return of movement is not achieved. Several reinnervation procedures for the paralyzed vocal fold have been described using anastomosis of the recurrent nerve to the ansa cervicalis, phrenic nerve, preganglionic symphatetic neurons, hypoglossal nerve, and nerve-muscle pedicles (Rubin and Sataloff 2007).

Attempting a direct nerve anastomosis of the RLN often leads to laryngeal synkinesis (Crumley 1985). Reinnervation using the anastomosis of the ansa cervicalis to the recurrent nerve provides weak tonic innervation to the intrinsic laryngeal muscles without return of movement. It is reported to improve vocal quality and restoration of the mucosal wave (Crumley 1991). Nerve-muscle pedicle technique involves implanting a piece of strap muscle innervated by the ansa cervicalis into one of the denervated laryngeal muscles, usually the LCA or TA (Tucker and Rusnov 1981; Tucker 1989). The results of the nerve-muscle pedicle technique can be further improved by combining medialization to reinnervation (Tucker 1999). Selective reinnervation of the abductor and adductor muscles of the larynx has been introduced with the intent of restoring bidirectional motion of the vocal folds in bilateral vocal fold paralysis. The combination of phrenic reinnervation of the PCA (abductor) and ansa cervicalis reinnervation of the adductor group has been reported in an animal model (Crumley 1984; Marie, Dehesdin et al. 1989). Although not yet published, an impressive result of selective reinnervation in humans was presented at a voice surgery congress in Paris 3 April 2009 by Dr. Marie and his colleagues from Rouen, France. In a female patient with bilateral vocal fold paralysis after thyreoidectomy, the return of abduction and normal breathing without compromising voice had been achieved with this new technique. Another new promising technique of motion-specific laryngeal reinnervation has been demonstrated with cats by muscle-nerve-muscle neurotization. The paralyzed TA muscle is reinnervated by way of axons that sprout from the contralateral innervated TA muscle through an interposed nerve graft thus avoiding laryngeal synkinesis (Hogikyan, Johns et al. 2001).

2.4.4. Future perspectives

As the time span of this dissertation expands over a period of ten years, many new perspectives on surgery of UVFP have emerged. The “static” medialization procedures to restore the laryngeal function after UVFP have been challenged by efforts to develop a “dynamic” means. Selective reinnervation alone has not been universally accepted. Already two decades ago, high expectations were projected towards the rehabilitation of laryngeal nerve palsy by an implantable pacemaker for

direct recurrent nerve or intrinsic laryngeal muscle stimulation (Broniatowski, Tucker et al. 1990). Electrical pacing of the PCA muscle in humans has been reported in an effort to restore glottal opening in bilateral recurrent nerve paralysis (Billante, Zealear et al. 2002). An animal study evaluated the suitability of a deep brain stimulation electrode for laryngeal pacing (Katada, Van Himbergen et al. 2008). The conclusion was that this electrode could reanimate the PCA muscle to a normal level in a case of synkinetic reinnervation and to 60 % of the normal level in a case of complete denervation.

In the future, advances in vocal fold regeneration through tissue engineering may produce results that are applicable to everyday laryngological practice. Instead of simply replacing vocal fold tissues with implants and grafts of uncertain fate, the revised aim is to predictably regenerate normal tissue (Ford 2008). The rheological properties of extracellular matrix (ECM) are critical to vocal fold oscillation. The acellular components of ECM, proteoglycans and glycoproteins play a major role in ECM viscosity and hydration. Hyaluronic acid (HA), a glycoprotein, has a key role in preventing scarring and maintaining the viscoelastic properties of the vocal fold. Researchers now strive to develop a synthetic ECM uniquely suitable to the biomechanical strains of vocal folds (Thibeault and Duflo 2008). The capacity of hepatocyte growth factor to induce deposition of HA and reduce scarring in the vocal folds has been demonstrated (Hirano, Bless et al. 2004).

Another application of molecular biology, gene therapy, may be a useful adjunct to enhance nerve regeneration in the setting of trauma or neurodegenerative disease. Taking advantage of retrograde axonal transport, it is now possible to deliver genes encoding therapeutic growth factors to the CNS. Remote injection of viral vectors into the recurrent nerve to deliver neurotrophic factors to the nerve´s cell bodies within the nucleus ambiguus has been reported with rats (Heavner, Rubin et al. 2007). The aim is to promote nerve regeneration and enhance both nuclear and nerve survival. Another form of gene therapy, injection of human insulinlike growth factor 1 gene into the paralyzed thyroarytenoid muscle of rat has been documented (Shiotani, O'Malley et al. 1999). It is hoped to prevent or reverse muscle atrophy, and enhance nerve sprouting and muscle reinnervation thereby augmenting surgical treatment modalities.

2.5. Outcome evaluation of voice surgery

Assessment of voice pathology needs to be multidimensional. Objective measurements have been used in numerous clinical settings to compare pre treatment to post treatment phonatory characteristics after a specific surgical intervention. A basic protocol for assessing voice treatment effect has been proposed by The European Laryngological Society (DeJonckere, Crevier-Buchman et al. 2003). It comprises five dimensions: videostroboscopy, perceptual evaluation, acoustic analysis, aerodynamic measurement and subjective patient rating of voice quality.

2.5.1. Videostroboscopy

Videostroboscopy is a clinical technique for recording and observing vocal fold vibration. The basic idea of stroboscopy was first invented as early as 1878. It was gradually introduced into clinical practice in Japan and Europe. At present, videostroboscopy is considered routine in the laryngologic examination globally (Bless, Hirano et al. 1987). The videostroboscopy apparatus consists of a stroboscopic (pulsed light) cold-light source, a videomonitor, a recording microphone and a videotape-recorder or computer software to store a record of the examination. An office-based endoscopy with either a rigid 70° or 90° angled laryngoscope transorally, or a flexible fiberoptic nasolaryngoscope in individuals with a hypersensitive gag reflex is performed. Laryngeal functions may be observed and recorded during prolonged phonation under standard white light or stroboscopic light with image magnification. Stroboscopy creates an illusion of slow motion by generating light flashes either at the same frequency as phonation observed as a still image, or a slight variation of the fundamental frequency of phonation seen as movement in slow motion. Asynchronization transforms the duration of a typical laryngeal cycle from 5 milliseconds up to between 0.25 and 1 second. The "cycle" therefore represents a montage of many laryngeal cycles, rather than documentation of a single cycle as in high-speed photography (Sercarz, Berke et al. 1992). The brain is then able to fuse these images of cycles into a perception of motion, since the retina only responds to images at a rate of five per second. Perceptual judgements of the vibratory patterns of the vocal folds are based on the knowledge of the cover-body theory and how the travelling mucosal wave varies as a function of frequency and intensity (Hirano and Kakita 1985). The mucosal wave is analyzed for its symmetry, regularity (periodicity), glottal closure, amplitude of vibration (lateral excursion of the fold during vibration) and stiffness (presence of immobility) (Bless, Hirano et al. 1987).

Stroboscopy is considered useful in the assessment of UVFP, but the clinicians have to be aware of the inherent limitations related to the technique (Sataloff, Spiegel et al. 1991). Stroboscopy is useful because of its sensitivity in demonstrating even a slight gap between the vocal folds and an asymmetry of the travelling wave. The mucosal wave on the paralyzed side appears later, travels slower and has diminished amplitude. This asymmetry is caused by lack of muscle tone, and is present in all types of laryngeal paralysis (VN, RLN and SLN). The resulting aperiodicity of vocal fold vibration is easily identified even by inexperienced observers (Sercarz, Berke et al. 1992). On the other hand, severe aperiodicity of vibration in patients with a wide glottal gap impairs the ability of the stroboscope to synchronize the light flash. Adequate signal for analysis is therefore not always achieved, especially in aphonic voices that most often warrant surgery (Harries and Morrison 1996). However, state-of-the-art evaluation of UVFP is considered to include videostroboscopy (Benninger, Crumley et al. 1994; Rubin and Sataloff 2007).

High-speed photography and high-speed digital imaging have been developed to overcome the limitations of stroboscopy with aperiodic phonatory disorders (Kaszuba and Garrett 2007). These techniques provide real-time images of successive glottal cycles of the larynx during phonation. High-speed photography (pictures taken at a rate of 3000-4000 frames per second) requires expensive equipment and technical expertise for proper operation. The view of the larynx during the camera recording is achieved by using a laryngeal mirror which can be technically challenging with some patients. High-speed digital imaging uses standard rigid endoscopes at a sampling rate

of 1000 to 8000 frames per second. The recorded events with both techniques are then played back and analyzed in ultraslow motion. Technical difficulty, combined with high cost and time expenditure necessary to complete the examination, have limited the clinical use of these methods.

2.5.2. Perceptual evaluation

No simple association exists between voice production, subjective auditory perception, and objective acoustic data. When assessing patients after a surgical procedure it is an advantage to have preoperative values as a reference to postoperative measurements. Perceptual evaluation of voice is often carried out by a panel of voice professionals who listen to recorded voice samples of connected speech. Despite of the difficulties in standardizing the task, it is still valued by many clinicians, since the ultimate goal of surgery is voice that sounds clear and healthy (Kreiman, Gerratt et al. 1993). The Japanese GRBAS system is probably the most widely used scale due to its relative simplicity (Behrman 2004). It consists of five dimensions of voice quality (Grade, Roughness, Breathiness, Asthenia, Strain) with a score of 0 to 3 assigned in each domain (0 = normal voice; 1 = minor dysfunction; 2 = moderate dysfunction; 3 = severe dysfunction). Even this scale carries the problem of intra- and interrater reliability, the general 'grade' value as well as 'roughness' and 'breathiness' of voice are evaluated by professionals with moderate reliability and interrater consistency (De Bodt, Wuyts et al. 1997).

2.5.3. Acoustic analysis

The voice of dysphonic patients can be analyzed objectively. The voice sample is recorded in a sound-proof booth and consists typically of sustained vowel phonation. Computer programs like Computerized Speech Lab®, CSpeech® and Dr.Speech® are available to provide a multidimensional voice analysis. Acoustic parameters analyzed include measures of perturbation (irregularity of frequency and amplitude), fundamental frequency and the relation of noise components to harmonic signal. Acoustic analysis is an attractive method for assessing pathological voice because it is easy to obtain, noninvasive, and provides objective data. However, perturbation measures rely on the inherent ability to determine accurate fundamental frequency. This may be difficult to obtain with severely dysphonic voices as in UVFP, which are often only marginally periodic (Kaszuba and Garrett 2007). UVFP results in a combination of insufficient glottal closure and asymmetry in vocal fold mass. The perturbation measures of voice acoustics reflect these physical facts in two different but interrelated ways. Irregular glottal pulses are heard as roughness of voice and reflected by jitter (Rontal, Rontal et al. 1983), a cycle-to-cycle frequency variation. Shimmer, a cycle-to-cycle amplitude variation increases with poor and inconsistent contact between the vocal fold edges (Yumoto 1983). In addition to period-to-period variations, inconsistent or absent vocal fold closure leads to air leakage through the glottis. It is acoustically characterized by high-frequency noise. The noise-to-harmonic ratio (NHR) gives an estimation of the proportion of aperiodic to periodic signal produced by the vocal folds. NHR seems to integrate both principal components of hoarseness: breathiness and roughness (Yumoto 1983). The reliability of the commercially available acoustical analysis software programs has raised some criticism. Perturbation values in particular agree poorly between programs, which may prevent comparison of data from one institution to another (Bielamowicz, Kreiman et al. 1996).

2.5.4. Aerodynamic measures

The maximum phonation time (MPT) and the s/z ratio are aerodynamic measures of maximum vocal performance that require only a stopwatch for instrumentation. They provide the clinician with an easy measure of phonation duration, which correlates to the integrity of phonatory glottal closure. MPT is assessed by asking the patient to take a deep breath and sustain the vowel /a/ for as long as possible on a continuous expiration. The s/z ratio is a statistic of the relative durations of maximum phonation of the phonemes /s/ and /z/. In UVFP, depending on the position of the paralyzed vocal fold and the width of the gap during phonation, MTP may vary from a few seconds to 20 seconds. Normative mean values for adults are 26 seconds for men and 21 seconds for women (Colton and Casper 1996). The validity and stability of this measure on repeat trials has been questioned, since age, sex, size, general health condition, cooperation and instructions have an influence on the results (Behrman 2004). However, MPT is feasible, when follow-up data from the same patient are to be analyzed (Hirano 1989).

2.5.5. Other physiologic measures

Several laboratory techniques used in experimental clinical voice research are also available. Electroglottography, photoglottography, ultrasound glottography, and videokymography all monitor the vibratory pattern of the vocal folds (Kaszuba and Garrett 2007). They are considerably less common, however, and require specialized instrumentation that is frequently unavailable in routine clinical practice (Behrman 2004).

2.5.6. Subjective evaluation of voice quality

Patient self-rating scales are used in laryngology to quantify the psychosocial consequences of voice disorders. While perceptual judgements by educated observers and objective measurement can produce valuable data, they do not provide insight into why patients with similar voice disorders experience differing levels of handicap and disability. The Voice Handicap Index (VHI) was developed as a psychometrically validated tool to demonstrate treatment effectiveness by relating clinical and more objective results to the patients´ subjective experience (Jacobson, Johnson et al. 1997). It consists of 30 statements that reflect the variety of experiences encountered by the patient with a voice disorder. The statements are divided into three subscales each consisting of 10 questions; Functional, Emotional and Physical. Patients report the frequency of each experience on a five-point equally-appearing scale (never, almost never, sometimes, almost always, always). The impact of dysphonia on the quality of life has been reported to be substantial even when compared with other chronic diseases such as angina pectoris, sciatica, chronic sinusitis and back pain (Benninger, Ahuja et al. 1998). Especially patients with vocal fold paralysis express problems related to the ability to cope with work and other daily tasks. It is interpreted to be due to the impact of incomplete glottic closure (stabilization of the intrathoracic pressure) on lifting and straining and other daily activities (Benninger, Ahuja et al. 1998). Other widely used dysphonia-specific quality-of-life instruments include Voice-Related Quality of Life (VQROOL) (Hogikyan and Sethuraman 1999) and Voice Outcome Survey (Gliklich, Glovsky et al. 1999).

3 Aims of the study

The aim of this work was to study how the autologous fascia complies in the vocal fold as an injected filler. Injection laryngoplasty with autologous fascia (ILAF) was performed on humans and animals with UVFP. The effects of extreme processing of fascia (mincing) on the stability of augmentation and on the host versus graft tissue reactions were of special interest.

Specific aims were as follows:
1. To analyze fascia graft survival and tissue reactions histologically in an animal model. (I)
2. To report initial results in humans after ILAF. (II)
3. To report the intermediate term (5-32 months) results after ILAF. (III)
4. To analyze glottal closure and vibratory characteristics of the vocal folds by videostroboscopy after ILAF (IV)
5. To present long-term (3-10 years) results after ILAF. (V)

4 Patients and methods

The studies are identified with Roman numerals. All patients in studies II, III, IV and V were examined at the Helsinki University Central Hospital, Helsinki, Finland, which is a tertiary referral center. The animal study (I) was conducted at the National Laboratory Animal Center, Kuopio University, Finland.

4.1. Surgical technique

Harvesting and preparation of the free fascia graft for injection laryngoplasty was introduced in 1998 (Rihkanen 1998). The fascia lata is exposed through a 2-4 cm longitudinal skin incision on the lateral aspect of the thigh under local anesthesia. A 3 x 2 cm area of fascia is excised with some small pieces of subcutaneous fat. No attempt is made to close the remaining edges of the fascia, because it is known to heal eventually with fibrous connective tissue. Fascia lata is a general donor site for free fascia transplantation; no significant muscle prolapse is usually evident (Boyce, Nuss et al. 1994). The fascia is then cut into small pieces to enable injection. Initially this was done by a scalpel on a polyamide-plastic disc. At present, mincing is done with scissors. The paste thus formed (approximately 0.3-0.5 mL) is placed in a 1 mL syringe in retrograde fashion (piston removed). This is best achieved with the help of a septum elevator or by loading the paste first into a 2 mL syringe, and then injecting it into the 1 mL syringe. The 1 mL plastic syringe needs to be manufactured for use with the Brunings syringe holder (Karl Storz, Tuttlingen, Germany; 27220) for proper fit. The paste is followed by 0.3 mL of fat to act as a vehicle for emptying the long needle (Karl Storz, Tuttlingen, Germany; length 18 cm, O.D. 1.3 mm/ 17.5G; 27200SM). Rigid suspension laryncomicroscopy under general anesthesia with jet-ventilation is performed. The injection is carried out by a Brunings syringe holder. The first injection site is lateral to the vocal process of the arytenoid cartilage and another is directed further anterior on the lateral aspect of the fold. Augmentation of the anterior third of the vocal fold has to be avoided. Slight over-correction is attempted initially. The injection is aimed deep into the TA muscle (a depth of 2-3 mm). The details of needle position are drawn in figure 1. After the injection, the vocal fold is stroked with a suction tube to smoothen the medial edge. Patients are discharged from the hospital on the same day or on the first postoperative day. They attend routine control visits 1 and 6 months postoperatively. A supplementary control was scheduled for the clinical trials. The main steps of the procedure are illustrated in figures 2 to 6.



Fig.1. Site of injection, superior and coronal view. Contour of the vocal fold medial edge before the injection is marked with a dotted line (®Mari Markkanen-Leppänen 2009).



Fig. 2. Incision on the lateral aspect of the right thigh. Exposure of the fascia lata.



Fig. 3. Excised fascia, size approximately 3 x 2 cm.

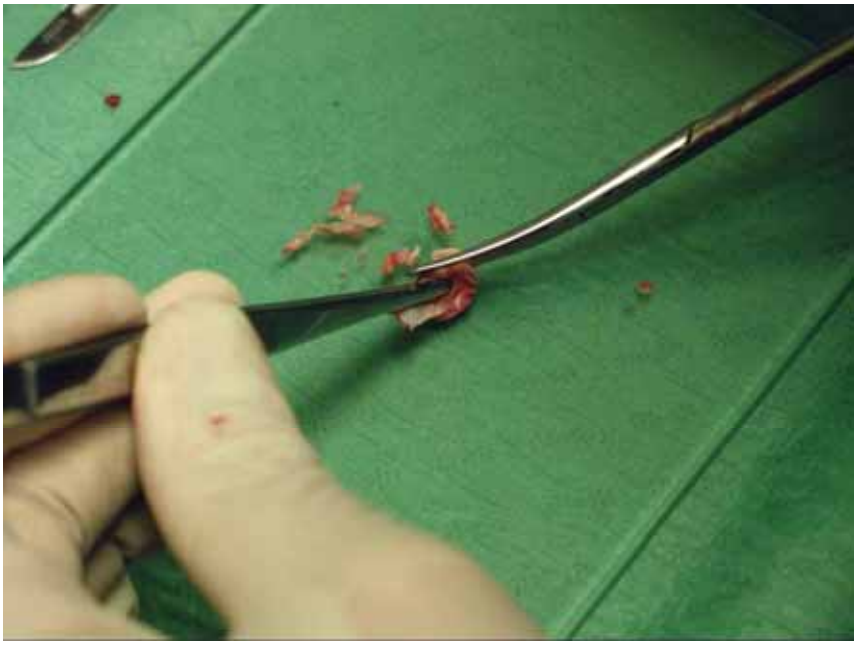

Fig. 4. Mincing the graft with scissors.

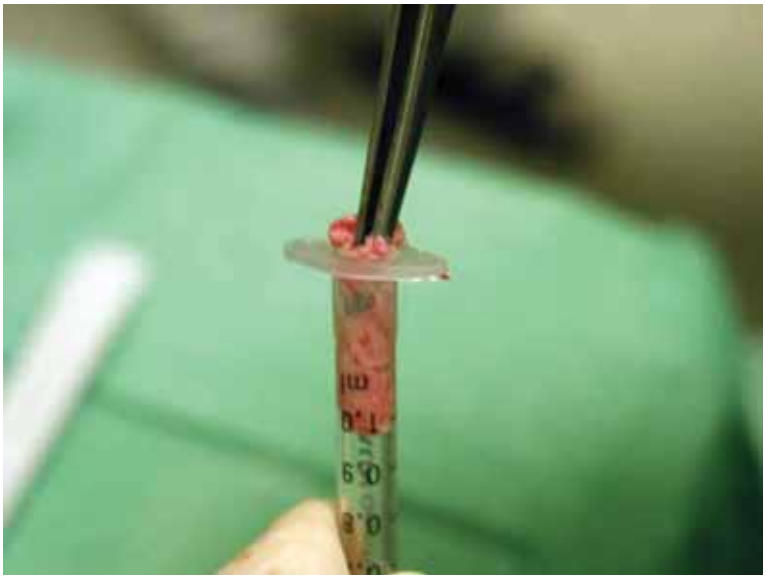

Fig. 5. Loading the minced fascia with forceps into the 1 mL syringe. An alternate technique is to inject the paste with a 2 mL syringe.



Fig. 6. Brunings syringe holder ready for injection.

4.2. Animal study (I)

Nine beagle dogs were operated on. The recurrent nerve was sectioned unilaterally. Graft harvesting and processing, and fascia injection of the paralyzed vocal fold were performed in a similar manner to humans. Two dogs were sacrificed three days after the procedure, one after ten days, three dogs at six and three dogs at twelve months. The larynges were removed and fixed in formalin. Serial coronal paraffin sections of the grafted vocal fold were made. Two contralateral mobile vocal folds were used as controls. Histology of the graft was analyzed by a pathologist.

4.3. Initial clinical trial with patients (II)

During a period of three years (1994-1997) a total of 23 patients underwent ILAF for UVFP. All patients had received at least ten sessions of voice therapy before surgery was suggested. The indications for surgery were poor voice quality and inadequate loudness as judged by the patient and the phoniatrician, combined with an open glottal gap during phonation on videostroboscopy. Five patients were excluded (death of ongoing primary disease before the trial was conducted, a child, a senile elderly man, a patient with multiple cranial nerve lesions, a patient with previously performed thyroplasty type I). Finally, 18 patients were included: 9 males and 9 females, mean age 57 years (range 43-73 years). Etiology of paralysis was surgical trauma in 12 patients. Other etiologies consisted of tumours (N=3), idiopathic causes (N=2), and one laryngeal trauma. The mean duration of paralysis was 2.2 years. The mean follow-up was 9 months (range 4-25 months). Acoustic analysis and MPT were measured to assess the outcome. Pre- and postoperative data were obtained by a sustained vowel phonation recorded in a sound-proof booth. Jitter, shimmer and NHR were calculated with a commercially available computer program.

4.4. Intermediate term clinical trial (III and IV)

The cohort of 23 patients for this study is partly the same as in study I. For this trial, a supplementary control with a longer follow-up was scheduled, and a more thorough workup for outcome evaluation was implemented. In order to find out the impact of a single procedure on voice or to be able to carry out a blinded perceptual evaluation 9 patients were excluded: age over 80 (N=1); age under 16 (N=1), a previous thyroplasty type 1 (N=1); lesions of several cranial nerves (N=1); lost to follow-up (N=2); death due to ongoing disease (N=2) and need for arytenoid adduction soon after fascial augmentation (N=1). Finally, 14 patients were included: 6 males and 8 females, aged from 42 to 73, mean age of 59. The etiology of paralysis was surgical trauma (N=10), tumour (N=2), trauma (N=1) and an idiopathic cause (N=1). The mean duration of paralysis was 14 months (range 5 -32 months) and the mean length of follow-up 13 months (range 5-32 months). The control visits were conducted during the winter 1997-98.

Perceptual evaluation, acoustic analysis, MPT, and videostroboscopy were chosen for outcome measurement. Perceptual evaluation was carried out by a panel of 4 voice professionals who listened to the voice samples of connected speech in a blinded fashion. A visual analogue scale (a line from 0 to 10 cm) was employed with three lines for each voice sample representing the

following domains: general grade, roughness and breathiness. The VAS-scale value of 10 marked normal voice, and 0 an aphonic voice. For the acoustic analysis and MPT, a sustained vowel phonation was recorded. Perturbation measurements (jitter, shimmer) and NHR were calculated.

The videostroboscopy was analyzed in two separate ways and sessions. Firstly, a frame-by-frame analysis was carried out by two of the authors. To exclude the difference in magnification from one recording to another the length of the healthy vocal fold during inspiration was measured and a gap-index was calculated: glottal gap divided by the length of the healthy membraneous vocal fold x 100. Videos under halogen light were available from 12/14 patients preoperatively (one recording lost, one patient with a hyperactive gag-reflex not permitting video imaging) and 13/14 patients postoperatively (one fiberoptic recording was too blurry for the frame-to-frame analysis). Secondly, a panel of four phoniatricians analyzed the mucosal wave only from the postoperative non-edited tapes run at normal speed. Postoperative videos with stroboscopic light were of adequate quality for the panel analysis in all 14 patients.

4.5. Long term clinical trial (V)

Between 1996 and 2006 a total of 94 consecutive patients had undergone ILAF for UVFP. Five patients were lost to follow-up. Nineteen had died. In order to find out the impact of a single injection or to be able to carry out a blinded perceptual evaluation, 13 patients were excluded from the study for the following reasons: re-injection with fascia (N=7), arytenoid adduction (N=2) or additional lipoinjection (N=1). Three patients had native language other than Finnish. Fifty-seven patients were invited to participate in the study. Thirteen patients refused or were unable to attend. Forty-four patients attended the follow-up visit. In one female patient the paralysis had recovered and she was excluded. Hence, 43 patients were included. The median age at surgery was 55 (range 14 – 72) years. Nine patients were males and 34 females. Median duration of paralysis was 1.1 (range 0.2 – 46.7) years. Median duration of follow-up was 5.8 (range 3.3 – 10.0) years. In 30 of the 43 patients, the paralysis was caused by surgical trauma. The rest were attributable to an idiopathic cause (N=3), infection (N=3), tumour compression (N=4), intracerebral hemorrhage or infarction (N=2), and intubation trauma (N=1). Preoperative patient evaluation, voice therapy, and indications for surgery were equal to our previous clinical trials. The one supplementary follow-up control for each patient in this study was conducted during the winter of 2006-07. Perceptual evaluation with the GRBAS scale was carried out by a panel of 3 speech therapists. Acoustic analysis (jitter, shimmer, and NHR) were calculated with a computer program. Postoperative videostroboscopy was digitally archived. The videos were later evaluated by two phoniatricians not involved in the operative treatment. The analyzed parameters were glottal closure, phase symmetry, and mucosal wave amplitude. At the postoperative follow-up visit, the patients returned the VHI-questionnaire (Jacobson, Johnson et al. 1997) translated into Finnish. The VHI was not in use when injection laryngoplasty with fascia was initiated in 1996. Thus, only the postoperative score was available for analysis.

4.6. Statistical methods

In studies II and III a nonparametric test (Wilcoxon signed rank test; SPSS 7.5) was chosen for all parameters, because both series consisted of a small number of subjects, and the distribution of results of acoustic analysis was wide and scattered unevenly. The intrarater reliability of the panel and the correlations between objective and subjective measurements were assessed by Pearson correlation coefficient (SPSS). In study IV paired *t*-test and Pearson's correlation was applied for numeral scales, Wilcoxon signed rank and Spearman correlation for ordinal or nominal values (SPSS 10.0). In study V, statistical analyses were performed with the Wilcoxon signed rank test and the Mann-Whitney U-test (SAS 9.1). Associations between different voice parameter values were measured by Spearman rank-order correlation coefficients. Multiple linear regression analyses (ANOVA) were performed to determine how preoperative values, sex, age at the time of injection, and length of follow-up affected the measurable difference between the voice parameters. In all trials p-value < .05 was considered statistically significant.

4.7. Ethics

In the clinical trials informed consent was obtained from all individuals, and the human experimentation guidelines of Helsinki University Central Hospital were followed. The study protocols were approved by the Ethics Review Board of the Helsinki and Uusimaa University Hospital District. The animal study received the approval from the Animal Ethics Committee of Kuopio University, Kuopio, Finland.

5 Results

5.1. Histomorphology of the fascia graft, animal study (I)

The objective of the study was to measure the degree of inflammatory response to the graft at the host site and the presence of a possible foreign-body reaction. The effect of extreme graft-processing and mobile host site on graft survival (reabsorption) were of special interest. Two dogs were sacrificed three days after the procedure, one dog after ten days, three dogs after six months, and three dogs after twelve months.

The study verified that fascia was well-tolerated by the vocal fold. Inflammation was moderate in two dogs at three and ten days, but a clear acute inflammation in one dog was seen at three days. No inflammatory reaction was present at six and 12 months. In the beginning there was some hemorrhage surrounding the grafts, but no extensive edema, areas of necrosis, or granuloma were found at any time. After one year the fascia graft persisted forming a firm tissue mass with viable fibrocytes, collagen bundles with parallel orientation, and blood supply with arterioles and venules. Quantification of the volumetric loss of the graft proved to be difficult. The ellipsoid volume formula used in fat graft animal studies (Mikus, Koufman et al. 1995) could not be applied because of the irregularity of the fascia graft contour.

Histomorphologically the graft consisted of disrupted fascia at first. Organization in the form of capillary ingrowth from the surrounding muscle tissue began at 3 days. Signs of collagen remodelling began to emerge at 10 days and at six months collagen fibers showed elongation and parallel orientation. At 12 months, the graft consisted of hypocellular dense fibrous tissue with well-established vascular structures. Moderate amounts of fibroblasts were seen in all specimens, but they were abundant in two dogs.

Giant-cell foreign-body reaction was found around singular, small, crystal-shaped foreign-bodies, which originated from the polyamide (nylon) disc on which the graft was minced. At six and 12 months, sparsely spaced crystals in the graft were not noted to form a core of collagen formation or major tissue reaction. The finding of polyamide crystals in the graft at 12 months was important. It was an affirmation to the pathologist that the collagen-rich bundle found in the vocal fold of the dogs was man-made. It also led to a modification of the surgical technique; we began to mince the fascia with scissors.

Mild scarring of the thyroarytenoid muscle occurred around the graft. One dog showed more extensive scarring at six months. The subepithelial layer of the vocal fold remained undisturbed in all specimens. Atrophy of the denervated vocalis muscle in the form of fatty degeneration was noted at 6 and 12 months.

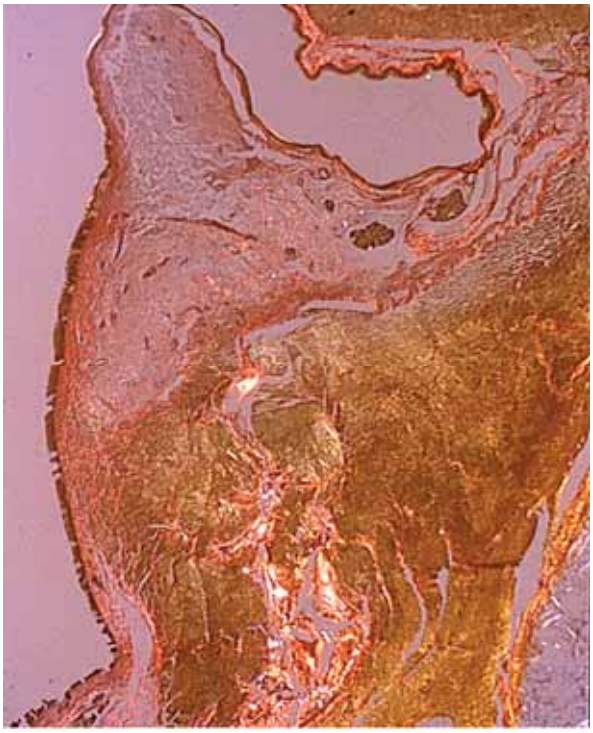

Fig. 7. The graft in the canine vocal fold at 12 months under polarizing light. H & E staining.



Fig. 8. Collagen fibres of the fascia graft at 12 months under polarizing light. The polyamide foreign-bodies are visible as white crystals.

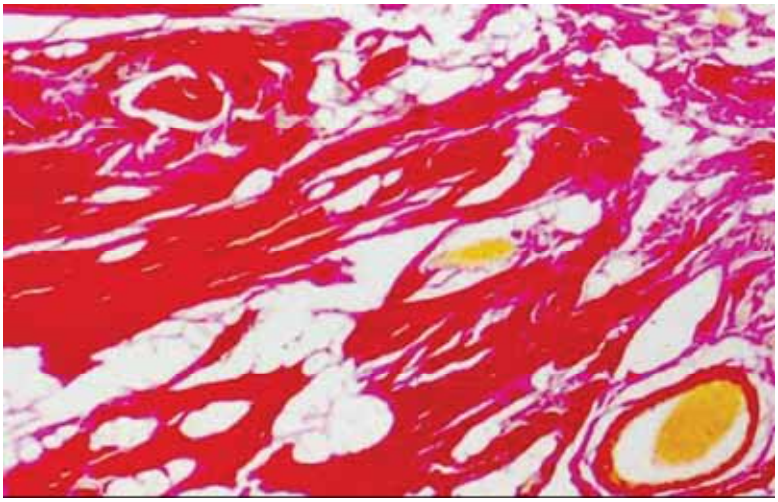

Fig. 9. Magnified view of the graft showing arterioles and venules in the graft at 12 months.

5.2. Voice quality, initial results (II)

The objective was to measure the short-term results of fascia augmentation. The mean follow-up of 18 patients was 9 months (range 4-25 months). The mean MPT doubled from 6.2 seconds (range 1-15 seconds) to 12.7 seconds (range 4-24 seconds). This change after intervention was significant ($p < .01$ Wilcoxon). In the acoustic analysis, significant improvements were measured in jitter ($p < .001$, Wilcoxon); shimmer ($p < .01$, Wilcoxon) and NHR ($p < .01$, Wilcoxon). The average fundamental frequency (Fo) showed no constant change. However, the Fo-variation diminished from 15.1 % to 6.1% ($p < .01$; Wilcoxon) indicating improved stability of voice.

5.3. Voice quality, intermediate term trial (III)

The objective was to measure the change in voice quality after augmentation of the paralyzed vocal fold with autologous fascia graft and to document possible donor site and host site morbidity. Fourteen patients were included in the study. The data for evaluation was collected at a supplementary control after the operation. The mean follow-up was 13 months (5-32 months). No perioperative or postoperative complications related to graft harvesting occurred. No edema or hematoma of the vocal fold with a possible airway compromise after the injection were seen. All patients were discharged from the hospital at the same or the following day. No antibiotics or corticosteroids were given. At the donor site, two prolapses of the vastus lateralis muscle occurred later, one of which was surgically corrected. No complaints were made of an aesthetically disturbing scar on the thigh.

In perceptual evaluation 10 of the 14 postoperative voices (71%) were rated as normal or near normal; the grade value was over 7.5 (VAS from 0 to 10). The improvement (change after intervention) was significant for grade ($p < .001$, Wilcoxon) and breathiness ($p < .001$, Wilcoxon). Pearson correlation quotients measuring intrarater agreement were high: $r = 0.93$ to $r = 0.99$. The aerodynamic improvement measured by MPT was statistically significant ($p < .01$, Wilcoxon). Mean values of MPT improved from 5.8 to 11.4 seconds. The change in MPT was more than 25 % in 9 out of 14 patients. In one patient the MPT was worse after the operation. Data for acoustic analysis were available from 12 patients. A significant change was measured for absolute jitter ($p < .01$, Wilcoxon), shimmer % ($p < .01$, Wilcoxon), and NHR ($p < .01$, Wilcoxon). The parameters of acoustic analysis and perceptual evaluation were not correlated statistically significantly.

5.4. Videostroboscopy, intermediate term trial (IV)

The objective was to assess glottal closure and vocal fold vibration by videostroboscopy after ILAF in UVFP. Possible stiffness, scarring, or other possibly harmful consequences of the graft on the viscoelastic properties of the vocal fold were of special interest. Also, a visual estimate of the persistence of fascia augmentation, and the ability of the graft to close the glottal gap were addressed. Correlation between mucosal wave findings and other voice quality parameters was analyzed. The patients in this work were the same as in the intermediate term study (III). There is a discrepancy in the original article between the text and Table 2 (videostroboscopy analyzed frame-by-frame); the number of patients in Table 2 is incorrect. The number of patients in each category of videostroboscopic evaluation has been corrected for this presentation.

No signs of chronic inflammation with granuloma formation or scarring were evident at the follow-up. The paralyzed vocal fold was bowed in 11 patients before the operation. A slight bowing was still seen in 5 patients after the procedure suggesting either inadequate augmentation initially, or slight reabsorption of the graft during the follow-up. No over-corrected protrusion of the vocal fold was seen postoperatively in any patient, the graft had been molded to appropriate size by the dynamic forces exerted on the vocal fold. The relatively small volume of fascia (< 0.5 mL) used in this series seems to be sufficient for augmentation in most patients.

The frame-by-frame analysis was carried out in patients in whom a successfully recorded preoperative (N=12) and postoperative (N=13) video was available. Analysis of the preoperative videos under cold light revealed a large glottal gap with no contact between vocal folds during phonation in 10 subjects. Two subjects had a partial contact of the anterior parts of vocal folds under stroboscopic light. Preoperative stroboscopy failed in 11 patients because the voices were too aperiodic to trigger the stroboscope demonstrating irregular or absent vocal fold vibration. Only one patient had a symmetric mucosal wave in phase and amplitude.

Postoperatively 11 patients had complete or partial glottal closure, and two patients had an open glottal gap. The mean gap-index (the gap width in relation to the vocal fold length) was preoperatively 7.21 and postoperatively 1.65. The change was significant ($p < .001$, paired *t*-test). Postoperatively vocal fold vibration with phase synchrony was present in 8/13 patients (66%). One postoperative fiberoptic stroboscopy was too blurry for the frame-by frame analysis, but of adequate quality for the panel evaluation.

In the postoperative videostroboscopy (N=14) run at normal speed the panel of phoniatricians agreed that 13 patients had complete or partial glottic closure and one patient had an open glottal gap during phonation. The mucosal wave demonstrated phase synchrony in 11 patients (78%). The panel ratings were in accordance with the frame-by-frame analysis of the authors.

When the perceptual evaluation and the postoperative videostroboscopy by the panel were compared, a high correlation was noted between vocal fold phase synchrony and breathiness (Spearman 0.679, $p < .01$). Statistically significant correlation was found also between phase synchrony and jitter, shimmer and NHR of acoustic analysis (Spearman 0.648, $p < .05$; Spearman 0.648, $p < .05$; Spearman 0.650, $p < .05$, respectively). The measured maximum postoperative gap between the vocal folds (gap-index) correlated statistically significantly not only to the perceived voice quality (grade: Spearman 0.665, $p < .01$; breathiness: Spearman 0.741, $p < .01$), but also to the acoustic parameters (jitter: Spearman 0.779, $p < .05$; shimmer: Spearman 0.629, $p < .05$; NHR: Spearman 0.680, $p < .05$).

5.5. Voice quality and videostroboscopy, long term trial (V)

The objective was to measure the stability of outcome after a single injection of fascia. Only patients with fascia injection as the first and only phonosurgical procedure were included. Forty-three patients attended only one follow-up visit in this retrospective trial. Median duration of follow-up was 5.8 years with a wide range (3.3 – 10.0).

In perceptual evaluation, the improvement after intervention was statistically significant ($p < .01$, Wilcoxon) in all domains of the GRBAS-scale except strain. In acoustic analysis the average proportion of jitter was reduced significantly from 5.25% to 2.61% ($p < .01$, Wilcoxon). The change in average shimmer and NHR was not statistically significant. Postoperative videostroboscopy showed complete or partial glottal closure in 83% of patients. Mucosal wave symmetry was detected in every cycle or most cycles in 74% of patients, and mucosal wave amplitude symmetry was present in 58% of patients. Postoperative mean VHI-score was 35 (median 29). VHI was below 30 in 24 of the 43 patients (56%), while 9 (21%) considered their voice to be poor (VHI over 60). The scale of VHI ranges from 0 to120.

Multiple regression analysis with single acoustic and perceptual parameters and VHI-scores showed that the length of follow-up and delay from onset of paralysis to injection laryngoplasty had no significant effect on the results. The results were neither dependent on the patient´s age. In perceptual evaluation, severely disturbed preoperative voice (high grade value) correlated with poor outcome (Spearman 0.404, $p < .05$). The results of patients whose paralysis was caused by chest surgery ($N = 7$) were clearly below the average.

6 Discussion

The need for safe and stable soft-tissue filler in reconstructive and aesthetic surgery is widely acknowledged. No single material to date has fulfilled all of the ideal requirements. Based on the results of this work, a new application for autologous free fascia transplantation has been established. Fascia seems applicable for long-term treatment of UVFP with certain limitations.

Injection of fascia deep into the vocal fold is not followed by haematoma or extensive oedema compromising the airway. According to the experiment with canine vocal folds, the fascia graft attracts only moderate inflammatory response at the host site without areas of necrosis, thus avoiding the need for antibiotics and corticosteroids postoperatively. The graft induces no chronic inflammation or formation of granulation tissue. Only mild scarring occurs around the graft. As the result, the vibratory medial margin of the vocal fold remains intact. This allows the return of a normal vocal fold mucosal travelling wave, once sufficient augmentation and adequate glottal closure are achieved. The viscoelastic properties of the injected minced fascia graft are not equal to the superficial lamina propria of the vocal fold mucosa. Thus, injection laterally and deep into the TA muscle is required.

The results of our animal study showed that extreme processing of the graft did not lead to increased phagocytic activity. Nor did the dynamics of the host site lead to deterioration of the graft. Quantification of volumetric loss of the injected graft at one year postoperatively in the animal study proved to be difficult because of the irregular stellar contour of the graft. Some compaction of the graft was evident, which was interpreted to be the result of collagen remodelling. The graft seemed to be integrated into the vocal fold tissue with blood vessels and viable fibrocytes.

The reported presence of polyamide particles in the vocal fold as a result of mincing the graft with a scalpel on a polymer plate has caused some concern (Kwon and Buckmire 2004). From our point of view, this finding in the animal study was important. Firstly, the polymer foreign particles amongst the graft affirmed the pathologist in our study that the collagen-rich bundle found in the vocal folds of the dogs was indeed man-made. Another animal study with ILAF had just previously stated that no graft was found in the histological sections of the vocal folds of six dogs with UVFP and a follow-up of 3-12 months (Rodgers, Abdul-Karim et al. 2000). It is difficult to explain why Rodgers was not able to find the graft from any of the specimens. The operative technique they applied was identical to ours. He states that although their pathologist had to examine the specimens in a blinded fashion, the side of the injection was readily identifiable in every specimen as there was significant muscle atrophy compared to the non-injected side. It is possible that the main bulk of the graft could have been missed, since only three coronal sections were made from each vocal fold. Secondly, the finding of foreign-bodies in the graft also led to a modification of the surgical technique. After conducting another animal study which confirmed the origin of the foreign-bodies to be the polymer plate, the authors commenced processing the graft with scissors (Rihkanen, Kaliste et al. 2003).

Our results with autologous fascia have been supported by a study which reported the combined results of an animal model and a clinical trial using a similar technique of ILAF (Duke, Salmon et al. 2001). Eight dogs underwent unilateral autologous fascia injection augmentation with simultaneous contralateral lipoinjection. The dogs were sacrificed at 12 weeks. Histological

analysis of canine larynges revealed high graft yield variability for both graft materials, mean graft yield being 32.7 % (range 4.8 % - 83.9 %) for fascia and 46.6 % (range 6.7 % - 95.7 %) for fat. The difference was not significant ($p = .57$). Host inflammatory response was graded as mild in all animals. It is noteworthy that the recurrent nerve was not sectioned before injection, and that both vocal folds were augmented simultaneously. Mobile augmented vocal folds during barking and coughing could expedite the exit of the graft and explain the modest yield.

In humans, vocal results after ILAF were good in our short term and intermediate term studies. Significant improvement was achieved in blinded perceptual evaluation, acoustic analysis and MPT. The return of mucosal wave was witnessed in videostroboscopy after successful injection augmentation. No over-correction with protrusion of the vocal fold was encountered; graft removals were therefore not necessary. This would suggest that the amount of fascia paste injected is not very critical, as long as glottal closure is achieved. Although not reported in our articles, relatively small volume of fascia (< 0.5 mL) is sufficient for augmentation in most patients. Fascia is virtually cost-free and readily available in large amounts from the thigh under local anaesthesia. Only minor complaints of donor site morbidity were met.

Another research group has examined the results of ILAF in humans (Duke, Salmon et al. 2001). In the clinical part of the study, 40 patients underwent autologous fascia injection laryngoplasty for various etiologies of glottal insufficiency (bowing, UVFP, scarring). All patients tolerated the procedure well. One cellulitis of the harvest site was encountered and treated with a short course of oral antibiotics. Thirty-eight of the 40 patients reported subjective improvement in their voice after the procedure. Although the graft yield with dogs was low (the results of canine experiment were published in the same article), they reported no significant graft resorption problems in patients, including some who had postoperative follow-up of two years. As a result, in contrast to lipoinjection, marked overcorrection was not performed when using fascia for injection. They concluded that autologous fascia may give excellent long-term results especially in the older patients with mild bowing or small glottal gap. However, in cases of paralysis, they prefer to perform medialization laryngoplasty, usually combined with arytenoid adduction.

Properly prepared, fascia is cited to be a good material for augmentation also in a textbook of voice surgery (Sataloff 2005). The author has tried the technique and variations of it for years. Major problems have been related to mincing. Obstruction of the injection needle by fascia particles resulted once in a breakage of the metal syringe holder. He reports relatively little resorption to take place and advices to avoid excessive over-correction. According to our experience, mincing the graft into tiny pieces, and cleaning the needle by rinsing it with saline immediately after the procedure to clear all remnants of fascia from the lumen has to be meticulous. It is also essential to use an injection needle with a 1.1 mm/17.5G lumen (Karl Storz, Tuttlingen, Germany 27200SM).

Another technique taking advantage of fascia grafting has been introduced to treatment of UVFP (Nishiyama, Hirose et al. 2006). It is a modification of a technique that was initially developed to treat vocal fold sulcus and scarring (Tsunoda, Takanosawa et al. 1999). The graft is harvested from the temporal fascia. Under suspension microlaryngoscopy, an incision is made on the lateral aspect of the vocal fold and a pocket is undermined under the sulcus or scarred vocal fold mucosa. A single-layer fascia graft is dried and trimmed, and transplanted into the pocket. In UVFP, the incision is made more posteriorly on the vocal fold, and the pocket is created so that the graft is able

to rotate the vocal process of the arytenoid medially. The exact placement of the fascia graft is unfortunately quite vaguely described in the article. One-year follow-up of eight patients showed improvement of glottal closure measured by MPT and stroboscopy.

Once the safety and acceptable vocal results of injection augmentation of paralytic dysphonia are established, the stability of medialization becomes an important issue. In our long term follow-up of median 5.8 years significant improvement of mean jitter and parameters of blinded perceptual evaluation were reported. The mean postoperative VHI was 35. The length of delay from the onset of paralysis to the injection or the length of follow-up after ILAF did not correlate with the result. This seems to be in concordance with the findings of our histological study of canine vocal folds where the graft was seen to form an integrated, viable mass in the vocal fold at 12 months suggesting long term stability with low if any resorption.

As the implants used in thyroplasty type I are synthetic, resorption is not an issue. Therefore, laryngeal framework surgery is considered as the gold standard in the treatment of UVFP against which the stability of other techniques is measured (Kwon and Buckmire 2004). Oddly though, long-term studies of thyroplasty type I or injection laryngoplasty with any material beyond one year are few (Behrman 2004). Most reported trials of thyroplasty type I with various implant materials are limited to a 12 month follow-up (Cummings, Purcell et al. 1993; Montgomery and Montgomery 1997; McCulloch and Hoffman 1998; Friedrich 1999). One study of 28 UVFP patients compared the 1-month results to the 12-month results; the measured parameters attained maximum improvement within one month of thyroplasty type I (Lundy, Casiano et al. 2000). This was interpreted to indicate that the result is permanent, if the augmentation is adequate initially. In contrast, some bowing with recurring glottal gap has been reported with thyroplasty type I, if the vocal fold volume continues to diminish as a result of muscle atrophy (Tucker 1999; Hogikyan, Wodchis et al. 2000). Such deterioration of results with time was not seen in a recent study, which reported the results of 16 UVFP patients treated with thyroplasty type I, and with a follow-up of 1-7 years (mean 26 months). Outcome data showed excellent results with continued improvements after 6 months (Dursun, Boynukalin et al. 2008).

Despite of many advantages of the autologous fascia graft, its application into the vocal fold has not been popularized during the past ten years. The need for operating on a remote surgical site for graft harvesting may be considered time-consuming and costly in the operating theatre. The deep harvest wound has been considered to add morbidity (Duke, Salmon et al. 2001; Kwon and Buckmire 2004). The technique of ILAF requires general anesthesia with jet ventilation, which excludes it from the office. Elderly patients with circulatory or respiratory comorbidities may not endure even a brief general anesthesia. Augmentation with fascia suffers also from the inherent shortcomings of injection laryngoplasty. Large posterior glottal gaps cannot be corrected with injection laryngoplasty regardless of material, because sufficient medialization of the arytenoid is not achieved, and the vertical disparity between vocal folds cannot be corrected.

The reliability of our results may leave some room for criticism. A basic shortcoming is that a randomized controlled protocol was not applied in these series. The total number of patients diagnosed with UVFP at our institution during these studies was not calculated in either clinical trial. No randomization of UVFP patients into groups receiving either no treatment, voice therapy alone, or voice therapy followed by surgery was performed. Randomization of a surgical treatment

with a control group receiving no treatment can be considered as ethically questionable. No universally accepted objective pre treatment guidelines suggesting either behavioural or surgical treatment in UVFP exist in terms of findings in videostroboscopy or parameters of acoustic analysis. Selection of patients might have been arbitrary and led to selection bias in the clinical trials. However, all patients in our cohorts had received several sessions of voice therapy with unsatisfactory outcome before surgery was suggested. It is thus safe to say that cases with minor voice complaints were not included in our series.

In addition, fascia augmentation was performed as the first and only phonosurgical procedure. UVFP patients with wide glottal gap and vertical disparity of the vocal processes of the arytenoids were not excluded. In retrospect, our results may have been adversely affected by this. The result of ILAF was especially unsatisfactory when the lesion was caused by an intrathoracic lesion of the VN. It is possible that the distance from the lesion in the thorax to the vocal fold is too great for any reinnervation to occur. Also the surgical trauma in the thorax is apparently severe leading more often to a complete transection of the nerve. This complete denervation results in an extremely lateral position of the vocal fold and a wide glottal gap that is difficult to correct with the injection technique. As a result of the present study, the treatment protocol of wide glottal gaps has been directed towards laryngeal framework surgery at our institution. These challenges in the research setting of our series are reflected in a review article of evidence-based treatment of paralytic dysphonia. A comprehensive literature survey of outcomes and efficacy revealed the virtual absence of randomized controlled trials addressing this patient population (Behrman 2004). Only one such study design was found, where the injection of bovine collagen was compared with the injection of HA (Hertegard, Hallen et al. 2004).

The objectivity and accuracy of outcome measurements is vital to the reliability of results. The parameters chosen to measure voice quality in our study agree well with the protocol suggested by the European Laryngological Society (DeJonckere, Crevier-Buchman et al. 2003). An effort towards unbiased perceptual and videostroboscopic evaluation was made by using panels of voice professionals not involved in the surgical treatment. In perceptual evaluation, the panels listened to the voice samples in a blinded fashion. To ensure accuracy, all recordings were made digitally. Two students of speech sciences with a thorough understanding of voice research recorded the voice samples at the supplementary postoperative controls related to these series, and also performed the acoustic analysis.

Direct conclusions of the benefits of ILAF over other surgical techniques are impossible to draw. We conducted no trial comparing fascia with other injection materials or to thyroplasty type I. Although an effort was made to reach all eligible patients, generalization and statistic analysis of the data on fascia augmentation are difficult because of small cohorts. The difficulties of conducting a retrospective trial with several years of follow-up after a rarely performed surgical procedure were encountered also in our series. Many elderly patients had died of comorbidites (20 %), and several patients refused to attend or were lost to follow-up. These facts reduced the number of patients originally identified in the computer data base search to half. Age tends to increase atrophy of the vocal fold. As the median age in clinical trials during the time of injection was 57-58 years, a median follow-up of six years is likely to increase the effect of aging to voice quality.

Preoperative voice samples of 15 patients were lost during the follow-up in the long-term trial. The number of patients available for each parameter of outcome evaluation varied because of the availability of recordings. The quality of many preoperative recordings (both in videostroboscopy and acoustic analysis) was not sufficient for analysis because of the aperiodicity of voice. This seems to be a fact one has to accept when treating and studying extremely hoarse voices. The preoperative voice samples in the long-term study (V) were recorded by several nurses and at two different facilities, which provides quite a different setting compared to a prospective study with a given number of consecutive patients recorded by the same staff with the same instrumentation. The videostroboscopies performed in the 1990s were recorded on a U-matic analogic recorder. Comparing those videos with the postoperative digital stroboscopic computerized files could not have been carried out in a blinded fashion. Therefore, only the postoperative videos were used for evaluation. All these reductions in the samples of different parameters have presumably affected the power of our cohort to represent the long-term results of fascia augmentation.

The work in vocal fold restoration has progressed through phases of tissue replacement with synthetic fillers and biological implants. The return of normal function remains to be the ultimate goal of treatment. Increasing knowledge of the molecular biology of the vocal fold and nerve regeneration probably leads to means of enhancing the recovery of the damaged recurrent nerve and the regeneration of atrophied and scarred vocal fold tissue. If the results of the animal experiments can be applied to humans, all the complex functions of the larynx could be restored simultaneously. Until then, our method appears to offer a practical solution to resolve this complex issue.

7 Conclusions

Based on the studies I-V, the following conclusions were drawn:

1. Histological analysis reveals that aggressive processing of fascia does not induce aggravated host versus graft tissue reactions. Fascia is well-tolerated by the vocal fold. After 12 months, the graft was integrated into the host tissue with viable fibrocytes and blood circulation. We were unable to measure the exact graft yield because of the irregular contour of the graft. Some compaction of the graft due to collagen remodelling with loss of initial augmentation volume was evident. Absence of phagocytic activity suggests long-term stability of the graft.

2. Significant short and intermediate term improvement of voice quality was achieved in UVFP patients after ILAF.

3. ILAF is a safe medialization technique with no immediate surgical complications and minimal postoperative morbidity.

4. Fascia induces no chronic inflammation with granuloma formation or stiff scarring of the vocal fold. This enables normal vibration of the vocal fold cover to occur during phonation.

5. The long term results were not as good and not as constant as those at one year. Wide glottal gaps should not be treated with fascia injection. The results were not dependent on the delay from onset of paralysis to surgery or the length of follow-up after ILAF. Fascia is a stable graft and most suitable for cases with less severe glottal insufficiency.

Acknowledgements

The clinical trials were carried out at the Department of Otorhinolaryngology, Head and Neck Surgery of the Helsinki University Central Hospital during the years 1997 - 2007. The animal study was conducted at The National Laboratory Animal Center of Kuopio University in close co-operation with the Department of Pathology of Helsinki University Central Hospital in 1998.

I owe my gratitude to Acting Professor Jukka Ylikoski, MD, PhD and to the head of the department docent Hans Ramsay, MD, PhD, for providing me with the opportunity to work and carry out this study at the Department of Otorhinolaryngology, Head and Neck Surgery. I am thankful to Professor Timo Nevalainen, DVM, PhD, who provided us with excellent facilities for the animal study at the Kuopio University. His personal professional contribution to the perioperative and postoperative care of the animals was invaluable.

I express my sincere gratitude to my supervisors docent Heikki Rihkanen, MD, PhD and docent Leena-Maija Aaltonen, MD, PhD. I am grateful to Heikki for initiating this work and for sharing his vast knowledge and clinical expertise in the field of laryngology. From the start I have been in awe of his ability to think and express himself clearly, both inherent qualities of a prominent clinician and teacher. I also especially thank Heikki for showing understanding and patience during my 5-year silent phase of this study, the "creative break", during which I started a family, built a house and established myself at my current post. I am deeply grateful to Leena-Maija, whose participation made it possible for me to continue this study after the break, and whose enthusiasm and commitment to laryngology has served as an example to follow.

I thank docent Jaana Sellman, MA, PhD, Kirsi Harinen, MA and Sari Lehikoinen-Söderlund, MA, from the Department of Speech Sciences of the University of Helsinki, for the voice research expertise required in the trials. Docent, pathologist Ilmo Leivo is thanked for his important participation in the histological analysis, which proved to be the cornerstone of this work in proving that the fascia really persists in the larynx.

Professor Marc Remacle and docent Jussi Laranne are warmly acknowledged for the flexible and swift review process of this thesis; their constructive criticism and comments clearly improved this thesis. I am truly grateful to Juha Silvola, MD, PhD, my head of the Department of Otorhinolaryngology at Päijät-Häme Central Hospital for giving me the opportunity to work at the department, and for providing me with consistent support to complete this thesis. I am thankful also to my fellow specialists at Lahti: Marit Starck, Mari-Liisa Tukia, Jyri Myller, Jouko Nieminen, and Aarre Salonen, who never complained for my recurrent leaves of absence from the office during this work. It is a privilege to work at our hospital with inspired colleagues and nurses, and state-of-the-art equipment.

I owe my sincere thanks to the personnel at the out-patient office of Laryngology and Phoniatrics of the Helsinki University Central Hospital for all their help. In particular I want to thank assistant nurse Tuula Säämänen for her extra effort during the enrolment of patients into the last trial. Without her persistence many more patients would have been "lost to follow-up". I am also indebted to phoniatricians Eija-Riitta Lauri, MD, Juha Vintturi, MD, PhD, and the speech therapists

Minna Apajalahti, Kaarina Ruusuvirta, and Marjo Rönkkö for donating their expertise and free time for the panels of outcome evaluation.

I want to thank all my friends and medical colleagues who have supported and encouraged me during these often challenging years. Thank you Olli and Maria Raitakari, Jouni Kuronen, Antti Lehtinen, Martti Lehtinen, Pekka Manninen, Harri Poka and Anna-Mari Haimi, Johan Hedström, Teemu Kinnari, and Harri Keski-Säntti. I am especially grateful to Ilpo Nuotio for shedding some light into the dark world of statistical mathematics, and to Mari Markkanen-Leppänen for her creative initiative with the drawings of the dissertation.

I wish to express my warmest thanks to my parents Seija and Yrjö and to my parents-in-law, Tuula and Ilkka Järvinen, who have provided our family with constant help in every-day life and baby-sitting.

Finally, I owe my deepest gratitude to my dear wife Hanna for her love, endless patience and invaluable support during these busy years. You and our beloved children Eetu, Kalle and Aino bring so much joy into my life each day.

This project was financially supported by the Helsinki University Research Funds, Government Research Funds of the Joint Authority for Päijät-Häme Social and Health Care, Finnish Medical Society Duodecim, and the Finnish Research Foundation of Otology.

References

Anderson, T. D. and R. T. Sataloff (2004). "Complications of collagen injection of the vocal fold: report of several unusual cases and review of the literature." J Voice **18**(3): 392-7.

Arnold, G. (1962). "Vocal rehabilitation of paralytic dysphonia: IX technique of intracordal injection." Arch otolaryng **76**(82).

Arnold, G. E. (1955). "Vocal rehabilitation of paralytic dysphonia. I. Cartilage injection into a paralyzed vocal cord." AMA Arch Otolaryngol **62**(1): 1-17.

Behrman, A. (2004). "Evidence-based treatment of paralytic dysphonia: making sense of outcomes and efficacy data." Otolaryngol Clin North Am **37**(1): 75-104, vi.

Benninger, M. S., A. S. Ahuja, et al. (1998). "Assessing outcomes for dysphonic patients." J Voice **12**(4): 540-50.

Benninger, M. S., R. L. Crumley, et al. (1994). "Evaluation and treatment of the unilateral paralyzed vocal fold." Otolaryngol Head Neck Surg **111**(4): 497-508.

Bharadwaj, B., E. Kurylo, et al. (1975). "The fate of autologous fascia lata grafts in dogs." Ann Thorac Surg **19**(2): 158-69.

Bielamowicz, S. (2004). "Perspectives on medialization laryngoplasty." Otolaryngol Clin North Am **37**(1): 139-60, vii.

Bielamowicz, S., J. Kreiman, et al. (1996). "Comparison of voice analysis systems for perturbation measurement." J Speech Hear Res **39**(1): 126-34.

Billante, C. R., D. L. Zealear, et al. (2002). "Effect of chronic electrical stimulation of laryngeal muscle on voice." Ann Otol Rhinol Laryngol **111**(4): 328-32.

Bless, D. M., M. Hirano, et al. (1987). "Videostroboscopic evaluation of the larynx." Ear Nose Throat J **66**(7): 289-96.

Boyce, R. G., D. W. Nuss, et al. (1994). "The use of autogenous fat, fascia, and nonvascularized muscle grafts in the head and neck." Otolaryngol Clin North Am **27**(1): 39-68.

Brandenburg, J. H., W. Kirkham, et al. (1992). "Vocal cord augmentation with autogenous fat." Laryngoscope **102**(5): 495-500.

Broder, K. W. and S. R. Cohen (2006). "An overview of permanent and semipermanent fillers." Plast Reconstr Surg **118**(3 Suppl): 7S-14S.

Broniatowski, M., H. M. Tucker, et al. (1990). "The future of electronic pacing in laryngeal rehabilitation." Am J Otolaryngol **11**(1): 51-62.

Bruning, W. (1911). "Uber eine neue Behandlungsmethode der rekurrenslahmung." Ver Deutsch Laryng **18**(23).

Chhetri, D. K., B. Jahan-Parwar, et al. (2004). "Injection laryngoplasty with calcium hydroxylapatite gel implant in an in vivo canine model." Ann Otol Rhinol Laryngol **113**(4): 259-64.

Colton, R. and J. Casper (1996). Understanding voice problems: a physiological perspective for diagnosis and treatment. Philadelphia, Lippincott Williams & Wilkins**:** p.358.

Courey, M. S. (2001). "Homologous collagen substances for vocal fold augmentation." Laryngoscope **111**(5): 747-58.

Crumley, R. (1985). Update on laryngeal reinnervation concepts and options. Surgery of the Larynx. B. Bailey and H. Biller. Philadelphia, W. Saunders**:** pp. 135-147.

Crumley, R. L. (1984). "Selective reinnervation of vocal cord adductors in unilateral vocal cord paralysis." Ann Otol Rhinol Laryngol **93**(4 Pt 1): 351-6.

Crumley, R. L. (1989). "Laryngeal synkinesis: its significance to the laryngologist." Ann Otol Rhinol Laryngol **98**(2): 87-92.

Crumley, R. L. (1991). "Update: ansa cervicalis to recurrent laryngeal nerve anastomosis for unilateral laryngeal paralysis." Laryngoscope **101**(4 Pt 1): 384-7; discussion 388.

Crumley, R. L. (1994). "Unilateral recurrent laryngeal nerve paralysis." J Voice **8**(1): 79-83.
Crumley, R. L. (2000). "Laryngeal synkinesis revisited." Ann Otol Rhinol Laryngol **109**(4): 365-71.
Cummings, C. W., L. L. Purcell, et al. (1993). "Hydroxylapatite laryngeal implants for medialization. Preliminary report." Ann Otol Rhinol Laryngol **102**(11): 843-51.
Das, S. K., S. F. Davidson, et al. (1990). "The fate of free autogenous fascial grafts in the rabbit." Br J Plast Surg **43**(3): 315-7.
De Bodt, M. S., F. L. Wuyts, et al. (1997). "Test-retest study of the GRBAS scale: influence of experience and professional background on perceptual rating of voice quality." J Voice **11**(1): 74-80.
Dedo, H. H., R. D. Urrea, et al. (1973). "Intracordal injection of Teflon in the treatment of 135 patients with dysphonia." Ann Otol Rhinol Laryngol **82**(5): 661-7.
DeJonckere, P. H., L. Crevier-Buchman, et al. (2003). "Implementation of the European Laryngological Society (ELS) basic protocol for assessing voice treatment effect." Rev Laryngol Otol Rhinol (Bord) **124**(5): 279-83.
Duke, S. G., J. Salmon, et al. (2001). "Fascia augmentation of the vocal fold: graft yield in the canine and preliminary clinical experience." Laryngoscope **111**(5): 759-64.
Dursun, G., S. Boynukalin, et al. (2008). "Long-term results of different treatment modalities for glottic insufficiency." Am J Otolaryngol **29**(1): 7-12.
Eppley, B. L. and B. Dadvand (2006). "Injectable soft-tissue fillers: clinical overview." Plast Reconstr Surg **118**(4): 98e-106e.
Fernandez-Acenero, M. J., E. Zamora, et al. (2003). "Granulomatous foreign body reaction against hyaluronic acid: report of a case after lip augmentation." Dermatol Surg **29**(12): 1225-6.
Ford, C. N. (2008). "Paradigms and progress in vocal fold restoration." Laryngoscope **118**(9): 1709-13.
Ford, C. N. and D. M. Bless (1986). "A preliminary study of injectable collagen in human vocal fold augmentation." Otolaryngol Head Neck Surg **94**(1): 104-12.
Ford, C. N., P. A. Staskowski, et al. (1995). "Autologous collagen vocal fold injection: a preliminary clinical study." Laryngoscope **105**(9 Pt 1): 944-8.
Friedrich, G. (1999). "Titanium vocal fold medializing implant: introducing a novel implant system for external vocal fold medialization." Ann Otol Rhinol Laryngol **108**(1): 79-86.
Gallie, W. (1948). "Fascial grafts." Br Surg Prac **4**(701).
Glatz, F. R., J. Kalkanis, et al. (2003). "Volume analysis of preadipocyte injection for vocal cord medialization." Laryngoscope **113**(7): 1113-7.
Gliklich, R. E., R. M. Glovsky, et al. (1999). "Validation of a voice outcome survey for unilateral vocal cord paralysis." Otolaryngol Head Neck Surg **120**(2): 153-8.
Guerrerosantos, J. (1991). "Nose and paranasal augmentation: autogenous, fascia, and cartilage." Clin Plast Surg **18**(1): 65-86.
Harries, M. L. (1996). "Unilateral vocal fold paralysis: a review of the current methods of surgical rehabilitation." J Laryngol Otol **110**(2): 111-6.
Harries, M. L. and M. Morrison (1996). "The role of stroboscopy in the management of a patient with a unilateral vocal fold paralysis." J Laryngol Otol **110**(2): 141-3.
Heavner, S. B., A. D. Rubin, et al. (2007). "Dysfunction of the recurrent laryngeal nerve and the potential of gene therapy." Ann Otol Rhinol Laryngol **116**(6): 441-8.
Hertegard, S., L. Hallen, et al. (2004). "Cross-linked hyaluronan versus collagen for injection treatment of glottal insufficiency: 2-year follow-up." Acta Otolaryngol **124**(10): 1208-14.
Heuer, R. J., R. T. Sataloff, et al. (1997). "Unilateral recurrent laryngeal nerve paralysis: the importance of "preoperative" voice therapy." J Voice **11**(1): 88-94.
Hill, D. P., A. D. Meyers, et al. (1991). "Autologous fat injection for vocal cord medialization in the canine larynx." Laryngoscope **101**(4 Pt 1): 344-8.

Hirano, M. (1989). "Objective evaluation of the human voice: clinical aspects." Folia Phoniatr (Basel) **41**(2-3): 89-144.
Hirano, M. and Y. Kakita (1985). Cover-body theory of vocal fold vibration. Speech Science. R. Daniloff. San Diego, Calif., College-Hill Press**:** 1-46.
Hirano, M., K. Mori, et al. (1995). "Vocal function in patients with unilateral vocal fold paralysis before and after silicone injection." Acta Otolaryngol **115**(4): 553-9.
Hirano, S., D. M. Bless, et al. (2004). "Growth factor therapy for vocal fold scarring in a canine model." Ann Otol Rhinol Laryngol **113**(10): 777-85.
Hogikyan, N. D., M. M. Johns, et al. (2001). "Motion-specific laryngeal reinnervation using muscle-nerve-muscle neurotization." Ann Otol Rhinol Laryngol **110**(9): 801-10.
Hogikyan, N. D. and G. Sethuraman (1999). "Validation of an instrument to measure voice-related quality of life (V-RQOL)." J Voice **13**(4): 557-69.
Hogikyan, N. D., W. P. Wodchis, et al. (2000). "Voice-related quality of life (V-RQOL) following type I thyroplasty for unilateral vocal fold paralysis." J Voice **14**(3): 378-86.
Isshiki, N. (1998). "Mechanical and dynamic aspects of voice production as related to voice therapy and phonosurgery." J Voice **12**(2): 125-37.
Isshiki, N., H. Morita, et al. (1974). "Thyroplasty as a new phonosurgical technique." Acta Otolaryngol **78**(5-6): 451-7.
Isshiki, N., M. Tanabe, et al. (1978). "Arytenoid adduction for unilateral vocal cord paralysis." Arch Otolaryngol **104**(10): 555-8.
Jacobson, B. H., A. Johnson, et al. (1997). "The voice handicap index (VHI):development and validation." Am J Speech Lang Pathol **6**: 66-70.
Karpenko, A. N., J. P. Dworkin, et al. (2003). "Cymetra injection for unilateral vocal fold paralysis." Ann Otol Rhinol Laryngol **112**(11): 927-34.
Kaszuba, S. M. and C. G. Garrett (2007). "Strobovideolaryngoscopy and laboratory voice evaluation." Otolaryngol Clin North Am **40**(5): 991-1001, vi.
Katada, A., D. Van Himbergen, et al. (2008). "Evaluation of a deep brain stimulation electrode for laryngeal pacing." Ann Otol Rhinol Laryngol **117**(8): 621-9.
Kelchner, L. N., J. C. Stemple, et al. (1999). "Etiology, pathophysiology, treatment choices, and voice results for unilateral adductor vocal fold paralysis: a 3-year retrospective." J Voice **13**(4): 592-601.
Kokesh, J., P. W. Flint, et al. (1993). "Correlation between stroboscopy and electromyography in laryngeal paralysis." Ann Otol Rhinol Laryngol **102**(11): 852-7.
Koufman, J. A. (1986). "Laryngoplasty for vocal cord medialization: an alternative to Teflon." Laryngoscope **96**(7): 726-31.
Kreiman, J., B. R. Gerratt, et al. (1993). "Perceptual evaluation of voice quality: review, tutorial, and a framework for future research." J Speech Hear Res **36**(1): 21-40.
Kwon, T. K. and R. Buckmire (2004). "Injection laryngoplasty for management of unilateral vocal fold paralysis." Curr Opin Otolaryngol Head Neck Surg **12**(6): 538-42.
Laccourreye, O., L. El Sharkawy, et al. (2005). "Thyroplasty type I with Montgomery implant among native French language speakers with unilateral laryngeal nerve paralysis." Laryngoscope **115**(8): 1411-7.
Laccourreye, O., J. F. Papon, et al. (2003). "Intracordal injection of autologous fat in patients with unilateral laryngeal nerve paralysis: long-term results from the patient's perspective." Laryngoscope **113**(3): 541-5.
Langman, J. (1969). Medical Embryology. Baltimore, The Williams & Wilkins Company.
Lee, S. W., Y. I. Son, et al. (2007). "Voice outcomes of polyacrylamide hydrogel injection laryngoplasty." Laryngoscope **117**(10): 1871-5.
Lewy, R. B. (1983). "Teflon injection of the vocal cord: complications, errors, and precautions." Ann Otol Rhinol Laryngol **92**(5 Pt 1): 473-4.

Lu, F. L., R. R. Casiano, et al. (1996). "Longitudinal evaluation of vocal function after thyroplasty type I in the treatment of unilateral vocal paralysis." Laryngoscope **106**(5 Pt 1): 573-7.
Lundy, D. S., R. R. Casiano, et al. (2000). "Thyroplasty type I: short- versus long-term results." Otolaryngol Head Neck Surg **122**(4): 533-6.
Marie, J. P., D. Dehesdin, et al. (1989). "Selective reinnervation of the abductor and adductor muscles of the canine larynx after recurrent nerve paralysis." Ann Otol Rhinol Laryngol **98**(7 Pt 1): 530-6.
McCulloch, T. M., B. T. Andrews, et al. (2002). "Long-term follow-up of fat injection laryngoplasty for unilateral vocal cord paralysis." Laryngoscope **112**(7 Pt 1): 1235-8.
McCulloch, T. M. and H. T. Hoffman (1998). "Medialization laryngoplasty with expanded polytetrafluoroethylene. Surgical technique and preliminary results." Ann Otol Rhinol Laryngol **107**(5 Pt 1): 427-32.
McCulloch, T. M., H. T. Hoffman, et al. (2000). "Arytenoid adduction combined with Gore-Tex medialization thyroplasty." Laryngoscope **110**(8): 1306-11.
Meurman, Y. (1952). "Operative mediofixation of the vocal cord in complete unilateral paralysis." AMA Arch Otolaryngol **55**(5): 544-53.
Mikaelian, D. O., L. D. Lowry, et al. (1991). "Lipoinjection for unilateral vocal cord paralysis." Laryngoscope **101**(5): 465-8.
Mikus, J. L., J. A. Koufman, et al. (1995). "Fate of liposuctioned and purified autologous fat injections in the canine vocal fold." Laryngoscope **105**(1): 17-22.
Miller, S. (2004). "Voice therapy for vocal fold paralysis." Otolaryngol Clin North Am **37**(1): 105-19.
Miller, T. A. (1988). "Temporalis fascia grafts for facial and nasal contour augmentation." Plast Reconstr Surg **81**(4): 524-33.
Milstein, C. F., L. M. Akst, et al. (2005). "Long-term effects of micronized Alloderm injection for unilateral vocal fold paralysis." Laryngoscope **115**(9): 1691-6.
Montgomery, W. W. and S. K. Montgomery (1997). "Montgomery thyroplasty implant system." Ann Otol Rhinol Laryngol Suppl **170**: 1-16.
Netterville, J. L., J. R. Coleman, Jr., et al. (1998). "Lateral laryngotomy for the removal of Teflon granuloma." Ann Otol Rhinol Laryngol **107**(9 Pt 1): 735-44.
Netterville, J. L., R. E. Stone, et al. (1993). "Silastic medialization and arytenoid adduction: the Vanderbilt experience. A review of 116 phonosurgical procedures." Ann Otol Rhinol Laryngol **102**(6): 413-24.
Nishiyama, K., H. Hirose, et al. (2006). "Long-term result of the new endoscopic vocal fold medialization surgical technique for laryngeal palsy." Laryngoscope **116**(2): 231-4.
Noordzij, J. P. and R. H. Ossoff (2006). "Anatomy and physiology of the larynx." Otolaryngol Clin North Am **39**(1): 1-10.
Payr (1915). "Plastik am Schildknorpel zur Behebung der Folgen einseitiger Stimmbandlähmung." Dtsch Med Wochenschr **43**(1265).
Pearl, A. W., P. Woo, et al. (2002). "A preliminary report on micronized AlloDerm injection laryngoplasty." Laryngoscope **112**(6): 990-6.
Peer, L. (1959). Transplantation of fascia in animals, vols. 1 and 2. Transplantation of tissues. L. Peer. Baltimore, Williams & Wilkins**:** 245-256.
Remacle, M., J. M. Dujardin, et al. (1995). "Treatment of vocal fold immobility by glutaraldehyde-cross-linked collagen injection: long-term results." Ann Otol Rhinol Laryngol **104**(6): 437-41.
Remacle, M., G. Lawson, et al. (2006). "Treatment of vocal fold immobility by injectable homologous collagen: short-term results." Eur Arch Otorhinolaryngol **263**(3): 205-9.
Rihkanen, H. (1998). "Vocal fold augmentation by injection of autologous fascia." Laryngoscope **108**(1 Pt 1): 51-4.

Rihkanen, H., E. Kaliste, et al. (2003). "Processing of fascia for vocal fold injection. A study in vitro and in paralyzed canine vocal folds." Ann Otol Rhinol Laryngol **112**(8): 729-33.
Rodgers, B. J., F. W. Abdul-Karim, et al. (2000). "Histological study of injected autologous fascia in the paralyzed canine vocal fold." Laryngoscope **110**(12): 2012-5.
Rontal, E., M. Rontal, et al. (1983). "Quantitative and objective evaluation of vocal cord function." Ann Otol Rhinol Laryngol **92**(5 Pt 1): 421-3.
Rosen, C. A. and A. A. Thekdi (2004). "Vocal fold augmentation with injectable calcium hydroxylapatite: short-term results." J Voice **18**(3): 387-91.
Rubin, A. D. and R. T. Sataloff (2007). "Vocal fold paresis and paralysis." Otolaryngol Clin North Am **40**(5): 1109-31, viii-ix.
Rubin, H. J. (1965a). "Intracordal Injection of Silicone in Selected Dysphonias." Arch Otolaryngol **81**: 604-7.
Rubin, H. J. (1965b). "Pitfalls in treatment of dysphonias by intracordal injection of synthetics." Laryngoscope **75**(9): 1381-97.
Sataloff, R. T. (2005). Voice Surgery. Treatment of Voice Disorders. San Diego, Oxford, Plural Publishing**:** 222-227.
Sataloff, R. T., J. R. Spiegel, et al. (1991). "Strobovideolaryngoscopy: results and clinical value." Ann Otol Rhinol Laryngol **100**(9 Pt 1): 725-7.
Sercarz, J. A., G. S. Berke, et al. (1992). "Videostroboscopy of human vocal fold paralysis." Ann Otol Rhinol Laryngol **101**(7): 567-77.
Shindo, M. L., L. S. Zaretsky, et al. (1996). "Autologous fat injection for unilateral vocal fold paralysis." Ann Otol Rhinol Laryngol **105**(8): 602-6.
Shiotani, A., B. W. O'Malley, Jr., et al. (1999). "Human insulinlike growth factor 1 gene transfer into paralyzed rat larynx: single vs multiple injection." Arch Otolaryngol Head Neck Surg **125**(5): 555-60.
Sittel, C., M. Echternach, et al. (2006). "Polydimethylsiloxane particles for permanent injection laryngoplasty." Ann Otol Rhinol Laryngol **115**(2): 103-9.
Sulica, L. (2008). "The natural history of idiopathic unilateral vocal fold paralysis: evidence and problems." Laryngoscope **118**(7): 1303-7.
Sunderland, S. (1978). Nerves and Nerve Injuries. London, Churchill Livingston.
Terris, D. J., D. P. Arnstein, et al. (1992). "Contemporary evaluation of unilateral vocal cord paralysis." Otolaryngol Head Neck Surg **107**(1): 84-90.
Thibeault, S. L. and S. Duflo (2008). "Inflammatory cytokine responses to synthetic extracellular matrix injection to the vocal fold lamina propria." Ann Otol Rhinol Laryngol **117**(3): 221-6.
Tsunoda, K., T. Baer, et al. (2001). "Autologous transplantation of fascia into the vocal fold: long-term results of a new phonosurgical technique for glottal incompetence." Laryngoscope **111**(3): 453-7.
Tsunoda, K., K. Kondou, et al. (2005). "Autologous transplantation of fascia into the vocal fold: long-term result of type-1 transplantation and the future." Laryngoscope **115**(12 Pt 2 Suppl 108): 1-10.
Tsunoda, K., M. Takanosawa, et al. (1999). "Autologous transplantation of fascia into the vocal fold: a new phonosurgical technique for glottal incompetence." Laryngoscope **109**(3): 504-8.
Tucker, H. M. (1977). "Reinnervation of the unilaterally paralyzed larynx." Ann Otol Rhinol Laryngol **86**(6 Pt 1): 789-94.
Tucker, H. M. (1989). "Long-term results of nerve-muscle pedicle reinnervation for laryngeal paralysis." Ann Otol Rhinol Laryngol **98**(9): 674-6.
Tucker, H. M. (1999). "Long-term preservation of voice improvement following surgical medialization and reinnervation for unilateral vocal fold paralysis." J Voice **13**(2): 251-6.

Tucker, H. M. and M. Rusnov (1981). "Laryngeal reinnervation for unilateral vocal cord paralysis: long-term results." Ann Otol Rhinol Laryngol **90**(5 Pt 1): 457-9.
Varvares, M. A., W. W. Montgomery, et al. (1995). "Teflon granuloma of the larynx: etiology, pathophysiology, and management." Ann Otol Rhinol Laryngol **104**(7): 511-5.
Woo, P. (1998). "Laryngeal electromyography is a cost-effective clinically useful tool in the evaluation of vocal fold function." Arch Otolaryngol Head Neck Surg **124**(4): 472-5.
Yumoto, E. (1983). "The quantitative evaluation of hoarseness." Arch Otolaryngol **109**(1): 48-52.
Zapanta, P. E. and S. A. Bielamowicz (2004). "Laryngeal abscess after injection laryngoplasty with micronized AlloDerm." Laryngoscope **114**(9): 1522-4.
Zaretsky, L. S., M. L. Shindo, et al. (1995). "Autologous fat injection for vocal fold paralysis: long-term histologic evaluation." Ann Otol Rhinol Laryngol **104**(1): 1-4.
Zeitels, S. M. (2000). "New procedures for paralytic dysphonia: adduction arytenopexy, Goretex medialization laryngoplasty, and cricothyroid subluxation." Otolaryngol Clin North Am **33**(4): 841-54.