



UNIVERSITY OF HELSINKI



<https://helda.helsinki.fi>

Helda

Changing Paradigms in the Management of Acute Uncomplicated Diverticulitis

Chabok, A

SAGE Publications Inc.

2021-06

Chabok, A, Thorisson, A, Nikberg, M, Schultz, JK & Sallinen, V 2021, 'Changing Paradigms in the Management of Acute Uncomplicated Diverticulitis', *Scandinavian Journal of Surgery*, vol. 110, no. 2, 14574969211011032, pp. 180-186. <https://doi.org/10.1177/14574969211011032>

<http://hdl.handle.net/10138/337041>

10.1177/14574969211011032

cc_by

publishedVersion



Downloaded from Helda, University of Helsinki institutional repository.

This is an electronic reprint of the original article.

This reprint may differ from the original in pagination and typographic detail.

Please cite the original version.

Changing paradigms in the management of acute uncomplicated diverticulitis

A. Chabok^{1,2}, A Thorisson^{2,3}, M. Nikberg^{1,2}, J. K. Schultz⁴
and V Sallinen^{5,6}

Scandinavian Journal of Surgery
2021, Vol. 110(2) 180–186
© The Finnish Surgical Society 2021



Article reuse guidelines:
sagepub.com/journals-permissions
DOI: 10.1177/14574969211011032
journals.sagepub.com/home/sjs



Abstract

Left-sided colonic diverticulitis is a common condition with significant morbidity and health care costs in Western countries. Acute uncomplicated diverticulitis which is characterized by the absence of organ dysfunction, abscesses, fistula, or perforations accounts for around 80% of the cases. In the last decades, several traditional paradigms in the management of acute uncomplicated diverticulitis have been replaced by evidence-based routines. This review provides a comprehensive evidence-based and clinical-oriented overview of up-to-date diagnostics with computer tomography, non-antibiotic treatment, outpatient treatment, and surgical strategies as well as follow-up of patients with acute uncomplicated diverticulitis.

Keywords

Colonic diverticulitis, acute uncomplicated diverticulitis, antibiotics, surgery, cancer

Date received: 28 October 2020; accepted: 30 March 2021

Introduction

Diverticular disease was first described during the 19th century by anatomists who described the development of the disease with inflammation and its complications including the formation of abscesses and fistulae (1–3). The disease was described as a surgical rarity during the 19th century. At the beginning of the 20th century, Bland-Sutton noted that the incidence had risen dramatically between 1910 and 1920 (4). In 1916, Telling and Gruner published a comprehensive description of diverticulosis and diverticulitis (5). Burkitt and Painter drew attention to the rate of diverticulitis during the 1960s and 1970s and reported the dependence of environmental factors and that differences in incidence between countries were associated with their level of economic development (6).

Colonic diverticulosis is a common condition affecting up to 70% of the population in Western countries by the age of 80 (7–9). However only 4%–5% of patients will develop symptomatic disease, most commonly acute diverticulitis, and about 20% of these patients will have complicated diverticulitis (10–14). Thus, acute diverticulitis usually has an uncomplicated course, which is characterized by the absence of organ dysfunction, abscesses, fistula, or perforations. This review provides a comprehensive evidence-based and clinical oriented overview of up to date

diagnostics, medical, and surgical treatment as well as follow-up of patients with acute uncomplicated diverticulitis.

Diagnostics

Clinical diagnosis

The most common presentation of patients with diverticulitis is pain in the left lower abdominal quadrant and changes

¹Department of Surgery, Region Västmanland Hospital, Västerås, Sweden

²Centre for Clinical Research Uppsala University, Region Västmanland Hospital, Västerås, Sweden

³Department of Radiology, Region Västmanland Hospital, Västerås, Sweden

⁴Department of Gastrointestinal Surgery, Akershus University Hospital, Lørenskog, Norway

⁵Department of Abdominal Surgery, University of Helsinki and HUS Helsinki University Hospital, Helsinki, Finland

⁶Department of Transplantation and Liver Surgery, University of Helsinki and Helsinki University Hospital, Helsinki, Finland

Corresponding author:

A. Chabok, Department of Surgery, Region Västmanland Hospital Västerås, 72189 Västerås, Sweden.

Email: abbas.chabok@regionvastmanland.se

in bowel habits (constipation or diarrhea) with or without fever. These symptoms are non-specific, and the clinical diagnosis of diverticulitis has a sensitivity of only 45%–72% (15–20); however, the diagnostic accuracy of acute diverticulitis may be increased to 86% with a combination of direct left-sided tenderness, absence of vomiting, and a C-reactive protein (CRP) > 50 mg/L (21,22). Common differential diagnoses for acute diverticulitis include appendicitis, colitis, epiploic appendagitis, and cancer.

Radiology

To confirm the diagnosis and to differentiate uncomplicated from complicated disease, radiological examination is needed. Since the introduction of computed tomography (CT) during the latter part of the 20th century, this modality has taken over as the primary examination method as it has excellent sensitivity for acute diverticulitis, and is rapid and relatively inexpensive to carry out (18,19,23). However, both ultrasonography (US) and magnetic resonance imaging (MRI) are viable alternatives. US is inexpensive and has high spatial resolution and is as sensitive as CT in the hands of an experienced radiologist, with the advantage of delivering no ionic radiation to the patient (24,25). However, the specificity of CT compared to US is higher (96% vs 90%), and US is highly operator-dependent and time-consuming (26). MRI is sensitive to the presence of diverticulitis; however, it is time-consuming, expensive, and susceptible to motion artifacts from the large bowel that can reduce image quality (27). MRI can be used in pregnant patients and has advantages in fistula diagnostics (28).

Even though CT is the most common examination tool used for suspected diverticulitis, CT examination protocols (exposure and choice of contrast) differ between countries and hospitals. In most Nordic countries, full-dose CT with intravenous contrast is used (Fig. 1). The use of rectal contrast medium, which is invasive and uncomfortable for the patient, is considered to add limited information in the acute setting. However, it can be advantageous in patients with chronic diverticulitis, especially for visualizing a fistula tract (29). Although low radiation-dose CT without intravenous contrast has a high sensitivity for diverticulitis, smaller perforations and small pericolic or intramural abscesses can be missed using this technique (30). Therefore, a full-dose CT protocol with intravenous contrast is recommended for patients with suspected acute diverticulitis.

Changes in treatment regimens

In the pre-antibiotic era, treatment of diverticulitis consisted of bed rest and no or low residual diet. These treatments had a rather high symptomatic success rate (31). Despite the lack of controlled studies, antibiotics have been used to treat uncomplicated diverticulitis for many years. The reason for this recommendation was the belief that acute diverticulitis is caused by the translocation of intestinal bacteria through

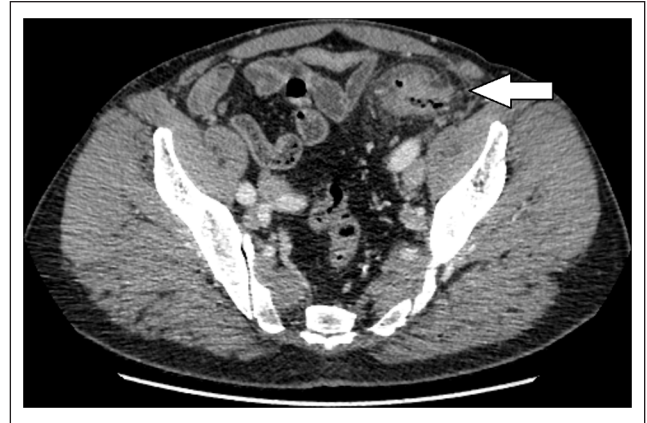

Fig. 1. A patient with lower left abdominal pain. This computed tomography scan of the lower abdomen shows colonic wall thickening in the proximal sigmoid colon, diverticula (arrow), and pericolic fat stranding. A diagnosis of uncomplicated diverticulitis was made.

the mucosa, resulting in bacterial infection. However, the observation that many patients already showed improvements after one dose of antibiotics and sometimes even before receiving antibiotics raised the question as to whether the improvement was actually in response to antibiotics. This was the background for the first and largest to date randomized controlled trial (RCT; the AVOD study) to evaluate the effect of antibiotics on recovery from acute uncomplicated diverticulitis (32). That study showed that antibiotic treatment neither prevents complications and recurrences nor does it reduce symptoms or length of hospital stay. The findings were confirmed in two other RTCs with patient cohorts from Netherlands and New Zealand/Australia (33,34). In addition, several prospective cohort studies with similar findings, from different countries have been published (Table 1) (20,36,38,39).

A long-term follow-up of the AVOD trial with data on 556 patients of the 623 originally included with a mean follow-up time of 11 years showed that antibiotics omission was safe in the long-term (36). The long-term safety of a non-antibiotic treatment protocol was further confirmed by van Dijk et al. (35) with an analysis of long-term data for patients included in the DIABOLO trial.

Strict patient selection in randomized studies is a drawback, and further studies in a population-based setting are necessary for external validity. Following the findings from RCTs, several retrospective population-based observational studies have shown the implementation and the safety of a non-antibiotics policy for AUD (12,40,41). In the light of this new evidence, several international surgical and gastroenterological organizations and have adopted the non-antibiotic policy (11,42–46). However, gastroenterological organizations in the United State have been more conservative in changing their recommendations (47,48). Interestingly, in a collaboration project between the European and American societies of endoscopic surgery (EAES and SAGES)

Table 1. Non-antibiotic therapy in acute uncomplicated diverticulitis.

Study	Year	Number of patients	Design	Outcomes
Chabok et al. (32)	2012	623	RCT	Recovery without complications
Daniels et al. (33)	2017	528	RCT	Time to recovery
van Dijk et al. (35)	2018	468	Follow-up RCT	Complications, recurrence, and surgery
Isacson et al. (36)	2019	556	Follow-up RCT	Complications, recurrence, and surgery
Jaung et al. (34)	2020	180	RCT	Hospital stay
Isacson et al. (37)	2015	155	Prospective	Admission
Mali et al. (38)	2016	161	Prospective	Admission and complications
Estrada et al. (39)	2016	77	Prospective	Complications

RCT: randomized controlled trial; IPDMA: individual participant data meta-analysis.

Table 2. Outpatient management for acute uncomplicated diverticulitis.

Study	Year	Number of patients	Design	Antibiotics	Treatment failure rate (%)
Moya et al. (53)	2012	32	Prospective	Yes	6.3
Biondo et al. (54)	2014	132	RCT	Yes	5.3
Isacson et al. (37)	2015	155	Prospective	No	2.6
Mali et al. (38)	2016	140	Prospective	No	2.9
Estrada et al. (39)	2016	77	Prospective	No	11

RCT: randomized controlled trial.

non-antibiotic policy in AUD was an area of disagreement. Only 26% of the members agreed on the consensus policy and as many as 50% disagreed that the available evidence would change their practice (49). This illustrates that strong evidence alone may not be enough to change traditional treatment habits. Further efforts are needed to convince colleagues around the world that in the absence of septicemia, antibiotics have no place in the management of immunocompetent patients with AUD.

Inpatient versus outpatient treatments

In recent years, outpatient treatment has gained much attention. In a systematic review, outpatient treatment in selected groups was shown to be safe, reduced healthcare costs considerably, and did not increase the risk of complications, revealing a pooled readmission rate of 7% and very low rates of surgical intervention (50,51). The concept of outpatient treatment without antibiotics was studied for the first time in a prospective cohort study (the PVOD trial) including 155 patients with CT-verified AUD (37). Only four patients (2.6%) were readmitted to hospital because of treatment failure, with none of them requiring surgical intervention. In 2018, Isacson et al. (52) showed that the outpatient regimen for uncomplicated diverticulitis halved the healthcare costs for this patient group with no increased risk of complications. Similarly, in another prospective trial, 140 patients with uncomplicated diverticulitis were treated as outpatients without antibiotics and only four (3%) needed to be admitted to the hospital during follow-up (38). The presented treatment failure rates in the literature

vary between 3% and 11% for outpatient treatment (Table 2) (53,54). The first randomized trial on non-antibiotic outpatient treatment of uncomplicated diverticulitis (DINAMO study) presented at the virtual ESCP meeting in 2020 showed similar results to the PVOD trial. However, an outpatient regimen should only be considered in patients with low comorbidity, proven immunocompetence, and the ability to tolerate oral intake.

Surgery—is it necessary?

In 1916, Telling stated in the *British Journal of Surgery* that the treatment of diverticula and diverticulitis “comprised in one word—Surgery” (5). Much has changed since then, and there is now a broad consensus that acute surgery is not indicated in patients with AUD. Even minor complications like small abscesses or covered perforations with extra luminal air can normally be handled conservatively, whereas emergency surgery is mainly reserved to severe complications (bowel obstruction or free perforation with peritonitis) (55,56). Elective sigmoid resection after one or more episodes of uncomplicated diverticulitis has been advocated after two episodes of uncomplicated diverticulitis (57–59). The rationale was to prevent complications. However, several studies have shown that the risk of severe complications decreases with the number of diverticulitis episodes ((14,60–63). Consequently, international guidelines have been revised, and there is a consensus that the decision for elective resection should be individualized and not based on the number of previous episodes (49,64). The only

Table 3. Elective surgery after acute uncomplicated diverticulitis.

Study	Year	Design	Main limitations	Main conclusions
LASER (71)	2020	RCT	Under-powered	Favors surgery
DIRECT trial primary outcome: long-term results (70,72)	2017, 2019	RCT	Under-powered Limited representativeness	Favors surgery
Polese et al. (68)	2018	Retrospective parallel group	Selection bias.	Favors surgery
Brandlhuber et al. (66)	2018	Retrospective parallel group	Selection bias	Favors conservative treatment
von Strauss Und Torney et al. (69)	2017	Cross-sectional cohort	HRQoL not evaluated, based on administrative data	Decline in proportion of colon resections over time
Boostrom et al. (65)	2012	Retrospective single cohort	No control group	Improved symptoms after surgery
Klarenbeek et al. (67)	2010	Retrospective parallel group	Selection bias HRQoL not evaluated	Favors conservative treatment for majority of patients

RCT: randomized controlled trial; HRQoL: health-related quality of life.

legitimate goal of sigmoid resection in an elective setting is to improve the patient's quality of life. Generally, there are two categories of patients: those with frequent recurrences of AUD and those with ongoing symptoms after an episode of uncomplicated diverticulitis.

There is a variety of mainly retrospective cohort studies investigating elective surgery after uncomplicated diverticulitis, all of which were hampered by a high risk of selection bias (65–69). Fortunately, two RCTs comparing conservative treatment to elective sigmoid resection for recurrent or persistent painful diverticulitis have been published: DIRECT and LASER trials (70,71). The trials' design was highly similar, but DIRECT trial has published results of 5-year follow-up, while LASER trial has only results for 6-month follow-up. A significant difference in health-related quality of life (HRQoL) favoring surgery was observed after 6 months in both trials, but also at 1 year and 5 years in DIRECT trial (70,72). However, premature abortion of both trials (DIRECT trial due to low recruitment and LASER trial due to benefit in interim analysis) may have led to an overestimation of the effect size (73). Although both trials favor elective sigmoid resection for patients with three or more episodes of diverticulitis within 2-year period, the risks of surgery must be born in mind. Risk for stoma was 5%–21%, and severe complication requiring reoperation occurred in 10%–28% patients randomized to surgery arm (70,71). From an economical point of view and based on DIRECT trial data, elective sigmoid resection was also found to be cost-effective (74). Some limitations of the trials are worth mentioning. Both trials were open-labeled, and a placebo effect in HRQoL results is likely. Although there was minimal (4%) cross-over from conservative treatment to surgery in LASER trial during the first 6 months, significant amount of patients crossed over to surgery in DIRECT trial (23% within 6 months, 46% at 5 years), which means that the results must be interpreted with caution. Key

studies on elective sigmoid resection after uncomplicated diverticulitis are summarized in Table 3 (65–72).

Any decision on sigmoid resection in patients with AUD should be individualized, and the advantages of elective sigmoid resection, namely superior HRQoL, lower pain, and fewer recurrences, need to be balanced against the significant risk of major complications of surgery.

Surgical techniques

Although evidence is limited, currently elective sigmoid resection with primary anastomoses is usually performed with minimal invasive techniques (75). Hartmann's procedure or temporary diversion of colonic anastomoses is preserved in patients with severe comorbidity or in cases with anastomotic complications. The main advantages of the laparoscopic approach are faster recovery, reduced wound infection rates and a reduced frequency of hernias; however, the conversion rates to open surgery is around 13% (76,77). Robotic sigmoid resection compared to laparoscopic resection might result in lower conversion rates of around 8% (77). More controversial is the extent of colonic resection and whether a central vessel ligation should be performed. Based on retrospective cohort studies, it is widely recommended that the lower resection margin should be at the colorectal junction and that all macroscopically inflamed bowel should be removed (78,79). However, there is no evidence for the removal of all diverticula-bearing proximal colon. Furthermore, there is no rationale for central vessel ligation in diverticular disease when malignancy has been ruled out. As central vessel ligation bears a theoretical risk of impaired perfusion of the colorectal anastomosis and a risk of nerve damage, it is not generally recommended. However, the evidence for this recommendation is sparse (80).

Follow-up

There is no consensus in the literature with regards to the need for a routine colonic examination after an episode of AUD. Meta-analyses of studies on cancer prevalence after an episode of acute diverticulitis have shown varying results with a prevalence of malignancy of 0.5%–2% for uncomplicated diverticulitis and 7.9%–10.8% for complicated diverticulitis (81,82). Given the high rate of carcinoma in patients diagnosed with complicated diverticulitis, all patients treated non-surgically for complicated diverticulitis should undergo a colonic examination to rule out malignancy. In patients with CT-verified uncomplicated diverticulitis, the prevalence for colorectal cancer is similar to predicted prevalence in screening populations of similar age in the majority of studies (32,83–88). However, some studies have found higher cancer prevalence in patients with diverticulitis, making omission of routine follow-up colonoscopy difficult (20,89).

In our opinion, omission of a routine follow-up colonoscopy could be considered in patients with CT-verified uncomplicated diverticulitis, where the CT scans have been re-evaluated by a gastrointestinal radiologist, the patient has no sign of colorectal cancer such as anemia, haematochezia, or change in bowel habit and where the symptoms of diverticulitis have diminished at a 4-week follow-up.

Declaration of conflicting interests

The author(s) declared no potential conflicts of interest with respect to the research, authorship, and/or publication of this article.

Funding

The author(s) disclosed receipt of the following financial support for the research, authorship, and/or publication of this article: Supported by research grants from the County of Västmanland Sweden.

ORCID iDs

A. Chabok  <https://orcid.org/0000-0001-9662-5045>

J. K. Schultz  <https://orcid.org/0000-0002-9427-2087>

References

- Voigtel. Verdauungsorgane, Vom Darmkanal überhaupt. Handbuch Der Pathologischen Anatomie Vol 2. Magdeburg: Hemmerde Und Schwetschke, 1804, pp. 573–577.
- Cruveilhier J: *Traité d'Anatomie Pathologique Générale*. Paris: Bailliere, 1849.
- Graser E: Das falsche Darmdivertikel. *Arch Klin Chir* 1899;59:638–647.
- Bland-Sutton J: Proceedings of the Royal Society of Medicine, section of surgery. 1920;13(64).
- Telling W: Acquired diverticula, diverticulitis and peridiverticulitis of the large intestine. *Br J Surg* 1917;4:468–530.
- Painter NS, Burkitt DP: Diverticular disease of the colon: A deficiency disease of Western civilization. *Br Med J* 1971;2(5759):450–454.
- Jacobs DO: Clinical practice. Diverticulitis. *N Engl J Med* 2007;357(20):2057–2066.
- Peery AF, Keku TO, Martin CF et al: Distribution and characteristics of colonic diverticula in a United States screening population. *Clin Gastroenterol Hepatol* 2016;14(7):980–985.
- Shabanzadeh DM, Wille-Jørgensen P: Antibiotics for uncomplicated diverticulitis. *Cochrane Database Syst Rev* 2012;11:CD009092.
- Shahedi K, Fuller G, Bolus R et al: Long-term risk of acute diverticulitis among patients with incidental diverticulosis found during colonoscopy. *Clin Gastroenterol Hepatol* 2013;11(12):1609–1613.
- Andersen JC, Bundgaard L, Elbrond H et al: Danish national guidelines for treatment of diverticular disease. *Dan Med J* 2012;59(5): C4453.
- Chabok A, Andreasson K, Nikberg M: Low risk of complications in patients with first-time acute uncomplicated diverticulitis. *Int J Colorectal Dis* 2017;32(12):1699–1702.
- Biondo S, Lopez Borao J, Millan M et al: Current status of the treatment of acute colonic diverticulitis: A systematic review. *Colorectal Dis* 2012;14(1): e1–e11.
- Alexanderson BT, Stefansson T: Incidence and recurrence rate of sigmoid diverticulitis in patients requiring admission to hospital in Iceland from 1985 to 2014: Nationwide population-based register study. *BJS Open* 2020;4:1217–1226.
- Goh H, Bourne R: Non-steroidal anti-inflammatory drugs and perforated diverticular disease: A case-control study. *Ann R Coll Surg Engl* 2002;84(2):93–96.
- Wilson RG, Smith AN, Macintyre IM: Complications of diverticular disease and non-steroidal anti-inflammatory drugs: A prospective study. *Br J Surg* 1990;77(10):1103–1104.
- Hiltunen KM, Kolehmainen H, Vuorinen T et al: Early water-soluble contrast enema in the diagnosis of acute colonic diverticulitis. *Int J Colorectal Dis* 1991;6(4):190–192.
- Rao PM, Rhea JT, Novelline RA et al: Helical CT with only colonic contrast material for diagnosing diverticulitis: Prospective evaluation of 150 patients. *AJR Am J Roentgenol* 1998;170(6):1445–1449.
- Werner A, Diehl SJ, Farag-Soliman M et al: Multi-slice spiral CT in routine diagnosis of suspected acute left-sided colonic diverticulitis: A prospective study of 120 patients. *Eur Radiol* 2003;13(12):2596–2603.
- Azhar N, Buchwald P, Ansari HZ et al: Risk of colorectal cancer following CT-verified acute diverticulitis: A nationwide population-based cohort study. *Colorectal Dis* 2020;22(10):1406–1414.
- Andeweg CS, Knobben L, Hendriks JC et al: How to diagnose acute left-sided colonic diverticulitis: Proposal for a clinical scoring system. *Ann Surg* 2011;253(5):940–946.
- Lameris W, van Randen A, van Gulik TM et al: A clinical decision rule to establish the diagnosis of acute diverticulitis at the emergency department. *Dis Colon Rectum* 2010;53(6):896–904.
- Rotert H, Noldge G, Encke J et al: [The value of CT for the diagnosis of acute diverticulitis]. *Radiologe* 2003;43(1):51–58.
- Liljegren G, Chabok A, Wickbom M et al: Acute colonic diverticulitis: A systematic review of diagnostic accuracy. *Colorectal Dis* 2007;9(6):480–488.
- Lembcke B: Diagnosis, differential diagnoses, and classification of diverticular disease. *Viszeralmedizin* 2015;31(2):95–102.
- Andeweg CS, Wegdam JA, Groenewoud J et al: Toward an evidence-based step-up approach in diagnosing diverticulitis. *Scand J Gastroenterol* 2014;49(7):775–784.
- Heverhagen JT, Sitter H, Zielke A et al: Prospective evaluation of the value of magnetic resonance imaging in sus-

- pected acute sigmoid diverticulitis. *Dis Colon Rectum* 2008;51(12):1810–1815.
28. VanBuren WM, Lightner AL, Kim ST et al: Imaging and surgical management of anorectal vaginal fistulas. *Radiographics* 2018;38(5):1385–1401.
 29. Sugi MD, Sun DC, Menias CO et al: Acute diverticulitis: Key features for guiding clinical management. *Eur J Radiol* 2020;128: 109026.
 30. Thorisson A, Nikberg M, Torkzad MR et al: Diagnostic accuracy of acute diverticulitis with unenhanced low-dose CT. *BJS Open* 2020;4(4):659–665.
 31. Rankin F: Diverticulitis of the colon. *Surg Gynecol Obstet* 1930;50: 836–847.
 32. Chabok A, Pahlman L, Hjern F et al: Randomized clinical trial of antibiotics in acute uncomplicated diverticulitis. *Br J Surg* 2012;99(4):532–539.
 33. Daniels L, Ünlü Ç, de Korte N et al: Randomized clinical trial of observational versus antibiotic treatment for a first episode of CT-proven uncomplicated acute diverticulitis. *Br J Surg* 2017;104(1):52–61.
 34. Jaung R, Nisbet S, Gosselink MP et al: Antibiotics do not reduce length of hospital stay for uncomplicated diverticulitis in a pragmatic double-blind randomized trial. *Clin Gastroenterol Hepatol* 2020;19:503–510.e1.
 35. van Dijk ST, Daniels L, Ünlü Ç et al: Long-term effects of omitting antibiotics in uncomplicated acute diverticulitis. *Am J Gastroenterol* 2018;113(7):1045–1052.
 36. Isacson D, Smedh K, Nikberg M et al: Long-term follow-up of the AVOD randomized trial of antibiotic avoidance in uncomplicated diverticulitis. *Br J Surg* 2019;106(11):1542–1548.
 37. Isacson D, Thorisson A, Andreasson K et al: Outpatient, non-antibiotic management in acute uncomplicated diverticulitis: A prospective study. *Int J Colorectal Dis* 2015;30(9):1229–1234.
 38. Mali JP, Mentula PJ, Leppaniemi AK et al: Symptomatic treatment for uncomplicated acute diverticulitis: A prospective cohort study. *Dis Colon Rectum* 2016;59(6):529–534.
 39. Estrada Ferrer O, Ruiz Edo N, Hidalgo Grau LA et al: Selective non-antibiotic treatment in sigmoid diverticulitis: Is it time to change the traditional approach. *Tech Coloproctol* 2016;20(5):309–315.
 40. Brochmann ND, Schultz JK, Jakobsen GS et al: Management of acute uncomplicated diverticulitis without antibiotics: A single-centre cohort study. *Colorectal Dis* 2016;18(11):1101–1107.
 41. Isacson D, Andreasson K, Nikberg M et al: No antibiotics in acute uncomplicated diverticulitis: Does it work. *Scand J Gastroenterol* 2014;49(12):1441–1446.
 42. Andeweg CS, Mulder IM, Felt-Bersma RJ et al: Guidelines of diagnostics and treatment of acute left-sided colonic diverticulitis. *Dig Surg* 2013;30(4-6):278–292.
 43. Binda GA, Cuomo R, Laghi A et al: Practice parameters for the treatment of colonic diverticular disease: Italian society of colon and rectal surgery (SICCR) guidelines. *Tech Coloproctol* 2015;19(10):615–626.
 44. Leifeld L, Germer CT, Bohm S et al: [S2k guidelines diverticular disease/diverticulitis]. *Z Gastroenterol* 2014;52(7):663–710.
 45. Pietrzak A, Bartnik W, Szczepkowski M et al: Polish interdisciplinary consensus on diagnostics and treatment of colonic diverticulosis (2015). *Pol Przegl Chir* 2015;87(4):203–220.
 46. Sartelli M, Catena F, Ansaloni L et al: WSES Guidelines for the management of acute left sided colonic diverticulitis in the emergency setting. *World J Emerg Surg* 2016;11: 37.
 47. Feingold D, Steele SR, Lee S et al: Practice parameters for the treatment of sigmoid diverticulitis. *Dis Colon Rectum* 2014;57(3):284–294.
 48. Stollman N, Smalley W, Hirano I et al: American gastroenterological association institute guideline on the management of acute diverticulitis. *Gastroenterology* 2015;149(7):1944–1949.
 49. Francis NK, Sylla P, Abou-Khalil M et al: EAES and SAGES 2018 consensus conference on acute diverticulitis management: Evidence-based recommendations for clinical practice. *Surg Endosc* 2019;33(9):2726–2741.
 50. van Dijk ST, Bos K, de Boer MGJ et al: A systematic review and meta-analysis of outpatient treatment for acute diverticulitis. *Int J Colorectal Dis* 2018;33(5):505–512.
 51. Cirocchi R, Randolph JJ, Binda GA et al: Is the outpatient management of acute diverticulitis safe and effective? A systematic review and meta-analysis. *Tech Coloproctol* 2019;23(2):87–100.
 52. Isacson D, Andreasson K, Nikberg M et al: Outpatient management of acute uncomplicated diverticulitis results in health-care cost savings. *Scand J Gastroenterol* 2018;53(4): 449–452.
 53. Moya P, Arroyo A, Pérez-Legaz J et al: Applicability, safety and efficiency of outpatient treatment in uncomplicated diverticulitis. *Tech Coloproctol* 2012;16(4):301–307.
 54. Biondo S, Golda T, Kreisler E et al: Outpatient versus hospitalization management for uncomplicated diverticulitis: A prospective, multicenter randomized clinical trial (DIVER Trial). *Ann Surg* 2014;259(1):38–44.
 55. Gregersen R, Mortensen LQ, Burcharth J et al: Treatment of patients with acute colonic diverticulitis complicated by abscess formation: A systematic review. *Int J Surg* 2016;35: 201–208.
 56. Mali J, Mentula P, Leppaniemi A et al: Determinants of treatment and outcomes of diverticular abscesses. *World J Emerg Surg* 2019;14: 31.
 57. Roberts P, Abel M, Rosen L et al: Practice parameters for sigmoid diverticulitis. The standards task force american society of colon and rectal surgeons. *Dis Colon Rectum* 1995;38(2): 125–132.
 58. Kohler L, Sauerland S, Neugebauer E: Diagnosis and treatment of diverticular disease: Results of a consensus development conference. *Surg Endosc* 1999;13(4):430–436.
 59. Wong WD, Wexner SD, Lowry A et al: Practice parameters for the treatment of sigmoid diverticulitis—Supporting documentation. *Dis Colon Rectum* 2000;43(3):290–297.
 60. Haglund U, Hellberg R, Johnsen C et al: Complicated diverticular disease of the sigmoid colon. An analysis of short and long term outcome in 392 patients. *Ann Chir Gynaecol* 1979;68(2): 41–46.
 61. Ritz JP, Lehmann KS, Frericks B et al: Outcome of patients with acute sigmoid diverticulitis: Multivariate analysis of risk factors for free perforation. *Surgery* 2011;149(5):606–613.
 62. Janes S, Meagher A, Frizelle FA: Elective surgery after acute diverticulitis. *Br J Surg* 2005;92(2):133–142.
 63. Buchs NC, Konrad-Mugnier B, Jannot AS et al: Assessment of recurrence and complications following uncomplicated diverticulitis. *Br J Surg* 2013;100(7):976–979; discussion979.

64. Hall J, Hardiman K, Lee S et al: The American society of colon and rectal surgeons clinical practice guidelines for the treatment of left-sided colonic diverticulitis. *Dis Colon Rectum* 2020;63(6):728–747.
65. Boostrom SY, Wolff BG, Cima RR et al: Uncomplicated diverticulitis, more complicated than we thought. *J Gastrointest Surg* 2012;16(9):1744–1749.
66. Brandlhuber M, Genzinger C, Brandlhuber B et al: Long-term quality of life after conservative treatment versus surgery for different stages of acute sigmoid diverticulitis. *Int J Colorectal Dis* 2018;33(3):317–326.
67. Klarenbeek BR, Samuels M, van der Wal MA et al: Indications for elective sigmoid resection in diverticular disease. *Ann Surg* 2010;251(4):670–674.
68. Polese L, Bressan A, Savarino E et al: Quality of life after laparoscopic sigmoid resection for uncomplicated diverticular disease. *Int J Colorectal Dis* 2018;33(5):513–523.
69. von Strauss Und Torney M, Thommen S, Dell-Kuster S et al: Surgical treatment of uncomplicated diverticulitis in Switzerland: Comparison of population-based data over two time periods. *Colorectal Dis* 2017;19(9):840–850.
70. van de Wall BJM, Stam MAW, Draaisma WA et al: Surgery versus conservative management for recurrent and ongoing left-sided diverticulitis (DIRECT trial): An open-label, multicentre, randomised controlled trial. *Lancet Gastroenterol Hepatol* 2017;2(1):13–22.
71. Santos A, Mentula P, Pinta T et al: Comparing laparoscopic elective sigmoid resection with conservative treatment in improving quality of life of patients with diverticulitis: The laparoscopic elective sigmoid resection following diverticulitis (LASER) randomized clinical trial. *JAMA Surg* 2020;156:129–136.
72. Bolkenstein HE, Consten ECJ, van der Palen J et al: Long-term outcome of surgery versus conservative management for recurrent and ongoing complaints after an episode of diverticulitis: 5-year follow-up results of a multicenter randomized controlled trial (DIRECT-Trial). *Ann Surg* 2019;269(4):612–620.
73. Bassler D, Briel M, Montori VM et al: Stopping randomized trials early for benefit and estimation of treatment effects: Systematic review and meta-regression analysis. *JAMA* 2010;303(12):1180–1187.
74. Bolkenstein HE, de Wit GA, Consten ECJ et al: Cost-effectiveness analysis of a multicentre randomized clinical trial comparing surgery with conservative management for recurrent and ongoing diverticulitis (DIRECT trial). *Br J Surg* 2019;106(4):448–457.
75. Abraha I, Binda GA, Montedori A et al: Laparoscopic versus open resection for sigmoid diverticulitis. *Cochrane Database Syst Rev* 2017;11: CD009277.
76. Al-Temimi MH, Chandrasekaran B, Agapian J et al: Robotic versus laparoscopic elective colectomy for left side diverticulitis: A propensity score-matched analysis of the NSQIP database. *Int J Colorectal Dis* 2019;34(8):1385–1392.
77. Bastawrous AL, Landmann RG, Liu Y et al: Incidence, associated risk factors, and impact of conversion to laparotomy in elective minimally invasive sigmoidectomy for diverticular disease. *Surg Endosc* 2020;34(2):598–609.
78. Thaler K, Baig MK, Berho M et al: Determinants of recurrence after sigmoid resection for uncomplicated diverticulitis. *Dis Colon Rectum* 2003;46(3):385–388.
79. Benn PL, Wolff BG, Ilstrup DM: Level of anastomosis and recurrent colonic diverticulitis. *Am J Surg* 1986;151(2):269–271.
80. Cirocchi R, Trastulli S, Farinella E et al: Is inferior mesenteric artery ligation during sigmoid colectomy for diverticular disease associated with increased anastomotic leakage? A meta-analysis of randomized and non-randomized clinical trials. *Colorectal Dis* 2012;14(9): e521–e559.
81. Meyer J, Orci LA, Combescure C et al: Risk of colorectal cancer in patients with acute diverticulitis: A systematic review and meta-analysis of observational studies. *Clin Gastroenterol Hepatol* 2019;17(8):1448–1456.
82. Rottier SJ, van Dijk ST, van Geloven AAW et al: Meta-analysis of the role of colonoscopy after an episode of left-sided acute diverticulitis. *Br J Surg* 2019;106(8):988–997.
83. Andrade P, Ribeiro A, Ramalho R et al: Routine colonoscopy after acute uncomplicated diverticulitis—Challenging a putative indication. *Dig Surg* 2017;34(3):197–202.
84. Brar MS, Roxin G, Yaffe PB et al: Colonoscopy following nonoperative management of uncomplicated diverticulitis may not be warranted. *Dis Colon Rectum* 2013;56(11):1259–1264.
85. Schmilovitz-Weiss H, Yalunin E, Boaz M et al: Does a colonoscopy after acute diverticulitis affect its management?: A single center experience. *J Clin Gastroenterol* 2012;46(4):317–320.
86. Westwood DA, Eglinton TW, Frizelle FA: Routine colonoscopy following acute uncomplicated diverticulitis. *Br J Surg* 2011;98(11):1630–1634.
87. Sallinen V, Mentula P, Leppaniemi A: Risk of colon cancer after computed tomography-diagnosed acute diverticulitis: Is routine colonoscopy necessary. *Surg Endosc* 2014;28(3): 961–966.
88. Suhardja TS, Norhadi S, Seah EZ et al: Is early colonoscopy after CT-diagnosed diverticulitis still necessary. *Int J Colorectal Dis* 2017;32(4):485–489.
89. Ramphal W, Schreinemakers JMJ, Seerden TCJ et al: Tumour characteristics of patients with colorectal cancer after acute uncomplicated diverticulitis. *Dig Dis* 2018;36(5):362–368.