



UNIVERSITY OF HELSINKI



<https://helda.helsinki.fi>

Helda

Plunging ranula - patient characteristics, treatment, and comparison between different populations

Lyly, Annina

Taylor and Francis Ltd.

2017

Lyly, A, Castren, E, Aronniemi, J & Klockars, T 2017, 'Plunging ranula - patient characteristics, treatment, and comparison between different populations', *Acta Oto-Laryngologica*, vol. 137, no. 12, pp. 1271-1274. <https://doi.org/10.1080/00016489.2017.1357082>

<http://hdl.handle.net/10138/311343>

10.1080/00016489.2017.1357082

acceptedVersion

Downloaded from Helda, University of Helsinki institutional repository.

This is an electronic reprint of the original article.

This reprint may differ from the original in pagination and typographic detail.

Please cite the original version.

Plunging ranula – patient characteristics, treatment, and comparison between different populations

Lyly Annina*, Castrén Eeva*, Aronniemi Johanna**, Klockars Tuomas*

*Department of Otorhinolaryngology – Head and Neck Surgery, Helsinki University Hospital and University of Helsinki, Helsinki, Finland

**Department of Radiology, HUS Medical Imaging Center, Helsinki University Hospital and University of Helsinki, Helsinki, Finland

Correspondence to: Annina Lyly, annina.lyly@helsinki.fi, tel. +358-50-5455051

Postal address: HYKS Korvaklinikka, Kasarmikatu 11-13, 00100 Helsinki

Word count: 1605

Abstract

Objectives: To review our clinical experience and characteristics of Finnish patients with plunging ranula and compare our results with reports from other populations.

Design: A retrospective study from the electronic hospital records between 2005-2016.

Setting: The Department of Otorhinolaryngology and Head & Neck Surgery of Helsinki University Hospital, Finland.

Results: We describe the characteristics and treatment of 41 patients with MRI-confirmed plunging ranula. Most of our patients were young adults and 88% of them were male. Surgery and sclerotherapy were used for treatment.

Conclusions: The vast majority of Finnish plunging ranula patients in our cohort were male, suggesting significant population-related differences in plunging ranula gender distribution. Transoral surgery seemed to result in lowest recurrence rate and was the most common treatment in our clinic.

Introduction

Plunging ranula is a pseudocyst consisting of salivary extravasation originating from the sublingual salivary gland (SLG). This 'plunging' traverses through the mylohyoideus muscle to the submandibular space and may extend into deeper cervical spaces. Possible mechanisms of formation include trauma of the SLG duct, defects in the mylohyoid muscle, or herniation of SLG through the mylohyoid (1). Genetic component has been suggested to play a role in the pathogenesis, as plunging ranulas are more common in certain ethnic groups (2) .

Plunging ranulas are usually diagnosed in early adulthood. Typically, the patient has unilateral, progressive, or recurrent painless neck swelling without associated oral swelling. Diagnosis is based on clinical evaluation and imaging. Misdiagnoses are not rare as plunging ranulas may mimic other neck masses, e.g. abscesses, lymphatic malformations, thyroglossal or branchial cysts, or lipomas (1,3). Magnetic resonance imaging (MRI), computer tomography, and ultrasonography with fine-needle aspiration cytology may be used for differential diagnosis. Treatment options for plunging ranulas include simple aspiration, sclerotherapy and surgery (transoral or transcervical) (4).

We describe the characteristics and treatment of 41 patients with plunging ranulas at the Helsinki University Hospital (HUH) and compare our findings with previous reports from other populations.

Materials and Methods

Ethical considerations

An institutional review board approval was granted for this retrospective study based on hospital records only.

Setting and data collection

HUH is a tertiary care center providing specialist-level care for approximately 1.6 million people. The data for this study was collected retrospectively by reviewing the HUH's electronic patient records covering years 2005-2016. The primary search was based on any of the following: 1) The ICD-10 diagnosis code for salivary gland extravasation cyst (K11.6), 2) the operation code ELB20 from the Nordic Classification of Surgical Procedures (NCSP) or 3) selecting all patients with submandibular swelling from HUH's vascular anomaly register. The primary search resulted in more than 300 patients and the electronic hospital records of all these patients were evaluated. A 1.5 Tesla MRI study with gadolinium enhancement was available from all patients. The MRI studies were re-evaluated by one radiologist and only patients with MRI confirming the diagnosis of plunging ranula were included for our analyses (Figure 1).

Results

Literature review

A PubMed search using the term "plunging ranula" yielded 70 abstracts, of which only those in English and published after year 2000 were evaluated. To compare the characteristics of plunging ranula in different populations we selected 10 publications with patient demographics for further analyses based on sample size and population coverage (1,2,4-11) (Table 1).

Our patients

We identified 41 patients with an MRI-confirmed plunging ranula. These patients were on average 29 years old, and the majority, 88%, were male (Table 2). No pediatric patients were identified. Plunging ranula located on the left side in 51% (21/41), right in 43% (18/41), and was bilateral in 5% (2/41) of the cases (Table 1).

Of the 41 patients, the initial MRI-based diagnosis suggested by radiologists was lymphatic malformation in 39% (16/41), plunging ranula in 27% (11/41), plunging ranula or lymphatic malformation in 12% (5/41) or other lesion in 22% (9/41) (Table 3). Fine needle aspiration cytology was taken from 16 (39%) patients and salivary amylase measurement from three (7%) patients.

Treatment

Surgery was the primary treatment for 18 patients (44%). Fourteen patients (34%) received sclerotherapy as a primary treatment, of which eight patients required further surgery due to insufficient sclerotherapy response. Nine patients (22%) did not wish any intervention (Table 3). Five patients were operated more than once (including surgery before 2005). The most common surgical approach was transoral (19/26, 73%). Three patients (3/7, 43%) needed re-operation after previous transcervical surgery whereas only one (1/19, 5%) needed additional surgery after transoral excision of the sublingual gland. Because our data is based on hospital records, the rate of complications is only suggestive; complications were seen in eight patients (30%), seven of which had been treated surgically, and one with sclerotherapy. Complications were assessed from grade I to V using the Clavien-Dindo classification of complication (12), standardized and widely used in various surgical but also in sclerotherapy settings (13,14). Severity of complications ranged from grade II to IIIb, and consisted mostly of local infections.

Discussion

To our knowledge, this is by far the largest patient cohort of Caucasian origin. We describe 41 patients, the second largest cohort being only ten patients. We found that a significant majority of

our plunging ranula patients were male, suggesting significant population-related differences in plunging ranula gender distribution.

Comparison with other studies

The incidence of plunging ranulas varies between populations. A recent epidemiological study conducted in New Zealand found Maoris and Pacific Islanders 10 times more likely to have a plunging ranula than Europeans (2). Also the gender distribution seems to vary between populations: studies conducted in Asian (8,10,11) show a moderate male predominance (59%), and in the multi-ethnic New Zealand, plunging ranula is equally common in both genders (2). The Finnish population, however, seems to differ regarding gender ratio: the majority (88%) of our patients were men. Therefore, ethnic background may not only have an impact on the incidence of plunging ranula but also on the gender distribution (Table 1).

The age distribution of plunging ranula appears to be similar in different populations, majority of patients being young adults (Table 1). Reports from Asia describe pediatric cases from 3 years old upwards (Table 1), whereas our youngest patient was 15 years old. It is possible, that there is congenital predisposition to plunging ranula in some ethnic groups, as previously suggested by Morton et al. (15). All in all, pediatric cases are rather rare, as are the middle-aged and older patients, raising a question of spontaneous recovery. If this is the case, patients should rather be followed-up than routinely operated on.

Diagnostics

MRI is valuable in differentiating plunging ranula from other cystic cervical masses (16,17). Plunging ranula typically appears as a well-defined fluid collection in the submandibular space with signal

high in T2- and low in T1- weighted sequences. The margins are often slightly enhancing after gadolinium suggesting previous inflammation. On the other hand, solid component or restricted diffusion are always absent. As a most important differentiating feature, a narrow extension connects the submandibular collection with the sublingual space, either around the posterior border of the mylohyoid muscle or through a defect in the anterior part of the muscle ("Tail-sign") (16,17) (Figure 1). Moreover, a concomitant partial herniation of the SLG through the mylohyoid defect is commonly visible.

Fine needle aspiration and amylase measurement are necessary in cases, in which clinical evaluation and MRI cannot differentiate a plunging ranula from other lymphatic lesions, as elevated levels of salivary amylase are characteristic to plunging ranula fluid (1).

Our treatment results

Due to our study design, we can draw only limited conclusions from the treatment outcomes and complications. Our results imply that transoral surgery results in lower recurrence rate than transcervical approach. The complications related to transoral surgery were mainly mild postoperative infections. Therefore, our findings support the current literature: recurrence rates are low and possible complications minor (1,4,6,18).

A few reports propose OK-432 sclerotherapy as a primary, less-invasive treatment option for plunging ranula (19,20). These relatively limited studies (from 9 to 12 patients) report total or near-total shrinkage rates varying between 52% and 83%. The follow-up times are relatively short (6-43 months), which may ignore some late-onset recurrence. As an advantage, OK-432 sclerotherapy is applicable without general anesthesia, does not require hospitalization, and complications are rare

and mainly self-limiting. In our experience, however, half of the patients receiving primary sclerotherapy were later treated surgically because of insufficient response. This should be taken into account when selecting the primary treatment for plunging ranula.

Our patients receiving sclerotherapy were all except one initially misdiagnosed as lymphatic malformations, and therefore received primary sclerotherapy. The misdiagnosis of plunging ranula, a challenge also identified by others (1,3), may predispose the patient to unnecessary treatments. Therefore, thorough clinical and radiological evaluation, and in some cases fine needle aspiration and salivary amylase measurement are required to set the correct diagnosis, and to recommend an adequate treatment strategy.

Conclusions

We describe the largest plunging ranula patient series of European origin. The vast majority of patients are male, differing from previous reports from other ethnic backgrounds. This report adds to the knowledge of diagnosis and treatment of plunging ranula, and brings out the demographic differences between populations.

Acknowledgements

This work was supported by the Stiftelsen Dorothea Olivia, Karl Walter och Jarl Walter Perkléns mine.

Conflicts of Interest

None declared.

References

- [1] O'Connor R, McGurk M. The plunging ranula: diagnostic difficulties and a less invasive approach to treatment. *Int J Oral Maxillofac Surg* 2013;42:1469-74.
- [2] Chin SJ, Zeng IS, Morton RP. The epidemiology of plunging ranula in South Auckland. *Laryngoscope* 2016;126:2739-43.
- [3] Jain R, Morton RP, Ahmad Z. Diagnostic difficulties of plunging ranula: case series. *J Laryngol Otol* 2012;126:506-10.
- [4] Patel MR, Deal AM, Shockley WW. Oral and plunging ranulas: What is the most effective treatment? *Laryngoscope* 2009;119:1501-9.
- [5] Sigismund PE, Bozzato A, Schumann M, Koch M, Iro H, Zenk J. Management of ranula: 9 years' clinical experience in pediatric and adult patients. *J Oral Maxillofac Surg* 2013;71:538-44.
- [6] Huang SF, Liao CT, Chin SC, Chen IH. Transoral approach for plunging ranula--10-year experience. *Laryngoscope* 2010;120:53-7.
- [7] Mahadevan M, Vasani N. Management of pediatric plunging ranula. *Int J Pediatr Otorhinolaryngol* 2006;70:1049-54.
- [8] Yang Y, Hong K. Surgical results of the intraoral approach for plunging ranula. *Acta Otolaryngol* 2014;134:201-5.
- [9] Kim MG, Kim SG, Lee JH, Eun YG, Yeo SG. The therapeutic effect of OK-432 (picibanil) sclerotherapy for benign neck cysts. *Laryngoscope* 2008;118:2177-81.
- [10] Zhao YF, Jia Y, Chen XM, Zhang WF. Clinical review of 580 ranulas. *Oral Surg Oral Med Oral Pathol Oral Radiol Endod* 2004;98:281-7.
- [11] Zhi K, Wen Y, Zhou H. Management of the pediatric plunging ranula: results of 15 years' clinical experience. *Oral Surg Oral Med Oral Pathol Oral Radiol Endod* 2009;107:499-502.
- [12] Dindo D, Demartines N, Clavien PA. Classification of surgical complications: a new proposal with evaluation in a cohort of 6336 patients and results of a survey. *Ann Surg* 2004;240:205-13.
- [13] Castren E, Aronniemi J, Klockars T, Pekkola J, Lappalainen K, Vuola P, et al. Complications of sclerotherapy for 75 head and neck venous malformations. *Eur Arch Otorhinolaryngol* 2016;273:1027-36.
- [14] Aronniemi J, Castren E, Lappalainen K, Vuola P, Salminen P, Pitkaranta A, et al. Sclerotherapy complications of peripheral venous malformations. *Phlebology* 2016;31:712-22.
- [15] Morton RP, Ahmad Z, Jain P. Plunging ranula: Congenital or acquired? *Otolaryngol Head Neck Surg* 2010;142:104-7.
- [16] Kurabayashi T, Ida M, Yasumoto M, Ohbayashi N, Yoshino N, Tetsumura A, et al. MRI of ranulas. *Neuroradiology* 2000;42:917-22.
- [17] La'porte SJ, Juttla JK, Lingam RK. Imaging the floor of the mouth and the sublingual space. *Radiographics* 2011;31:1215-30.
- [18] Samant S, Morton RP, Ahmad Z. Surgery for plunging ranula: the lesson not yet learned? *Eur Arch Otorhinolaryngol* 2011;268:1513-18.
- [19] Rho MH, Kim DW, Kwon JS, Lee SW, Sung YS, Song YK, et al. OK-432 sclerotherapy of plunging ranula in 21 patients: it can be a substitute for surgery. *AJNR Am J Neuroradiol* 2006;27:1090-5.
- [20] Roh JL, Kim HS. Primary treatment of pediatric plunging ranula with nonsurgical sclerotherapy using OK-432 (Picibanil). *Int J Pediatr Otorhinolaryngol* 2008;72:1405-10.

Plunging ranula – patient characteristics, treatment, and comparison between different populations

Lyly Annina*, Castrén Eeva*, Aronniemi Johanna**, Klockars Tuomas*

*Department of Otorhinolaryngology – Head and Neck Surgery, Helsinki University Hospital and University of Helsinki, Helsinki, Finland

**Department of Radiology, HUS Medical Imaging Center, Helsinki University Hospital and University of Helsinki, Helsinki, Finland

Correspondence to: Annina Lyly, annina.lyly@helsinki.fi, tel. +358-50-5455051

Postal address: HYKS Korvaklinikka, Kasarmikatu 11-13, 00100 Helsinki

Table 1. Literature search.

	Reference	Population/country	Years of data collection	No of plunging ranula patients	M/F (ratio)	Mean age (range)	L/R/B ratio
1	O'Connor and McGurk, 2013 (1)	London, UK	2002-2011	8	nd	nd (17-37)	nd
2	Sigismund et al., 2013 (5)	Germany	2001-2010	10	8/2 (1:0.25)	26 (8-48)	1:1
3	Patel et al., 2009 (4)	North Carolina, USA	1990-2007	10	6/4 (1:0.7)	34.6 (17-65)	1:2.3
4	Huang et al., 2010 (6)	Taiwan	1999-2009	18	9/9 (1:1)	23.1 (6-48)	1:1
5	Mahavedan and Vasan, 2006 (7)	New Zealand (pediatric)	nd (prospective study)	21	14/7 (1:0.5)	10.8 (6-16)	1:0.4:0.2
6	Yang and Hong, 2014 (8)	Republic of Korea	nd (prospective study)	23	9/14 (1:1.56)	23.1 (9-38)	nd
7	Kim et al., 2008 (9)	Republic of Korea	2001-2007	42	nd	nd	nd
8	Zhao et al., 2004 (10)	China	1962-2002	118	68/50 (1:0.74)	appr. 20 (derived from the data)	1:1.38
9	Zhi et al., 2009 (11)	China (pediatric)	1990-2005	129	82/47 (1:0.57)	12 (3-16)	1:0.7:0.1
10	Chin et al., 2016 (2)	New Zealand (multi-ethnic population)	2001-2013	134	80/54 (1:0.68)	M: 24.1 (6-52) F: 23.2 (6-49)	1:0.83:0.1
11	This paper	Finland	2005-2016	41	36/5 (1:0.14)	29 (15-47)	1:0.86:0.1

Table 2. Age and gender distribution of confirmed plunging ranula patients at referral.

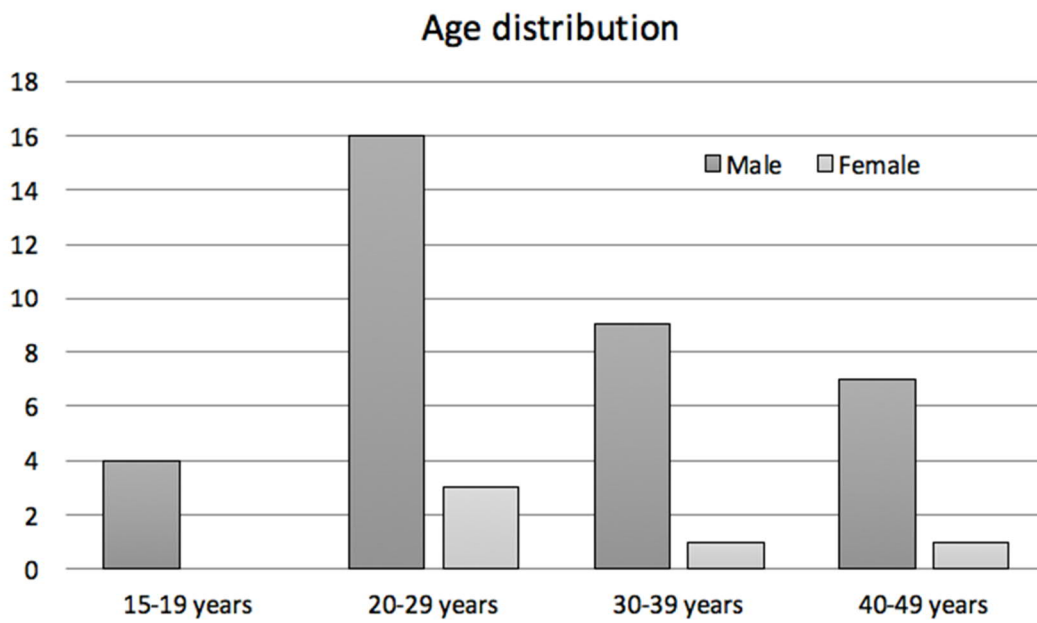


Table 3. Our patients. Treatment, surgical approach, initial radiologic diagnosis and number and severity of complications according to the Clavien-Dindo classification.

Treatment	Approach	Number of patients	Initial radiologic diagnosis (PR= plunging ranula, LM= lymphatic malformation)				Number of complications (Clavien-Dindo)	Passive follow-up after last intervention until 30.6.2016 Average (median;range)
			PR	LM	PR or LM	Other		
Primary surgery	Transcervical	3	1		2	1 (II)	21 (14; 1-75)	
	Transoral	15	7	4	2	2		4 (II)
Sclerotherapy only		6	0	4	1	1	1 (II)	50 (45; 26-105)
Surgery after sclerotherapy	Transcervical	4	0	3	1		1 (IIIb)	17 (19; 4-25)
	Transoral	4	1	2	1		2 (II)	
No intervention		9	3	4		2		
Total		41					8	