



UNIVERSITY OF HELSINKI

<https://helda.helsinki.fi>

## **Intracranial Vertebral Artery Aneurysms : Clinical Features and Outcome of 190 Patients**

**Lehto, Hanna; Niemela, Mika; Kivisaari, Riku; Laakso, Aki; Jahromi, Behnam Rezai ...**

**2015-08**

Elsevier Inc.

<http://hdl.handle.net/10138/223810>

Lehto, H, Niemela, M, Kivisaari, R, Laakso, A, Jahromi, B R, Hijazy, F, Andrade-Barazarte, H, Dashti, R & Hernesniemi, J 2015, 'Intracranial Vertebral Artery Aneurysms : Clinical Features and Outcome of 190 Patients', *World Neurosurgery*, vol. 84, no. 2, pp. 380-389. <https://doi.org/10.1016/j.wneu.2015.03.034>

Downloaded from Helda, University of Helsinki institutional repository. <https://helda.helsinki.fi>  
This is an electronic reprint of the original article.  
This reprint may differ from the original in pagination and typographic detail.  
Please cite the original version.



## Intracranial Vertebral Artery Aneurysms: Clinical Features and Outcome of 190 Patients

Hanna Lehto, Mika Niemelä, Riku Kivisaari, Aki Laakso, Behnam Rezai Jahromi, Ferzat Hijazy, Hugo Andrade-Barazarte, Reza Dashti, Juha Hernesniemi

■ **BACKGROUND:** Vertebral artery (VA) aneurysms comprise approximately one-third of posterior circulation aneurysms. They are morphologically variable, and located critically close to the cranial nerves and the brainstem. We aim to represent the characteristics of these aneurysms and their treatment, and to analyze the outcome.

■ **METHODS:** We reviewed retrospectively 9709 patients with intracranial aneurysms. Of these, we included 190 with aneurysms at the VA or VA–posterior inferior cerebellar artery junction. These patients were treated in the Department of Neurosurgery, Helsinki, Finland, between 1934 and 2011.

■ **RESULTS:** The 190 patients had 193 VA aneurysms, among which 131 (68%) were ruptured. The VA aneurysm caused a mass effect in 7 and ischemia in 2 patients. Compared to 4387 patients with a ruptured aneurysm in other locations, those with a VA aneurysm were older, their aneurysms were more often fusiform, and more often caused intraventricular hemorrhages. Among surgically treated aneurysms, clipping was the treatment in 91 (88%) saccular and 11 (50%) fusiform aneurysms. Treatment was endovascular in 13 (9%), and multimodal in 6 (4%) aneurysms. Within a year after aneurysm diagnosis, 53 (28%) patients died. Among the survivors, 104 (93%) returned to an independent or to their previous state of life; only 2 (2%) were unable to return home.

■ **CONCLUSIONS:** Microsurgery is a feasible treatment for VA aneurysms, although cranial nerve deficits are more common than in endovascular surgery. Despite the challenge of an often severe hemorrhage, of challenging

morphology, and risk for laryngeal palsy, most patients surviving the initial stage return to normalcy.

### INTRODUCTION

Aneurysms of the vertebral artery (VA) comprise approximately one-third of all posterior circulation aneurysms (49). Their characteristic morphologic and anatomic features make them unique among other intracranial aneurysms. Morphologically, a VA aneurysm can range from a small, saccular aneurysm in the VA–posterior inferior cerebellar artery (PICA) junction to a fragile, dissecting fusiform lesion, or to a giant aneurysm with brainstem compression. Anatomically, they are located deep in the posterior fossa in close proximity to the brainstem and cranial nerves.

With the exception of a 1996 report by Drake, Peerless, and Hernesniemi (12) of a series with 195 VA aneurysm patients, series on VA aneurysms are relatively small, mostly with <50 patients (1-6, 10-12, 14, 27, 32, 36, 41, 42, 49). After International Subarachnoid Aneurysm Trial (ISAT), most recent VA aneurysm studies focus on endovascular treatment (2, 5, 6, 10, 14, 27, 32, 36, 38).

In this retrospective study, we present 190 consecutive patients with 193 VA aneurysms treated mainly by microneurosurgical clipping. This series includes aneurysms originating from the VA itself or the VA–PICA junction. No distal PICA aneurysms reported earlier are included in the present report (28). Our aim is to describe the typical anatomic and morphologic features of VA aneurysms, to analyze the treatment outcome, and in particular to compare those that ruptured with aneurysms that ruptured at other locations.

#### Key words

- Cerebral aneurysm
- Microneurosurgery
- Vertebral artery

#### Abbreviations and Acronyms

- CT:** Computed tomography  
**CTA:** Computed tomography angiography  
**H&H:** Hunt and Hess  
**MRA:** Magnetic resonance angiography  
**PICA:** Posterior inferior cerebellar artery  
**SAH:** Subarachnoid hemorrhage  
**VA:** Vertebral artery

Department of Neurosurgery, Helsinki University Central Hospital, Helsinki, Finland

To whom correspondence should be addressed: Hanna Lehto, M.D.  
 [E-mail: hanna.lehto@hus.fi]

Citation: *World Neurosurg.* (2015) 84, 2:380-389.

<http://dx.doi.org/10.1016/j.wneu.2015.03.034>

Journal homepage: [www.WORLDNEUROSURGERY.org](http://www.WORLDNEUROSURGERY.org)

Available online: [www.sciencedirect.com](http://www.sciencedirect.com)

1878-8750/\$ - see front matter © 2015 Elsevier Inc. All rights reserved.

## METHODS

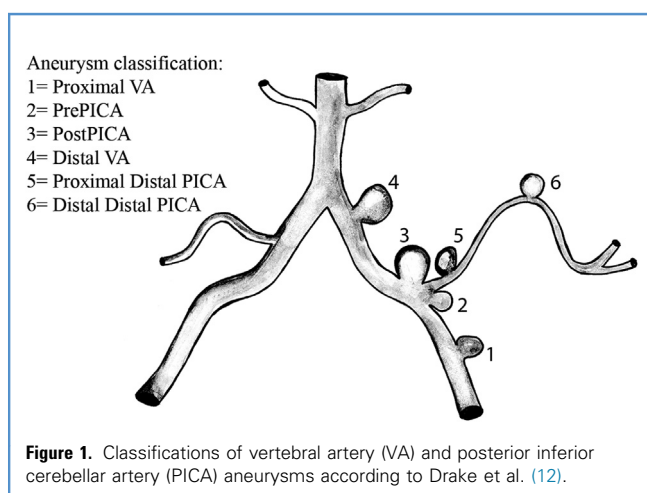
### Classification of VA Aneurysms

The 2 vertebral arteries are usually the first and largest branches originating from the subclavian arteries. Occasionally, they can arise from other sites, mainly from the aortic arch. VAs are divided into 4 segments, namely V1–V4, with V4 being the intradural segment (25). Distally VAs end by joining to form the basilar artery. To classify the VA aneurysms more exactly, we used the classification of Drake, Peerless, and Hernesniemi (12) subdividing the aneurysms into 4 groups according to their location as the PICA (Figure 1).

### Patient and Radiologic Data

We reviewed retrospectively 9709 consecutive patients with intracranial aneurysms treated between 1934 and 2011 in the Department of Neurosurgery at Helsinki University Central Hospital in Finland. We included among VA aneurysms also those aneurysms at the junction of VA and the PICA. We excluded aneurysms located more distally in the PICA, as well as aneurysms extending into the basilar artery. After excluding 3 patients referred from abroad to ensure a population-based series, a total of 190 patients harboring at least one VA aneurysm, were included. Aneurysms were identified either by a conventional or digitally subtracted angiogram, a computed tomography (CT) angiogram (CTA), or a magnetic resonance angiogram (MRA), or as an autopsy finding. Subarachnoid hemorrhage (SAH) was diagnosed by CT (n = 127) or by lumbar puncture (n = 27); 3 aneurysms found by angiography were revealed surgically to be ruptured.

We reviewed all medical records including operative reports and radiologic images. Patients' neurological condition was assessed by the Hunt and Hess (H&H) scale without its correction for general disease (18). We compared patients with a ruptured VA aneurysm to patients with a ruptured aneurysms elsewhere. Data for comparison came from a database comprising all patients with intracranial aneurysms treated in our department from 1980 to 2009. This part of the study was limited to the period after the 1980s, the era of microneurosurgery and CT scanning.



All images after 1989 were available for review. Where images were unavailable, we completed the analysis on the basis of radiologic and surgical reports; aneurysms not visible on an angiogram underwent assessment solely by a surgical or autopsy report.

### Follow-up Data

Patients were followed up until death or the end of 2011. Vital status on December 31, 2011, and any date of death came from the Population Register Center, comprising all Finnish residents. Statistics Finland ([http://www.stat.fi/index\\_en.html](http://www.stat.fi/index_en.html)) provided causes of death. We sent a written questionnaire to those alive asking about their present health status. For those unresponsive to the query, we gained the follow-up data from the department of neurosurgery. Of those by then deceased, we sought medical records from all public health services.

### Statistical Analysis

We performed data analysis by commercial statistical software (IBM SPSS Statistics, version 21.0.0 for Mac, Chicago, IL). For comparison between groups, we used the Mann-Whitney U-test for continuous and Pearson's  $\chi^2$  or Fisher's exact test for categorical variables. For those patients primarily diagnosed with a ruptured VA aneurysm and in whom the aneurysm was treated, we analyzed risk factors for death at 1 year. In the univariate analysis we included age, sex, Fisher grade, size and morphology of the aneurysm, possible rebleeding, shunt-dependent hydrocephalus, H&H grade in good (H&H 1–3) and poor (H&H 4 and 5) grade groups, and decade of treatment. Multivariate analysis was impossible due to small sample size. A probability value of < 0.05 was considered statistically significant.

## RESULTS

### Patients

The 190 patients had a total of 193 VA aneurysms. After 2000, the start of regular use of CTA and MRA in our department, the prevalence of VA aneurysms has been 2.0% of all and 3.5% of the ruptured aneurysms. Among all patients with intracranial aneurysms, a VA aneurysm was diagnosed in 2.8% of patients. Before the 1980s we found 16 patients; from 1980 to 1989 we found 31 patients; from 1990 to 1999 we found 35 patients; with the remaining 108 patients diagnosed after 2000. The first VA aneurysm was treated surgically in 1963, and the first endovascular treatment took place in 1997.

Of the 190 patients, 126 (67%) presented with a ruptured VA aneurysm and 24 with a ruptured aneurysm in another location (Table 1). Among patients surviving 1 year after their initial bleeding, 8 later had a second episode of SAH: 1 patient from a previously totally occluded VA-PICA aneurysm, 5 from previously undiagnosed VA aneurysms, and 2 from aneurysms at other locations. The time from the rupture of the first aneurysm to the second ranged from 2–50 years. One patient had SAH from a VA aneurysm diagnosed 3 years earlier. In addition, 2 patients were diagnosed with unruptured *denovo* aneurysms (VA and middle cerebral artery).

Beside rupture cases, a VA aneurysm was diagnosed due to mass effect in 7 patients and because of ischemia in 2 patients.

**Table 1.** Patient Characteristics (n = 190)

Age at Diagnosis (years)	Median (range)
Patients with SAH	51 (23–82)
Patients without SAH	55 (16–85)
Sex	No. (%)
Men	79 (42)
Women	111 (58)
Presentation	No. (%)
SAH from a VA aneurysm	126 (66)
Later SAH from another aneurysms	2
SAH from another aneurysm	24 (13)
Later SAH from a VA aneurysm	5
Mass lesion	7 (4)
Ischemia	2 (1)
Ruptured arteriovenous malformation	1 (1)
Asymptomatic	30 (15)
Hunt&Hess Grade	No. Total (VA)
1	31 (28)
2	48 (40)
3	26 (20)
4	20 (18)
5	32 (25)

SAH, subarachnoid hemorrhage; VA, vertebral artery.

Altogether there were 324 aneurysms, with the most commonly associated aneurysm being in the middle cerebral artery. Four-vessel angiography, CTA, or MRA was initially done for 148 patients (78%).

### Aneurysms

Of all VA aneurysms, post-PICA aneurysms were most common, accounting for 115 (60%) (Table 2). Small (<7 mm) ruptured aneurysms accounted for 64 (48%) and unruptured 32 (55%). Saccular aneurysms accounted for 150 (78%) and fusiform for 42 (22%) (Figure 2). Of the 150 saccular aneurysms, the VA-PICA junction accounted for 136 (91%) and within other locations in the VA for 9 (6%). The exact location was not available for 5 aneurysms (3%). Of all aneurysms, 109 (56%) were located on the left side.

Compared to patients with saccular aneurysms, those with fusiform aneurysms were more often male ( $P < 0.01$ ), and if the aneurysm had ruptured the patient had a higher H&H grade ( $P < 0.001$ ). There was no difference in 1-year mortality between the two groups ( $P = 0.70$ ).

**Table 2.** Characteristics of Vertebral Artery Aneurysms

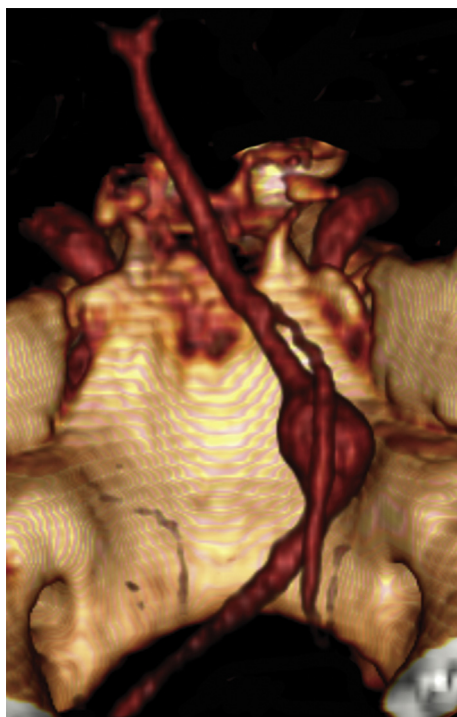
	Ruptured; Number (%)	Unruptured; Number (%)	Total; Number
Number of Aneurysms	131 (68)	62 (32)	193
Location			
Proximal	9 (7)	5 (8)	14
VA-PICA junction			
Pre-PICA	6 (5)	2 (3)	8
Post-PICA	79 (60)	35 (56)	114
Fusiform, including origin of PICA	6 (5)	4 (6)	10
Exact location not available	12 (9)	2 (3)	14
Distal	14 (11)	9 (15)	23
VA, no PICA	1 (1)	2 (3)	3
NA	4 (3)	3 (5)	7
Side			
Right	48 (37)	35 (56)	83
Left	83 (63)	27 (44)	110
Size			
<7 mm	64 (49)	32 (52)	96
7–14 mm	58 (44)	13 (21)	71
15–24 mm	5 (4)	9 (15)	14
>24 mm	—	4 (6)	4
NA	4 (3)	4 (6)	8
Morphology			
Saccular	105 (80)	45 (73)	150
Fusiform	25 (19)	17 (27)	42
NA	1 (1)	—	1

VA, vertebral artery; PICA, posterior inferior cerebellar artery; NA, not available.

### Patients with Ruptured VA Aneurysms

**Patients and Aneurysms.** A total of 131 patients (67%) (55 men and 76 women; median age, 51 years) presented with ruptured VA aneurysms. Among them, H&H grade 1–3 occurred in 88 patients (67%), and H&H grades 4 and 5 in 43 patients (33%); 66% of the poor grade patients underwent surgery after 2000. Among patients who had CT, Fisher grade was scaled as 4 in 77 (69%), 3 in 20 (18%), 2 in 10 (9%), and 1 in 5 patients (4%).

Comparing those patients with a ruptured VA aneurysm to patients with ruptured aneurysms at other locations, the former were slightly older (median 52 vs. 49 years;  $P = 0.03$ ) (Table 3). Ruptured VA aneurysms were more often fusiform than were aneurysms ruptured at other locations, and the VA aneurysms were located more often on the left side. Patients with ruptured VA aneurysms were of higher Fisher grade due to their high frequency of intraventricular hemorrhage, although no VA aneurysm had



**Figure 2.** An example of a fusiform aneurysm.

caused intracerebellar bleeding. Yet a statistically significant difference between the H&H grades was never apparent.

**Treatment.** A total of 84 aneurysms (64%) were clipped (**Figures 3 and 4**), and due to incomplete occlusion, 1 aneurysm was re-clipped during the same hospitalization. One clipped aneurysm re-ruptured and was embolized twice afterward.

Six aneurysms were treated by an endovascular technique, of which 3 needed surgical treatment thereafter: 1 due to failed embolization, 1 due to incomplete occlusion, and 1 due to coil extravasation, bleeding, and incomplete occlusion.

Of the 22 patients treated conservatively, 11 were of poor grade, 6 were considered inoperable mainly in the earlier part of the series. In 2 patients, the aneurysm was found at autopsy after a negative angiography, and in 2 cases an anterior circulation aneurysm was incorrectly considered ruptured, and the actual ruptured VA aneurysm emerged only at autopsy. One patient back in the 1960s refused surgery.

#### Other Symptomatic VA Aneurysms

Seven patients presented with a mass effect from the aneurysm (**Figure 5**). The size of the aneurysm ranged from 20–50 mm. In addition, 1 residive aneurysm operated on was 27 mm. Four of the aneurysms were saccular and 3, fusiform. One aneurysm was totally thrombosed, and was originally suspected to be a recurrent hemangioblastoma. All the other aneurysms were partially thrombosed. Six patients were treated surgically, 1 requiring a bypass. Three patients returned to work and 1 to an

independent life. Two of the patients died: a 81-year-old with her aneurysm invading the brainstem and a 16-year-old girl from an aneurysm rupture 4 days after VA occlusion in 1965. The only conservatively treated patient is still alive 19 years after diagnosis.

Two patients presented with ischemia. Both aneurysms were fusiform/dissecting: at diagnosis 1 aneurysm was thrombosed together with the VA, the other thrombosed during follow-up.

#### Unruptured VA Aneurysms with Bleeding from Another Aneurysm or an Arteriovenous Malformation

Of the 24 patients with SAH from an aneurysm in another location, in 12 the VA aneurysm was treated later.

One patient with a ruptured arteriovenous malformation had her post-PICA and distal PICA aneurysms clipped at the same session with extirpation of the malformation.

#### Incidental Aneurysms

In 29 patients the aneurysm was an incidental finding. Of these, 15 were treated by microsurgery, 4 by endovascular techniques, and 1 was treated with a combination of both modalities. Nine patients were initially treated conservatively, and among them, 1 patient later underwent clipping after rupture of the aneurysm.

#### Outcome

**Angiographic Outcome.** Postoperative angiography was performed in 124 patients (86%). Among the saccular aneurysms, total occlusion was achieved in 76 (88%), and of those clipped, 68 (91%). Among fusiform aneurysms, total occlusion was achieved in 14 (44%) of all treated patients and in 8 (73%) of the clipped aneurysms. After surgery, 5 aneurysms re-ruptured: 2 after clipping (1 dissecting aneurysm and 1 primarily totally occluded saccular aneurysm 3 years later), 2 after wrapping, and 1 fusiform (dissecting) aneurysm after proximal occlusion. In addition 1 unruptured giant aneurysm ruptured after proximal occlusion.

Among aneurysms treated endovascularly, 3 were occluded totally. Due to failed embolization, 5 patients were referred to surgery. One aneurysm rebled after stenting. Altogether 9 aneurysms treated primarily by endovascular surgery were fusiform.

**Clinical Outcome.** The mean follow-up time of the patients was 6.8 years (median, 3.1 years; range, 0 days to 50 years). The vital status at the end of 2011 was available for each except for 2 foreign patients. Of the 109 patients still alive, 78 (72%) replied to the query.

Of the 186 patients treated before 2011, 53 (28%) died within 1 year after their first aneurysm diagnosis. The most common cause was severe SAH in 30 patients. No patient with an incidental aneurysm died from any treatment-related cause. Treatment unintentionally for of the unruptured aneurysm led to rebleeding and death in 3 patients. After treatment of their aneurysms, 4 patients died from rerupture of a dissecting aneurysm within 10 days after treatment. Brain infarction due to spasm led to the death of 2 patients and the unexpected PICA occlusion of 1 patient. Cause of death was pneumonia in 6 and cardiac infarction in 2 patients. One patient died from SAH after treatment of an unruptured giant VA aneurysm, which caused a mass effect with a Cruchfield clamp in the 1960s. This aneurysm was diagnosed due to its mass effect but was unruptured preoperatively. Two patients died from trauma: 1 after a car crash while being transported to

**Table 3.** Patients with Ruptured VA Aneurysms Compared with Patients with Other Ruptured Aneurysms

	VA	Other	P Value
Number of aneurysms	109	4387	
Age at diagnosis (years)	Median (range)	Median (range)	0.03
All	52 (28–79)	49 (1–92)	
Men	52 (29–78)	47 (1–88)	
Women	52 (28–79)	52 (12–92)	
Sex	No. (%)	No. (%)	0.43
Men	44 (40)	1945 (44)	
Women	65 (60)	2442 (56)	
Number of aneurysms			
Single	77 (71)	3087 (70)	1.00
Multiple	32 (29)	1297 (30)	
Morphology of the aneurysm			
Saccular	86 (79)	4235 (97)	< 0.001
Fusiform	23 (21)	128 (3)	
NA	—	24 (1)	
Size of the aneurysm			
<7 mm	53 (48)	1347 (31)	0.52
7–14 mm	48 (44)	1861 (42)	
15–24 mm	4 (4)	369 (8)	
>24 mm	—	57 (1)	
NA	4 (4)	753 (17)	
Side of the aneurysm*			
Right	42 (39)	2196 (53)	< 0.01
Left	67 (61)	1925 (46)	
NA	—	64 (2)	
Fisher grade			
No scan	7 (6)	329 (8)	< 0.001
1	5 (5)	239 (5)	
2	9 (8)	396 (9)	
3	20 (18)	1259 (29)	
4	—	1737 (40)	
NA	68 (62)	427 (10)	
IVH			
No	38 (34)	2490 (57)	< 0.001
Yes	69 (63)	1089 (25)	
NA	—	808 (18)	

Continues

**Table 3.** Continued

	VA	Other	P Value
ICH			
No	102 (93)	2406 (55)	< 0.001
Yes	—	1225 (28)	
NA	7 (6)	756 (17)	
Hunt&Hess grade			
1	20 (18)	813 (19)	0.33
2	35 (32)	1220 (28)	
3	16 (15)	891 (20)	
4	17 (16)	769 (18)	
5	21 (19)	574 (13)	
NA	—	120 (3)	
Rebleeding before treatment			
No	78 (72)	3364 (77)	0.10
Yes	30 (28)	946 (22)	
NA	1 (1)	77 (2)	

VA, vertebral artery; NA, not available; IVH, intraventricular hemorrhage; ICH, intracerebellar hemorrhage.

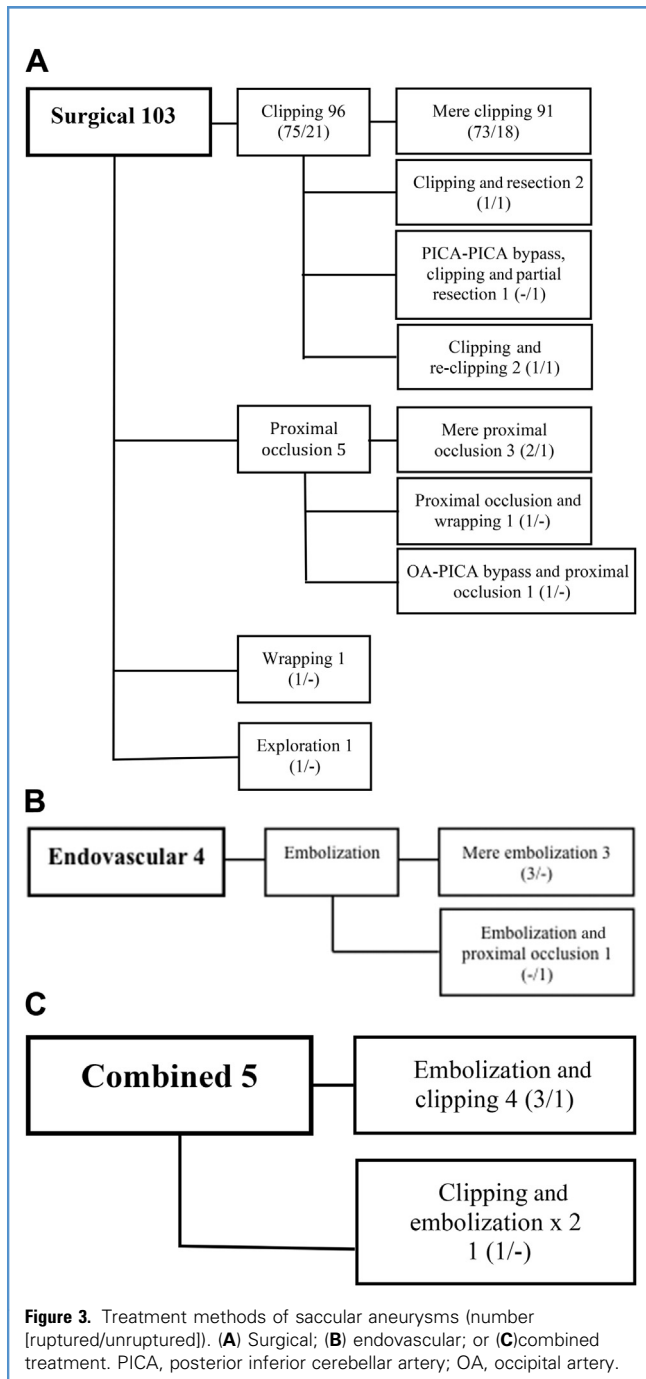
\*Midline aneurysms excluded.

rehabilitation, the other had severe balance disturbances after SAH and died from cerebral contusions after a fall. In addition, within 1 year of diagnosis, 3 patients died of cancer.

Later than the first year of the aneurysm diagnosis, 7 patients died from an aneurysm-related cause: 2 died from the rupture of a previously undiagnosed VA and one from an anterior communicating artery aneurysm rupture. One patient died from the rupture of a VA aneurysm diagnosed incidentally 3 years earlier. One 85-year-old patient died after regrowth of a previously clipped aneurysm; the aneurysm caused hemiplegia, and after the re-clipping, she remained bedridden and died a month later. One patient died from rebleeding 13 years after the wrapping of a VA aneurysm, and the patient who refused surgery, died from rebleeding 8 years later.

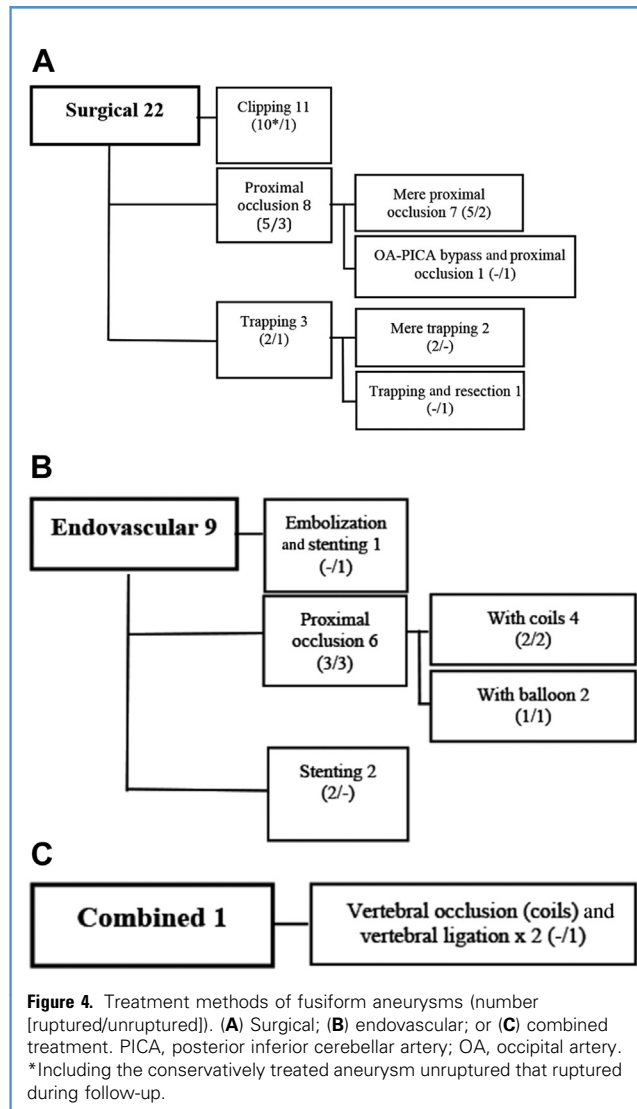
Among the 112 patients with an actively treated VA aneurysm surviving beyond 1 year, those recovering their former or independent state of living numbered 104 (93%). Seven patients, all with ruptured VA aneurysms, remained dependent on help: 1 of them died 13 months after the bleeding, 2 remained hospitalized, 4 lived at home with support. One foreign patient was transferred to her home country in poor condition and was lost to follow-up.

Among patients originally operated on for a ruptured VA aneurysm, the risk factors for death at 1 year in the univariate analysis were old age ( $P = 0.02$ ), male gender ( $P < 0.001$ ), and high H&H grade ( $P < 0.01$ ). No difference in outcome was seen between those with ruptured fusiform or saccular aneurysms ( $P = 0.09$ ).



The aneurysm morphology caused no difference in outcome either for those with ruptured ( $P = 0.08$ ) or with incidental aneurysms ( $P = 0.09$ ).

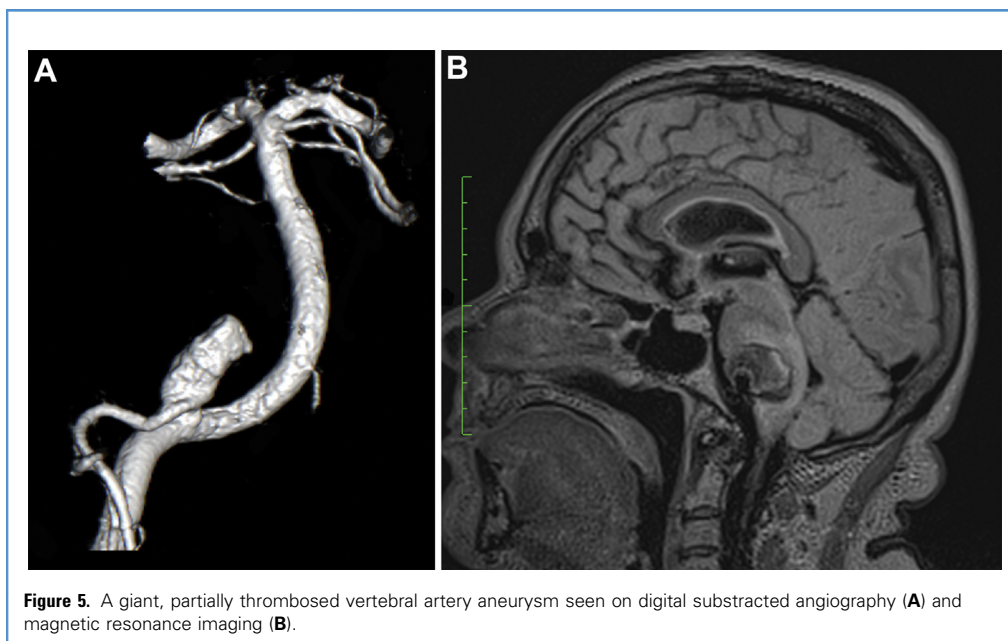
Among patients with an actively treated VA aneurysm, cranial nerve deficit(s) at admission occurred in 21 (15%), and after treatment of the aneurysm, in 72 (50%) (Table 4). The most common deficit was laryngeal palsy in 59 (41%), with 28 needing a tracheostomy. Among patients treated only by



endovascular means, 1 had laryngeal palsy already diagnosed before treatment. The paresis recovered fully in 28 patients and partially in 20, among whom 5 had only slightly hoarse voices. Two patients needed a permanent tracheostomy and a percutaneous endoscopic gastrostomy. Both of these patients were preoperatively unconscious and had small, saccular PICA aneurysms. In addition, 9 patients with a tracheostomy died within a month after the operation. The second most common cranial nerve deficit was diplopia, mainly from bilateral abducens nerve palsy caused by brainstem compression. Problems related to the trigeminal nerve showed no recovery.

## DISCUSSION

We studied 190 patients with 193 VA aneurysms. Among all patients with aneurysms, 2.8% had a VA aneurysm. Patients with ruptured VA aneurysms were older than those with ruptured aneurysms at other locations. More VA aneurysms were fusiform,



**Figure 5.** A giant, partially thrombosed vertebral artery aneurysm seen on digital subtracted angiography (A) and magnetic resonance imaging (B).

and when ruptured, more often caused intraventricular hemorrhage than did other aneurysms. Among fusiform (dissecting) aneurysms, the only method definitively preventing rebleeding was trapping. Despite often the higher Fisher and H&H grades, the aneurysm's challenging morphology, and the risk for a lower cranial nerve deficit, most patients surviving the initial stage made a good recovery.

#### Characteristics of VA Aneurysms

The most characteristic feature of VA aneurysms is their high degree of morphologic and anatomic variability. Their size can be highly variable, with a wide range of presenting symptoms. VA aneurysms are reported to be located at the origin of the PICA (3, 12), and aneurysms in the VA–PICA junction comprised 63% of our cases. The origin and course of a PICA can be highly variable, with the aneurysm located even extracranially (8, 20, 31). The percentage of nonsaccular aneurysms was high—22%; in other series, 13%–41% (3, 12, 49).

#### Treatment

VA aneurysms are challenging, with a variety of techniques involved in their treatment. Microneurosurgical techniques reported after 2000 include clipping (1, 11, 13, 23, 30, 35, 43), wrapping (43), clipping with wrapping (13), and trapping or proximal occlusion with (19, 43) or without bypass (11, 13, 30, 43). The endovascular methods include selective coiling (13, 40), coil occlusion of the aneurysm with PICA or VA of both (internal trapping) (2, 14, 19, 26, 40, 45), stent-assisted coiling (2, 9, 33, 40, 45), stenting or use of a flow diverter (7, 22, 33, 50), and proximal occlusion with coils or balloon (13, 40). Multimodality treatment as an original plan mostly included a bypass procedure combined with endovascular vessel occlusion (14, 19). Our series featured a clear surgical dominance, even in recent years. Altogether 135 aneurysms were treated surgically compared with 13 endovascular treatments. An additional 6 patients were treated eventually with both methods. During the years, VA aneurysms have been treated with more than 20 different ways.

**Table 4.** Cranial Nerve Deficits Among Actively Treated Patients (n = 144)

	Preoperative, Number (%)	Postoperative, Number (%)	Total Recovery	Partial Recovery	No Recovery
Laryngeal palsy	9 (6)	59 (41)	28	20	2
Diplopia	12 (8)	15 (10)	10	—	1
Facial nerve deficit	3 (2)	6 (4)	5	—	1
Trigeminal deficit	1 (1)	3 (2)	—	—	3
Hearing loss	—	1 (1)	—	—	1
Accessory deficit	1 (1)	7 (5)	5	1	1
NA	30 (21)	12 (8)	—	—	—

NA, not available.

This reflects the challenge of the treating lesion, as well as a passion to find the best possible treatment.

**Saccular Aneurysms.** Microsurgical treatment of a saccular VA aneurysm is challenged because of their deep location between the cranial nerves and by the preservation of the PICA originating from the base of the aneurysm. Most surgeons use a far-lateral approach, as described especially by Heros (15), or use its transcondylar, supracondylar, or paracondylar extensions. Another common approach is the lateral suboccipital approach, used also by Drake et al. (12). Of the recent patients in our series, most underwent surgery using the lateral suboccipital approach, and only aneurysms lying within a centimeter from the foramen magnum required its opening. As in earlier series, direct clipping was possible in most of these aneurysms, and nearly all were treated by proximal occlusion, which occurred in the 1970s. Surgery allows clot removal, debulking of the aneurysm, and any required revascularization. One risk of surgery is laryngeal palsy. It occurred in 41% of all cases, but only 2 patients needed a permanent tracheostomy. In endovascular surgery, no cranial nerves are manipulated. Instead, the challenge remains to preserve the PICA despite a wide-necked aneurysm and this is achieved by total occlusion. In a recent study (6) on endovascular treatment of PICA aneurysms, complete occlusion of the aneurysm was achieved in 63% of patients. This figure includes dissecting and distal PICA aneurysms. In that same study, the recurrence rate among selectively coiled aneurysms at the VA–PICA junction or the anteromedullary segment of the PICA was 21%. The rehemorrhage rate in the study was low, 1.4%, but the mean follow-up time was only 17 months. To assist in the embolization, several recent reports describe stent or balloon-assisted coiling in wide-neck PICA aneurysms (6, 9, 10).

**Fusiform Aneurysm.** Fusiform aneurysms are frequently dissecting. Their treatment remains a challenge for micro-neurosurgical and endovascular techniques. Dissecting aneurysms have a high rebleeding rate and a high associated mortality and morbidity. Most rebleedings occur within the first 24 hours (26, 37, 48). Although the aim is to isolate the fusiform aneurysm from the circulation, preservation of flow in the parent vessel is important. Mere proximal occlusion of the parent artery may be insufficient, as seen in 1 of our patients who died from rebleeding, and mentioned earlier (21, 24). We also learned of 2 other fatal rebleedings from fusiform aneurysms: 1 dissecting aneurysm was wrapped in the early part of the series, and the other was treated with clip reconstruction. In addition, 1 patient died due to rebleeding after endovascular treatment with a stent, leaving trapping as the only safe method to prevent rebleeding. In their series on vertebrobasilar dissecting aneurysms, Kim et al. (22) found, after endovascular treatment, an 8% rebleeding rate. Recurrence after successful stent-supported coil embolization and after internal coil occlusion also occurs (34, 44). At present, the most commonly reported treatment of dissecting VA aneurysms is trapping, mostly by endovascular means combined, if needed, with bypass (19, 43).

## Outcome

**Cranial Nerve Deficits.** In their series on patients with VA aneurysms, Lv et al. (32) saw a lower cranial nerve deficit of 17%. The incidence in our series was somewhat lower (7%). We were, however, unable to examine 20% of the patients properly due to their being unconscious. After surgery, up to 48% of patients have been reported with a lower cranial nerve deficit (1, 11, 17, 42). This rate in the present series was 41%. Despite the high occurrence rate, postoperative laryngeal palsy prognosis is favorable. Only 2 of our patients needed a permanent tracheostomy.

In addition to lower cranial nerve deficits, we found a diverse range of other cranial nerve deficits resulting mainly from brain-stem compression. These are known to be either part of the lateral medullary syndrome or a separate finding (4, 19, 42, 49). In our series, the patients with gaze palsies recovered well, although none of the symptoms related to the trigeminal nerve improved. Due to the rarity of these deficits, no comparison with the literature was possible.

**Recurrent SAH.** Cumulative incidence of recurrent SAH within the first 10 years has been 3.2% (47). We had a high rate among actively treated patients with ruptured VA aneurysms: 9 (9%) suffered rebleeding. This high rate of recurrent bleedings can be in part explained by suboptimal treatment: 2 aneurysms were wrapped, 1 treated with proximal occlusion, and 1 fusiform (dissecting) aneurysm, including the origin of the PICA, was treated with incomplete clipping. In addition, 5 patients with an earlier rupture of an anterior circulation aneurysm suffered later from a rupture of a VA aneurysm. Unfortunately, no 4-vessel angiogram was performed for all patients; for 3 patients we do not know whether any possibility existed to detect the aneurysm when unruptured. Ruptures from the other side occurred 6–51 years after the first bleeding, emphasizing the need for long follow-up when studying recurrent SAH incidence.

In general, the overall outcome of treating distal PICA aneurysms is rather favorable, with 80%–85% of patients recovering to Glasgow outcome scale 4–5 (16, 29, 30, 39, 46). In our series, the percentage was somewhat lower (69%). Our figure, however, included many patients who died due to severe bleeding, and also included conservatively treated patients. Among those who survived 1 year, only 2 patients did not recover to an independent state of life.

## CONCLUSIONS

Of our patients with intracranial aneurysms, 2.8% had a VA aneurysm. In patients with a ruptured VA aneurysm, the risk factors for death at 1 year in univariate analysis were old age, male sex, and high H&H grade. The anatomic and morphologic features of these aneurysms make their treatment challenging. Despite many cases of severe bleeding and the risk of laryngeal palsy caused by surgery, among patients surviving 1 year after diagnosis, the outcome may be favorable, with almost all returning to independent life or to their previous state of life.

## ACKNOWLEDGMENTS

We thank Carolyn Brimley Norris for language advice.

## REFERENCES

- Al-khayat H, Al-Khayat H, Beshay J, Manner D, White J: Vertebral artery-posterior inferior cerebellar artery aneurysms: clinical and lower cranial nerve outcomes in 52 patients. *Neurosurgery* 56:2-10, 2005.
- Albuquerque FC, Fiorella DJ, Han PP, Deshmukh VR, Kim LJ, McDougall CG: Endovascular management of intracranial vertebral artery dissecting aneurysms. *Neurosurg Focus* 18:E3, 2005.
- Andoh T, Shirakami S, Nakashima T, Nishimura Y, Sakai N, Yamada H, Ohkuma A, Tanabe Y, Funakoshi T: Clinical analysis of a series of vertebral artery aneurysm cases. *Neurosurgery* 31:987-993, 1992.
- Bertalanffy H, Sure U, Petermeyer M, Becker R, Gilsbach JM: Management of aneurysms of the vertebral artery-posterior inferior cerebellar artery complex. *Neurol Med Chir (Tokyo)* 38 (Suppl):93-103, 1998.
- Bradac GB, Bergui M: Endovascular treatment of the posterior inferior cerebellar artery aneurysms. *Neuroradiology* 46:1006-1011, 2004.
- Chalouhi N, Jabbour P, Starke RM, Tjoumakaris SI, Conzalez LF, Witte S, Rosenwasser RH, Dumont AS: Endovascular treatment of proximal and distal posterior inferior cerebellar artery aneurysms. *J Neurosurg* 118:991-999, 2013.
- Chalouhi N, Tjoumakaris S, Dumont AS, Gonzalez LF, Randazzo C, Starke RM, Rosenwasser RH, Jabbour P: Treatment of posterior circulation aneurysms with the pipeline embolization device. *Neurosurgery* 72:883-889, 2013.
- Chen CJ, Chen ST: Extracranial distal aneurysm of posterior inferior cerebellar artery. *Neuroradiology* 39:344-347, 1997.
- Cho YD, Kang H-S, Lee WJ, Kim KM, Kim JE, Han MH: Stent-assisted coil embolization of wide-necked posterior inferior cerebellar artery aneurysms. *Neuroradiology* 55:877-882, 2013.
- Crowley RW, Albuquerque FC, Ducruet AF, Williamson RW, McDougall CG: Technical considerations in the endovascular management of aneurysms of the posterior inferior cerebellar artery. *Neurosurgery* 71:ONS204-ONS218, 2012.
- D'Ambrosio AL, Kreiter KT, Bush CA, Sciacca RR, Mayer SA, Solomon RA, Conolly ES: Far lateral suboccipital approach for the treatment of proximal posterior inferior cerebellar artery aneurysms: surgical results and long-term outcome. *Neurosurgery* 55:39-50, 2004.
- Drake CG, Peerless SJ, Hernesniemi JA: *Surgery of Vertebralbasilar Aneurysms*: London, Ontario Experience on 1767 Patients. Wien, New York: Springer; 1996.
- Groden C, Regelsberger J, Neumaier-Probst E, Grzyska U, Herrmann HD, Zeumer H: Operative or endovascular treatment of ruptured intracranial vertebral artery aneurysms? *Neuroradiology* 42:685-691, 2000.
- Hamada J-I, Kai Y, Morioka M, Yano S, Todaka T, Ushio Y: Multimodal treatment of ruptured dissecting aneurysms of the vertebral artery during the acute stage. *J Neurosurg* 99:960-966, 2003.
- Heros RC: Lateral suboccipital approach for vertebral and vertebralbasilar artery lesions. *J Neurosurg* 64:559-562, 1986.
- Horiuchi T, Tanaka Y, Hongo K, Nitta J, Kusano Y, Kobayashi S: Characteristics of distal posterior inferior cerebellar artery aneurysms. *Neurosurgery* 53:589-595, 2003.
- Horowitz M, Kopitnik T, Landreneau F, Krummerman J, Batjer HH, Thomas G, Samson D: Posterior inferior cerebellar artery aneurysms: surgical results for 38 patients. *Neurosurgery* 43:1026-1032, 1998.
- Hunt WE, Hess RM: Surgical risk as related to time of intervention in the repair of intracranial aneurysms. *J Neurosurg* 28:14-20, 1968.
- Iihara K, Sakai N, Murao K, Sakai H, Higashi T, Kogure S, Takahashi JC, Nagata I: Dissecting aneurysms of the vertebral artery: a management strategy. *J Neurosurg* 97:259-267, 2002.
- Katsuno M, Tanikawa R, Ota N, Izumi N, Hashimoto M: Subarachnoid hemorrhage caused by ruptured posterior inferior cerebellar artery aneurysm arising from the extracranial portion of an anomalous vertebral artery. *Neurol Med Chir (Tokyo)* 52:499-501, 2012.
- Kawamata T, Tanikawa T, Takeshita M, Onda H, Takakura K, Toyoda C: Rebleeding of intracranial dissecting aneurysm in the vertebral artery following proximal clipping. *Neurol Res* 16:141-144, 1994.
- Kim BM, Shin YS, Kim S-H, Suh SH, Ihn YK, Kim DI, Kim DJ, Park SI: Incidence and risk factors of recurrence after endovascular treatment of intracranial vertebralbasilar dissecting aneurysms. *Stroke* 42:2425-2430, 2011.
- Kim MJ, Chung J, Kim SL, Roh HG, Kwon BJ, Kim BS, Kim TH, Kim BM, Shin YS: Stenting from the vertebral artery to the posterior inferior cerebellar artery. *Am J Neuroradiol* 33:348-352, 2012.
- Kitanaka C, Morimoto T, Sasaki T, Takakura K: Rebleeding from vertebral artery dissection after proximal clipping. Case report. *J Neurosurg* 77:466-468, 1992.
- Krauenbühl H, Yasargil MG: *Die Vasculären Erkrankungen im Gebiet Der Arteria Vertebralis Und Arteria Basilaris (Vascular Diseases of the vertebral and basilar arteries)*. Verlag: Georg Thieme; 1957.
- Kurata A, Ohmomo T, Miyasaka Y, Fujii K, Kan S, Kitahara T: Coil embolization for the treatment of ruptured dissecting vertebral artery aneurysms. *AJNR* Am J Neuroradiol 22:11-18, 2001.
- Lee J-M, Kim T-S, Joo S-P, Yoon W, Choi H-Y: Endovascular treatment of ruptured dissecting vertebral artery aneurysms—long-term follow-up results, benefits of early embolization, and predictors of outcome. *Acta Neurochir* 152:1455-1465, 2010.
- Lehto H, Harati A, Niemelä M, Dashti R, Laakso A, Elsharkawy A, Satopää J, Billon-Grand R, Canato B, Kivisaari R, Hernesniemi J: Distal posterior inferior cerebellar artery aneurysms: clinical features and outcome of 80 patients. *World Neurosurg* 82:702-713, 2014.
- Lewis SB, Chang DJ, Peace DA, Lafrentz PJ, Day AL: Distal posterior inferior cerebellar artery aneurysms: clinical features and management. *J Neurosurg* 97:756-766, 2002.
- Liew D, Ng P-Y, Ng I: Surgical management of ruptured and unruptured symptomatic posterior inferior cerebellar artery aneurysms. *Br J Neurosurg* 18:608-612, 2004.
- Lin CF, Hsu SP, Chen MT, Chen HH, Shih YH, Lee LS, Chen MH: Posterior inferior cerebellar artery with extracranial origin harboring an extracranial aneurysm. *Surg Neurol* 68 (Suppl 1):S64-S67, 2007.
- Lv X, Jiang C, Li Y, Wu Z: Clinical outcomes of lower cranial nerve palsies caused by vertebral artery-posterior inferior cerebellar artery aneurysms after endovascular embolization. *Neurol Res* 32:796-800, 2010.
- Lv X, Jiang C, Li Y, Wu Z: Clinical outcomes of ruptured and unruptured vertebral artery-posterior inferior cerebellar artery complex dissecting aneurysms after endovascular embolization. *Am J Neuroradiol* 31:1232-1235, 2010.
- MacKay CI, Han PP, Albuquerque FC, McDougall CG: Recurrence of a vertebral artery dissecting pseudoaneurysm after successful stent-supported coil embolization: case report. *Neurosurgery* 53:754-759, 2003.
- Matsushima T, Matsukado K, Natori Y, Inamura T, Hitotsumatsu T, Fukui M: Surgery on a saccular vertebral artery-posterior inferior cerebellar artery aneurysm via the transcondylar fossa (supracondylar transjugular tubercle) approach or the transcondylar approach: surgical results and indications for using two different lateral skull base approaches. *J Neurosurg* 95:268-274, 2001.
- Mericle RA, Reig AS, Burry MV, Eskioğlu E, Firmont CS, Santra S: Endovascular surgery for proximal posterior inferior cerebellar artery aneurysms: an analysis of Glasgow Outcome Score by Hunt-Hess grades. *Neurosurgery* 58:619-625, 2006.
- Mizutani T, Aruga T, Kirino T, Miki Y, Saito I, Tsuchida T: Recurrent subarachnoid hemorrhage from untreated ruptured vertebralbasilar dissecting aneurysms. *Neurosurgery* 36:905-911, 1995.
- Molyneux A, Kerr R, Stratton I, Sandercock P, Clarke M, Shrimpton J, Holman R: International Subarachnoid Aneurysm Trial (ISAT) Collaborative Group, International Subarachnoid Aneurysm Trial (ISAT) of neurosurgical clipping versus endovascular coiling in 2143 patients with ruptured intracranial aneurysms: a randomized trial. *Lancet* 26:1267-1274, 2002.
- Orakcioglu B, Schuknecht B, Otani N, Khan N, Imhof HG, Yonekawa Y: Distal posterior inferior

- cerebellar artery aneurysms: clinical characteristics and surgical management. *Acta Neurochir* 147:1131-1139, 2005.
40. Peluso JP, van Rooij WJ, Sluzewski M, Beute GN, Majoie CB: Posterior inferior cerebellar artery aneurysms: incidence, clinical presentation, and outcome of endovascular treatment. *AJNR Am J Neuroradiol* 29:86-90, 2008.
  41. Sadato A, Maeda S, Hayakawa M, Kato Y, Sano H, Hirose Y, Miyamoto S, Hashimoto N: Endovascular treatment of vertebral artery dissection using stents and coils: its pitfall and technical considerations. *Minim Invasive Neurosurg* 53:243-249, 2010.
  42. Salcman M, Rigamonti D, Numaguchi Y, Sadato N: Aneurysms of the posterior inferior cerebellar artery-vertebral artery complex: variations on a theme. *Neurosurgery* 27:12-20, 1990.
  43. Sanaï N, Tarapore P, Lee AC, Lawton MT: The current role of microsurgery for posterior circulation aneurysms: a selective approach in the endovascular era. *Neurosurgery* 62:1236-1249, 2008.
  44. Sawada M, Kaku Y, Yoshimura S, Kawaguchi M, Matsuhisa T, Hirata T, Iwama T: Antegrade recanalization of a completely embolized vertebral artery after endovascular treatment of a ruptured intracranial dissecting aneurysm. Report of two cases. *J Neurosurg* 102:161-166, 2005.
  45. Suma T, Shibuya T, Kutsuna N, Takada Y, Matsuzaki T, Nakamura S, Hirayama T, Katayama Y: Endovascular treatment for ruptured vertebral artery dissecting aneurysms at the acute stage. *Acta Neurochir Suppl* 118: 273-276, 2013.
  46. Tokimura H, Yamahata H, Kamezawa T, Tajitsu K, Nagayama T, Sugata S, Takiguchi K, Tanikuchi A, Niino M, Hihara K, Takasaki K, Oyoshi T, Arita K: Clinical presentation and treatment of distal posterior inferior cerebellar artery aneurysms. *Neurosurg Rev* 34:57-67, 2011.
  47. Wermer MJH, Greebe P, Algra A, Rinkel GJE: Incidence of recurrent subarachnoid hemorrhage after clipping for ruptured intracranial aneurysms. *Stroke* 36:2394-2399, 2005.
  48. Yamada M, Kitahara T, Kurata A, Fujii K, Miyasaka Y: Intracranial vertebral artery dissection with subarachnoid hemorrhage: clinical characteristics and outcomes in conservatively treated patients. *J Neurosurg* 101:25-30, 2004.
  49. Yamaura A: Diagnosis and treatment of vertebral aneurysms. *J Neurosurg* 69:345-349, 1988.
  50. Yoon WK, Kim YW, Kim S-R, Park IS, Kim SD, Jo KW, Baik MW: Angiographic and clinical outcomes of stent-alone treatment for spontaneous vertebrobasilar dissecting aneurysm. *Acta Neurochir* 152:1477-1486, 2010.

*Conflict of interest statement: This study was funded by the Maire Taponen Foundation and the Emil Aaltonen Foundation.*

*Received 23 November 2014; accepted 18 March 2015*

*Citation: World Neurosurg. (2015) 84, 2:380-389.  
http://dx.doi.org/10.1016/j.wneu.2015.03.034*

*Journal homepage: www.WORLDNEUROSURGERY.org*

*Available online: www.sciencedirect.com*

*1878-8750/\$ - see front matter © 2015 Elsevier Inc.  
All rights reserved.*



## ELSEVIER Subscription Customer Service

3251 Riverport Lane, Maryland Heights, MO 63043

**Tel:** (314) 447-8871 (International)

**Tel:** (800) 654-2452 (US)

**Fax:** (314) 447-8029 (US and International)

**Email:** journalcustomerservice-usa@elsevier.com