

Department of Plastic Surgery
University of Helsinki
Finland

SURGICAL TREATMENT OF SOFT TISSUE
SARCOMAS

Pentscho Popov

Academic Dissertation

To be presented, with the permission of the Faculty of Medicine,
University of Helsinki, for public discussion in the main lecture hall of
Töölö Hospital, Helsinki, on 10 October 2005 at 12 noon.

Helsinki 2005

Supervised by

Erkki Tukiainen, MD, PhD
Professor
Department of Plastic Surgery
University of Helsinki
Helsinki, Finland

Reviewed by

Inkeri Elomaa, MD, PhD
Professor
Department of Radiotherapy and Oncology
University of Helsinki
Helsinki, Finland

Karl von Smitten, MD, PhD
Docent
Department of Surgery, Breast Surgery Unit
University of Helsinki
Helsinki, Finland

Opponent

Hans-Ulrich Steinau, MD, PhD
Professor
Department for Plastic Surgery and Burns
Handcenter, Sarcoma Reference Center
BG - University Hospital "Bergmannsheil"
Ruhr University Bochum
Bochum, Germany

ISBN 952-91-9098-0 (paperback)
ISBN 952-10-2625-1 (PDF)
University Printing House
Helsinki 2005

To cancer patients and their loved ones

CONTENTS

LIST OF ORIGINAL PUBLICATIONS	6
ABSTRACT	7
ABBREVIATIONS	9
INTRODUCTION	10
REVIEW OF THE LITERATURE	11
1. Soft tissue sarcomas	11
1.1 Histology and classification	11
1.2 Incidence and clinical presentation	12
1.3 Pattern of growth	13
1.4 Grading	13
1.5 Aetiology	14
1.6 Dermatofibrosarcoma	15
1.7 DNA copy number changes in recurrent tumours	16
2. Treatment of soft tissue sarcomas of the extremities	16
2.1 Diagnosis	16
2.2 Surgical margin	17
2.3 Radiotherapy	19
2.4 Adjuvant chemotherapy	20
2.5 Centralisation of treatment to multidisciplinary teams	20
2.6 Treatment protocol at Helsinki University Central Hospital	21
2.7 Surgery for locally recurrent disease	21
2.8 Isolated limb perfusion and other neoadjuvant treatments	22
2.9 Surgery for metastatic disease	23
2.10 Reconstructive surgery in limb salvage	23
2.11 Extensive amputations and specific techniques	25
2.12 Tumour- and patient-related clinical prognostic factors for local recurrence	26
2.13 Outcome	28
3. Chest wall reconstruction	30
3.1 Tumours of chest wall	30
3.2 Methods for chest wall reconstruction	30
3.3 Survival of patients and results of surgery after chest wall resection	32
4. Surgery in dermatofibrosarcoma	33

AIMS OF THE STUDY	34
MATERIALS AND METHODS	35
1. Clinical material in soft tissue sarcomas of the extremities (Studies I and III)	35
1.1 Treatment guidelines	35
2. Comparative genomic hybridisation (Study II)	37
3. Resections and reconstructions of the chest wall (Study IV)	38
4. Dermatofibrosarcomas (Study V)	38
5. Statistical analysis (Studies I–V)	39
RESULTS	40
1. Sarcomas of the extremities (Studies I and III), Reconstructions of the chest wall (Study IV) and Dermatofibrosarcomas (Study V)	40
1.1 Procedures performed	40
1.2 Outcome of patients	43
1.3 Clinical prognostic factors	44
1.4 Surgical margins	44
2. DNA copy number changes between primary tumours and local recurrences (Study II)	47
2.1 Overview of results and mean number of changes	47
2.2 Most frequent minimal common regions of DNA aberrations	47
2.3 Clonal relationship	48
DISCUSSION	49
1. Treatment protocol for extremity soft tissue sarcomas (Studies I and III)	49
2. DNA copy number changes in local recurrences (Study II)	51
3. Reconstructions in musculoskeletal tumour surgery (Studies I, III–V)	52
5. Surgical treatment of chest wall tumours (Study IV)	55
4. Treatment protocol for dermatofibrosarcoma (Study V)	56
SUMMARY AND CONCLUSIONS	58
ACKNOWLEDGEMENTS	60
REFERENCES	62
ORIGINAL PUBLICATIONS	77

LIST OF ORIGINAL PUBLICATIONS

This thesis is based on the original articles listed on this page. They are referred to in the text by their Roman numerals. Some unpublished data are also presented.

- I Popov P, Tukiainen E, Asko-Seljavaara S, Huuhtanen R, Virolainen M, Virkkunen P, Blomqvist C. Soft tissue sarcomas of the lower extremity: surgical treatment and outcome. *Eur J Surg Oncol* 2000; 26: 679–85.
- II Popov P, Virolainen M, Tukiainen E, Asko-Seljavaara S, Huuhtanen R, Knuutila S, Tarkkanen M. Primary soft tissue sarcoma and its local recurrence: genetic changes studied by comparative genomic hybridisation. *Modern Pathology* 2001; 14: 978–84.
- III Popov P, Tukiainen E, Asko-Seljavaara S, Huuhtanen R, Virolainen M, Virkkunen P, Blomqvist C. Soft-tissue sarcomas of the upper extremity: surgical treatment and outcome. *Plast Reconstr Surg* 2004; 113: 222–30; discussion 231–2.
- IV Tukiainen E, Popov P, Asko-Seljavaara S. Microvascular reconstructions of full-thickness oncological chest wall defects. *Ann Surg* 2003; 238: 794–801; discussion 801–2.
- V Popov P, Böhling T, Asko-Seljavaara S, Tukiainen E. Microscopic margins and results of surgery for dermatofibrosarcoma protuberans. Accepted for publication in *Plast Reconstr Surg* in 8/2005.

ABSTRACT

Background: Soft tissue sarcoma (STS) is a relatively rare mesenchymal malignancy, that may occur almost anywhere in the human body; the most common sites, however, are the limbs. STS has an infiltrative growth pattern, and local recurrence of the disease after surgical treatment is common. STS typically disseminates haematogenously, most frequently in the lungs. Although the death of a patient with STS is usually due to distant metastases, local recurrence causes abundant morbidity and may lead to mutilating operations. The prevention and prediction of local recurrence are therefore an important goal. STSs of the extremities were traditionally managed by amputation. Today, however, a combination of limb-salvage surgery with radiotherapy has proved to be as effective as amputation in local control. The modern combined modality treatment and challenging diagnostics have prompted the need for multidisciplinary treatment groups. One such group was established at Helsinki University Central Hospital (HUCH) in 1988. Dermatofibrosarcoma, which has distinctive and more benign features than other types of STS, is excluded from the STS treatment protocol. Extensive plastic surgical reconstructions are frequently needed in the treatment of STS. In addition to the extremities, a common site for the occurrence of a malignancy requiring plastic surgical reconstructions is the chest wall, where the majority of the tumours are sarcomas or breast cancer recurrences.

Materials and Methods: The results of our STS treatment protocol are evaluated in a series of 186 patients with STS in an extremity. The gross and microscopic margins and the results of surgical treatment for 40 patients with dermatofibrosarcoma are studied, and guidelines for

treatment are sought. The results of the management of full-thickness chest wall resections with microvascular reconstructions in 26 patients are also evaluated. As local recurrence poses a problem in the treatment of STS, the genetic changes occurring between primary tumours and their subsequent local recurrences are studied in 20 patients by comparative genomic hybridisation (CGH). All plastic surgical reconstructions required in the treatment of these musculoskeletal malignancies are reported, with special reference to microsurgical techniques used in the chest wall.

Results: For extremity STSs, the 5-year local recurrence-free survival rate was 79%, the metastasis-free survival rate 70% and the disease-specific overall survival rate 76%. Ninety per cent of these patients were treated by limb salvage. The strongest factor predicting local relapse was extra-compartmental tumour location. In the patients with dermatofibrosarcomas, there were no local or distant recurrences or amputations, with average microscopic tumour-free margins of 1.6 cm. In patients requiring full-thickness chest wall resection, the 5-year survival rate was 28% for sarcomas and 13% for breast cancer recurrences; no operative mortality or flap losses occurred. The increase in genetic changes from primary to locally recurrent STS was detected by CGH, although no alteration specific for local recurrence was found. Plastic surgical reconstructions were required in 53% of all patients. The success rate for free flaps was 96.4%.

Conclusions: The treatment protocol of HUCH for STS is functioning well. Tumours located extracompartmentally should be the main target of efforts to improve treatment strategies. In the ma-

majority of patients with dermatofibrosarcoma, good local control can be achieved by plain surgical excision in one operation. Owing to tumour progression, local recurrences show an increased amount of genetic changes compared to primary STS. Reconstructive plastic surgical procedures, including free flaps, have a high

success rate and are frequently needed. Large microvascular reconstructions for full-thickness chest wall defects can be performed with acceptable results. The treatment of malignant musculoskeletal tumours often requires plastic surgical reconstructions.

ABBREVIATIONS

AIDS	acquired immunodeficiency syndrome
CGH	comparative genomic hybridisation
CNB	core needle biopsy
COL1A1	collagen type I alpha-1
CT	computed tomography
DFS	disease-free survival
DFSP	dermatofibrosarcoma protuberans
DSOS	disease-specific overall survival
EBV	Epstein-Barr Virus
FFCC	French Federation of Cancer Centers
FNA	fine needle aspiration
FNCLCC	Fédération Nationale des Centres de Lutte Contre le Cancer
HHV 8	human herpes virus 8
HUCH	Helsinki University Central Hospital
ILP	isolated limb perfusion
INF- γ	interferon gamma
LD	latissimus dorsi
LRFS	local recurrence-free survival
MFH	malignant fibrous histiocytoma
MFS	metastasis-free survival
MPNST	malignant peripheral nerve sheath tumour
MRI	magnetic resonance imaging
NCI	National Cancer Institute
NF 1	neurofibromatosis type 1
OS	overall survival
PDGF	platelet-derived growth factor
PNET	primitive neuroectodermal tumour
PTFE	polytetrafluoroethylene
RT	radiotherapy
SSG	Scandinavian Sarcoma Group
STS	soft tissue sarcoma
TFL	tensor fasciae latae
TNF- α	tumour necrosis factor alpha
TRAM	transverse rectus abdominis muscle
US	ultrasonography
VRAM	vertical rectus abdominis muscle
WHO	World Health Organization

INTRODUCTION

Soft tissue sarcoma (STS) is a relatively rare cancer that can occur in almost any site of the body. Unlike many other malignant neoplasms, it has various histological types and malignancy grades. Throughout history, this heterogenic nature of STS has caused difficulties in diagnostics and treatment. Formerly, STS was managed by amputation in nearly half of the patients. However, advances in radiotherapy (RT) and its application in conjunction with conservative surgery created a limb salvage treatment modality, and amputation rates began to fall. The increasing co-operation between specialities, the infrequent nature of these tumours, and the special problems involved in diagnosis created a need for multidisciplinary teams in which adequate diagnostics and treatment could be planned within the expertise of a pathologist, molecular genetic, radiologist, oncologist and surgeon familiar with the tumours.

Just such a team, the soft tissue sarcoma group was established at Helsinki University Central Hospital (HUCH) in 1988, and a treatment protocol that favoured limb salvage treatment and the selective combination of surgery and RT, depending on the postoperative margins achieved, was developed. The group meets once a week and plans the treatment of STS patients, who are referred from all over Finland. Scientific co-operation with the Scandinavian Sarcoma Group is close. In addition to patients with sarcomas, some with other musculoskeletal tumours calling for a multidis-

ciplinary approach, mainly for treatment by plastic surgeons, are also referred. To be successful, a multidisciplinary team should hold regular and frequent meetings, possess expertise in musculoskeletal oncological surgery and have the capability and resources for quick diagnosis and treatment. The prerequisite for running an effective multidisciplinary team is a sufficient number of patients. At the moment, the STS group of HUCH treats the majority of STS patients in Finland.

The STS group of HUCH has been running for almost 17 years now and in that time it has treated a considerable number of patients. The same principles for combining surgery and radiotherapy as practised at the beginning have been systematically applied during all these years. At the same time, experience has accumulated in operative techniques and methods of reconstructive surgery. When introducing new methods of treatment and diagnostics, it is essential to assess the adequacy of older methods to justify the need, if any, for changes in treatment programmes. Until a definitive, targeted treatment against STS at the molecular level has been developed, the main challenges in the treatment are how to further reduce the rate of local recurrence and need for amputations and to provide treatment with even better cosmesis and functional outcome. In these studies, we evaluate our experience in the treatment of STS and some other musculoskeletal malignancies with a view to improving the management of these diseases in this country and internationally.

REVIEW OF THE LITERATURE

1. Soft tissue sarcomas

1.1 Histology and classification

Soft tissue sarcomas are malignant non-epithelial soft tissue tumours located extra-skeletally. They are generally considered as primary malignant tumours of soft tissue. Soft tissue derives from the mesenchyme, embryological tissue consisting of mesodermal cells that, in the adult, give rise to structures such as connective tissues, muscle, blood, lymphatics, bone and cartilage. STSs also include malignant tumours arising from the peripheral nervous system because they present as soft tissue masses and pose similar problems in diagnosis and treatment (Weiss et Golblum 2001). The current thinking is that sarcomas develop from preprogrammed, undifferentiated, stem cells originating from tissue pools or bone marrow and not from mature cells, e.g. adipocyte or skeletal muscle cells (Miettinen 2003).

Soft tissue sarcomas constitute a diverse group of tumours that are neoplastic and have the propensity to recur locally or to metastasise distally. They are classified on the basis of tumour differentiation according to the tissue they resemble or are thought to resemble. The generally accepted basis for soft tissue tumour classification is the World Health Organization's (WHO) classification, which was revised in 2002 (Fletcher et al. 2002). It divides malignant soft tissue tumours or tumours of intermediate malignancy into more than 60 histological types. The main groups are as follows: adipocytic tumours, fibroblastic / myofibroblastic tumours, so-called fibrohistiocytic tumours, smooth muscle tumours, pericytic (perivascular) tu-

mours, skeletal muscle tumours, vascular tumours, chondro-osseous tumours and tumours of uncertain differentiation. In addition, a number of STSs are included in the WHO's classifications for neural tumours, skin tumours and bone tumours (Hogendoorn et al. 2004). A simplified classification of STS by cell type differentiation is presented in Table 1.

Although STSs are a heterogeneous group of tumours, they are considered as one group because of the similarities in the surgical treatment. Exceptions are the STSs of children and the sarcomas of adults located intra- or retroperitoneally, which are usually treated with different protocols. The most common histological types in adults are malignant fibrous histiocytoma (MFH) (38%), liposarcoma (14%), synovial sarcoma (11%) and leiomyosarcoma (6%) constituting approximately 70% of all STSs (Zagars et al. 2003). In young adults, synovial and fibrosarcoma are the most common types, whereas in older persons MFHs, liposarcomas and malignant peripheral nerve sheath tumours (MPNSTs) predominate. In children, rhabdomyosarcoma is the most common STS.

The classification of STS is based on histology. The most important step therefore is the examination of haematoxylin-eosin-stained sections under light microscopy at low power. The architectural pattern, appearance of the cells and the characteristics of the stroma give rise to several differential diagnostic options. Examination at high power magnification yields information on the degree and type of cellular differentiation, mitotic counts and figures, and nuclear atypia. More than 70 immunohistochemical markers are commonly available to help classify tumours accurately. The most important ones are en-

dothelial, muscle cell, neural and neuroendocrine, melanoma and histiocytic markers, keratins, other epithelial and mesothelial markers, other cell type markers and cell cycle markers. Most immunohistochemical markers are not specific to a certain sarcoma type and the diagnosis is usually based on the results of light microscopy and several immu-

nostainings with different markers. In recent times, genetic methods have revealed specific genetic alterations in several STS types. These changes are used as diagnostic tools and they may also be specific targets for treatment in the future (Knuutila et al. 1998, Knuutila et al. 1999, Borden et al. 2003).

Table 1. Main types of STS by cell types they resemble

Type of differentiation	Most common sarcoma type
Adipocytic	liposarcoma
Fibroblastic / myofibroblastic	fibrosarcoma
So-called fibrohistiocytic	malignant fibrous histiocytoma
Smooth muscle	leiomyosarcoma
Pericytic (perivascular)	malignant glomus tumour
Skeletal muscle	rhabdomyosarcoma
Vascular	angiosarcoma, Kaposi sarcoma
Chondro-osseous	extraskelatal chondrosarcoma, extraskelatal osteosarcoma
Peripheral nerve	MPNST (malignant peripheral nerve sheath tumour)
Uncertain differentiation	synovial sarcoma, epithelioid sarcoma, extraskelatal Ewing sarcoma, clear cell sarcoma

1.2 Incidence and clinical presentation

Soft tissue sarcomas are rare tumours. In Finland, the incidence of STS was 144 new cases in 2002, with an annual incidence rate for females of 1.4 per and for males of 1.9 per 100 000 person years (Finnish Cancer Registry 2004). STSs account for about 1% of all malignancies. The incidence of benign mesenchymal tumours is at least 100 times that of malignant ones. The incidence of STS increases heavily after 60 years of age. Approximately 60% of STSs are located in limbs and, of these, more than two

thirds in the lower limbs. Other sites are the trunk (17.9%), retroperitoneum (12.5%), head and neck region (8.9%) and mediastinum (1.3%) (Lawrence et al. 1987). On average, 40% of the tumours are located superficially, the remainder being deep-seated (Trovik et al. 2000). One-tenth of the patients have detectable metastases at diagnosis of the primary tumour. Of all distant and local recurrences, 70% develop within two years and 93% within five years of initial treatment (Zagars et al. 2003).

Soft tissue sarcoma normally presents as an enlarging, painless and asymptomatic soft tissue mass in the limbs or

trunk. The consistency varies depending on the tumour type, but it often resembles a soft, benign lesion such as a lipoma. In several cases, patients have linked the occurrence of the tumour with some previous trauma in the affected area, but there are no data to support a causal relationship. Local symptoms usually develop late (Stefanovski et al. 2002). A large tumour may cause compression of neural and vascular structures, resulting in radicular pain, venous stasis and lymphoedema. In the advanced stage, the tumour may infiltrate the overlying skin, causing ulceration or necrosis. In a large tumour, necrosis may cause pain, swelling and fever (Figure 1). Deep-seated tumours are often difficult to assess by palpation. The median tumour size at diagnosis varies from 6 to 7 cm with a wide range (Coindre et al. 1996, Vraa et al. 1998).

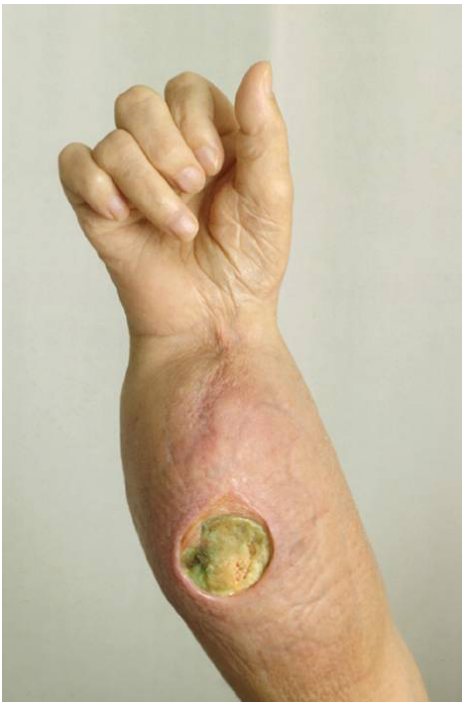

Figure 1. MFH in the forearm

1.3 Pattern of growth

Soft tissue sarcomas enlarge in a centrifugal fashion. As the tumour grows, peripheral cells are compressed in parallel layers, constituting a macro- and microscopic “pushing” border. (Broders et al. 1939) Peripheral to this is the “reactive zone”, which is composed of granulation-like mesenchymal proliferations with oedema and neovascularity. Microscopic extensions of the tumour nearly always pass through the reactive zone into normal tissue. These two zones have been called the “pseudocapsule”, as the gross appearance resembles the anatomic capsule-like boundary that separates the tumour from normal-looking tissue. (Enneking et al. 1981) Skip metastases, which are tumour tissue but not connected to the parent tumour, are usually found in high-grade lesions.

1.4 Grading

As well as being divided into histological types, STSs are graded according to degree of malignancy. The most important factor predicting the probability of metastases and survival is the histological malignancy grade (Coindre et al. 1996). This grade also affects the probability of local recurrence and has profound influence on the treatment strategy eventually chosen. Three grading systems are widely used. The French Federation of Cancer Centers (FFCC, also called FNCLCC) and the National Cancer Institute (NCI) both use systems with three grades (I low, II and III high) according to tumour differentiation, mitotic count and tumour necrosis (Guillou et al. 1997). In Scandinavia, a four-grade system is generally used (Markhede et al. 1982, Meis-Kindblom et al. 1999). It has indeed been reported that a four-grade system (I and II low, III and IV high) increases the prognostic information (Broders et al. 1939, Alvegård et al. 1989). All sys-

tems designate tumours as high or low-grade tumours. Low-grade sarcomas generally have a good prognosis and a low capacity for distant metastases, though local relapses occur after inadequate surgical excision. High-grade tumours have a high propensity for distant metastases and also for local recurrence. In the four-tiered system, patients with grade I or II tumours had 100% five-year survival, grade III 68% and grade IV 47% (Markhede et al. 1982). In the three-grade system including all locations, the five-year survival rates for grades I, II and III tumours were 78.4%, 57.8% and 25.3%, respectively (Hashimoto et al. 1992).

1.5 Aetiology

All neoplastic tumours are believed to arise because of genetic alterations leading to increased or decreased production of the proteins, that regulate normal cell growth and proliferation. In STSs, the aetiology is poorly understood. Only a minority of STSs can be attributed to known aetiological agents. Ionizing radiation has been shown to induce sarcomas in the previously irradiated field. The most common types of postirradiation sarcomas are MFH and osteosarcoma (Wiklund et al. 1991). Postirradiation sarcomas are usually high-grade tumours. The most common diseases for which patients receive radiation therapy are breast, ovarian and endometrial carcinomas and lymphomas. The median latent period from irradiation to sarcoma diagnosis has been reported to be 13 years (Amendola et al. 1989). The risk of developing postirradiation sarcoma after radiotherapy with long-term follow-up has been estimated to range from 0.03% to 0.80% (Mark et al. 1994). Chronic lymphoedema, either congenital or acquired, has been documented to induce angiosarcomas on rare occasions (Roy et al. 2004). Treatment-related

angiosarcoma occurring in lymphedematous extremity after breast cancer surgery (Stewart-Treves syndrome) has accounted for the majority of these cases (Stewart et Treves 1948).

Oncogenic viruses are responsible for some sarcoma cases, especially in patients with immunodeficient conditions such as AIDS or therapeutic immunosuppression. There is strong evidence that HHV 8 is the causative factor in AIDS-associated Kaposi sarcoma (Chang et al. 1994, Pantanowitz et al. 2004). EBV may also cause leiomyosarcomas and other smooth-muscle tumours in immunodeficient patients (McClain et al. 1995).

Exposure to certain toxins has been proposed to increase the risk of developing STS. Vinyl chloride, which is a chemical agent used in the plastics industry, has been documented to induce hepatic angiosarcoma (Evans et al. 1983). An increased risk of STS in workers exposed to phenoxyacetic herbicides and dioxin has also been reported (Kogevinas et al. 1995). No increase in risk due to low exposure to dioxin via food was detected in a population-based series (Tuomisto et al. 2004).

A number of genetic diseases predispose to the development of soft tissue tumours and also sarcomas (Zahm et al. 1997). The most important for STS is type 1 neurofibromatosis (NF 1), in which patients develop numerous benign neurofibromas, and in which the risk of developing malignant peripheral nerve sheath tumours (MPNST, earlier called malignant schwannomas) is also increased. Li-Fraumeni syndrome is characterised by familial rhabdomyosarcomas, early onset of breast carcinoma and other neoplasms. The inherited form of retinoblastoma is also associated with the development of other malignancies, notably osteosarcoma. In Gardner's syndrome, familial polyposis of the colon occurs with mesenchymal lesions such as desmoid tumours, aggressive fibromatosis, osteoma and, infrequently fibrosarcoma.

1.6 Dermatofibrosarcoma

Dermatofibrosarcoma, also called dermatofibrosarcoma protuberans (DFSP), is a low-grade superficial STS originating in the skin or, rarely, in the subcutaneous tissue (Diaz-Cascajo et al. 1998). DFSP typically occurs in young or middle-aged adults, with male predominance. It comprises less than 0.1% of all malignancies and 1% of STSs (McPeak et al. 1967, Smola et al. 1991). It is usually located in the trunk or proximal extremity, but can occur anywhere in the dermis (Figure 2). DFSP behaves like low-grade superficial STS and tends to grow slowly.

Histologically, DFSP is a mesenchymal tumour originating in the dermis and consisting of fusiform fibroblasts arranged in a cartwheel or storiform pattern. It is distinguished from fibrosarcoma by features such as absence of nuclear atypia, increased mitotic rate and increased cellularity. DFSP is positive for the immunohistochemical markers vimentin and CD 34. The origin of DFSP is indeed attributed to periadnexal cd 34-positive fibroblasts as their immunohistochemical profile is similar to that of DFSP. Immunohistochemical staining for CD 34 is especially helpful in differential diagnosis of DFSP and dermatofibroma (also called benign fibrous histio-

cytoma, BFH, histiocytoma). Recently, a novel immunohistochemical marker, apolipoprotein D, which is relatively specific for DFSP, has also been reported to be useful in differential diagnosis of DFSP and dermatofibroma (West et al. 2004). Ring chromosomes containing material from chromosomes 17 and 22 are typical cytogenetic changes in DFSP in adults (Naeem et al. 1995). DFSP has a specific t(17;22)(q22;q13) translocation with COL1A – PDGFB gene fusion (Simon et al. 1997), resulting in production of platelet-derived growth factor beta (PDGF β), subsequently leading to autocrine growth stimulation of the tumour.

Histological tumour margins usually extend far beyond the gross margins, with tentacle-like projections. DFSP typically recurs locally unless complete excision is performed. Local recurrences tend to develop late, 25–30% of them more than five years after the initial treatment (Snow et al. 2004, Chang et al. 2004). Metastasis is rare and occurs in fewer than 4% of patients; it is commonly preceded by multiple local recurrences. Metastases tend to develop in DFSPs with fibrosarcomatous changes, but are not necessarily preceded by de-differentiation in local recurrence (Rutgers et al. 1992, Mentzel et al. 1998).

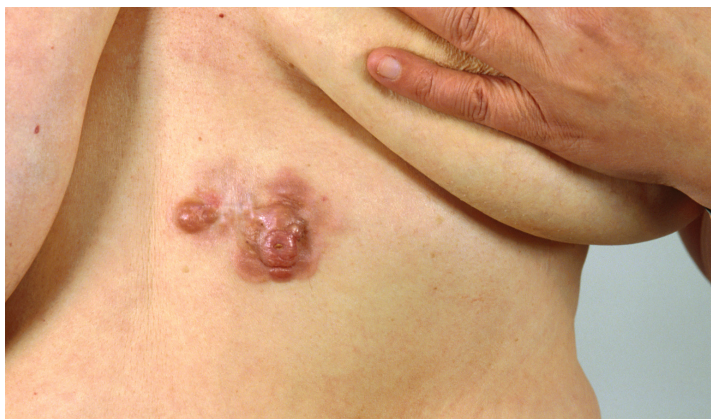

Figure 2. Dermatofibrosarcoma in the epigastrium

1.7 DNA copy number changes in recurrent tumours

In general, the evolution of a malignant tumour is initiated at the molecular level. In some tumours these initial changes lead to alterations in the DNA sequence copy number, where single genes may have been multiplied or lost (Struski et al. 2002). At the chromosomal level, these changes in DNA copy number may be visible as losses or gains of particular chromosomal regions or even of entire chromosomes. Comparative genomic hybridisation (CGH) detects alterations in the DNA sequence copy number, in other words, gains, losses and high level amplifications, screening the whole tumour genome in a single hybridisation (Kallioniemi et al. 1992). The alterations detected can be used as differential diagnostic tools, prognostic markers or markers predicting a response to targeted treatment (Hogendoorn et al. 2004). Comparisons between a primary tumour and its recurrence offer a longitudinal view of tumour progression.

At present, little is known about the local genetic progression of STS. Only a few reports about cytogenetic changes in primary and locally recurrent STS appear to have been published (Örndal et al. 1993, Mandahl et al. 1989). In one of these, the evolution of a fibrosarcoma was monitored by cytogenetic methods over a period of 26 months, revealing that chromosomal aberrations increased in parallel with clinical and histopathological tumour progression (Örndal et al. 1993). An increase in copy number aberrations in local recurrences studied by CGH has also been found in in situ ductal breast carcinomas (Waldman et al. 2000) and in prostate cancer (Visakorpi et al. 1995). No large series concerning genetic changes in primary and locally recurrent STS studied by CGH have been reported.

Genetic tumour progression has been more extensively studied in metastatic disease. An increase in the total number of changes during tumour progression has been found between primary sarcomas and their pulmonary metastases (Tarkkanen et al. 1999). An increase in copy number aberrations from a primary tumour to a metastasis, studied by CGH has also been detected in breast cancer (Nishizaki et al. 1997), melanoma (Balázs et al. 2001), colorectal cancer (Al-Mulla et al. 1999, Jiang et al. 2005), aesthesioneuroblastoma (Bockmühl et al. 2004) and fibrolamellar hepatocellular carcinoma (Wilkins et al. 2000).

Specific alterations for metastatic tumours have not been detected in sarcomas (Tarkkanen et al. 1999), breast cancer (Nishizaki et al. 1997) or small-cell lung carcinoma (Schwendel et al. 1997). In renal clear cell carcinoma, an increase in the copy number of genes located at 1q has been reported to correlate with metastatic events (Gronwald et al. 1997). In colorectal cancer, loss of 4q has been suggested as a potential supplementary factor for dissemination of the disease (Jiang et al. 2005). In aesthesioneuroblastomas, deletions on chromosome 11 and gains of 1p are associated with metastasis formation and poorer prognosis (Bockmühl et al. 2004).

2. Treatment of soft tissue sarcomas of the extremities

2.1 Diagnosis

Biopsy is the critical step in the diagnosis of soft tissue tumours. The methods commonly available are open surgical biopsy, core-needle biopsy (CNB) and fine needle aspiration (FNA). Surgical biopsy takes the form of either incisional biopsy, in which wedge-shaped sample of tumour is

incised, or excisional biopsy, in which the entire macroscopic tumour is removed. In the past, before treatment was centralised, open biopsies were favoured. Surgical biopsy is, however, an inherently difficult procedure, with high potential to spread the disease and jeopardise limb-salvage treatment. In a series of patients that included biopsies performed in referring institutions and those performed at the treatment centre, the rate of diagnostic error for open biopsies was as high as 18%, and problems with the biopsy forced the surgeon to carry out a different, and often more complex, operation or to use adjuvantive RT or chemotherapy in 19% of patients (Mankin et al. 1996). For this reason and due to the development of other methods, surgical biopsies have nowadays been mainly replaced by CNB and FNA. In the infrequent cases in which surgical biopsy is required, it should be performed by the definitive operating surgeon, so that it is planned in concordance with the eventual operation. It has been proposed that superficial soft tissue tumours larger than 5 cm and all deep seated lesions (with a 10 % risk of malignancy) should be referred to a specialised centre before any surgical procedures are conducted (Rydholm 1983).

Needle biopsies are minimally invasive procedures and they have mostly replaced surgical biopsies. CNB has been shown to have a sensitivity of 82–100% and a specificity of 91–100% in STS, with complication rates of 0–1.1% (Welker et al. 2000). CNB is as effective as incisional biopsy in the diagnosis of soft tissue tumours and the subtyping or grading of STS and has, moreover, lower morbidity (Hoeber et al. 2001). CNB and FNA can also be combined to increase accuracy. FNA provides only a cytological sample with scant tissue, and thus exact typing and grading are not usually possible. However, in the diagnosis of sarcoma, a positive predictive value of 99% has been reported when the cytopathologist was

provided with clinical information (Thunnissen et al. 1993). In tumours with a hard consistency yielding a non-diagnostic CNB, FNA may be diagnostic as it penetrates the tumour more readily than CNB. To ensure representative samples at the first attempt, needle biopsies are usually taken under ultrasound or computed tomography (CT) guidance. Guidance with radiological methods is particularly important in deep tumours and in tumours containing radiologically divergent areas.

2.2 Surgical margin

Surgery is the first-line treatment in the management of STS. Owing to infiltrative growing, plain macroscopic tumour removal, the “shelling-out procedure”, results in local recurrences in a majority of cases. Until the 1970’s, amputation was the only curative option for patients with STS. At many centres, sarcomas were first locally excised, usually with inadequate margins. Then, if the tumour recurred locally, the limb was amputated. This resulted in amputations in nearly half of the patients (Shiu et al. 1975).

In 1981, Enneking evaluated the importance of fascial boundaries to local recurrence rate (Enneking et al. 1981). In a classification that forms the basis for the concept of surgical margin in sarcoma surgery, he divided the surgical margin into four types: in the intralesional margin, the tumour forms the periphery of part or all of the specimen; in the marginal margin, a pseudocapsule forms the periphery of the specimen; in the wide margin, a cuff of non-reactive normal tissue forms the periphery of the specimen; and in the radical margin, all normal tissue of the compartment(s) involved encases the specimen *en bloc*. Because, theoretically, sarcomas do not penetrate fascial boundaries, the radical margin leaves no residual microscopic

disease. Enneking applied his classification of margin to both excisions and amputations. However, in clinical practice, the term “radical margin” or “radical surgery” should be addressed with caution, since it has been used to describe margins that are maximal in the surgeon’s judgement, without any connection to the actual histological margin.

Enneking’s classification has been accepted worldwide. Nevertheless, it is not always sufficiently accurate due to the broad range of definitions of wide surgical margin. According to Enneking’s definition, a margin is wide when it is surrounded by a cuff of normal tissue irrespective of its thickness (Enneking et al. 1981). In recent years, though, a variety of more accurate descriptions of the surgical margin have been used. Common practice is to classify margins as positive or negative. A positive margin has been defined as one in which tumour cells are present at or within 1 mm of the resection margin, but which is otherwise negative (Alektiar et al. 2002). In some reports, margins have been documented as grossly positive, microscopically positive, close (5 mm or smaller) or negative (Herbert et al. 1993); in others as clear (≥ 10 mm), close (1–9 mm) or positive (McKee et al. 2004).

Radiotherapy combined with surgery has been shown to reduce local recurrences (Rosenberg et al. 1982, Pisters et al. 1996, Yang et al. 1998). Implying that RT eliminates viable tumour cells left in the operation area, this finding has resulted in narrower margins and less mutilating operations. Radical or compartmental margins cause abundant morbidity, and they are no longer goal of treatment. However, even with RT, the rate of local recurrence is increased when postoperative margins are positive (Herbert et al. 1993, Sadoski et al. 1993, Alektiar et al. 2002). Thus, optimal surgical removal of the disease is still of paramount importance.

The only prognostic factor the surgeon can influence is the surgical margin. A positive microscopic surgical margin is an unfavourable prognostic factor for local control and disease-free survival (McKee et al. 2004, Vraa et al. 1998). The extent of the adequate surgical margin has not, however, been uniformly defined. Moreover, few studies have been conducted on the link between a precise margin width and outcome.

Wide excision is usually considered to be resection of the tumour with a rim of normal tissue in the judgement of the surgeon, regardless of the thickness of the normal tissue rim (McKee et al. 2004). In a recent report from the Roswell Park Cancer Institute, in approximately one half of the tumours treated with wide excisions, the closest margin of resection measured less than 1 cm, and in 10% of the widely excised tumours microscopic margins were positive (McKee et al. 2004). Similar results have been published earlier (Pisters et al. 1996, Sadoski et al. 1993, Lewis et al. 2000). The prognostic factor for local recurrence was a margin width less than 1 cm, and in these cases postoperative radiotherapy is recommended (McKee et al. 2004). In an 837 patient-series from Tokyo, the largest reported to date, the width of surgical margins was analysed in detail. Margins greater than 2 cm resulted in approximately 90% local control ($p < 0.001$) (Kawaguchi et al. 2004). The system of margin evaluation used in the study, drafted by the Bone and Soft Tissue Committee of the Japanese Orthopaedic Association in 1989, is the most comprehensive published and can be applied to bone sarcomas. It also takes into account the role of barriers (the tissues resisting tumour invasion e.g. fascia, joint capsule, tendon). The authors conclude that, for high-grade sarcomas, the margin should be wider than 3 cm; for narrower margins, RT is recommended (Kawaguchi et al. 2004).

2.3 Radiotherapy

Progress in RT has made more conservative surgery possible. The efficacy of RT combined with surgery has been well documented to improve local control in the STS of the extremities (Rosenberg et al. 1982, Pisters et al. 1996, Yang et al. 1998). The use of RT has enabled the size of resection margins to be reduced to wide or even marginal. Radical resection margins, which are most often feasible only by amputation, are nowadays seldom encountered.

Radiotherapy can be applied externally either before (preoperative) or after (postoperative) the surgery. In brachytherapy, the radiation dose is delivered at a low rate for a few days after surgery through catheters placed in the surgical bed during the operation (Alektiar et al. 2002). In intraoperative RT, the radiation dose is delivered during the surgery either through high dose rate radioactive catheters in the surgical bed (Kretzler et al. 2004) or via an electron beam accelerator fitted in the operating room (Lehnert et al. 2000). In a randomised trial, intraoperative RT combined with postoperative RT reduced local recurrences of retroperitoneal sarcomas as compared with postoperative RT alone (Sindelar et al. 1993). In all RT, irrespective of the specific technique used, it is essential to avoid radiation of joints or full limb circumference. It has also been reported that the risk of radiation-induced femoral shaft fracture is 29%, when radiation is combined with periosteal stripping (Lin et al. 1998).

External beam RT is the most widely used modality, since practices for its use are routine nowadays, and its application is technically less complex. In a randomised prospective study, it was reported that, in local control, conservative surgery with external beam RT is as effective as amputation in high-grade STS (Rosenberg et al. 1982). Another randomised

prospective trial found that external beam RT improves local control for both high and low-grade tumours in extremities (Yang et al. 1998). RT is more commonly given postoperatively than preoperatively. Postoperative RT has the following advantages: the operation can be performed without delay; the surgical specimen and margins can be accurately histologically analysed; and, in the event of wide margins, RT can be omitted. Nevertheless, preoperative RT may be favoured in efforts to reduce the tumour size before surgery with a view to minimising the resection area, reducing the seeding of viable tumour cells over the operative field and reducing the treatment volume. However, a randomised trial comparing pre- and postoperative RT, with wound complications as an end point, found that preoperative RT was associated with a greater risk of wound complications (O'Sullivan et al. 2002). In another randomised trial, the delivery of RT either pre- or postoperatively had only minimal impact on the function of patients (Davis et al. 2002). Preoperative RT and chemotherapy also cause tumour necrosis and thus confound histopathological typing and grading of the surgical specimen. Neither sequencing of RT with surgery has been proved to provide a reliable benefit for outcome (Strander et al. 2003). Preoperative RT is recommended for large tumours in a difficult location to reduce their size and to make conservative surgery possible (Robinson et al. 1998).

In one randomised trial, brachytherapy reduced the number of local recurrences in high-grade tumours (Pisters et al. 1996), whereas in another the reoperation frequency due to wound complications was higher with brachytherapy and surgery than with surgery alone, but lacked statistical significance (Alektiar et al. 2000). In general, local control rates and complications are similar to those of external beam RT, and the choice of RT method depends on the institution, the

physician's expertise and the clinical situation (Strander et al. 2003). Some authors have even concluded that RT should be applied to low-grade tumours under the same principles as for high-grade tumours (Choong et al. 2001, Yang et al. 1998).

Current treatment protocols combine a wide variety of surgical procedures with some modality of RT. An important distinction in the pattern of multimodality therapy is whether RT is combined with surgery routinely or selectively. In most series, RT is delivered liberally to nearly all patients with variable widths of postoperative excision margins (Zagars et al. 2003). In a report from Italy, RT is delivered to all high-grade tumours and to marginal resections in tumours of any grade (Stefanovski et al. 2002). Current treatment protocols recommend radiation therapy for all tumours greater than 5 cm (Pisters et al. 1998, Demetri et al. 1998). The non-selective application of postoperative RT to all, at least to high-grade, sarcomas is probably due to the lack of recommendations for safe margins. A selective combination of treatment modalities, in which the delivery of RT is based on depth and surgical margins, has been employed in some countries, e.g. in Scandinavia (Trovik et al. 2001) and Japan (Kawaguchi et al. 2004).

2.4 Adjuvant chemotherapy

According to meta-analysis of 14 randomised trials comprising a total of 1568 patients, doxorubicin-based adjuvant chemotherapy appeared to significantly increase the time to local or distant recurrence and to improve the overall recurrence-free survival rate in adults with localised resectable STS. Significant absolute benefits were 6-10% at 10 years, and there was some evidence of a trend towards improved overall survival (Sar-

coma Meta-Analysis Collaboration, 2000). A recent randomised trial also found that the impact of chemotherapy was significant for disease-free survival and overall survival (Frustaci et al. 2001), although contradictory results have been reported, too (Gortzak et al. 2001).

2.5 Centralisation of treatment to multidisciplinary teams

A multidisciplinary approach consisting of conservative surgery, modern reconstructive methods and RT has proved to be the most effective method in local control and in efforts to preserve a functional limb (Wiklund et al. 1996, Gustafson et al. 1994). In a large SSG study based on 1851 patients treated in 1986-1997, a wide or compartmental margin was achieved in 66% of patients operated on at sarcoma centres as compared to 11% of those operated on elsewhere, with five-year local recurrence free survival rates of 80% and 30%, respectively (Bauer et al. 2001). In another series from Sweden, this one with 375 patients, the local control rate for patients referred to a specialist centre before surgery was 82%, for those referred after surgery 76% and for those not referred at all 55% (Gustafson et al. 1994). In a report from the USA, 91% of the patients referred to a specialist centre after an excision judged to be complete in a local hospital were found to have microscopic residual tumour in the wider re-excision specimen (Karakousis et al. 1995). In a regional audit from the UK evaluating STS treatment practice in 1986-1992, 21% of patients satisfied the criteria for optimal preoperative investigation, 40% did not have any cytological or histological confirmation of the diagnosis before supposed definitive surgery, and only 60% were eventually treated adequately (Clasby et al. 1997). In a recent series from France, only 7% of patients were reviewed by a multidisciplinary team before biopsy, and

clinical practice guidelines for initial surgery were fulfilled in 52% of patients (Ray-Coquard et al. 2004). In a historical, population-based study from Finland, the local control rate for patients with extremity STS was 57%, with an amputation rate of 10% (Rantakokko et al. 1979). In a more selected series from our hospital before the multidisciplinary treatment era, the three-year disease-free survival rate was 36% (Gröhn et al. 1979) whereas in the preliminary report on the present series the three-year disease-free survival rate was 69% (Wiklund et al. 1996). In the light of the better conformity in diagnostics and the more favourable treatment results, centralisation of the treatment of STS is recommended.

2.6 Treatment protocol at Helsinki University Central Hospital

The HUCH treatment protocol includes all adult STSs excluding visceral sarcomas, DFSP and Kaposi sarcoma. The principles of treatment are surgery selectively combined with postoperative RT. A detailed description of the extent of surgical margins and the combination of surgery with RT is given in the section Materials and Methods. Preoperative RT is delivered to large tumours in difficult locations where even marginal surgery does not seem feasible and conservative surgery is attempted. RT is planned by means of CT scanning. The target volume is the involved muscle compartment in a transversal direction, and a margin of at least 5 cm longitudinally. Whenever possible, a strip of subcutaneous tissue, long bone or joint is spared. In both preoperative and postoperative RT, the radiation dose is 50 Gy over a period of five weeks. A boost of 10-20 Gy is delivered at a smaller target volume to microscopically positive surgical margins.

At present, adjuvant chemotherapy is given to all patients under 70 years of

age with high-grade tumours or tumours that fulfil two of the following criteria: size larger than 8 cm (in synovial sarcomas 5 cm), necrosis, vascular invasion. Adjuvant chemotherapy is also considered for patients in whom surgery and RT are not expected to give adequate local control. Adjuvant chemotherapy consists of an adriamycin-ifosfamid combination that is given six times with three-week breaks between treatments. Chemotherapy is applied with a different scheme to histological types such as extraskelatal Ewing sarcoma, PNET, extraskelatal chondrosarcoma, extraskelatal osteosarcoma, rhabdomyosarcoma, malignant mesenchymoma, clear cell sarcoma, alveolar soft part sarcoma and epithelioid sarcoma.

Currently, all patients with pulmonary metastases undergo metastasectomy, if feasible. After surgery, chemotherapy is delivered to patients under 70 years of age if the number of metastases exceeds five or disease-free survival is expected to be less than six months. Inoperable metastases are treated with chemotherapy.

The follow-up interval for high-grade tumours is two months during the first two years and thereafter four months, and for low-grade sarcomas four and six months, respectively. A chest x-ray is taken at each follow-up visit and also a chest CT when necessary. A CT or MRI scan from the operative area is routinely taken six months postoperatively in high-grade sarcomas and one year postoperatively in low-grade STS, and thereafter if local recurrence is suspected. Patients are routinely followed for at least five years.

2.7 Surgery for locally recurrent disease

Local recurrence presents a challenge in the treatment of STS. The frequency of local recurrence ranges from 10% to

60%, depending on the extent of the surgery performed. Today, the rate of local recurrence is considered as an indicator of the quality of primary treatment. However, it is well known that patients with local recurrence are more prone to develop distant metastases (Lewis et al. 1997). Consensus is lacking as to whether this is a sign of a more malignant tumour with a greater propensity to spread or whether there is a causal association between local recurrence and the development of distant metastases. Prior local recurrence was reported as a significant factor for subsequent local recurrences in the largest series published (Pisters et al. 1996, Zagars et al. 2003).

With modern treatment for primary tumours, the frequency of local recurrences reported in most series has been 10–20% (Table 3). In a study on patterns of recurrence, the disease recurred in 35% of patients, with isolated local recurrences accounting for about 20% and local recurrences with synchronous metastases for 4% of all disease recurrences (Potter et al. 1985). Thus the frequency of patients presenting with an isolated local recurrence after multidisciplinary treatment was no more than 7%. The outcome may be more favourable for late recurrences, since 50% of recurrences occurring later than five years after initial treatment were local failures alone as compared with 25% of the recurrences occurring earlier than five years after initial treatment (Gibbs et al. 2000). Previous surgery and / or RT for primary tumour make the operating conditions more difficult. It is thus also more difficult to achieve adequate local control (Robinson et al. 1990). In isolated local recurrences treated surgically, the five-year local recurrence-free and overall survival rates were 72% and 77%, respectively, with an amputation rate of 25% (Midis et al. 1998). In another series, the amputation rate was 22%, which was more than twice as high as with primary tumours (Trovik et al. 2000). Aggressive surgical

treatment of local recurrences would seem to be justified in the light of relatively good results achieved after adequate treatment of local recurrence.

2.8 Isolated limb perfusion and other neoadjuvant treatments

Isolated limb perfusion (ILP) is a treatment method, in which the limb is isolated from the systemic circulation and perfused with anti-tumour drugs. ILP exposes tumours to drug concentrations 20 times as high as in systemic therapy (Benckhuijsen et al. 1988). Although ILP was initially described in 1958 (Creech et al. 1958), it has mainly been employed during the last 15 years, most frequently in melanoma and STS. There are no studies on ILP in locally resectable STS (Noorda et al. 2004). No randomised trials have been conducted on ILP in unresectable STS, though several retrospective series have been reported. The treatment protocol most often described is mild hyperthermic perfusion with melphalan and TNF- α , in some patients with additional IFN- γ (Eggermont et al. 1996). In the largest series, comprising 186 patients treated with ILP combined with surgery, 64% of patients attained local tumour control with limb preservation (Eggermont et al. 1996). Limb salvage rates from 57% to 86% have been reported in smaller series (Noorda et al. 2003, Lejeune et al. 2000). Another method of treatment for locally advanced tumours is intra-arterial chemotherapy combined with preoperative RT, but this has been associated with a high rate of complications and toxicity (Huth et al. 1988). According to a recent meta-analysis consisting of 19 series with a total of 1173 patients, ILP seems to be a more effective limb sparing, neoadjuvant treatment modality than any of the other neoadjuvant treatment options for unresectable STS of the limb (Noorda et al. 2004).

2.9 Surgery for metastatic disease

Pulmonary metastases affect from 20% to 38% of all STS patients (Potter et al. 1985, Gadd et al. 1993, Billingsley et al. 1999). The most common site for metastases is the lungs, and most patients dying from STS have pulmonary metastases. Pulmonary metastases without synchronous recurrence at other sites is the most common pattern of recurrence and accounts for about half of all disease recurrences (Potter et al. 1985). There are no prospective randomised studies on the impact of resection of pulmonary metastases on survival. In a meta-analysis of 2612 patients, resection of pulmonary metastases yielded five-year survival rates of 21–38%, with median survival of 18–21 months (Chao et al. 2000). For a few patients, the procedure may even be curative (Gadd et al. 1993, Casson et al. 1992). These clinical series suggest that metastasectomy improves survival. Moreover, in a recent study of 1124 patients with pulmonary metastases, pulmonary resection was the most cost-effective treatment strategy (Porter et al. 2004). Multiple studies have shown that the most important favourable predictor for survival is the ability to completely resect all disease (Van Geel et al. 1996, Pastorino et al. 1997, Billingsley et al. 1999, Verazin et al. 1992). Negative markers for survival in most studies have been rapid tumour doubling time (less than 20 days), short disease-free interval (less than 12 months) and high tumour grade. A new method for the treatment of pulmonary metastases is isolated lung perfusion with chemotherapeutic agents. The clinical value and survival benefit of this new treatment are being tested in ongoing trials (Van Putte et al. 2003).

In most types of STS, metastases of the lymph nodes are relatively rare. Exceptions are rhabdomyosarcoma, epithelioid, clear cell, synovial and vascular sarcomas (Blazer et al. 2003). In a recent

series of 1066 patients, 39 (3.6%) developed lymph node metastases. Resection of the lymph nodes involved led to five-year survival of 57%, whereas patients treated without surgery all died within 30 months (Riad et al. 2004). In an earlier series of 1772 patients, radical lymphadenectomy for patients with nodal involvement in the absence of other metastases yielded 34% five-year survival (Fong et al. 1993). These results suggest that aggressive surgical treatment for lymph node metastases is justified.

Sentinel node biopsy (SNB) is not currently a routine procedure in the treatment of STS, since sarcomas do not usually send metastases to regional lymph nodes. Its use has been reported only in the sarcomas with a propensity for lymph node metastasis, e.g. clear cell sarcomas (Al-Refaie et al. 2004) and childhood rhabdomyosarcomas (McMulkin et al. 2003). The value of SNB is currently being investigated in these tumours, but due to the rarity of these diseases no patient series has as yet been reported.

2.10 Reconstructive surgery in limb salvage

Wide or even marginal excision of STS often causes a large soft tissue defect, and the wound cannot then be closed due to a lack of soft tissue. In cases of direct wound closure, the excessive tension in the wound edges reduces the blood flow in the wound, thus impairing the capacity for healing. In a randomised study on the complications of brachytherapy, a width of excised skin exceeding 4 cm resulted in a significantly higher re-operation rate (Alektiar et al. 2000). If the floor of the operative field contains muscle, skin grafts may be used for reconstruction. However, if tendons, joints, major vessels or nerves are exposed, the reconstruction has to be performed with vascularised tissue. Immediate vascular-

ised tissue transfers are particularly important in defects of the thoracic and abdominal walls or cranium, where the lack of soft tissue would otherwise leave vital organs exposed.

Traditionally, two types of flap have been available for reconstruction, local and pedicled. These flaps may contain skin and subcutaneous tissue and / or muscle. Pedicled flaps are connected to the circulation via their vascular pedicle and local flaps via their base, which consists of skin and subcutaneous tissue. The flaps are transposed or rotated to their new location to cover the defect. However, the arch of rotation limits the use of such flaps and they do not always extend far enough to cover the defect. Moreover, flaps may already have been used, they may have been violated by previous surgery or RT, or their elevation might cause unacceptable morbidity to an already compromised extremity. Further, in cases where the extent of the tumour excision is inadequate, harvesting a local flap may spread the disease to the donor site.

Progress in microvascular techniques has solved many of the problems associated with local or pedicled flaps, so much so that free flaps are now everyday workhorse techniques with high success rates. In a series of 854 free flaps from the MD Anderson Cancer Center, the overall success rate was 96% (Kroll et al. 1996), and a report from the Memorial Sloan-Kettering Cancer Center on reconstruction for oncological defects in 716 free flaps gives an overall success rate of 98%, with an 8% re-exploration rate. Only five flap types were necessary to solve most problems in the extremities. The flap most commonly used in the lower limb was the latissimus dorsi (53%) followed by the rectus abdominis muscle and the fibula. In the upper limb, the fibular flap (52%) was the most common followed by the rectus abdominis muscle and the latissimus dorsi (Hidalgo et al. 1998). The success rate for

free flaps in oncological surgery is similar to that in other free flap applications (Cordeiro et al. 1994).

It is generally agreed that RT interferes with wound healing. A significant increase in skin-graft loss after external beam RT, despite a good initial graft uptake, was detected in an experiment with rats (Tadjalli et al. 1999). Partial or total skin-graft loss after RT has been reported in 10% of oncological patients. It is nevertheless concluded that their use is relatively safe if they are placed on well-vascularised muscle beds (Bui et al. 2004). External beam RT did not affect the survival of free flaps in rats (Virolainen et al. 2002). In a series of 43 patients with free flaps, pedicled flaps and skin grafts, tissue transfers tolerated postoperative external beam RT well, but brachytherapy was followed by an increase in wound complications (Spierer et al. 2003). In a series of 100 fibular free flaps, complication rates in patients receiving external beam RT were no higher than in patients not receiving RT (Choi et al. 2004). A free flap or regional flap permits radiation of the tumour site and can safely be used in oncological surgery when RT is required (Evans et al. 1997, Hidalgo et al. 1998, Lee et al. 2004).

The results for free tissue transfer to a previously irradiated site vary. Prior irradiation makes dissection of recipient vessels more difficult and may interfere with the development of collateral circulation from surrounding tissue to the flap. In a multivariate analysis of 1384 free flaps used for breast and head and neck reconstruction, previous irradiation of the operative field did not affect free flap success (Kroll et al. 1998). It was, however, a significant factor in flap failure in a prospective multivariate analysis of 493 free flaps, with a failure rate of 9% (Khouri et al. 1998). It is therefore advisable to be prudent in irradiated areas and to ensure that only reliable flaps are used.

Reconstructions with free tissue transfers have been shown to have many advantages over direct wound closure. Tumours can be operated on with wider margins (Lohman et al. 2002), and even muscle function can be restored if necessary (Doi et al. 1999). In addition to skin, subcutaneous tissue and fascia, the free flap may contain muscle and vascularised bone tissue. The flap type and its composition are selected to closely suit the anatomy of the defect and to fulfil functional demands. Nowadays, primary amputation is usually only performed if the tumour infiltrates major neurovascular structures; even in some of these cases, it has been recommended that the limb should be salvaged with the aid of vascular reconstructions (Hohenberger et al. 1999). Modern plastic surgical methods, such as the use of muscle and musculocutaneous free flaps and pedicled flaps, allow immediate reconstruction and should be available when needed in STS and other oncological surgery (Reece et al. 1994, Anthony et al. 1993).

2.11 Extensive amputations and specific techniques

Although salvage of the limb is the aim of treatment, amputations cannot always be avoided in STS surgery. If the sacrifice of major nerves or considerable shortening of the lower extremity would lead to poor function, amputation may be a preferable option. Extensive amputations are sometimes required in proximal extremities, and in thoracic and pelvic girdle regions if the tumour infiltrates the neurovascular bundle. These procedures include forequarter amputation, extended forequarter amputation and external hemipelvectomy. Such operations are regarded as among the most mutilating procedures in cancer treatment. The prognosis for patients tends to be poor due to recurrence, large size and high

grade of the tumour. However, in selected patients these procedures may be curative and in others palliative, relieving symptoms such as pain, fetor, bleeding, persistent infection and discharge. In a 40-patient series consisting of all the extensive amputations for STS performed at one institution, the two-year disease-free survival rate was 23% (Clark et al. 2003). In another series of patients who underwent a curative operation, the five-year survival rate after forequarter amputation was 30% (Bhagia et al. 1997). These procedures are infrequent and require considerable expertise in reconstruction.

In procedures such as external hemipelvectomy and extended forequarter amputation, coverage of the defect may require a free flap. Free flaps dissected from the amputated upper extremity (fillet flap) have been used, the advantages being a lack of donor site morbidity (Cordeiro et al. 1998) and the feasibility of reconstructing the shoulder contour (Osanai et al. 2005). In hemipelvectomy, the vascularity of local skin flaps is often compromised by resection, and flap necrosis has been the most common complication reported in 38% of patients (Baliski et al. 2004). The pedicled vertical rectus abdominis myocutaneous (VRAM), tensor fascia latae (TFL) and rectus abdominis muscle flaps (Ross et al. 1998) as well as fillet flaps from the amputated lower extremity have been used to cover large defects caused by hemipelvectomies. Fillet flaps can be raised both as free flaps (Tran et al. 2000) and as pedicled flaps (Butler 2002) with good results.

Certain methods of resection are preferable to amputation in terms of body contour and function. Tikhoff-Linberg humeroscapular resection is superior to forequarter amputation in tumours of the shoulder, proximal humerus and scapula, assuming that the axillary neurovascular pedicle is tumour free

(Voggenreiter et al. 1999). Recently, endoprosthetic scapular reconstruction has shown some promising results in shoulder movement as compared with plain resection (Wodajo et al. 2003). In tumours of the upper arm, segmental amputation of the involved region and re-plantation of the lower arm to the proximal humerus gives better functional results than amputation (Windhager et al. 1995).

In distal amputations specific reconstructions are sometimes needed. In a non-conservatively treatable tumour in the leg, where the excision of soft tissues would not allow bone coverage and would thus lead to above-knee amputation, the amputation level can be made more distal by free flap coverage and / or bone elongation, giving a better functional result. Experience in covering amputation stumps with free flaps has been accumulated mostly through trauma surgery, and some surgeons consider the fillet of foot free flap as a first choice (Kasabian et al. 1995). A classical method used mainly in children to preserve the important function of the knee joint is rotationplasty of the leg, in which a tumour involving the knee joint is resected with the joint, and the ankle joint is rotated 180 degrees and joined to the femur (Van Nes 1950, Fuchs et al. 2004).

2.12 Tumour- and patient-related clinical prognostic factors for local recurrence

In the literature, the prognostic factors for distant metastasis and local recurrence in STS differ (Zagars et al. 2003). Most studies give tumour grade, tumour size and tumour depth related to investing fascia as important factors for distant metastasis (Pisters et al. 1996, Stefanovski et al. 2002, Coindre et al. 1996, LeVay et al. 1993). These factors have also been included in the AJCC staging sys-

tem (American Joint Committee on Cancer 2002). For local recurrence, prognostic factors are, however, less well defined. The most frequently cited significant factors are status of the surgical resection margin and tumour malignancy grade, followed by patient age and locally recurrent presentation. In some of the large series, tumour size, tumour location in compartment, tumour site and tumour depth have also been significant (Table 2).

Prognostic factors can be classified as patient, tumour or treatment related. Patient- and tumour-related factors cannot be altered, and their principal role is to provide information about the severity of the disease so that a treatment strategy can be devised. Treatment-related factors, including surgical margins, can be directly influenced by the treating team and are discussed in the sections "Surgical margins" and "Radiotherapy".

Tumour malignancy grade is the factor that best measures a tumour's biological aggressiveness. A high malignancy grade is generally accepted as a prognostic factor for local recurrence (Table 2). However, reports have been published in which high grade has not been significant for local recurrence (Gibbs et al. 1997, Pisters et al. 1996). A possible explanation is that differences in RT administration and the extent of the surgical margins between low- and high-grade tumours confound multivariate analysis as also the interpretation of histological grades.

A number of studies report advanced age of the patient as a significant factor for local recurrence (Table 2). The largest studies have used cut-off values of 50 and 64 years (Pisters et al. 1996, Zagars et al. 2003). The causal effect of age on local recurrence has not, however, been satisfactorily explained. One suggestion is that, in the detailed analysis of surgical margins in millimetres, elderly patients would not have been operated

on with as wide margins as younger patients, but data on this issue are lacking.

Prior local recurrence of STS is strongly associated with the development of metastases and tumour mortality, and it is a negative prognostic factor (Lewis et al. 1997). Prior local recurrence is also a prognostic factor for subsequent local recurrence. This issue is discussed in detail in the section "Surgery for locally recurrent disease".

The impact of tumour size on local recurrence was documented as a significant prognostic factor in one of the largest series published, that of Zagars et al., in which the cut-off size was 10 cm (Table 2). However, many large studies conclude that tumour size does not affect local recurrence (Table 2). This may be explained by the association of size with the surgical margins achieved, regarded by multivariate analysis. Thus, for local control, the importance of tumour size is mainly treatment related, and is emphasised in the head and neck region where the extent of resection is more limited.

The depth of the tumour and its association with anatomical structures that resist tumour spread is of paramount importance to the surgeon, especially when RT is not delivered. A system for the surgical staging of musculoskeletal sarcoma based on tumour malignancy grade and the concept of the surgical compartment was described in 1980 (Enneking et al. 1980). Although this system has been replaced by newer ones with better survival predictability (Wunder et al. 2000), it still forms the basis for the designation of surgical treatment. However, the depth of the tumour and its location in the compartment are no longer considered so important due to the more liberal use of RT. The majority of multivariate analyses give no data on tumour depth or compartment, and these factors are often ei-

ther analysed together with factors such as tumour site or are defined differently, thus preventing objective comparison (Table 2).

The concept of tumour location from the surgeon's point of view has been refined still further. By definition, a subcutaneous tumour is located in subcutaneous tissue with the deep fascia unopened and without tumour invasion; an intramuscular tumour is located inside a muscle, with no involvement of muscle fascia and has not been subjected to prior surgery; an extramuscular tumour grows through or into the deep fascia, or is deep-seated and grows partly or totally outside muscles (Rydholm et al. 1991). Subcutaneous tumours recur locally in 5-7.5% of patients (Gibbs et al. 1997, Rydholm et al. 1991). Intramuscular tumours treated with myectomy alone have recurred locally in 6% of patients (Rydholm et al. 1986). Extramuscular tumours have been shown to have the worst prognosis in terms of survival and local recurrence (Gibbs et al. 1997, Rydholm et al. 1991).

Patients with STS in the extremities have a better prognosis than those with STS in the deep trunk (Zagars et al. 2003, Dinges et al. 1994). Retroperitoneal sarcomas are not usually analysed with STS of the extremities or trunk owing to their anatomic peculiarity, lack of surgical boundaries and asymptomatic growth of huge masses. A local recurrence rate of 88% has been reported in retroperitoneal STS (Gronchi et al. 2004). Head and neck sarcomas recur locally in 41% of patients. These sarcomas thus have poorer local control than STS of the extremities (Bentz et al. 2004).

In large series, the histopathological subtypes MPNST and fibrosarcoma (Pisters et al. 1996), and MPNST, MFH and epithelioid sarcoma (Zagars et al. 2003) have been more likely to recur locally.

Table 2. Prognostic factors for local recurrence by multivariate analysis in large series

Author	Years	Institution	n	Grade	Size	Comp	LR	SM	D	Age	Site
Zagars et al.	1960-2003	M.D. Anderson Hospital, Houston	1225	0.003	>10 cm	nd	<0.001	<0.001	nd	>64	<0.001
Pisters et al.	1982-1996	Memorial Sloan-Kettering Cancer Center, NY	1041	n.s.	n.s.	nd	<0.001	<0.001	n.s.	> 50	n.s.
Trovik et al.	1986-2000	Scandinavian Sarcoma Group	559	0.002	n.s.	nd	nd	<0.001	nd	n.s.	n.s.
Coindre et al.	1980-1996	French Federation of Cancer Centers	546	<0.001	n.s.	nd	nd	<0.001*	0.01	n.s.	nd
Stefanovski et al.	1985-2002	Centro di Riferimento Oncologico, Aviano	395	0.04	n.s.	nd	nd	<0.01	nd	n.s.	n.s.
Vraa et al.	1979-1998	University Hospital of Aarhus	316	0.01	n.s.	<0.001	nd	0.03	n.s.	0.004	n.s.

Comp = compartment, LR = local recurrence, SM = surgical margins, D = depth
 decimals are p-values, n.s. = non-significant, nd = no data

* local excision vs more extensive operation

** head and neck or deep trunk

2.13 Outcome

There are numerous reasons why it is difficult to make an objective comparison of treatment results between centres. First, STS is a relatively rare disease and thus patient series are collected over long periods of time that may include several treatment strategies. Second, there is a large number of histological subtypes. Third, different centres use different classification and grading systems. Fourth, STS can be located in almost any site of the body and, moreover, within the site, tumour location varies from intra- to extracompartmental. All these factors affect the severity of the disease. At the moment, there is no standardised practice of reporting the characteristics of patients and, what is more, the inclusion criteria for the series differ.

The definitive surgical procedure is the single most important therapeutic manoeuvre for the outcome of a STS patient. However, systems for evaluating surgical margins vary. To compare the effectiveness of nonsurgical treatment, both the stage and the surgical procedure must be identical (Enneking et al.

2003). For example, it is not appropriate to compare the effectiveness of RT for a deep extracompartmental high-grade tumour treated with intralesional operation with the effectiveness of RT for a superficial intracompartmental high-grade tumour treated with wide excision. Finally, the indications for adjuvant RT and chemotherapy differ from one centre to another.

The oncological outcome measures commonly used are local recurrence-free survival (LRFS), disease free-survival (DFS), metastasis free-survival (MFS), disease-specific overall survival (DSOS) and overall survival (OS). All these measures can be reported as actual events or estimated by the Kaplan-Meier method. In STS, a commonly used cut-off point is five years. The uniform factors measuring limb salvage are amputation or limb salvage rates. Amputation rate and LRFS together give a relatively good impression of the quality of treatment from the surgeon's point of view.

Amputation rates from the 1950s to 1970s were 37–50%, with local recurrences of 9–31% (Table 3, Shiu et al. 1975, Enneking et al. 1981, Abbas et al.

1981, Rosenberg et al. 1982). The frequent adoption of RT in the 1980s brought amputation rates down to 6–30%, usually to less than 15%, with local recurrences of 6–23% (Table 3, Karakousis et al. 1991, Rydholm et al. 1991, Pisters et al. 1996, Vraa et al. 1998, Trovik et al. 2001, Lohman et al. 2002). These results imply that limb-salvage treatment, when adequately performed, is as safe as amputation in terms of local control. However, there have been no major

changes in MFS or OS for many years (Table 3). This situation is attributed to the fact that the type of local treatment, provided that it is performed adequately (whether by conservative surgery with RT or amputation), is incapable of affecting the systemic dissemination of STS. A MFS rate of 78% and DSOS rate of 81% at five years were reported in one of the largest series published (Pisters et al. 1996).

Table 3. Results of treatment in 15 studies of soft tissue sarcoma of the extremities

Author	Institution	no.	yr	LOC	Grade	RT	AMP	LR	DFS	MFS	DSOS	Loc rec incl
Shiu et al. 1975	Memorial Sloan-Kettering Cancer Center, NY	297	1949-1968	lower extr	high and low	no	47	18	40 ^{^^}	74 ^{^^}	55 [^]	yes
Enneking et al. 1981	University of Florida	40	1963-1978	thigh	31 high, 9 low	no	50	15	58	60	60	yes
Lindberg et al. 1981	M.D. Anderson Hospital, Houston	200	1963-1977	extr	high and low	yes	15	20	56	75	54 [^]	nd
Abbas et al. 1981	Roswell Park Memorial Institute, Buffalo	117	1965-1975	extr	majority high	yes	38	31	nd	nd	50 [^]	yes
Rosenberg et al. 1982	National Cancer Institute, Bethesda	43	1975-1981	extr	35 high, 8 low	yes	37	9	79	88	88	nd
Suit et al. 1988	Harvard Medical School, Boston	180	1971-1985	extr	high and low	yes	3	13	70	nd	nd	nd
Karakousis et al. 1991	Roswell Park Memorial Institute, Buffalo	144	1977-1986	extr	high and low	yes	6	6	61	nd	71	yes
Rydholm et al. 1991	University Hospital, Lund, Sweden	119	1980-1986	extr	101 high, 18 low	yes	10	11	nd	nd	82	no
Coindre et al. 1996	French Federation of Cancer Centers	331	1980-1989	extr	majority high	yes	4	29	nd	60	69 [^]	no
Pisters et al. 1996	Memorial Sloan-Kettering Cancer Center, NY	1041	1982-1994	extr	678 high, 363 low	yes	13	17	68	78	81	yes
Gibbs et al. 1997	University of Chicago	62	1975-1993	extr*	46 high, 16 low	yes	6	5	81	nd	87	yes
Vraa et al. 1998	University Hospital of Aarhus, Denmark	222	1979-1993	extr	high and low	yes	30	21	nd	nd	74	yes
Trovik et al. 2001	SSG register, Scandinavia	459	1986-1993	extr	high	yes	15	23	46	56	nd	no
Choong et al. 2001	St Vincent's Hospital, Melbourne	132	1980-1995	extr	low	yes	nd	8	nd	95	92	no
Lohman et al. 2002	M.D. Anderson Hospital, Houston	100	1992-1997	upper extr	70 high, 30 low	yes	13	13	nd	nd	82	yes

yr = years, LOC = location, RT = radiotherapy, AMP = amputation %, LR = local recurrence %
 DFS = disease-free survival % at five years, MFS = metastasis-free survival % at five years
 DSOS = disease-specific overall survival %

* all subcutaneous ^ not disease-specific overall survival ^^ during total follow-up

3. Chest wall reconstruction

3.1 Tumours of the chest wall

A tumour of the chest wall can originate primarily within the chest wall, develop as a local recurrence from a previously excised chest wall lesion, present as metastatic disease from a distant site or manifest itself as a primary tumour from intrathoracic organs infiltrating the chest wall. Primary chest wall tumours account for about 5% of thoracic neoplasms and for 1–2% of all primary tumours (Perry et al. 1990). In sarcomas, the chest wall accounts for 6–7% of the total (Walsh et al. 2001). Approximately 45% of primary malignant tumours of the chest wall arise from soft tissue sarcomas and 55% appear in cartilaginous or bony tissue (Incarbone et al. 2001). The most frequent diagnosis is sarcoma, and less frequently plasmacytoma or lymphoma. Chondrosarcoma is the most common primary bone chest wall sarco-

ma (Figure 3). The chest wall is also a site of radiation-induced sarcomas (Wiklund et al. 1991, Chapelier et al. 1997). Breast cancer recurrence as a tumour in the chest wall is common. With modern treatment local recurrences occur in 5–22 % of the breast cancer patients (Huston et al. 2005). In bronchogenic carcinoma, direct chest wall invasion occurs in 5–8% of patients (Facciolo et al. 2001). Extensive full-thickness chest wall resections are most frequently performed in patients with primary sarcomas or local recurrence of breast cancer (Incarbone et al. 2001, Vandeweyer et al. 2002).

3.2 Methods for chest wall reconstruction

The goal of chest wall reconstruction is stability, water- and air-tight closure, and an acceptable cosmetic appearance. Soft tissue coverage can be attained in various ways. Small defects can be closed directly

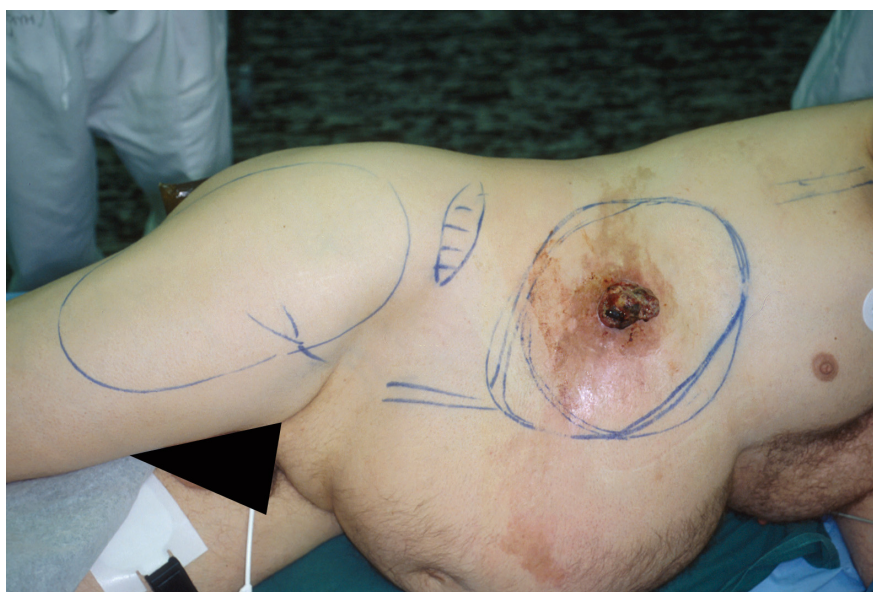


Figure 3. Patient with chondrosarcoma in the chest wall.

but larger defects are reconstructed with flaps. In the early days of reconstruction, local skin flaps were used and, of these, the contralateral breast flap is still in use today (Wysocki et al. 2004), although it is not preferred by plastic surgeons. The pedicled latissimus dorsi muscle was introduced for chest wall reconstruction in 1950 (Campbell 1950) and, together with its modifications, has been in regular use ever since. The pedicled omental transposition flap has also been used with success for reconstruction, especially for infected sternotomy wounds (Hultman et al. 2002).

The regional pedicled muscular or musculocutaneous flap has been the first choice for soft tissue coverage of a chest wall defect, and flaps such as the latissimus dorsi, vertical rectus abdominis (VRAM), transverse rectus abdominis (TRAM), and pectoralis, serratus and external oblique muscles have commonly been employed (Arnold et al. 1996, Mansour et al. 2002, Mathes et al. 1995, Samuels et al. 1993). Multiple local or pedicled flaps have also been applied to cover extensive defects (Chang et al. 2004). The choice of flap depends on the location of the tumour, the size of the defect, and the availability of autogenous graft material. However, a pedicled flap cannot be used in all patients for several reasons. Local options may already have been used, the pedicle or flap may have been damaged by previous operations or RT, or the flap may be of inadequate size to cover the defect. Harvesting a flap on the abdominal or chest wall area may also cause additional impairment in breathing. The larger the defect, the greater the need for microsurgical techniques. In a large, 200-patient series with chest wall resection, the frequency of free flap reconstructions was 9% (Mansour et al. 2002). In a series of 20 free flaps for full-thickness chest wall reconstruction, myocutaneous rectus abdominis flaps and fillet extremity free flaps were used

(Cordeiro et al. 2001). Other free flaps employed for chest wall reconstruction include the latissimus dorsi and omentum (Al-Kattan et al. 1995, Losken et al. 2004, Chang et al. 2004).

Full-thickness chest wall resection causes a defect in which pleural cavity is open and the vital intrathoracic organs are exposed. Bony stability has to be restored in wide defects to avoid paradoxical respiratory movement and, hence, impaired respiratory function, without limiting normal breathing. It has been found that defects larger than 5 cm need stabilisation of the bony chest wall (McCormack 1989). This has been achieved in various ways, for example, with autologous free fascial grafts (Watson et al. 1947) and rib grafts (Bisgard et al. 1948), which long constituted the basis for reconstruction. Strips and plates of metal, stainless steel, tantalum and fibreglass have also been used, though today synthetic materials are preferred. Marlex® mesh was documented as relatively safe in a retrospective series of 101 patients with full-thickness chest wall resection; in 40 of the patients stability was achieved with, and in 61 of them without, Marlex mesh. Infection developed in 5% of the Marlex group patients, but the mesh did not need to be removed. The length of ventilatory support was shorter in the Marlex group (Kroll et al. 1993). Other synthetic materials commonly used are Vicryl® mesh, Prolene® mesh, polytetrafluoroethylene (PTFE) patch (Gore-Tex®), and “shield” or “sandwich” prostheses (methyl methacrylate sandwiched between two sheets of prolene mesh), or their combinations (Nash et al. 1991, Shiba et al. 1988, Anderson et al. 1994, Sabanathan et al. 1997). The “shield” prosthesis offers good stability, but complications due to loosening and displacement of the prosthesis have been documented (Jönsson et al. 1998). A type of graft recently described is the iliac bone allograft, which has the advantage that it integrates with

the host patient's living tissue (Cara et al. 1993, Garcia-Tutor et al. 2004). However, agreement about the method of reconstruction is lacking and decisions are mainly based on the surgeon's preference.

The pedicled tensor fasciae latae (TFL) musculocutaneous flap has been used for lower abdominal wall reconstruction since its description in 1934 (Wagensteen 1934). Although use of this flap is limited by the arch of rotation to the infraumbilical region, its application as a myocutaneous free flap (Hill et al. 1978) has made reconstructions of the supraumbilical region possible (O'Hare et al. 1983, Cafee et al. 1983, Williams et al. 1997). Recently, its use was described in full-thickness chest wall defects in a series of seven patients (Heitmann et al. 2000). To our knowledge, there are no reports from larger series about chest wall reconstruction with the TFL free flap, which can be very large and yet its harvesting does not affect the patient's respiratory function.

3.3 Survival of patients and results of surgery after chest wall resection

Previous studies have shown that chest wall resection is seldom curative in patients with breast cancer recurrence in the chest wall. Long-term survival may be poor in such patients, yet the operation may offer them remarkable palliation, since they may suffer intense local pain, bleeding and discharge, infection, fetor, continuing tumour growth, oedema or paralysis of the upper extremity due to the compression of motor nerves. Such patients may be candidates for palliative resection and reconstruction. In one series of 38 patients with breast cancer recurrence who underwent full-thickness chest wall resection and, in most cases, reconstruction with a pedicled flap, the overall survival rate was

18% at five years (Downey et al. 2000); in another series of 13 similar patients it was 31% (Nash et al. 1991). In a series of 98 patients with less complex breast cancer recurrence who underwent mainly soft tissue resection, the overall survival rate was 56% at five years (Dahlstrom et al. 1993). In a series of 15 patients with breast cancer recurrence treated mainly with soft tissue resection and reconstruction with pedicled flaps, the survival rate was 13% even though the post-operative margins were tumour free (Vandeweyer et al. 2002). A disease-free interval longer than two years after primary therapy for breast cancer results in significantly longer survival after radical treatment of chest wall recurrence (Faneyte et al. 1997).

Patients with sarcoma in the chest wall have a better prognosis and for them surgery may be curative. In a series of 51 patients with localised sarcoma in the thoracic wall who underwent full-thickness resection, the survival rate was 64% at five years. In the treatment of chest wall sarcomas, wide margins remain the most important surgical objective, and the extent of resection should never be compromised because of concern about closing the defect (Walsh et al. 2001). This has also been documented in a series of 28 patients with primary, locally recurrent and metastatic sarcomas with 59% survival (Perry et al. 1990). In a series of 15 patients with postirradiation sarcoma who underwent bony chest wall resection, survival was 48% at five years (Chapelier et al. 1997). In chondrosarcomas, survival was 64% but in osteosarcomas only 15% (Burt et al. 1992).

In a recent series of chest wall resections, perioperative mortality was 0–17% (Cordeiro et al. 2001, Arnold et al. 1996, Mansour et al. 2002, Al-Kattan et al. 1995, Cohen et al. 1996). From most reports, it would seem that chest wall resection is a relatively safe procedure.

4. Surgery in dermatofibrosarcoma

Traditionally, the recommended treatment for dermatofibrosarcoma has been wide surgical excision with gross margins of at least 3 cm (McPeak et al. 1967, Rutgers et al. 1992, Bendix-Hansen et al. 1983, Roses et al. 1986). In a literature review comprising 913 cases of dermatofibrosarcoma, local recurrences were reported in 32–76% (mean 52%) of patients after an operation with undefined surgical margins; after wide excision, local recurrences occurred in 0–60% (mean 13%) of the patients (Rutgers et al. 1992).

During the last 10 years, more information about the microscopic tumour-free margins has been gathered through reports about micrographic surgery (Ah-Weng et al. 2002, Gloster et al. 1996, Ratner et al. 1997, Haycox et al. 1997), originally developed by Dr Frederick Mohs at the University of Wisconsin. In Mohs surgery excision is guided by frozen sections in order to minimise tissue defects and to remove the tumour completely. At some centres, Mohs micrographic surgery has been the treatment of choice for DFSP. According to a review of 169 patients with a relatively short follow-up time, the average recurrence rate in patients treated with Mohs surgery was 2.4% (Haycox et al. 1997); in another recent review, of 136 patients with a follow-up time of more than five years, the recurrence rate was 6.6% (Snow et al. 2004). In comparison, excellent results with no recurrences were reported in a large, retrospective series of 117 patients treated with 5-cm-wide excision margins with a mean follow-up time of more than 5 years (Arnaud et al. 1997). Traditional

excisional surgery is still the preferred procedure, but excellent results can also be achieved with a selective combination of excisional and micrographic surgery (DuBay et al. 2004).

On certain occasions, albeit infrequently, adequate surgical margins cannot be obtained by conservative surgery. RT may be beneficial in patients with intralesional margins (Haas et al. 1997, Lindner et al. 1999, Ballo et al. 1998), but its definitive role still remains unclear due to the lack of randomised trials. DFSP is characterised by chromosomal rearrangements resulting in the production of PDGF (Simon et al. 1997). A new, molecularly targeted drug, the selective tyrosine-kinase inhibitor imatinib (Glivec®), functions as an inhibitor of PDGF receptors, thus blocking this autocrine stimulation. Recent case reports document promising results in the treatment of advanced DFSP with imatinib (Maki et al. 2002, Rubin et al. 2002, Price et al. 2004).

Reports on the use of wide excisions have mainly concentrated on gross surgical tumour-free margins (Roses et al. 1986, Arnaud et al. 1997) or, histologically, on the presence of tumour tissue in the cut surfaces (Bowne et al. 2000). However, owing to the extremely infiltrative growth pattern of DFSP, it is felt that terms such as a “microscopically positive” or “negative” margin are not sufficiently accurate to verify the radicality of the operation. Detailed information about a histological tumour-free margin, measured in millimetres, and about its effect on the local recurrence rate, is needed in order to set recommendations for treatment with excisional surgery.

AIMS OF THE STUDY

Studies I and III: to evaluate the justification for limb-saving multidisciplinary treatment of extremity soft tissue sarcomas (STS) and to report the results achieved by the treatment protocol of Soft Tissue Sarcoma Group at Helsinki University Central Hospital.

Study II: to compare genetic aberrations in primary soft tissue sarcomas and their local recurrences and to evaluate the genetic changes occurring during local tumour progression.

Study IV: to evaluate the suitability of microvascular flaps, especially TFL, for the reconstruction of extensive full-thickness defects of the chest wall caused by excision of malignancies.

Study V: to report the results of 40 patients with dermatofibrosarcoma treated by surgical excision, with special reference to gross and histological margins.

MATERIALS AND METHODS

1. Clinical material in soft tissue sarcomas of the extremities (Studies I and III)

The patient series in Studies I and III consist of patients treated by the Multimodality Soft Tissue Sarcoma Group of Helsinki University Central Hospital (HUCH) according to the group's protocol. The main guidelines for treatment comply with those recommended by the SSG. Data on patients were prospectively recorded and retrospectively collected in the STS registry of HUCH for research purposes.

In Study I, 130 patients with STS located in the lower limb were referred to the sarcoma group between August 1987 and November 1994. For survival analysis, we included patients with local disease who were operated on with curative intention. Excluded were three dermatofibrosarcomas, four atypical lipomas, one Kaposi sarcoma, 14 patients with haematogenous metastases and two patients with lymph node metastases. The number of patients thus remaining for survival analysis was 106 (Table 4). Tumour size was recorded as the longest diameter, with a median size of 7.0 cm (range, 0.5 to 35.0 cm). There were 77 (73%) high-grade and 28 (26%) low-grade tumours; in one tumour the grade was unclassified. The most common histological types were MFH, leiomyosarcoma, liposarcoma and synovial sarcoma. Eighty-seven patients were referred for primary tumour and 19 for local recurrence. The referral status of primary tumours before surgery was: virgin, fine-needle, core-needle or incisional biopsy in 41 and curatively intended excision in 46 patients. Of the patients referred for local recurrence, the number of local recurrences before referral was: one in 14, two in three and three in two patients.

In Study III, 95 patients with a soft tissue sarcoma located in the upper extremity were referred to the sarcoma group between August 1987 and August 1999. Excluded from the survival analysis were seven dermatofibrosarcomas, six patients with haematogenous metastases, one extraskeletal Ewing sarcoma that was not operated on, and one patient who refused any treatment. Eighty patients were operated on with curative intention (Table 4). Tumour size ranged from 0.5 to 22.0 cm, with a median size of 5.0 cm. There were 67 (84%) high-grade and 13 (16%) low-grade tumours. The most common histological types were MFH, synovial sarcoma, leiomyosarcoma, liposarcoma, fibrosarcoma and epitheloid sarcoma. Sixty-five patients were referred for primary tumour and 15 for local recurrence. The referral status of primary tumours before the operation was: virgin, fine-needle, core-needle or incisional biopsy in 41 and curatively intended excision in 24 patients. Of the patients referred for local recurrence, the number of local recurrences before referral was: one in five patients, two in five, three in one, five in one and eight in one patient.

1.1 Treatment guidelines

The diagnosis was confirmed by cytological and histological needle biopsies. Tumour malignancy was graded on a four-point scale, and any former histological samples that may have been related to the tumour were re-examined. Surgical history was evaluated in detail. Preoperatively, CT, MRI and/or ultrasound scan were performed on the tumour area. All patients had a chest x-ray, and a chest CT scan was a routine procedure for patients with high-grade tumours. The extent of

the operation was then planned on the basis of the data thus acquired.

The excised tissue was sent immediately without preservation to the pathologist, who examined the postoperative surgical margins. These were defined as compartmental when an intracompartmental tumour was resected *en bloc* with the involved muscle compartment. For intramuscular tumours, myectomy was considered as radical as compartmental surgery. Postoperative margins were con-

sidered wide when the thickness of normal tissue separating the tumour from the excision margin was at least 2.5 cm histologically. If the thickness was less, the margin was considered marginal. The excision was also considered wide if the distance was less than 2.5 cm but an intact anatomical barrier (intercompartmental, deep or muscle fascia) separated the tumour from the excision margin (Figure 4). If the tumour was cut through, visible tumour tissue was left

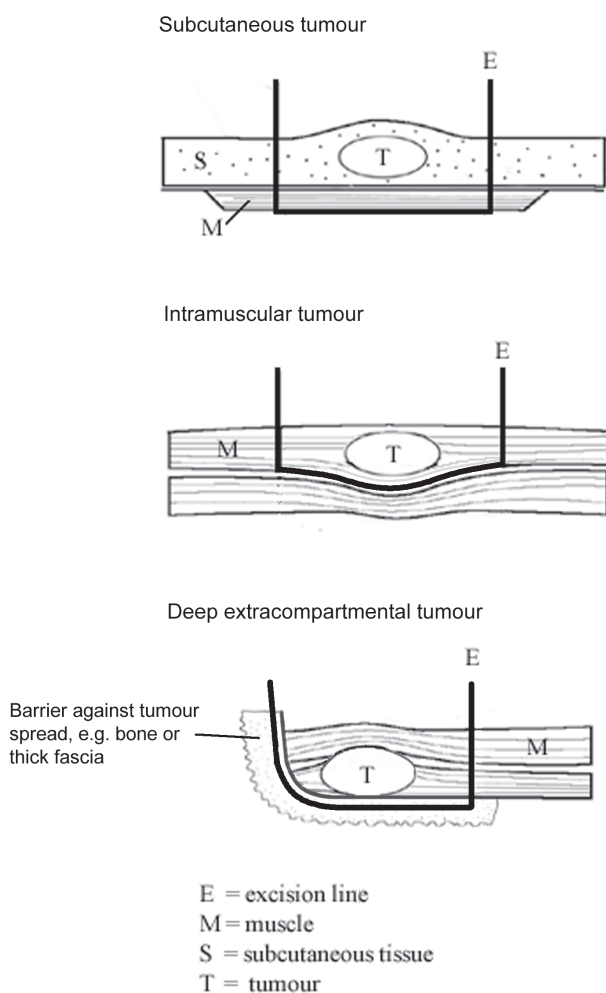


Figure 4. Resection of tumours according to compartment

on the operation area or histological tumour-free margins were not achieved, the margin was considered intralesional.

The aim of the surgery was to achieve wide or compartmental excision margins with preservation of the limb and its function. In the event of marginal resection margins, post-operative RT was recommended (Figure 5). A few patients were given preoperative RT for tumours judged to be inoperable. Excision of the tumour often led to extensive tissue defects. Exposure or defects of bone, major joints or tendons and also large cavities were managed with reconstructive surgery. The limb was amputated only if

there was extensive infiltration of a major nerve, bone or joint by the tumour, and not even marginal resection was feasible. In these cases, a great risk of local recurrence or of poor limb function favoured amputation. For intralesional margins, re-operation was performed when feasible.

Adequate treatment was defined as wide / compartmental surgery alone or marginal surgery combined with post-operative RT. Chemotherapy was not routinely used except for extraskeletal Ewing sarcomas or metastatic disease. Pulmonary metastases, as also local recurrences, were operated on when feasible.

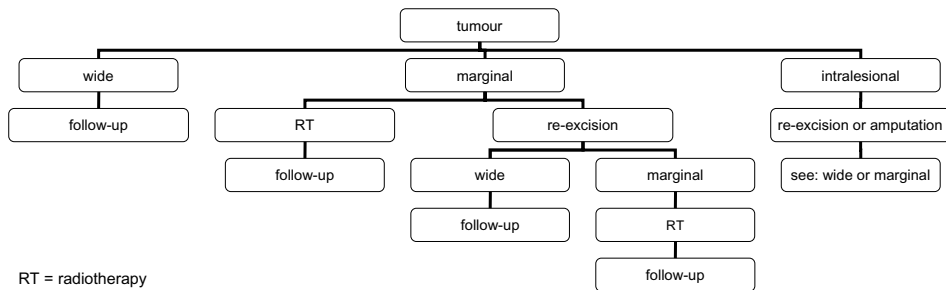


Figure 5. Treatment algorithm for soft tissue sarcomas at Helsinki University Central Hospital. Excluded from this protocol are dermatofibrosarcomas, Kaposi and visceral sarcomas

2. Comparative genomic hybridisation (Study II)

The study used paired samples of primary tumours and their local recurrences for CGH analyses. The material consisted of 20 samples of primary tumours and 20 samples of local recurrences from 20 patients with STS whose primary tumour and its corresponding, subsequent local recurrence were studied by CGH. The patients were selected from the registry of the Soft Tissue Sarcoma Group at HUCH. The inclusion criteria were a disease-free period exceeding four months

from the operation of the primary tumour to the detection of the local recurrence, and excision of all macroscopic tumour mass in the first operation. The exclusion criteria were delivery of any chemotherapy and/or RT for the primary tumour, and preoperative chemotherapy and/or RT for the local recurrence.

The most representative block of tumour tissue was chosen for CGH analysis by light-microscopic examination.

DNA was isolated by standard methods (Miller et al. 1988, Sambrook et al. 1989). CGH was performed as described earlier (Larramendy et al. 1997, El-Rifai

et al. 1997). Chromosomal regions were interpreted as overrepresented when the ratio of tumour DNA to normal DNA was higher than 1.17 (gains) and underrepresented when the ratio was lower than 0.85 (losses). These limits were based on our earlier findings and on control experiments: each experiment included a negative control (two differentially labelled normal human DNAs) and a positive control (a tumour sample with known DNA sequence copy number changes). Gains exceeding the 1.5 limit were termed high-level amplifications (Knuutila et al. 1998).

3. Resections and reconstructions of the chest wall (Study IV)

The series consisted of 26 patients who underwent full-thickness chest wall resection and reconstruction with a free flap at the Department of Plastic Surgery, Helsinki University Central Hospital, between 1988 and 2001. These patients require one of the most complicated treatments and have the poorest prognosis of all patients with soft tissue tumours.

The indication for operation was a tumour that required extensive soft tissue reconstruction after excision in a situation in which use of a conventional pedicular flap was not feasible. The disease requiring reconstruction was a STS in eight patients, chondrosarcoma in five, breast cancer recurrence in eight, desmoid tumour in two, carcinoma metastases in two and bronchopleural fistula in one patient. Sixteen patients were operated on with curative intention and 10 palliatively to relieve serious local symptoms. Chest wall resection and soft tissue reconstruction with a free flap were performed in the same operation. When necessary, the chest wall was stabilised with free rib grafts or synthetic mesh. Usually one or two ribs (e.g. ribs

number 6 and 8, or 5 and 7) from the affected side were harvested for grafts. The rib grafts, which were fixed to the bony chest wall with cerclage wires, were placed such that the bony defect was divided into smaller areas and the convex shape of the chest was maintained. Polypropylene mesh was used for stabilisation either separately or in conjunction with rib grafts. The mesh was always sutured both to rib grafts and to the chest wall.

To reduce the operating time, harvesting of the flap and resection (including preparation of the recipient vessels) were performed simultaneously. Once adequate recipient vessels had been found, the vascular supply to the flap was divided. Microvascular anastomoses were established in major vessels in axillary, subclavial, sternal, cervical, or inguinal areas either end-to-end or end-to-side. The anastomoses were performed under magnifying operation glasses with 7-0 or 8-0 sutures. In cases in which the pedicle did not reach the recipient vessels, a great saphenous vein loop (Freedman et al. 1989) was used to provide the artery and vein for the TFL free flap. The vessels were flushed frequently with heparin-Ringer's sterile solution.

Anticoagulation medication during and after the operation consisted of low molecular heparin 2500 IU administered subcutaneously twice a day. The medication was started on the first preoperative day and was discontinued when the patient was ambulatory, usually 7-12 days after the operation. Oral anticoagulation medication was not given.

4. Dermatofibrosarcomas (Study V)

Forty patients with DFSP were referred to the Soft Tissue Sarcoma Group between August 1987 and February 2001. Among patients with STS, the surgical treatment of these patients is non-com-

plicated and their prognosis is good. Radiological (excluding chest CT) and other examinations as described in Studies I and III were conducted before the operation. The excision, which was made *en bloc*, was usually planned with 3-cm macroscopic margins in the skin, subcutaneous tissue or muscle. In patients in whom the tumour was located in the skin only, and abundant margins of subcutaneous tissue were likely to be achieved, the deep fascia was not violated. If the tumour extension in depth was uncertain, especially in local recurrences, the deep fascia was excised together with underlying muscle. Postoperative surgical margins were defined as wide, marginal or intralesional (as described in Studies I and III). The aim of the surgery was wide excision. In patients in whom wide margins would have called for sacrifice of vital neurovascular structures, the margins were left as marginal and the increased risk of local recurrence was accepted. All wounds were closed primarily, and the soft tissue defects were reconstructed with skin grafts or with local, pedicled or microvascular flaps when necessary. Oncological treatment such as RT or chemotherapy was not used.

During the operation, the excised specimen was marked at all cut surfaces with sutures. Frozen sections were obtained in the event of suspicious margins. At the Department of Pathology all margins of the formalin-fixed specimens were marked with ink or other stains before taking an ample number of samples for histological examination. Depending on the size of the specimen, the number might be anything up to 20. Several parallel samples were taken from sites where the tumour seemed to be closest to the margin macroscopically. The tumour-free margins were measured from histological slides, in recent cases with a computerised system (Pathfinder, CompuCyte Corporation, MA, USA). If the microscopic mar-

gin was less than 1.5 cm, re-operation was performed when feasible.

All 40 patients with DFSP were operated on. Two of the tumours had fibrosarcomatous changes. The tumour size, which was recorded as the longest diameter, ranged from 1.0 to 9.5 cm, with a median size of 2.7 cm. Twenty-seven patients were referred for primary and 13 for locally recurrent tumour. Of the patients with primary tumours, 20 were referred after marginal excision, six after incisional biopsy and one virginally. Of those with local recurrences, two were referred for the first, 10 for the second and one for the third recurrence. None of the patients presented with distant metastases.

5. Statistical analysis (Studies I–V)

Disease-specific overall survival (DSOS), local recurrence-free survival (LRFS), metastasis-free survival (MFS) and disease-free survival (DFS) rates were calculated according to the method of Kaplan and Meier (Studies I, III, IV and V). A death occurring for reasons other than sarcoma was considered as lost to follow-up. Univariate analysis for clinical prognostic factors was performed by the Cox regression model. Variables found to be significant in univariate analysis were introduced into the multivariate model. The multivariate analysis was performed by the Cox proportional hazard method (Studies I and III). Outcome measures refer to five-year survival. A p-value less than 0.05 was considered statistically significant. All p-values refer to overall outcomes and not to specific points in time. The difference in copy number aberrations between primary tumours and local recurrences was calculated and statistically analysed by a paired t-test (Study II).

RESULTS

1. Sarcomas of the extremities (Studies I and III), Reconstructions of the chest wall (Study IV) and Dermatofibrosarcomas (Study V)

1.1 Procedures performed

The total number of patients treated in the clinical studies (Studies I and III-V) was 252. Of these, 106 presented with STS in the lower limb, 80 with STS in the upper limb, 26 with chest wall resection due to various malignancies and 40 with dermatofibrosarcomas (Table 4). Excluding those with desmoid tumours and dermatofibrosarcomas, the number of STS patients was 194. The operation was excision and direct closure in 99 patients (39%, Table 5). Twenty-five major amputations were performed as follows: two forearm, five humeral, two humeral exarticulations, one forequarter, five extended forequarter, one hemipelvectomy, two femoral, three femoral exarticulations, three below-knee and one distal foot. In extremity sarcomas, the amputation frequency was 10% (lower limbs 9%, upper limbs 12.5%) and in thoracic wall tumours 19%; there were no amputations in dermatofibrosarcoma patients. Limb salvage was possible in 90% of all patients.

Free flap reconstructions were required in all extended forequarter amputations and hemipelvectomies ($n=6$). When direct closures and amputations without reconstructions were excluded, reconstructions were needed in 137 patients (53%). Reconstructive procedures were required in the lower limbs in 45%, in the upper limbs in 48%, in full-thickness chest wall resections in 100% and in DFSPs in 58% of the patients. There were 56 microvascular flaps, 28 pedicled

flaps, 17 skin flaps, 42 split-thickness skin grafts, one forearm replantation and two humeroscapular resections according to Tikhoff and Linberg (Sugarbaker et al. 1992, Table 5). The most common free flap was TFL ($n=22$) followed by latissimus dorsi muscle ($n=20$). The success rate for microvascular flaps was 96.4%.

In the study on chest wall resections (Study IV) there were eight sternal, five lateral, and eight thoraco-abdominal full-thickness resections of the chest wall; in addition, five patients underwent extended forequarter amputation with resection of the ribs. The average number of ribs resected was 3.9, the mean area of soft tissue resection 503 cm² and the mean diameter of resection 28 cm. The chest was stabilised with synthetic mesh in eight patients and with free rib grafts in nine patients. For reconstructions of soft tissue, see Table 5. In seven thoraco-abdominal resections, the TFL flap had to be placed so proximally that the pedicle vessels could not reach the inguinal area and a great saphenous vein loop was used. There was no perioperative mortality or flap losses. The average operation time was seven hours (range 3 1/2–10 hours) and perioperative blood loss 3800 ml (range 700–7000 ml). The median treatment period in the intensive care unit was six days (range 0–35 days) and in the surgical ward 20 days (range 10–39 days). Four patients required a tracheostomy due to prolonged ventilatory support, and five patients required revision of the microvascular anastomosis. Six patients had to be operated on due to healing problems in the resection or the flap donor site. In one patient, a postoperative hernia was repaired. One patient needed a free rib graft owing to paradoxal movement of the chest wall that caused severe ventilatory dysfunction. There were no chronic

Table 4. Patient and tumour characteristics

Study no.	I	III	IV	V	All	%
Gender						
Female	64	36	15	18	133	53
Male	42	44	11	22	119	47
Age						
Median	55	57	61	45		
Range	18-91	20-84	23-77	22-77		
Histology						
MFH	33	30	2		65	25.8
Dermatofibrosarcoma				40	40	15.9
Leiomyosarcoma	23	7	1		31	12.3
Synovial sarcoma	10	14			24	9.5
Liposarcoma	16	6			22	8.7
Sarcoma NOS	9	5	3		17	6.7
Fibrosarcoma	2	6			8	3.2
Breast cancer recurrence			8		8	3.2
Malignant schwannoma	4	1			5	2
Epithelioid sarcoma		5			5	2
Chondrosarcoma			5		5	2
Extraskelatal sarcoma Ewing	4				4	1.6
Malignant hemangiopericytoma	3		1		4	1.6
Other			3		3	1.2
Extraskelatal chondrosarcoma	2				2	0.7
Clear cell sarcoma		2			2	0.7
Desmoid tumor			2		2	0.7
Extraskelatal osteosarcoma		1			1	0.4
Myxofibrosarcoma		1			1	0.4
Angiosarcoma			1		1	0.4
Lymphangiosarcoma		1			1	0.4
Alveolar soft-part sarcoma		1			1	0.4
Grade						
High	77	67	9		153	63
Low	28	13	6	40	87	36
Unclassified	1				1	1
Site						
Lower limb	106			8	114	45
Upper limb		80		9	89	35
Upper trunk				12	12	5
Chest wall, full-thickness			26		26	10
Lower trunk				7	7	3
Head and neck				4	4	2
Total number of patients	106	80	26	40	252	

MFH = malignant fibrous histiocytoma, NOS = not otherwise specified

Table 5. Procedures performed in Studies I, III–V

Procedure	Study	I	III	IV	V	All
Direct closure		52	30	0	17	99
Amputation		10	12	5		27
Minor			2			2
Major		10	10	5		25
Skin graft		20	11		11	42
Pedicled or local skin flap		3	7		7	17
Pedicled muscular, musculocutaneous or fasciocutaneous flap		12	13		3	28
Latissimus dorsi			9		1	10
Brachioradial			1			1
Pectoral			1			1
Radial forearm			1			1
Lateral arm flap			1			1
Gastrocnemius		8				8
Soleus		1				1
Tensor fasciae latae		1				1
Gluteus maximus		1				1
Vastus lateralis		1				1
Rectus abdominis					1	1
Temporal					1	1
Microvascular flaps		18	10	26	2	56
Radial forearm			4		1	5
Latissimus dorsi		16	3		1	20
Fibula			2			2
Tensor fasciae latae plus crista iliaca			1			1
Tensor fasciae latae				16		16
Tensor fasciae latae plus rectus femoris				5		5
Remnant leg		1				1
Remnant forearm				2		2
Gracilis		1				1
TRAM				3		3
Forearm replantation after excision of elbow area			1			1
Nerve reconstruction			4			4
Main blood vessel reconstruction			1			1
Tikhoff-Linberg procedure			2			2
Number of patients		111*	80	26	40	257

* patients included in the survival analysis + 5 patients operated on palliatively

deep infections or exposures of synthetic mesh or rib grafts. Five patients required further rehabilitation at other hospitals. All but three patients were able to return home after the operation.

1.2 Outcome of patients

The survival of all patients in clinical studies (Studies I and III-V) is presented in Table 6.

For extremity sarcomas, LRFS at five years was 79%, MFS 70%, DFS 63% and DSOS 76%, as estimated by the Kaplan-Meier method. Local recurrence developed in 32 patients (17%) and metastases in 59 patients (32%). Forty-five patients

(25%) who were not lost to follow-up died from their disease. For patients treated adequately, LRFS was 82% in lower limbs and 90% in upper limbs, as compared with 74% and 40%, respectively, with inadequate treatment.

For patients with full-thickness chest wall malignancies (Study IV) the overall survival rate at two years was 52% and at five years 25% (Table 6). The five-year survival rate was 28% for sarcomas and 13% for breast cancer recurrences. There was no postoperative mortality.

In patients with dermatofibrosarcoma (Study V), there were no local recurrences, development of metastases or deaths from disease during the follow-up time.

Table 6. Outcome of patients

	LRFS 5	MFS 5	DFS 5	DSOS 2	DSOS 5
Study I					
follow-up, months	mean 56, median 55, range 2-221				
survival %	79	72	63	87	76
Study III					
follow-up, months	mean 74, median 72.0, range 10-177				
survival %	79	68	62	91	75
Study IV					
follow-up, months	mean 28, median 19, range 2 - 83				
survival %				52	25*
Study V					
follow-up, months	mean 40, median 34, range 0.2 - 114				
survival %	100	100	100	100	100

* overall survival

LRFS 5 = local recurrence-free survival at five years

MFS 5 = metastasis-free survival at five years

DFS 5 = disease-free survival at five years

DSOS 2 = disease-specific overall survival at two years

DSOS 5 = disease-specific overall survival at five years

1.3 Clinical prognostic factors

The prognostic factors in STS of the extremities (Studies I and III) are presented in Table 7. In lower extremity STS (Study I), the prognostic factors tested in univariate analysis were patient gender and age, tumour malignancy grade, and tumour size, site, compartmentalisation and referral status (primary vs. locally recurrent tumour). Prognostic factors for the development of local recurrence in univariate analysis were extra-compartmental site ($p < 0.01$) and large size ($p < 0.01$), and both retained significance in multivariate analysis ($p < 0.01$ and $p = 0.05$, respectively). For the development of metastases, extracompartmental site ($p < 0.01$), large size ($p < 0.01$) and high grade ($p < 0.01$) were significant factors in univariate analysis, and they all remained significant in multivariate analysis ($p = 0.02$, $p < 0.01$ and $p = 0.01$, respectively). The estimated five-year disease-free survival rate was 63% and disease-specific overall survival rate 76%. Non-favourable for disease-specific overall survival in univariate analysis were extracompartmental site ($p = 0.02$), large size ($p < 0.01$), high grade ($p < 0.01$) and advanced age of the patient ($p = 0.01$), and the three last mentioned retained their significance in the multivariate model ($p < 0.01$, $p = 0.01$ and $p < 0.01$).

In upper extremity STS (Study III), the prognostic factors for local recurrence in univariate analysis were extracompartmental site ($p < 0.01$) and extramuscular or subcutaneous location with fascial penetration ($p = 0.02$). For the development of metastases, extracompartmental site ($p < 0.01$), large size ($p < 0.01$) and extramuscular or subcutaneous location with fascial penetration ($p = 0.01$) were significant in univariate analysis. The estimated five-year disease-specific overall survival rate was 75%. Extracompartmental site ($p = 0.04$) and large size ($p = 0.01$) were associated with fatal disease.

In STSs of the extremities, extracompartmental site was the strongest prognostic factor for local recurrence, with 62% LRFS in the lower limbs and 69% in the upper limbs, the total LRFS in limb sarcomas being 65%. Extracompartmental site tumours had 56% MFS in extremity sarcomas. In Studies I and III, 91% (29/32) of the local recurrences occurred in patients with extracompartmental tumours, and all amputations except one were performed in this group. LRFS for subcutaneous or intramuscular tumours was 97% in extremity sarcomas.

In malignancies of the chest wall (Study IV), nine out of 13 sarcoma patients (69%) and eight out of 10 breast cancer patients (80%) died of their disease during the follow-up time. In the subgroup of sarcoma patients, the survival rate was 54% at two years and 28% at five years, whereas in the subgroup of breast cancer patients the figures were 38% and 13%, respectively. The mean survival time for patients with sarcomas was 39 months (median 27 months, range 5–83 months) and for those with breast cancer 18 months (median 9 months, range 2–37 months). In the subgroup treated with curative intention, the survival rate was 65% at two years and 38% at five years, with a mean survival time of 46 months (median 47 months, range 5–83 months). In the subgroup of patients treated palliatively, the figures were 30% and 0%, respectively, with a mean survival time of 14 months (median 7 months, range 2–37 months).

1.4 Surgical margins

In sarcomas of the extremities (Studies I and III), the most common treatments were wide or compartmental surgery without RT (38.7%) and marginal surgery with RT (32.7%, Table 8). RT was delivered to 43% of patients. The treat-

Table 7. Prognostic factors in Studies I and III for extremity soft tissue sarcomas

	Study I	Study III
Local recurrence		
Number of local recurrences	18 (17%)	14 (17.5%)
Median time to development of local recurrence, months (range)	24 (3-54)	16 (7-90)
Extracompartmental site		
Extramuscular or subcutaneous location with fascial penetration	<0.01**	0.02
Large size	<0.01	n.s.
Metastases		
Number of occurrences of metastases	32 (30%)	27 (34%)
Median time to development of metastases, months (range)	20 (3-105)	17 (5-76)
Extracompartmental site		
Extramuscular or subcutaneous location with fascial penetration	<0.01**	0.01
Large size	<0.01	<0.01
High grade	<0.01	n.s.
Disease-specific survival		
Disease deaths	27 (25%)	18 (22.5%)
Extracompartmental site		
Extramuscular or subcutaneous location with fascial penetration	0.02*	0.04
Large size	<0.01	0.01
High grade	<0.01	n.s.
Advanced age	0.01	n.s.

The values are p-values in univariate analysis (95% confidence interval). In Study I, multivariate analysis was also performed.

* = n.s. in multivariate model, significant in univariate model

** = result of univariate analysis, not introduced into multivariate model in original article

ment protocol was strictly adhered to in 74% of the patients, with local control of 86% of patients. In 26% of the patients, treatment was considered inadequate, with local control of 62%. The most common reason for inadequate treatment was omission of RT (16.7%) after marginal excision owing to the patient's refusal of any further therapy, proximity to wide margins or earlier RT. The second most common reason was that reoperation after an intralesional margin was not performed because the patient refused amputation. Therefore RT was delivered to intralesional margins in

8.6% of patients. A wide or compartmental excision margin could be achieved in 40.6% of the patients and a marginal operation margin in 49.4%. In 9.7% of patients the intralesional margin was left, because the patient refused to have the amputation that would have been required. The LRFS for intralesional margins was 25% in the upper and 58% in the lower extremity, with disease-free survivals of 25% and 33%, respectively. In extracompartmental tumours treated with a wide margin the five-year LRFS was 77%, and in those treated with a marginal margin and RT, it was 78%.

Table 8. Treatment of limb sarcomas according to soft tissue sarcoma treatment protocol in Studies I and III

Treatment	Study no.					
	I	%	III	%	total	%
Adequate	74	70	63	79	137	74
Marginal + RT	29	27	32	40	61	32.7
Wide	43	41	24	30	67	36.0
Wide + RT	1	1	2	3	3	1.6
Compartmental	0	0	5	6	5	2.7
Compartmental + RT	1	1	0	0	1	0.3
Inadequate	32	30	17	21	49	26
Intralesional	2	2	0	0	2	1.1
Intralesional + RT	10	9	6	8	16	8.6
Marginal	20	19	11	14	31	16.7
Total number of patients	106		80		186	

RT = radiotherapy

In patients with full-thickness chest wall malignancies (Study IV), postoperative margins were analysed but not recorded, since analysis of surgical margins was not the object of this study.

Thirty-four out of 40 dermatofibrosarcoma patients (Study V) underwent only single primary or re-excision. In five patients, re-excision had to be repeated due to inadequate margins. One patient had to be operated on three times at our centre before the margins were adequate. In all, 47 operations were required for the 40 patients to achieve adequate margins (mean 1.2 stages per patient). The postoperative margins achieved were wide in 11 patients, marginal in 28 and intralesional in one patient. Gross margins were recorded as the gross tumour-free mar-

gins assessed by either the surgeon or the pathologist. Gross margins were more than 2 cm in 68% and more than 3 cm in 38% of patients. Histological margins exceeded 1.5 cm in 50% and 0.5 cm in 75% of patients. In all patients, the mean gross margin was 3.1 cm and the mean histological margin 1.6 cm. The average difference between gross and histological margins was 1.5 cm. There were no significant differences in margins between different patient groups, except that histological margins tended to be smaller in the head and neck region (mean 0.7 cm) than in other locations (mean 1.7 cm). For primary tumours, 41% of patients (13/27) needed reconstruction; for local recurrences the proportion was 77% (10/13).

2. DNA copy number changes between primary tumours and local recurrences (Study II)

2.1 Overview of results and mean number of changes

Sixty per cent (24/40) of all the samples showed copy number aberrations. In 10 tumour pairs, the number of aberrations was greater in local recurrences than in primary tumours, although the histological grade changed to more malignant in only one tumour pair. In three pairs, more aberrations were detected in primary tumours than in their local recurrences. In two pairs, the number of aberrations was equal in primary and locally recurrent tumours. In five pairs, CGH found no copy number changes in the primary tumour nor in its local recurrence. These tumours were: two MFHs (grade 3), two synovial sarcomas (grade 3) and one myxoid liposarcoma (grade 2). Of all the samples, CGH showed no changes in 10 primary tumours and six local recurrences.

Fifty per cent (10/20) of the primary tumours showed copy number aberrations. In local recurrences, copy number aberrations were detected in 70% (14/20) of the tumours. The total number of aberrations in local recurrences was more than twice that in primary tumours. This increase in copy number changes from primary tumours to local recurrences was statistically significant ($p=0.02$). The increase in gains from primary tumours to local recurrences was also significant ($p=0.03$). The increase in losses was without statistical significance. The mean numbers of DNA changes are presented in Table 9.

The mean number of changes differed between high-grade (grades 3 and 4) and low-grade (grades 1 and 2) tumours. In primary tumours, the low- and high-grade malignant sarcomas

showed an equal number of copy number changes, whereas in local recurrences the mean number of changes was more than twice as high in high-grade as in low-grade tumours (Table 9).

Sarcomas can be grossly divided into tumours with simple karyotypes and specific genetic alterations (translocation associated) and tumours with complex karyotypes but no specific genetic alterations (non-translocation associated). The translocation-associated group ($n=4$) had one myxoid liposarcoma and three synovial sarcomas. The non-translocation-associated group ($n=16$) had eight MFHs, three fibrosarcomas, two leiomyosarcomas, one lipoma-like liposarcoma and two sarcomas NOS. In the translocation-associated group, there was no difference in the number of changes between primary and locally recurrent tumours whereas in the non-translocation-associated group the number of changes was twice as high in locally recurrent as in primary tumours (Table 9).

2.2 Most frequent minimal common regions of DNA aberrations

The most frequent copy number change was loss at 9p, with the minimal common region of 9p22-pter. This change occurred in 30% of the local recurrences; in only one (5%) primary tumour was a loss affecting 9p21-pter detected. The second most frequent copy number changes were gains at 5p (minimal common region 5p14-15.1) and 20q, both of which occurred in 25% of local recurrences. In primary tumours, there were gains of 5p in 10% and of the entire chromosome 20 in 5% of tumours. The most frequent copy number changes that affected primary tumours as well as local recurrences with almost the same frequencies were a gain at 7p with a mini-

Table 9. Mean number of changes in 20 tumour pairs analysed by comparative genomic hybridisation

	Primary tumours	Local recurrences	
All changes	2.45	5.05	p=0.02
Gains	1.45	3.3	p=0.03
Losses	1.0	1.75	p=n.s.
High level amplifications	0.4	0.8	
<hr/>			
Low grade (n=6)			
All changes	2.5	2.8	
<hr/>			
High grade (n=14)			
All changes	2.4	5.8	
<hr/>			
Translocation associated (n=4)			
All changes	0.25	0.25	
<hr/>			
Non-translocation associated (n=16)			
All changes	3.1	6.3	
<hr/>			

primary tumours (15%) and 7p11.2-pter in local recurrences (20%) and losses of 13q21 and 8p12-pter (15% and 20%; 15% and 15%, respectively).

The most frequent high-level amplification at 18p11.3 was detected in 15% of the local recurrences but in none of the primary tumours. Recurrent high-level amplifications were also seen at 17p (primary tumours 5%, local recurrences 10%), 22q11.2 (local recurrences 10%), 1q21 (primary tumours 10%) and 1q21-23 (local recurrences 5%).

2.3 Clonal relationship

Only two of the pairs in which both samples had aberrations according to CGH (n=9) shared identical aberrations, although in one of them the length of some aberrations had changed. One pair did not have any common changes, and in the remainder, common changes outnumbered differences in two pairs and differences outnumbered common changes in two pairs. In two pairs, the numbers of common changes and of differences were identical.

DISCUSSION

1. Treatment protocol for extremity soft tissue sarcomas (Studies I and III)

Prevention of local recurrence of STS has traditionally been, and still is, surgically the most important goal of treatment. Local control rates ranging from 71% to 95% have been reported from large sarcoma centres with modern treatment (Table 3). A procedure that long presented a surgical challenge was limb-salvage, though this has now been widely met. With conservative surgery combined with RT, amputation rates from 4% to 30% have been reported, the rate being between 10% and 20% in most tumour centres specialised in the management of STS. RT is often routinely combined with conservative surgery.

In these studies we evaluated the treatment and outcome of 186 patients with STS of the extremities referred to our hospital, which serves as the largest tertiary referral centre for soft tissue tumours and reconstructive surgery in Finland. The objective has been to centralise the treatment of STSs. Nevertheless, many of the small, easily accessible primary tumours are still initially operated on at district hospitals. The majority of the patients in the studies had high-grade tumours and patients referred for local recurrence were also included. For these reasons, our studies cannot be considered population based.

Our protocol, which comprises detailed analysis of postoperative margins and selective application of RT, seems to be justified since the outcome of patients is similar to that reported for earlier series (Coindre et al. 1996, Lohman et al. 2002). In our series, the estimated five-year LRFS was 79%, MFS 70%, DFS 63% and DSOS 76%. Our treatment protocol proved its efficacy in local treatment.

The protocol was strictly followed in 74% of patients, with 86% local control at five years. The most common reason for protocol violation was omission of RT. This implies that strict adherence to the protocol would further reduce the frequency of local recurrences. The second most common reason for inadequate treatment was the patient's refusal of amputation after an intralesional operation, an action that is more difficult to interfere with. However, 90% of the patients maintained a functional limb. The 12.5% amputation rate for the upper extremity was slightly higher than that (9%) for the lower extremity, although the median tumour size was smaller in the upper than in the lower extremity (5 cm vs 7 cm). This reflects the fact that adequate operation margins are more difficult to achieve in the upper extremity owing to the scantiness of soft tissues. There were no significant differences in end-point outcome measures between patients with STS in the upper extremity and those with STS in the lower extremity. Further, with the exception of epitheloid sarcoma (five patients), which occurred only in the upper extremity, there was no difference in histological diagnoses between the upper and lower extremities. Wide or compartmental (40.6%) or marginal (49.4%) surgical margins could be achieved in 90% of patients.

Intracompartmental tumours, which consist of intramuscular and subcutaneous tumours, had favourable local control (97%), an outcome that is consistent with earlier results (Gibbs et al. 1997, Rydholm et al. 1986). In this group of patients, improvement in local treatment is hardly needed, as intramuscular tumours can usually be managed by myectomy alone, as also found by other investigators (Rydholm et al. 1986). In subcutaneous tumours not penetrating

the fascia, wide excision is usually sufficient treatment. In our experience, RT should be delivered if postoperative margins are less than 2.5 cm.

The main factors determining tumour resectability are the size and anatomical location of the tumour. The strongest prognostic factor for local recurrence was extracompartmental site with 65% local control in extremity sarcomas; this factor was significant in both upper and lower limbs. These tumours comprised two-thirds of the extremity tumours treated, and 91% of the local recurrences occurred in this group. Thus extracompartmental tumours constitute the most frequent and challenging subgroup in terms of local control. In extracompartmental tumours treated with wide excision, local control was 77%, suggesting that a margin of 2.5 cm may not be sufficient for such tumours. Perhaps the treatment protocol should be altered to permit RT to be routinely delivered to all extracompartmental tumours, even in the event of wide excision margins. However, our result has to be considered tentative only because of the small number of patients; the issue needs to be addressed within the context of larger clinical trials. It has recently been suggested by other authors, too, that RT should be delivered to these tumours more liberally, irrespective of excision margins (Trovik et al. 2001). Efforts to improve treatment results should be targeted mainly at this group of tumours.

Large tumour size was significant for local recurrence in STS of lower limbs but lacked significance in upper limbs, most likely due to the small sample size. In upper limbs, the median tumour size was smaller (5 cm vs. 7 cm in lower limbs) and not sufficient to gain sufficient statistical power. Large tumour size is usually strongly (but not necessarily always) associated with extracompartmental site. However, location in the

compartment may still be a more accurate prognostic factor than tumour size for local recurrence, because it has a more direct effect on the extent of surgical margins and thus on the likelihood of residual tumour.

High malignancy grade was not significant for local recurrence in either study. Although high histological grade is generally considered a strong prognostic marker for local recurrence, results similar to ours have been reported elsewhere (Cany et al. 1999, Pisters et al. 1996). This may indicate that tumour compartmentalisation and size, which determine surgical resectability, are more important than malignancy grade for local recurrence.

Surprisingly, the presentation status (primary or local recurrence) did not have prognostic significance for any of the outcome measures, even in univariate analysis. This is contrary to findings in many earlier studies (Pisters et al. 1996, Zagars et al. 2003) and may be due to the small proportion (18%) of patients referred with local recurrence and thus to the lack of statistical power.

A strong association has been found between positive surgical margins and local recurrence (Herbert et al. 1993). In our studies these factors were not included in the statistical models for prognostic significance. This omission is due to our protocol, which states that no tumour should be left with intralesional margins (that is, "positive margins"). Even so, some patients were left with intralesional margins and, in them, local recurrence-free survival was poor, 25% in the upper and 58% in the lower extremity, with disease-free survival rates of 25% and 33%, respectively.

The strongest prognostic factors for the development of metastases were extracompartmental site and large tumour size, both of which were significant in upper and lower limbs. MFS in patients with extracompartmental tumours was

56%. High grade of the tumour was significant for the development of metastasis in lower limbs but not in upper limbs, although a trend towards decreased MFS was noted in high-grade tumours of the upper limb (low grade 92% MFS vs. high grade 63%). The lack of statistical power is due to the larger proportion of high-grade tumours in upper limbs (84%) than in lower limbs (73%) and also to the smaller sample size. These studies demonstrate that tumour grade is a strong factor predicting the development of metastasis, as previously reported (Pisters et al. 1996, Coindre et al. 1996).

The local recurrence rates in patients treated with modern limb salvage methods are similar to those previously treated with amputation. Efforts to improve the outcome of patients with resectable STS are now mainly focused on tumours with negative prognostic factors. In terms of local recurrence, these are extracompartmental high-grade tumours. The preferable method and sequencing of RT still remain to be established. Adjuvant chemotherapy may have a beneficial effect on local as well as on distant recurrence (Sarcoma Meta-Analysis Collaboration 2000), and a randomised multicentre trial (Issels et al. 2002) has been set up to answer these questions. New operative techniques have been introduced to further reduce the number of amputations (Matsumoto et al. 2002). In the future, advances in microsurgical techniques in parallel with molecular biological discoveries may resolve problems related to major nerve regeneration (Siemionow et al. 2004) while novel methods, such as isolated limb perfusion with TNF and melphalan, may improve local control in tumours with poor prognosis. However, until definitive molecularly targeted treatment to change the natural history of STS is available, even absolute local control is not likely to resolve the problem of distant dissemination. As treatment strategies for STS con-

tinue to be refined, probably the most important factors for improving the outcome of sarcoma patients are to minimize diagnostic and treatment failures and to avoid delays in treatment. These goals are best achieved by the centralisation of definitive treatment and by the provision of nationwide information about primary diagnostics and referral practice.

2. DNA copy number changes in local recurrences (Study II)

In this study we conducted a genome-wide survey of primary STS and local recurrences by CGH. Fifty per cent of the tumour pairs showed more aberrations in the locally recurrent than in the primary tumour. A more than two-fold increase in the number of copy number aberrations was detected in local recurrences although there was no change in histopathological grade in 19 out of 20 tumour pairs. These findings suggest that tumour progression from primary to locally recurrent STS may be associated with an increase in genetic changes and that local recurrences are thus more advanced than primary tumours. Genetic progression has also been noted in relapses of intra-abdominal STS (Weng et al. 2005). An increased number of aberrations has also been detected in large Merkel cell carcinomas with a higher risk of distant metastasis than small tumours (Larramendy et al. 2004). Nevertheless, in our study, the copy number karyotype, a gain of chromosome 2, of one primary synovial sarcoma remained identical, also in the local recurrence, over a period of 32 months.

In our study, gains predominated over losses in primary tumours with a ratio of 3:2. A similar trend was detected in local recurrences, with a ratio of 13:7. The number of high-level amplifications was twice as high in local recurrences as in primary tumours. The most common

copy number change, a loss at 9p with the minimal common region 9p22-pter, occurred in 30% of the local recurrences but in only 5% of the primary tumours. Thus a clear increase in the losses at 9p was noted in local recurrences as compared with primary tumours. 9p losses are reported to be as common in primary sarcomas as in their metastases (Tarkkanen et al. 1999) but they are also frequent in various human neoplasms (Knuutila et al. 1999).

Gains at 5p were relatively common, being found in 10% of primary tumours and in 25% of local recurrences. High-level amplifications at 5p were also noted but these were not recurrent. Gains and high-level amplifications at 5p are often seen in sarcomas and carcinomas of different subtypes (Knuutila et al. 1998). The increase in gains was also detected at 20q, occurring in 5% of the primary tumours and in 25% of the local recurrences. High-level amplification in 18p was detected in three local recurrences but in none of the primary tumours. The histopathological diagnosis for these recurrences was two MFHs and one fibrosarcoma.

Quantitative changes, for example, those in which a gain changed into a high-level amplification or in which the length of a change increased, occurred in several tumour pairs. It was also noted that an aberration in one of the samples appeared as a "trend" in the other sample but did not exceed the thresholds for gain or loss. Similar observations have previously been made in primary sarcomas and their pulmonary metastases (Tarkkanen et al. 1999).

Some degree of clonal relationship was detected in eight of the nine tumour pairs with aberrations in both samples, in agreement with observations made in sarcoma metastases (Tarkkanen et al. 1999). In one tumour pair, primary tumour and local recurrence were genetically completely different. In metastatic renal cell carcinomas, a high probability

of a common clonal progenitor was found in 58% of the patients, but 32% of the metastases were genetically almost totally different from the primary tumour (Bissig et al. 1999).

Comparative genomic hybridisation detected no changes in 16 samples. Of these, 15 were paraffin-embedded samples and one was a freshly frozen tissue sample, so it is not likely that the normal copy number karyotype was due to a non-representative sample. A possible explanation for the normal finding might be intratumoural variation with multiple subclones. CGH detects only clonal changes. Aberrations in subclones may balance one another, thus giving a normal result by CGH. It is also possible that the copy number aberrations were too small to be detected by CGH. Moreover, since CGH does not detect balanced aberrations, a tumour with only a specific translocation will appear normal according to CGH, which may explain why no aberrations were detected by CGH in some cases. Normal karyotypes have been reported in metastases of Ewing sarcoma (Brisset et al. 2001) and also in metastases of synovial sarcoma and MFH (Tarkkanen et al. 1999).

Although specific alterations in local recurrence were not detected, our study confirms that an increasing number of DNA sequence copy number aberrations is a dominant feature in the progression from a primary tumour to a local recurrence.

3. Reconstructions in musculoskeletal tumour surgery (Studies I, III–V)

When amputations without free flap reconstructions were excluded from the total, reconstructions were required in 53% of the patients. The most common reconstruction was a free flap, which was required in 22% of all patients and in

15% of those with the extremity STSs. The second most common reconstruction was a skin graft, followed by pedicled muscle flaps and skin flaps. The success rate for the 56 free flaps was 96.4%, which is similar to results from other centres (Cordeiro et al. 1994, Kroll et al. 1996, Hidalgo et al. 1998). Note that the high rate of plastic surgical reconstructions in this series reflects the complicated referral pattern of our tertiary referral centre, where free flaps are probably overrepresented. The high rate of reconstructions also implies that all-inclusive treatment of musculoskeletal tumours requires considerable application of plastic surgical methods. Wide excision of a large, extracompartmental STS is seldom possible without adequate reconstruction. Even in dermatofibrosarcomas, reconstructions were used for more than half of the patients.

The possibility of using adjuvant treatments must be taken into account when planning the surgery. The operation should be planned to minimise the probability of wound complications, such as wound dehiscence, infection and seroma formation, and to enable RT and chemotherapy, if required, to be delivered without delay. Wound complications are commonly minimised with flap reconstructions. Particularly important is that the flaps allow tension-free closure and good perfusion in wound edges. Muscle and musculocutaneous flaps provide abundant, well vascularised tissue for the operation / radiation area filling the cavities. By selective combination of RT and surgery, the unnecessary morbidity associated with RT can be avoided (Yang et al. 1998). Omitting RT in cases in which it is not actually needed enables the safe use of skin grafts in reconstruction (Bui et al. 2004). This reduces the number of unnecessary microvascular flaps and thus lowers the cost of treatment. However, there should be no doubt about delivering RT if excision margins remain inadequate.

The choice between free and local / pedicled flaps depends very much on the anatomic region to be restructured (Hidalgo et al. 1998). In the thigh area, flaps are not usually needed due to the abundance of soft tissues. In the proximal upper limb, pedicled LD is a good option and was used in nine patients (11%). In the knee or proximal lower leg, pedicled gastrocnemius is available and was used in eight patients (7%). If the re-excision demands large resection or the tumour is located in the middle or distal upper extremity or distal lower extremity, wide excision is not usually possible without free flap reconstruction. The role of reconstructive surgery is even more pronounced after tumour excision in the upper limb than elsewhere in the body, since excision is more likely to cause tendon and nerve defects and thus severe functional deficiencies.

The selection of a free flap for oncological musculoskeletal reconstruction has to take all the traditional aspects, such as aesthetic and functional result, donor site morbidity and technical feasibility, into account. Also important is the reliability of the flap (Kroll et al. 1996). In this series, only five different types of free flap, namely TFL (n=22), LD (n=20), radial forearm (n=5), fillet extremity (n=3) and TRAM (n=3), were needed to reconstruct most of the defects. Thus, these flaps accounted for 95% of all the free flaps used. The TFL free flap was mainly used for chest wall reconstructions (21/26). LD was most frequently used in the extremities (18/29); in the lower extremity it was capable of solving nearly all problems (16/18 free flaps). Radial forearm free flap was used only in the upper extremity and was the free flap most commonly used in that site (5/11). It is obvious that selection of these methods for reconstruction reflects the experience accumulated in our institution with these particular flaps. It has been reported that only a few flap types

comprise the armamentarium needed to reconstruct most cases (Hidalgo et al. 1998). However, all the flaps we used, possibly excluding fillet flaps, are consistent, reliable and regularly used by reconstructive microsurgeons (Salemark et al. 1991, Kroll et al. 1998).

Certain points have to be taken into account in the selection of flaps for chest wall reconstruction. In the event of flap loss or major wound complications, the vital intrathoracic organs will be exposed, leading to life-threatening complications (Cordeiro et al. 2001). Thus the reliability of the flap is even more pronounced in the chest wall than in other regions. The ideal flap has a constant anatomy and a reliable and sufficiently large pedicle. Its composition is versatile, and it preferably provides mechanical support, too. It has resistance against infection owing to the common use of synthetic materials and rib-grafts in these operations. Further, it should be possible to harvest the flap quite rapidly with the patient in either the supine or the lateral position, thus avoiding major postural changes during the operation. Moreover, donor site morbidity should be acceptable and in proportion to the indication. The defect is often large, since it is important to excise as much of the unhealthy or radiated tissue as possible (Arnold et al. 1996). Thus a flap of considerable size may be required. Multiple pedicled flaps have traditionally been used for the reconstruction of large (average 428 cm², 21×21 cm) defects (Chang et al. 2004). If the defect affects only one pleural cavity, it is not advisable to disturb the healthy side by needlessly harvesting a flap, e.g. latissimus dorsi with an extensive skin island, or rib graft. Such procedures may further impair the patient's respiratory function, and so prolong, or even prevent, recovery. In this sense, one large free flap harvested from a distant site might be safer than a pedicled flap that would result in a do-

nor site with morbidity at or close to the chest area.

The musculocutaneous TFL flap surface area can be up to 1400 cm² (35×40 cm) and it can include the rectus femoris muscle if abundant muscle tissue is needed, e.g. to cover a bronchopleural fistula or to fill the chest cavity after empyema. The pedicle is under the flap (not outside as in the latissimus dorsi), a location usually well suited to the anatomy of the defect. The pedicle is large and long (Heitmann et al. 2000), and it can be further extended by including the descending branch of the lateral circumflex femoral artery. This manoeuvre is performed with very large flaps; if necessary, even one of the motor nerve branches to the vastus lateralis muscle may be divided (and reconstructed) in order to obtain optimal pedicle vessels. We did not lose any TFL flaps, which proved to be very reliable, despite the use of a saphenous vein loop in seven of the 22 flaps. The temporary arteriovenous loop method has been successfully applied in reconstructions of the extremities (Lin et al. 2004), trunk (Earle et al. 1990, Karanas et al. 1998) and head and neck region (Kim et al. 1998), and in our series it was a valuable tool in full-thickness chest wall reconstructions. Anastomosing the pedicle to intraperitoneal vessels has also been documented (Chevray et al. 2003). We intentionally avoided this procedure since, in the event of reoperation, the stabilising reconstructions would have been opened and the peritoneal and thoracic cavity exposed repeatedly, thus increasing the risk of hernias or pedicle compression. The strong fascial portion of the TFL flap gives additional stability to the reconstructed chest wall and it can be sutured tightly to prevent air leakage. We consider TFL especially suitable after forequarter amputation if the fillet extremity flap cannot be used. Clearly, the widest TFL donor sites cannot be closed primarily,

and then a skin graft cover is used. As the donor site is in the thigh, harvesting a TFL flap does not affect the patient's respiratory function. TRAM also makes a large, reliable and constant flap. In suitable patients, donor site morbidity (pain, tension and respiratory effect) may be acceptable, but in very slim patients the flap is of limited size. It has also been demonstrated in breast reconstructions that elevation of a TRAM flap increases intra-abdominal pressure (Losken et al. 2002). The effect on respiratory function when the TRAM flap is used for chest wall reconstructions may be considerable, especially in patients with advanced disease treated with several therapies and in a catabolic state.

In our series we had one forequarter and five extended forequarter amputations. All the extended forequarter amputations required a large free flap. Remnant forearm was used in two patients and TFL in three. If extended forequarter amputation or hemipelvectomy is to be performed, the fillet extremity is usually the first option for the free flap, assuming that the flap and the pedicle area (distal brachial or popliteal vessels) are tumour free (Tran et al. 2000, Cordeiro et al. 2001). In two Tikhoff-Linberg resections, one was closed directly and the other with a LD free flap. We emphasise that in extremely radical and mutilating procedures such as forequarter amputation or hemipelvectomy the possible curativity of the operation should not be compromised by the limited reconstructive options available.

4. Surgical treatment of chest wall tumours (Study IV)

Full-thickness chest wall resection with microsurgical reconstruction is one of the most challenging procedures in reconstructive surgery today. It has to be emphasised, however, that the free flap

method is not routine for chest wall reconstruction. The group of patients described here is highly selected and constitutes a small fraction of all patients with chest wall resection. The chest wall defects of most patients can be reconstructed with conventional methods such as local or pedicled flaps (Mansour et al. 2002). A free flap is only indicated when conventional flaps are not available or they are too small. Moreover, in small defects, stabilisation of the chest wall is not mandatory (McCormack 1989).

Patients with chest wall tumours often present with advanced disease and compromised general condition, and their tolerance of complications is impaired. Careful individual evaluation to appraise the risks and benefits is important. Even a minor problem may lead to major systemic complications, such as infection of the prosthetic material, mesh removal or pulmonary dysfunction (Cordeiro et al. 2001). Because two extensive operations are combined, with an average operation time of seven hours, a two-team approach (tumour resection and free flap harvest) is necessary to shorten the duration of these operations.

At the beginning we did not use foreign materials or free rib grafts in our patients, because they have been associated with deep infections, albeit infrequently (Deschamps et al. 1999). However, it became evident that stability is crucial in the early postoperative period, when the patient is being extubated. In one patient with extended forequarter amputation, the unstable chest wall prevented spontaneous breathing. A new operation, in which rib grafts were placed under the flap, was performed and the patient recovered. Thereafter, we began to use synthetic mesh and rib grafts more liberally. Our decision to do so is borne out by earlier studies reporting that the use of synthetic mesh or rigid prosthesis reduced ventilator dependence (Nash et al. 1991, Kroll et al. 1993). The rib grafts were al-

ways harvested from the resection side (if not sternal) to avoid morbidity on the healthy side. Inferior ribs were preferred and no adjacent ribs were harvested. In thoracoabdominal resections, the diaphragm was sutured back to its original position or reconstructed with synthetic material (PTFE). In our experience, bony stability is particularly important in patients who have a defect after sternal excision, high lateral resection or extended forequarter amputation.

Surprisingly, there were no deep infections in this series even though the tumours were often infected, ulcerated, and irradiated. Thus shield prostheses of methylmethacrylate could probably be used safely to stabilise the chest wall. The primary target of such prostheses would be the sternal area, where rib grafts are not easily available. It has been claimed that free flaps should not be used in the presence of infection (Al-Kattan et al. 1995). Our results contradict this conclusion, since the absence of deep infections in our patients may reflect the importance of well-vascularised flap tissue covering the defect, without the tension and vascular compromise often seen in pedicled flaps of limited size and range.

Perioperative mortality was 0-17% in a recent series of chest wall resections (Cordeiro et al. 2001, Arnold et al. 1996, Mansour et al. 2002, Al-Kattan et al. 1995, Cohen et al. 1996). Our results imply that extensive chest wall resections with microvascular reconstructions are relatively safe. Although long-term survival is poor, especially in breast cancer patients, the procedure may offer them considerable palliation (Vandeweyer et al. 2002, Downey et al. 2000, Dahlstrom et al. 1993). However, in the proximal sternal area, where major vessels and phrenic nerves are particularly vulnerable during resection, it may not be sensible to perform a full-thickness resection if the nature of the operation is palliative. Long-term survival is better in sar-

coma patients, and in them the resections may even be curative, which is consistent with the findings of earlier studies (Walsh et al. 2001). In STS patients, an intralesional operation must be avoided at all costs, because it leads to dissemination of the disease into pleural cavities. In curatively intended treatment, the extent of the tumour resection should not be compromised by the size of the local or pedicled flaps available. To achieve wide resection margins in local disease, microvascular reconstructions should perhaps be used more liberally in sarcoma patients.

5. Treatment protocol for dermatofibrosarcoma (Study V)

In this series, 40 patients with dermatofibrosarcoma protuberans (DFSP) were treated by surgical excision, with no recurrences during the follow-up. The wide range of the results of wide excision in the literature is probably due to the vagueness of the term "wide excision", which is generally defined as an excision with 2-3-cm gross margins and histologically "negative" margins. Previous reports document that increasing the gross margin decreases the local recurrence rate (Roses et al. 1986, Bowne et al. 2000). However, due to the infiltrative growth pattern with fingerlike-projections in DFSP, it is not likely that even the most careful histological examination would be able absolutely to preclude intralesional operation when histological margins are short. To improve local control, more exact recommendations concerning the length of histological tumour-free margins are therefore probably needed.

Our study demonstrates that good local control can be achieved with repeated excisional surgery. The clinical assessment of an adequate surgical margin is extremely difficult. The mean gross mar-

gin in our patients was 3.1 cm but histologically it was 1.6 cm. The average difference between gross and histological margins was 1.5 cm, with a broad range. A histological tumour-free margin averaging 1.6 cm was sufficient for complete local control. In a recent series of 60 patients, a minimum histological tumour-free margin of 1 cm yielded a five-year recurrence rate of 14% (Chang et al. 2004). However, in a study of patients operated on with Mohs surgery, a sole 3-cm-wide gross margin would have left 15.5% of the tumours inadequately excised (Ratner et al. 1997). It is thus emphasised that, after a so-called wide excision, the postoperative margin should always be verified by careful histological examination whatever the extent of the gross margins.

The main advantage of excisional surgery over micrographic surgery is that it is time saving. In micrographic surgery, subsequent operations are often needed due to inadequate excision or for reconstruction of a primary defect that was left open. In an earlier series of 58 patients treated with micrographic surgery, the mean number of stages was 2.4, with a range of 1–8 (Ratner et al. 1997). In a randomised study of basal cell carcinoma, no significant differences in local recurrence rates were noted between excisional and Mohs surgery, but the costs were almost twice as high in the latter (Smeets et al. 2004). In our series, the mean number of stages was 1.2, with a range of 1–3, which demonstrates that the number of operations needed in Mohs surgery is twice that in excisional surgery.

In cases in which the tumour infiltrates the deep fascia or muscle, especially in local recurrences that may have been operated on several times, all efforts should focus on aggressive and wide removal of the tumour, since recurrence will usually lead to mutilating operations some time in the future. If flap reconstructions are performed, there should be no doubt about the adequacy

of the excision, as flaps may prevent the early detection of a local recurrence. Wide excision and primary reconstruction in one stage can be performed on most patients, with good functional and cosmetic results. In the head and neck region, histological margins were shorter (mean 0.7 cm) than in other locations (1.7 cm). In these areas, where extensive margins usually cause greater morbidity, micrographic surgery may be a valuable tool, particularly for primary tumours. Our treatment policy is that when a histological margin is less than 1.5 cm a re-operation is usually performed. However, if the re-operation would severely impair the functional or cosmetic result, more scarce margins may be accepted, and patients are carefully followed. Even an intralesional margin may then be accepted in non-fibrosarcomatous cases, since DFSP typically grows slowly and the risk of fibrosarcomatous differentiation and the development of metastases is relatively low. In the future, imatinib could perhaps be used as an adjuvant therapy in patients in whom it is impossible to achieve sufficient surgical margins with conservative surgery (Sirvent et al. 2003, McArthur et al. 2005).

The local aggressiveness of the disease poses a challenge in the treatment of DFSP. Extensive operations may be required, but with current treatment the prognosis is good and curative treatment usually possible. Reconstructive procedures are frequently needed, even in primary tumours. The extent of the resection should not be compromised by the reconstructive options available. In locally recurrent DFSP, most patients (77%) needed a skin-graft or a flap due to a large tissue defect. Thus it is emphasised that coordination of the treatment of dermatofibrosarcomas should be centralised in institutions with expertise in the treatment of musculoskeletal tumours and reconstructive surgery.

SUMMARY AND CONCLUSIONS

1. The limb-salvaging treatment protocol for STS is functioning well and it should be strictly followed.
2. Tumours located extracompartmentally have the poorest prognosis and should be the main target of efforts to improve treatment strategies. RT may be of value to all deep extracompartmental tumours.
3. Reconstructive procedures are successful and frequently needed in STS surgery. Tumours should be operated on at centres where all plastic surgical reconstruction options are available.
4. Owing to tumour progression, the number of genetic changes studied by CGH is increased in local recurrences.
5. Large microvascular reconstructions for full-thickness defects of the chest wall are possible with acceptable results. The TFL free flap is well suited to chest wall reconstruction. In STS, the operation may be curative and in breast cancer it may offer valuable palliation.
6. Good local control can be achieved in the majority of patients with dermatofibrosarcoma in one operation, as long as excision is not compromised by the limited number of reconstructive surgery options available.

The studies discussed here evaluated a wide variety of surgical procedures for musculoskeletal malignancies, the majority of them STS. Plastic surgical reconstructions were needed in more than half of the cases. The success rate of

these procedures was good, even when combined with oncological treatment. Although some surgical procedures were infrequent even in this highly selected patient material, five different types of free flap were capable of solving 95% of the reconstructive problems. The free flap most commonly used in the lower extremity was LD, in the upper extremity radial forearm flap and in the chest wall TFL.

The extremity STS patients treated with the HUCH protocol were evaluated. The protocol, which aims to spare limbs through a selective combination of surgery and RT, was found to function well in terms of limb salvage rate and oncological outcome measures. Subcutaneous and intramuscular tumours can frequently be managed by surgical treatment alone. Tumours penetrating the deep or muscle fascia and those located extra-compartmentally have the poorest local control despite wide surgery with 2.5-cm microscopic margins; patients with such tumours might be the main target for adjuvant therapies. Some proposals for even better results were made. One was the delivery of RT to deep extracompartmental tumours despite wide excision margins. Another was strict adherence to the treatment protocol in the future. In most of the protocol violations, RT was omitted after marginal surgery or amputation was not performed after an intralesional operation.

An analysis of 20 cases of primary STS and their subsequent local recurrence according to CGH revealed an increase in copy number changes in local recurrences due to tumour progression. Gains predominated over losses. Loss at 9p and gains at 5p and 20q were more frequent in local recurrences, and high-level amplification of 18p11.3 was only

detected in local recurrences. Although no alteration specific to local recurrence was found, these alterations may represent changes that are important during STS progression.

The operative techniques used in patients with chest wall malignancy requiring extensive full-thickness resection were evaluated. Important factors concerning flap selection, stabilisation of the chest wall and selection of patients were reported, thus helping the planning of operations. The lack of infectious complications, even after synthetic mesh and free rib graft reconstructions, may reflect the importance of well-vascularised flap tissue coverage. Information about patient outcome was gathered, leading to the conclusion that the operation is palliative for breast cancer, even after maximal extent of resection, but that it may be curative for sarcomas. The TFL free flap was found to be reliable in full-thickness chest wall reconstruction in our series, which, to our knowledge, is the largest series reported.

In the treatment of dermatofibrosarcomas, we demonstrated that clinical margin assessment is extremely difficult. A gross margin averaging 3.1 cm resulted in a 1.6-cm histological, tumour-free margin. Hence, postoperative histological margins should be evaluated with care and as meticulously as in other

types of STS. A histological margin of 1.6 cm was sufficient for complete local control, and is therefore suggested as a treatment guideline. Most tumours were surgically excised in one operation.

In conclusion, our results for treatment of STS are consistent with the findings of other tumour centres, and demonstrate that limb-sparing surgery and a selective combination of treatment modalities give good local control and acceptable survival. It is emphasised that no routine solutions exist for the treatment of musculoskeletal malignancies. Surgically, these tumours are characterised by their variable location, and by the wide spectrum of ablative procedures and the extensive amount of reconstructions required. Surgical and oncological treatments are combined and planned for each patient individually. As efforts continue to refine treatment strategies and adjuvant therapies for musculoskeletal malignancies, STS in particular, the most important factor for the outcome of these patients is that their treatment should be concentrated in specialist centres, where adequate diagnostics, surgery and adjuvant treatments can be undertaken at the primary stage. In the treatment of these malignancies, plastic surgical reconstructive procedures are an essential part of surgery and should be readily available.

ACKNOWLEDGEMENTS

This study was carried out at the Department of Plastic Surgery, at the Department of Radiology and Oncology and at the Department of Medical Genetics, Helsinki University Central Hospital, in 1999–2005.

First of all I would like to express my deepest gratitude to Professor Sirpa Asko-Seljavaara for her encouragement, support and outstanding ever-positive attitude towards research and the education of residents. She had the admirable ability always to find a moment to comment on a manuscript or to organise research matters, even when she had retired from hospital work.

I am truly grateful to my supervisor, Professor Erkki Tukiainen, Department Head, for his encouragement and for sharing his considerable expertise in methods of reconstructive surgery and in the treatment of patients with soft tissue tumours. It has been a privilege to work with such a skilful and versatile surgeon.

My sincere thanks go to Docent Carl Blomqvist for his insightful comments on the oncological aspects of this study, for passing on his expertise in statistical analysis, and his advice and support, which were much needed in the early part of my work.

I wish to thank Docent Martti Viro-lainen for performing the pathological analysis of the specimens, for revising the manuscripts – and for his amazing sample search-and-find ability.

I am indebted to Docent Maija Tarkkanen for her support, and for her kind and patient introduction to cytogenetic methods and principles in an area that cannot be seen, even with loupes. I also thank her for revising the manuscript of Study II.

I am sincerely grateful to Docent Tom Böhling for assiduously evaluating the pathological aspects of this thesis, for revising the manuscript of Study V and for providing insightful advice, always in his characteristically amiable manner.

I want to thank Dr Riikka Huuh-tanen for her sound and friendly advice, for introducing me to the sarcoma registry and for revising the manuscripts. My appreciation is also due to all members of the Soft Tissue Sarcoma Group at HUCH, especially to Docent Tom Wiklund for maintaining the sarcoma registry in the early years.

I kindly thank Professor Inkeri Elo-maa and Docent Karl von Smitten, the reviewers of the thesis, for their incisive comments and advice.

I wish to thank my co-workers Professor Sakari Knuutila for providing the facilities for CGH and Docent Pekka Virkkunen for revising the manuscripts of original articles. I also thank Professor Risto Mokka for his support in this research, and for the interesting discussions we held while I was working as a resident of surgery at Päijät-Häme Central Hospital.

I would like to express my gratitudes to all my colleagues and other members of staff at the Department of Plastic Surgery, especially those who have supported me with advice or helped in other, practical ways during this process, namely, Docent Hannu Kuokkanen, Dr Sinikka Suominen, Dr Tiina Jahkola, photographer Jukka Alstela and secretaries, Eila Nousiainen and Tuija Kolehmainen. I also appreciate the work of the obliging staff at the archives of Töölö Hospital and the Department of Oncology.

I wish to thank Gillian Häkli for efficiently revising the English language of the original articles and this thesis, often at very short notice.

I am sincerely indebted to my father, Laltcho Popov, MD, for initially firing my enthusiasm for surgery and, later, for never wavering in his support, faith, and interest in my research. I do so much wish you could have been here today.

Above all, I would like to say a big thank you to all those lovely people who have indirectly, some unwittingly, contributed to my work – for their support and encouragement, for stimulating conversations, for just cracking a joke or two when seriously needed or helping me out in one way or another: my mother Elvi Popov, my brother Toni Popov, Markku K, Mika P, Ville L, Kaarlo S, Maija K, Patrik L, Anne M, Jouni L, Tiina P, Jarmo N, my cousins Mika S and Kaj S, Ira K, Rauno N, Kimmo M, Deniz S, Janne

H, Tommi P and all those other splendid people I may have forgotten to mention! Without your contribution, this thesis would have been so much harder to see through to completion.

And last, but certainly not least, I warmly thank Alline Caçador Vaz for greatly facilitating the final part of this project.

This study was supported by the grants from the Leiras Research Foundation, the Finnish Medical Society Duodecim Foundation, the Irja Karvonen Foundation, the Foundation for the Finnish Cancer Institute, the Biomedicum Helsinki Foundation, Helsinki University Central Hospital, Päijät-Häme Central Hospital and the Helsinki University Central Hospital -Institute.

REFERENCES

- Abbas JS, Holyoke ED, Moore R, Karakousis CP (1981). The surgical treatment and outcome of soft tissue sarcoma. *Arch Surg* 116: 765-9.
- Ah-Weng A, Marsden JR, Sanders DSA, Waters R (2002). Dermatofibrosarcoma protuberans treated by micrographic surgery. *Br J Cancer* 87: 1386-9.
- Alektiar KM, Leung D, Zelefsky MJ, Healey JH, Brennan MF (2002). Adjuvant brachytherapy for primary high-grade soft tissue sarcoma of the extremity. *Ann Surg Oncol* 9: 48-56.
- Alektiar KM, Zelefsky MJ, Brennan MF (2000). Morbidity of adjuvant brachytherapy in soft tissue sarcoma of the extremity and superficial trunk. *Int J Radiat Oncol Biol Phys* 47: 1273-9.
- Al-Kattan KM, Breach NM, Kaplan DK, Goldstraw P (1995). Soft tissue reconstruction in thoracic surgery. *Ann Thorac Surg* 60: 1372-5.
- Al-Mulla F, Keith N, Pickford I, Going J, Birnie G (1999). Comparative genomic hybridization analysis of primary colorectal carcinomas and their synchronous metastases. *Genes Chromosomes Cancer* 24: 306-14.
- Al-Refaie WB, Ali MW, Chu DZ, Paz IB, Blair SL (2004). Clear cell sarcoma in the era of sentinel lymph node mapping. *J Surg Oncol* 87: 126-9.
- Alvegård TA, Berg NO (1989). Histopathology peer review of high-grade soft tissue sarcoma: the Scandinavian Sarcoma Group experience. *J Clin Oncol* 7:1845-51.
- Amendola BE, Amendola ME, McClatchey KD, Miller CH (1989). Radiation-associated sarcoma: a review of 23 patients with postradiation sarcoma over a 50 year period. *Am J Clin Oncol* 12: 411-5.
- American Joint Committee on Cancer (2002). *AJCC cancer staging manual*. 6th ed., Springer : New York.
- Anderson BO, Burt ME (1994). Chest wall neoplasms and their management. *Ann Thorac Surg* 58: 1774-81.
- Anthony JP, Mathes SJ, Hoffman WY (1993). Immediate flap coverage in the treatment of large surgical defects after tumor resection. *Surg Gynecol Obstet* 176: 355-9.
- Arnaud EJ, Perrault M, Revol M, Servant J-M, Banzet P (1997). Surgical treatment of dermatofibrosarcoma protuberans. *Plast Reconstr Surg* 100: 884-95.
- Arnold PG, Pairolo PC (1996). Chest-wall reconstruction: An account of 500 consecutive patients. *Plast Reconstr Surg* 98: 804-10.
- Balázs M, Ádám Z, Treszl A, Bégány Á, Hunyadi J, Ádány R (2001). Chromosomal imbalances in primary and metastatic melanomas revealed by comparative genomic hybridization. *Cytometry* 46: 222-32.
- Baliski CR, Schachar NS, McKinnon G, Stuart GC, Temple WJ (2004). Hemipelvectomy: a changing perspective for a rare procedure. *Can J Surg* 47: 99-103.
- Ballo MT, Zagars GK, Pisters P, Pollack A (1998). The role of radiation therapy in the management of dermatofibrosarcoma protuberans. *Int J Radiat Oncol Biol Phys* 40: 823-7.
- Bauer HC, Trovik CS, Alvegard TA, Berlin O, Erlanson M, Gustafson P, Klepp R, Moller TR, Rydholm A, Saeter G, Wahlström O, Wiklund T (2001). Monitoring referral and treatment in soft tissue sarcoma: study based on 1,851 patients from the Scandinavian Sarcoma Group Register. *Acta Orthop Scand* 72: 150-9.
- Benckhuijsen C, Kroon BBR, Van Geel AN, Wieberdink J (1988). Regional perfusion treatment with melphalan for melanoma in a limb: evaluation of drug kinetics. *Eur J Surg Oncol* 14: 157-63.
- Bendix-Hansen K, Myhre-Jensen O, Kaae S (1983). Dermatofibrosarcoma protuberans: a clinico-pathologic study of nineteen cases and review of world literature. *Scand J Plast Reconstr Surg* 17: 247-52.

- Bentz BG, Singh B, Woodruff J, Brennan M, Shah JP, Kraus D (2004). Head and neck soft tissue sarcomas: a multivariate analysis of outcomes. *Ann Surg Oncol* 11:619-28.
- Bhagia SM, Elek EM, Grimer RJ, Carter SR, Tillman RM (1997). Forequarter amputation for high-grade malignant tumours of the shoulder girdle. *J Bone Joint Surg* 79-B: 924-26.
- Billingsley KG, Burt ME, Jara E, Ginsberg RJ, Woodruff JM, Leung DH, Brennan MF (1999). Pulmonary metastases from soft-tissue sarcoma: analysis of patterns of disease and postmetastasis survival. *Ann Surg* 229: 602-12.
- Bissig H, Richter J, Desper R, Meier V, Schraml P, Schäffer A, Sauter G, Mihatsch M, Moch H (1999). Evaluation of the clonal relationship between primary and metastatic renal cell carcinoma by comparative genomic hybridization. *Am J Pathol* 155: 267-74.
- Blazer DG 3rd, Sabel MS, Sondak VK (2003). Is there a role for sentinel lymph node biopsy in the management of sarcoma? *Surg Oncol* 12: 201-6.
- Bockmühl U, You X, Pacyna-Gengelbach M, Arps H, Draf W, Petersen I (2004). CGH pattern of esthesioneuroblastoma and their metastases. *Brain Pathol* 14: 158-63.
- Borden EC, Baker LH, Bell RC, Bramwell V, Demetri GD, Eisenberg BL, Fletcher JA, Ladanyi M, Meltzer P, O'Sullivan B, Parkinson DR, Pisters PWT, Saxman S, Singer S, Sundaram M, van Oosterom AT, Verweij J, Waalen J, Weiss SW, Brennan MF (2003). Soft tissue sarcomas of adults: State of the translational science. *Clin Cancer Res* 9: 1941-56.
- Bowne WB, Antonescu CR, Leung DHY, Katz SC, Hawkins WG, Woodruff JM, Brennan MF, Lewis JJ (2000). Dermatofibrosarcoma protuberans. A clinicopathologic analysis of patients treated and followed at a single institution. *Cancer* 88: 2711-20.
- Brisset S, Schleiermacher G, Peter M, Mairal A, Oberlin O, Delattre O, Aurias A (2001). CGH analysis of secondary genetic changes in Ewing tumors: correlation with metastatic disease in a series of 43 cases. *Cancer Genet Cytogenet* 130: 57-61.
- Broders AC, Hargrave R, Meyerding HW (1939). Pathologic features of soft tissue fibrosarcoma. *Surg Gynecol Obstet* 69: 267-80.
- Bui DT, Chunilal A, Mehrara BJ, Disa JJ, Alektiar KM, Cordeiro PG (2004). Outcome of split-thickness skin grafts after external beam radiotherapy. *Ann Plast Surg* 52:551-6.
- Burt M, Fulton M, Wessner-Dunlap S, Karpeh M, Huvos AG, Bains MS, Martini N, McCormack PM, Rusch VW, Ginsberg RJ (1992). Primary bony and cartilaginous sarcomas of the chest wall: Results of therapy. *Ann Thorac Surg* 54: 226-32.
- Butler CE (2004). Reconstruction of an extensive hemipelvectomy defect using a pedicled upper and lower leg incontinuity fillet flap. *Plast Reconstr Surg* 109: 1060-5.
- Cafee HH (1983). Reconstruction of the abdominal wall by variations of the tensor fasciae latae flap. *Plast Reconstr Surg* 71: 348.
- Campbell DA (1950). Reconstruction of the anterior thoracic wall. *J Thorac Surg* 19: 456.
- Cany L, Stoeckle E, Coindre JM, Kantor G, Bonichon F, Bui BN (1999). Prognostic factors in superficial adult soft tissue sarcomas: analysis of a series of 105 patients. *J Surg Oncol* 71: 4-9.
- Cara JA, Lacleriga AE, Canadell J (1993). Iliac allograft used for sternal reconstruction after resection of a chondrosarcoma. *Int Orthop* 17: 297-9.
- Casson AG, Putnam JB, Natarajan G, Johnston JA, Mountain C, McMurtrey M, Roth JA (1992). Five-year survival after pulmonary metastasectomy for adult soft tissue sarcoma. *Cancer* 69: 662-8.
- Chang CK, Jacobs IA, Salti GI (2004). Outcomes of surgery for dermatofibrosarcoma protuberans. *Eur J Surg Oncol* 30 (3): 341-5.
- Chang RR, Mehrara BJ, Hu QY, Disa JJ, Cordeiro PG (2004). Reconstruction of complex oncologic chest wall defects. A 10-year experience. *Ann Plast Surg* 52: 471-9.

- Chang Y, Cesarman E, Pessin MS, Lee F, Culpepper J, Knowles DM, Moore PS (1994). Identification of herpesvirus-like DNA sequences in AIDS-associated Kaposi's sarcoma. *Science* 266: 1865-9.
- Chao C, Goldberg M (2000). Surgical treatment of metastatic pulmonary soft-tissue sarcoma. *Oncology (Huntingt)* 14: 835-41.
- Chapelier AR, Bacha EA, de Montpreville VT, Dulmet EM, Rietjens M, Margulis A, Macchiarini P, Darteville PG (1997). Radical resection of radiation-induced sarcoma of the chest wall: Report of 15 cases. *Ann Thorac Surg* 63: 214-19.
- Chevray PM, Singh NK (2003). Abdominal wall reconstruction with the free tensor fascia lata musculofasciocutaneous flap using intraperitoneal gastroepiploic recipient vessels. *Ann Plast Surg* 51: 97-102.
- Choi S, Schwartz DL, Farwell G, Austin-Seymour M, Futran N (2004). Radiation therapy does not impact local complication rates after free flap reconstruction for head and neck cancer. *Arch Otolaryngol Head Neck Surg* 130: 1308-12.
- Choong PFM, Petersen IA, Nascimento AG, Sim FH (2001). Is radiotherapy important for low-grade soft tissue sarcoma of the extremity? *Clin Orthop Rel Res* 387: 191-99.
- Clark MA, Thomas JM (2003). Major amputation for soft-tissue sarcoma. *Br J Surg* 90:102-7.
- Clasby R, Tilling K, Smith MA, Fletcher CD (1997). Variable management of soft tissue sarcoma: regional audit with implications for specialist care. *Br J Surg* 84: 1692-96.
- Cohen M, Ramasastry SS (1996). Reconstruction of complex chest wall defects. *Am J Surg* 172: 35-40.
- Coindre JM, Terrier P, Bui NB, Bonichon F, Collin F, Le Doussal V, Mandard AM, Vilain MO, Jacquemier J, Duplay H, Sastre X, Barlier C, Henry-Amar M, Mace-Lesech J, Contesso G (1996). Prognostic factors in adult patients with locally controlled soft tissue sarcoma. A study of 546 patients from the French Federation of Cancer Centers Sarcoma Group. *J Clin Oncol* 14: 869-77.
- Cordeiro PG, Cohen S, Burt M, Brennan MF (1998). The total volar forearm musculocutaneous free flap for reconstruction of extended forequarter amputations. *Ann Plast Surg* 40: 388-96.
- Cordeiro PG, Neves RI, Hidalgo DA (1994). The role of free tissue transfer following oncologic resection in lower extremity. *Ann Plast Surg* 33: 9-16.
- Cordeiro PG, Santamaria E, Hidalgo D (2001). The role of microsurgery in reconstruction of oncologic chest wall defects. *Plast Reconstr Surg* 108: 1924-30.
- Creech OJ, Kremenz ET, Ryan RF, Winblad JN (1958). Chemotherapy of cancer: Regional perfusion utilizing an extracorporeal circuit. *Ann Surg* 148: 616-32.
- Dahlstrom KK, Andersson AP, Andersen M, Krag C (1993). Wide local excision of recurrent breast cancer in the thoracic wall. *Cancer* 72: 774-77.
- Davis AM, O'Sullivan B, Bell RS, Turcotte R, Catton CN, Wunder JS, Chabot P, Hammond A, Benk V, Isler M, Freeman C, Goddard K, Bezjak A, Kandel RA, Sadura A, Day A, James K, Tu D, Pater J, Zee B (2002). Function and health status outcomes in a randomized trial comparing preoperative and postoperative radiotherapy in extremity soft tissue sarcoma. *J Clin Oncol* 20: 4472-77.
- Demetri GD, Pollock R, Baker L, Balcerzak S, Casper E, Conrad C, Fein D, Hutchinson R, Schupak K, Spiro I, Wagman L (1998). NCCN sarcoma practice guidelines. National Comprehensive Cancer Network. *Oncology (Huntingt)* 12: 183-218.
- Deschamps C, Tirnaksiz BM, Darbandi R, Trastek VF, Allen MS, Miller DL, Arnold PG, Pairolero PC (1999). Early and long-term results of prosthetic chest wall reconstruction. *J Thorac Cardiovasc Surg* 117: 588-92.

- Diaz-Cascajo C, Weyers W, Rey-Lopez A, Borghi S (1998). Deep dermatofibrosarcoma protuberans: A subcutaneous variant. *Histopathology* 32: 552-55.
- Dinges S, Budach V, Budach W, Feldmann HJ, Stuschke M, Sack H (1994). Local recurrences of soft tissue sarcomas in adults: a retrospective analysis of prognostic factors in 102 cases after surgery and radiation therapy. *Eur J Cancer* 30A: 1636-42.
- Doi K, Kuwata N, Kawakami F, Hattori Y, Otsuka K, Ihara K (1999). Limb-sparing surgery with reinnervated free-muscle transfer following radical excision of soft-tissue sarcoma in the extremity. *Plast Reconstr Surg* 104: 1679-87.
- Downey RJ, Rusch V, Hsu FI, Leon L, Venkatraman E, Linehan D, Bains M, van Zee K, Korst R, Ginsberg R (2000). Chest wall resection for locally recurrent breast cancer: Is it worthwhile? *J Thorac Cardiovasc Surg* 119: 420-28.
- DuBay D, Cimmino V, Lowe L, Johnson TM, Sondak VK (2004). Low recurrence rate after surgery for dermatofibrosarcoma protuberans. A multidisciplinary approach from a single institution. *Cancer* 100: 1008-16.
- Earle AS, Feng LJ, Jordan RB (1990). Long saphenous vein grafts as an aid to microsurgical reconstruction of the trunk. *J Reconstr Microsurg* 6: 165-69.
- Eggermont AMM, Koops HS, Klausner JM, Kroon BB, Schlag PM, Lienard D, van Geel AN, Hoekstra HJ, Meller I, Nieweg OE, Kettelhack C, Ben-Ari G, Pector JC, Lejeune FJ (1996). Isolated limb perfusion with tumor necrosis factor and melphalan for limb salvage in 186 patients with locally advanced soft tissue extremity sarcomas. The cumulative multicenter european experience. *Ann Surg* 224: 756-65.
- El-Rifai W, Larramendy M, Björkqvist A-M, Hemmer S, Knuutila S (1997). Optimization of comparative genomic hybridization using fluorochrome conjugated to dCTP and dUTP nucleotides. *Lab Invest* 77:699-700.
- Enneking WF, Spanier SS, Goodman MA (1980). A system for the surgical staging of musculoskeletal sarcoma. *Clin Orthop* (153): 106-28.
- Enneking WF, Spanier SS, Goodman MA (2003). A system for the surgical staging of musculoskeletal sarcoma. 1980. *Clin Orthop Relat Res.* 2003 (415): 4-18.
- Enneking WF, Spanier SS, Malawer MM (1981). The effect of the anatomic setting on the results of surgical procedures for soft parts sarcoma of the thigh. *Cancer* 47: 1005-22.
- Evans DM, Williams WJ, Jung IT (1983). Angiosarcoma and hepatocellular carcinoma in vinyl chloride workers. *Histopathology* 7: 377-88.
- Evans GR, Black JJ, Robb GL, Baldwin BJ, Kroll SS, Miller MJ, Reece GP, Schusterman MA (1997). Adjuvant therapy: The effects on microvascular lower extremity reconstruction. *Ann Plast Surg* 39: 141-44.
- Facciolo F, Cardillo G, Lopergolo M, Pallone G, Sera F, Martelli M (2001). Chest wall invasion in non-small cell lung carcinoma: a rationale for en bloc resection. *J Thorac Cardiovasc Surg* 121: 649-56.
- Faneyte IF, Rutgers EJ, Zoetmulder FA (1997). Chest wall resection in the treatment of locally recurrent breast carcinoma. Indications and outcome for 44 patients. *Cancer* 80: 886-91.
- Finnish Cancer Registry (2004). Cancer statistics in Finland at www.cancerregistry.fi, last updated on 21.8.2004.
- Fletcher CDM, Unni KK, Mertens F (Eds.) (2002). *World Health Organization Classification of Tumours. Pathology and Genetics of Tumours of Soft Tissue and Bone.* IARC Press: Lyon.
- Fong Y, Coit DG, Woodruff JM, Brennan MF (1993). Lymph node metastasis from soft tissue sarcoma in adults: analysis of data from a prospective database of 1772 sarcoma patients. *Ann Surg* 217: 72-77.
- Freedman AM, Meland NB (1989). Arteriovenous shunts in free vascularized tissue transfer for extremity reconstruction. *Ann Plast Surg* 23: 123-28.

- Frustaci S, Gherlinzoni F, De Paoli A, Bonetti M, Azzarelli A, Comandone A, Olmi P, Buonadonna A, Pignatti G, Barbieri E, Apice G, Zmerly H, Serraino D, Picci P (2001). Adjuvant chemotherapy for adult soft tissue sarcomas of the extremities and girdles: results of the Italian randomized cooperative trial. *J Clin Oncol* 19: 1238-47.
- Fuchs B, Sim FH (2004). Rotationplasty about the knee: surgical technique and anatomical considerations. *Clin Anat* 17:345-53.
- Gadd MA, Casper ES, Woodruff JM, McCormack PM, Brennan MF (1993). Development and treatment of pulmonary metastases in adult patients with extremity soft tissue sarcoma. *Ann Surg* 218: 705-12.
- Garcia-Tutor E, Yeste L, Murillo J, Auba C, Sanjulian M, Torre W (2004). Chest wall reconstruction using iliac bone allografts and muscle flaps. *Ann Plast Surg* 52: 54-60.
- Gibbs CP, Peabody TD, Mundt AJ, Montag AG, Simon MA (1997). Oncological outcomes of operative treatment of subcutaneous soft-tissue sarcomas of the extremities. *J Bone Joint Surg* 79A: 888-97.
- Gibbs JF, Lee RJ, Driscoll DL, McGrath BE, Mindell ER, Kraybill WG (2000). Clinical importance of late recurrence in soft-tissue sarcomas. *J Surg Oncol* 73: 81-86.
- Gloster HM, Harris KR, Roenigk RK (1996). A comparison between Mohs micrographic surgery and wide surgical excision for the treatment of dermatofibrosarcoma protuberans. *J Am Acad Dermatol* 35: 82-87.
- Gortzak E, Azzarelli A, Buesa J, Bramwell VHC, van Coevorden F, van Geel AN, Ezzat A, Santoro A, Oosterhuis JW, van Glabbeke M, Kirkpatrick A, Verweij J, the E.O.R.T.C. Soft Tissue Bone Sarcoma Group and the National Cancer Institute of Canada Clinical Trials Group / Canadian Sarcoma Group (2001). A randomized phase II study on neo-adjuvant chemotherapy for 'high-risk' adult soft-tissue sarcoma. *Eur J Cancer* 37: 1096-103.
- Gröhn P, Heinonen E, Santavirta S, Sandelin J, Sundell B, Holsti LR (1979). The management of soft tissue sarcomas. *Duodecim* 95: 1301-6.
- Gronchi A, Casali PG, Fiore M, Mariani L, Lo Vullo S, Bertulli R, Colecchia M, Lozza L, Olmi P, Santinami M, Rosai J (2004). Retroperitoneal soft tissue sarcomas: patterns of recurrence in 167 patients treated at a single institution. *Cancer* 100:2448-55.
- Gronwald J, Störkel S, Holtgreve-Grez H, Hadaczek P, Brinkschmidt C, Jauch A, Lubinski J, Cremer T (1997). Comparison of DNA gains and losses in primary renal clear cell carcinomas and metastatic sites: importance of 1q and 3p copy number changes in metastatic events. *Cancer Res* 57:481-87.
- Guillou L, Coindre JM, Bonichon F, Nguyen BB, Terrier P, Collin F, Vilain MO, Mandard AM, Le Doussal V, Leroux A, Jacquemier J, Duplay H, Sastre-Garau X, Costa J (1997). Comparative study of the National Cancer Institute and French Federation of Cancer Centers Sarcoma Group grading systems in a population of 410 adult patients with soft tissue sarcoma. *J Clin Oncol* 15: 350-62.
- Gustafson P, Dreinhofer KE, Rydholm A (1994). Soft tissue sarcoma should be treated at a tumor center. A comparison of quality of surgery in 375 patients. *Acta Orthop Scand* 65: 47-50.
- Haas RL, Keus RB, Loftus BM, Rutgers EJ, van Coevorden F, Bartelink H (1997). The role of radiotherapy in the local management of dermatofibrosarcoma protuberans. *Soft Tissue Tumors Working Group. Eur J Cancer* 33: 1055-60.
- Ham SJ, Schraffordt Koops H, Veth RP, van Horn JR, Eisma WH, Hoekstra HJ (1997). External and internal hemipelvectomy for sarcomas of the pelvic girdle: consequences of limb-salvage treatment. *Eur J Surg Oncol* 23: 540-46.
- Hashimoto H, Daimaru Y, Takeshita S, Tsuneyoshi M, Enjoji M (1992). Prognostic significance of histologic parameters of soft tissue sarcomas. *Cancer* 70:2816-22.

- Haycox CL, Odland PB, Olbricht SM, Casey B (1997). Dermatofibrosarcoma protuberans (DFSP): growth characteristics based on tumor modeling and a review of cases treated with Mohs micrographic surgery. *Ann Plast Surg* 38: 246-51.
- Heitmann C, Pelzer M, Menke H, Ger-
mann G (2000). The free musculocu-
taneous tensor fascia lata flap as a
backup procedure in tumor surgery.
Ann Plast Surg 45: 399-404.
- Herbert SH, Corn BV, Solin LJ, Lanciano
RM, Schultz DJ, McKenna WG, Coia
LR (1993). Limb-preserving treatment
for soft tissue sarcomas of the extremi-
ties. The significance of surgical mar-
gins. *Cancer* 72: 1230-38.
- Hidalgo DA, Disa JJ, Cordeiro PG, Hu QY
(1998). A review of 716 consecutive
free flaps for oncologic surgical def-
ects: refinement in donor-site selec-
tion and technique. *Plast Reconstr
Surg* 102: 722-32.
- Hill H, Nahai F, Vasconez L (1978). The
tensor fascia lata myocutaneous free
flap. *Plast Reconstr Surg* 61: 517-22.
- Hoeber I, Spillane AJ, Fisher C, Thomas
JM (2001). Accuracy of biopsy tech-
niques for limb and limb girdle soft
tissue tumors. *Ann Surg Oncol* 8: 80-7.
- Hogendoorn P, Collin F, Daugaard S, Dei
Tos P, Fisher C, Schneider U, Sciot R
(2004). Changing concepts in the
pathological basis of soft tissue and
bone sarcoma treatment. *Eur J Cancer*
40: 1644-54.
- Hohenberger P, Allenberg JR, Schlag PM,
Reichardt P (1999). Results of surgery
and multimodal therapy for patients
with soft tissue sarcoma invading to
vascular structures. *Cancer* 85: 396-408.
- Hultman CS, Carlson GW, Losken A, Jones
G, Culbertson J, Mackay G, Bostwick J,
Jurkiewicz MJ (2002). Utility of omen-
tum in the reconstruction of complex
extraperitoneal wounds and defects.
Donor-site complications in 135 pa-
tients from 1975 to 2000. *Ann Surg*
235: 782-95.
- Huston TL, Simmons RM (2005). Locally
recurrent breast cancer after conserva-
tion therapy. *Am J Surg* 189: 229-35.
- Huth JF, Eilber FR (1988). Patterns of met-
astatic spread following resection of
extremity soft-tissue sarcomas and
strategies for treatment. *Semin Surg
Oncol* 4: 20-6.
- Incarbone M, Pastorino U (2001). Surgical
treatment of chest wall tumors. *World
J Surg* 25: 218-30.
- Issels RD, Schlemmer M (2002). Current
trials and new aspects in soft tissue
sarcoma of adults. *Cancer Chemother
Pharmacol* 49: 4-8.
- Jiang J-K, Chen Y-J, Lin C-H, Yu I-T, Lin
J-K (2005). Genetic changes and clon-
ality relationship between primary
colorectal cancers and their pulmo-
nary metastases – an analysis by com-
parative genomic hybridization. *Genes
Chrom Cancer* 43: 25-36.
- Jönsson P, Gyllstedt E, Hambraeus G, Lil-
logil R, Rydholm A (1998). Chest wall
sarcoma: outcome in 22 patients after
resection requiring thoracic cage re-
construction. *Sarcoma* 2: 143-7.
- Kallioniemi A, Kallioniemi O-P, Sudar D,
Rutovitz D, Gray JW, Waldman F, Pin-
kel D (1992). Comparative genomic
hybridization for molecular cytogenet-
ic analysis of solid tumours. *Science*
258:818-21.
- Karakousis CP, Emrich LJ, Rao U, Khalil M
(1991). Limb salvage in soft tissue sar-
comas with selective combination of
modalities. *Eur J Surg Oncol* 17: 71-80.
- Karakousis CP, Proimakis C, Rao U, Velez
AF, Driscoll DL (1996). Local recur-
rence and survival in soft-tissue sarco-
mas. *Ann Surg Oncol* 3:255-60.
- Karakousis CP, Proimakis C, Walsh DL
(1995). Primary soft tissue sarcoma of
the extremities in adults. *Br J Surg* 82:
1208-12.
- Karanas YL, Yim KK, Johannet P, Hui K,
Lineaweaver WC (1998). Use of 20 cm
or longer interposition vein grafts in
free flap reconstruction of the trunk.
Plast Reconstr Surg 101: 1262-67.
- Kasabian AK, Glat PM, Eidelman Y, Colen S,
Longaker MT, Attinger C, Shaw W
(1995). Salvage of traumatic below-knee
amputation stumps utilizing the file of
foot free flap: critical evaluation of six
cases. *Plast Reconstr Surg* 96: 1145-53.

- Kawaguchi N, Ahmed AR, Matsumoto S, Manabe J, Matsushita Y (2004). The concept of curative margin in surgery for bone and soft tissue sarcoma. *Clin Orthop* 419: 165-72.
- Khouri RK, Cooley BC, Kunselman AR, Landis JR, Yeramian P, Ingram D, Natarajan N, Benes CO, Wallemark C, International Microvascular Research Group (1998). A prospective study of microvascular free-flap surgery and outcome. *Plast Reconstr Surg* 102: 711-21.
- Kim KA, Chandrasekhar BS (1998). Cephalic vein in salvage microsurgical reconstruction in the head and neck. *Br J Plast Surg* 51: 2-7.
- Knuutila S, Aalto Y, Autio K, Björkqvist A-M, El-Rifai W, Hemmer S, Huhta T, Kettunen E, Kiuru-Kuhlefelt S, Larramendy ML, Lushnikova T, Monni O, Pere H, Tapper J, Tarkkanen M, Varis A, Wasenius V-M, Wolf M, Zhu Y (1999). DNA copy number losses in human neoplasms. *Am J Pathol* 155:683-94.
- Knuutila S, Björkqvist A-M, Autio K, Tarkkanen M, Wolf M, Monni O, Szymanska J, Larramendy ML, Tapper J, Pere H, El-Rifai W, Hemmer S, Wasenius V-M, Vidgren V, Zhu Y (1998). DNA copy number amplifications in human neoplasms. *Am J Pathol* 152:1107-23.
- Kogevinas M, Kauppinen T, Winkelmann R, Becher H, Bertazzi PA, Bueno-de-Mesquita HB, Coggon D, Green L, Johnson E, Littorin M (1995). Soft tissue sarcoma and non-Hodgkin's lymphoma in workers exposed to phenoxy herbicides, chlorophenols, and dioxins: Two nested case-control studies. *Epidemiology* 6: 396-402.
- Kretzler A, Molls M, Gradinger R, Lukas P, Steinau H-U, Würschmidt F (2004). Intraoperative radiotherapy of soft tissue sarcoma of the extremity. *Strahlentherapie und Onkologie* 180: 365-70.
- Kroll SS, Robb GL, Reece GP, Miller MJ, Evans GRD, Baldwin BJ, Wang B, Schusterman MA (1998). Does prior irradiation increase the risk of total or partial free-flap loss? *J Reconstr Microsurg* 14: 263-68.
- Kroll SS, Schusterman MA, Reece GP, Miller MJ, Evans GR, Robb GL, Baldwin BJ (1996). Choice of flap and incidence of free flap success. *Plast Reconstr Surg* 98:459-63.
- Kroll SS, Walsh G, Ryan B, King RC (1993). Risks and benefits of using Marlex mesh in chest wall reconstruction. *Ann Plast Surg* 31: 303-6.
- Larramendy M, Tarkkanen M, Valle J, Kivioja AH, Ervasti H, Karaharju E, Salmivalli T, Elomaa I, Knuutila S (1997). Gains, losses and amplifications of DNA sequences evaluated by comparative genomic hybridization in chondrosarcomas. *Am J Pathol* 150b:685-91.
- Larramendy M, Koljonen V, Böhling T, Tuukiainen E, Knuutila S (2004). Recurrent DNA copy number changes revealed by comparative genomic hybridization in primary Merkel cell carcinomas. *Modern Pathology* 17: 561-67.
- Lawrence W Jr, Donegan WL, Natarajan N, Mettlin C, Beart R, Winchester D (1987). Adult soft tissue sarcomas. A pattern of care of survey of the American College of Surgeons. *Ann Surg* 205: 349-59.
- Lee H-Y, Cordeiro PG, Mehrara BJ, Singer S, Alektiar KM, Hu Q-Y, Disa JJ (2004). Reconstruction after soft tissue sarcoma resection in the setting of brachytherapy. A 10-year experience. *Ann Plast Surg* 52: 486-92.
- Lehnert T, Schwarzbach M, Willeke F, Treiber M, Hinz U, Wannemacher MM, Herfarth C (2000). Intraoperative radiotherapy for primary and locally recurrent soft tissue sarcoma: morbidity and long-term prognosis. *Eur J Surg Oncol* 26: S21-4.
- Lejeune FJ, Pujol N, Liénard D, Mosimann F, Raffoul W, Genton A, Guillou L, Landry M, Chassot PG, Chiolero R, Bischof-Delaloye A, Leyvraz S, Mirimanoff RO, Bejkos D, Leyvraz PF (2000). Limb salvage by neoadjuvant isolated perfusion with TNF alpha and melphalan for non-resectable soft tissue sarcoma of the extremities. *Eur J Surg Oncol* 26: 669-78.

- LeVay J, O'Sullivan B, Catton C, Bell R, Fornasier V, Cummings B, Hao Y, Warr D, Quirt I (1993). Outcome and prognostic factors in soft tissue sarcoma in the adult. *Int J Radiat Oncol Biol Phys* 27:1091-9.
- Lewis JJ, Leung D, Espat J, Woodruff JM, Brennan MF (2000). Effect of resection in extremity soft tissue sarcoma. *Ann Surg* 231: 655-63.
- Lewis JJ, Leung D, Heslin M, Woodruff JM, Brennan MF (1997). Association of local recurrence with subsequent survival in extremity sarcoma. *J Clin Oncol* 15: 646-52.
- Lin C-H, Mardini S, Lin Y-T, Yeh J-T, Wei F-C, Chen H-C (2004). Sixty-five clinical cases of free tissue transfer using long arteriovenous fistulas or vein grafts. *J Trauma* 56: 1107-17.
- Lin P, Schupak K, Boland P, Brennan M, Healey J (1998). Pathologic femoral fracture after periosteal excision and radiation for the treatment of soft tissue sarcoma. *Cancer* 82: 2356-65.
- Linberg BE (1928). Interscapulo-thoracic resection for malignant tumors of the shoulder joint region. *J Bone Joint Surg* 44A: 1423-29.
- Lindberg RD, Martin RG, Romsdahl MM, Barkley HT Jr (1981). Conservative surgery and postoperative RT in 300 adults with soft tissue sarcomas. *Cancer* 47: 2391-7.
- Lindner NJ, Scarborough MT, Powell GJ, Spandier S, Enneking WF (1999). Revision surgery in dermatofibrosarcoma protuberans of the trunk and extremities. *Eur J Surg Oncol* 25: 392-97.
- Lohman RF, Nabawi AS, Reece GP, Pollock RE, Evans GR (2002). Soft tissue sarcoma of the upper extremity: a 5-year experience at two institutions emphasizing the role of soft tissue flap reconstruction. *Cancer* 8: 2256-64.
- Losken A, Carlson GW, Tyrone JW, Jones GE, Culbertson JH, Beegle PH jr., Elliott LF II (2005). The significance of intraabdominal compartment pressure after free versus pedicled TRAM flap breast reconstruction. *Plast Reconstr Surg* 115: 261-63.
- Losken A, Thourani VH, Carlson GW, Jones GE, Culbertson JH, Miller JJ, Mansour KA (2004). A reconstructive algorithm for plastic surgery following extensive chest wall resection. *Br J Plast Surg* 57: 295-302.
- Maki RG, Awan RA, Dixon RH, Jhanwar S, Antonescu CR (2002). Differential sensitivity to imatinib of 2 patients with metastatic sarcoma arising from dermatofibrosarcoma protuberans. *Int J Cancer* 20: 623-6.
- Mandahl N, Heim S, Arheden K, Rydholm A, Willén H, Mitelman F (1989). Separate karyotypic features in a local recurrence and a metastasis of a fibrosarcoma. *Cancer Genet Cytogenet* 37:139-40.
- Mankin HJ, Mankin CJ, Simon MA (1996). The hazards of the biopsy, revisited. Members of the Musculoskeletal Tumor Society. *J Bone Joint Surg Am* 78: 656-63.
- Mansour KA, Thourani VH, Losken A, Reeves JG, Miller JJ Jr, Carlson GW, Jones GE (2002). Chest wall resections and reconstruction: a 25-year experience. *Ann Thorac Surg* 73: 1720-25.
- Mark RJ, Poen J, Tran LM, Fu YS, Selch MT, Parker RG (1994). Postirradiation sarcomas: a single institution study and review of the literature. *Cancer* 73: 2653-62.
- Markhede G, Angervall L, Stener B (1982). A multivariate analysis of the prognosis after surgical treatment of malignant soft tissue tumors. *Cancer* 49: 1721-33.
- Mathes SJ (1995). Chest wall reconstruction. *Clin Plast Surg* 22: 187-98.
- Matsumoto S, Kawaguchi N, Manabe J, Matsushita Y (2002). "In situ preparation": new surgical procedure indicated for soft-tissue sarcoma of a lower limb in close proximity to major neurovascular structures. *Int J Clin Oncol* 7: 51-6.
- McArthur G, Demetri G, van Oosterom A, Heinrich M, Debiec-Rychter M, Corless C, Nikolova Z, Dimitrijevic S, Fletcher J (2005). Molecular and clinical analysis of locally advanced dermatofibrosarcoma protuberans treated with imatinib: imatinib target exploration

- tion consortium study B2225. *J Clin Oncol* 23: 866-73.
- McCormack (1989). Use of prosthetic materials in chest-wall reconstruction. *Surg Clin North Am* 69: 965-76.
- McClain KL, Leach CT, Jenson HB, Joshi VV, Pollock BH, Parmley RT, DiCarlo FJ, Chadwick EG, Murphy SB (1995). Association of Epstein-Barr virus with leiomyosarcomas in children with AIDS. *N Engl J Med* 332: 12-8.
- McKee MD, Liu DF, Brooks JJ, Gibbs JF, Driscoll DL, Kraybill WG (2004). The prognostic significance of margin width for extremity and trunk sarcoma. *J Surg Oncol* 85: 68-76.
- McMulkin HM, Yanchar NL, Fernandez CV, Giacomantonio C (2003). Sentinel lymph node mapping and biopsy: a potentially valuable tool in the management of childhood extremity rhabdomyosarcoma. *Pediatr Surg Int* 19: 453-6.
- McPeak CJ, Cruz T, Nicastrì AD (1967). Dermatofibrosarcoma protuberans: an analysis of 86 cases – five with metastasis. *Ann Surg* 166: 803-16.
- Meis-Kindblom JM, Bjerkehaug B, Böhling T, Domanski H, Halvorsen TB, Larsson O, Lilleng P, Myhre-Jensen O, Stenwig E, Virolainen M, Willén H, Åkerman M, Kindblom L-G (1999). Morphologic review of 1000 soft tissue sarcomas from the Scandinavian Sarcoma Group (SSG) register. The peer-review committee experience. *Acta Orthop Scand* (suppl. 285) 70:18-26.
- Mentzel T, Beham A, Katenkamp D, Dei Tos AP, Fletcher CDM (1998). Fibrosarcomatous (“high-grade”) dermatofibrosarcoma protuberans. Clinicopathologic and immunohistochemical study of a series of 41 cases with emphasis on prognostic significance. *Am J Surg Pathol* 22: 576-87.
- Midis GP, Pollock RE, Chen NP, Feig BW, Murphy A, Pollack A, Pisters PWT (1998). Locally recurrent soft tissue sarcoma of the extremities. *Surgery* 123: 666-71.
- Miettinen M (Ed.) (2003). *Diagnostic Soft Tissue Pathology*. Churchill Livingstone: Hong Kong.
- Miller SA, Dykes DD, Polesky HF (1988). A simple salting out procedure for extracting DNAs from human nucleated cells. *Nucleic Acids Res* 16: 1215.
- Naeem R, Lux ML, Huang SF, Naber SP, Corson JM, Fletcher JA (1995). Ring chromosomes in dermatofibrosarcoma protuberans are composed of interspersed sequences from chromosomes 17 and 22. *Am J Pathol* 147: 1553-58.
- Nash AG, Tuson JRD, Andrews SM, Stacey-Clear A (1991). Chest wall reconstruction after resection of recurrent breast tumours. *Ann R Coll Surg Engl* 73: 105-10.
- Nishizaki T, DeVries S, Chew K, Goodson III WH, Ljung B-M, Thor A, Waldman FM (1997). Genetic alterations in primary breast cancers and their metastases: direct comparison using modified comparative genomic hybridization. *Genes Chromosomes Cancer* 19:267-72.
- Noorda EM, Vrouenraets BC, Nieweg OE, van Coevorden F, Kroon BB (2004). Isolated limb perfusion: what is the evidence for its use? *Ann Surg Oncol* 11: 837-45.
- Noorda EM, Vrouenraets BC, Nieweg OE, van Coevorden F, van Slooten GW, Kroon BBR (2003). Isolated limb perfusion with TNF-alpha and melphalan for unresectable soft tissue sarcoma of the extremities. *Cancer* 98: 1483-90.
- O’Hare PM, Leonard AG, Brennen MD (1983). Experience with the tensor fasciae latae free flap. *Br J Plast Surg* 36: 98.
- O’Sullivan B, Davis AM, Turcotte R, Bell R, Catton C, Chabot P, Wunder J, Kandel R, Goddard K, Sadura A, Pater J, Zee B (2002). Preoperative versus postoperative radiotherapy in soft-tissue sarcoma of the limbs: a randomised trial. *Lancet* 359: 2235-41.
- Osanaï T, Kashiwa H, Ishikawa A, Takahara M, Ogino T (2005). Improved shoulder contour following forequarter amputation with an osteomyocutaneous free flap from the amputated extremity: two cases. *Br J Plast Surg* 58: 165-9.
- Pantanowitz L, Dezube BJ (2004). Advances in the pathobiology and treatment

- of Kaposi sarcoma. *Curr Opin Oncol* 16: 443-9.
- Pastorino U, Buyse M, Friedel G, Ginsberg RJ, Girard P, Goldstraw P, Johnston M, McCormack P, Pass H, Putnam JB Jr (1997). Long-term results of lung metastasectomy: prognostic analyses based on 5206 cases. *J Thorac Cardiovasc Surg* 113: 37-49.
- Perry RR, Venzon D, Roth JA, Pass HI (1992). Survival after surgical resection for high-grade chest wall sarcomas. *Ann Thorac Surg* 49: 363-9.
- Pisters PW (1998). Combined modality treatment of extremity soft tissue sarcomas. *Ann Surg Oncol* 5:464-72.
- Pisters PW, Harrison LB, Leung DH, Woodruff JM, Casper ES, Brennan MF (1996). Long-term results of a prospective randomized trial of adjuvant brachytherapy in soft tissue sarcoma. *J Clin Oncol* 14: 859-68.
- Pisters PWT, Leung DHY, Woodruff J, Shi W, Brennan MF (1996). Analysis of prognostic factors in 1,041 patients with soft tissue sarcomas of the extremities. *J Clin Oncol* 14: 1679-89.
- Porter GA, Cantor SB, Walsh GL, Rusch VW, Leung DH, DeJesus AY, Pollock RE, Brennan MF, Pisters PWT (2004). Cost-effectiveness of pulmonary resection and systemic chemotherapy in the management of metastatic soft tissue sarcoma: A combined analysis from the University of Texas M.D. Anderson and Memorial Sloan-Kettering Cancer Centers. *J Thorac Cardiovasc Surg* 127: 1366-72.
- Potter DA, Glenn J, Kinsella T, Glatstein E, Lack EE, Restrepo C, White DE, Seipp CA, Wesley R, Rosenberg SA (1985). Patterns of recurrence in patients with high-grade soft-tissue sarcomas. *J Clin Oncol* 3: 353-66.
- Price VE, Fletcher JA, Zielenska M, Cole W, Viero S, Manson DE, Stuart M, Pappo AS (2005). Imatinib mesylate: An attractive alternative in young children with large, surgically challenging dermatofibrosarcoma protuberans. *Pediatr Blood Cancer* 44: 511-15.
- Rantakokko V, Ekfors TO (1979). Sarcomas of the soft tissues in the extremities and limb girdles. Analysis of 240 cases diagnosed in Finland in 1960-1969. *Acta Chir Scand* 145: 385-94.
- Ratner D, Thomas CO, Johnson TM, Sondak VK, Hamilton TA, Nelson BR, Swanson NA, Garcia C, Clark RE, Grande DJ (1997). Mohs micrographic surgery for the treatment of dermatofibrosarcoma protuberans. *J Am Acad Dermatol* 37: 600-13.
- Ray-Coquard I, Thiesse P, Ranchere-Vince D, Chauvin F, Bobin JY, Sunyach MP, Carret JP, Mongodin B, Marec-Berard P, Philip T, Blay JY (2004). Conformity to clinical practice guidelines, multidisciplinary management and outcome of treatment for soft tissue sarcomas. *Ann Oncol* 15:307-15.
- Reece GP, Schusterman MA, Pollock RE, Kroll SS, Miller MJ, Baldwin BJ, Romsdahl MM, Janjan NA (1994). Immediate versus delayed free-tissue transfer salvage of the lower extremity in soft tissue sarcoma patients. *Ann Surg Oncol* 1: 11-17.
- Riad S, Griffin AM, Liberman B, Blackstein ME, Catton CN, Kandel RA, O'Sullivan B, White LM, Bell RS, Ferguson PC, Wunder JS (2004). Lymph node metastasis in soft tissue sarcoma in an extremity. *Clin Orthop* (426): 129-34.
- Robinson M, Barr L, Fisher C, Fryatt I, Stotter A, Harmer C, Wiltshaw E, Westbury G (1990). Treatment of extremity soft tissue sarcomas with surgery and radiotherapy. *Radiother Oncol* 18: 221-33.
- Robinson MH, Keus RB, Shasha D, Harrison LB (1998). Is preoperative radiotherapy superior to postoperative radiotherapy in the treatment of soft tissue sarcoma? *Eur J Cancer* 34: 1309-16.
- Rosenberg SA, Tepper J, Glatstein E, Costa J, Baker A, Brennan M, DeMoss EV, Seipp C, Sindelar WF, Sugarbaker P, Wesley R (1982). The treatment of soft tissue sarcomas of the extremities: Prospective randomized evaluation of (1) limb-sparing surgery plus radiation therapy compared with amputation and (2) the role of adjuvant chemotherapy. *Ann Surg* 196: 305-15.

- Roses DF, Valensi Q, La Trenta G, Harris MN (1986). Surgical treatment of dermatofibrosarcoma protuberans. *Surg Gynecol Obstet* 162: 449-52.
- Ross DA, Lohman RF, Kroll SS, Yasko AW, Robb GL, Evans GRD, Miller MJ (1998). Soft tissue reconstruction after hemipelvectomy. *Am J Surg* 176: 25-29.
- Roy P, Clark MA, Thomas JM (2004). Stewart-Treves syndrome - treatment and outcome in six patients from a single centre. *Eur J Surg Oncol* 30: 982-86.
- Rubin BP, Schuetze SM, Eary JF, Norwood TH, Mirza S, Conrad EU, Bruckner JD (2002). Molecular targeting of platelet-derived growth factor B by imatinib mesylate in a patient with metastatic dermatofibrosarcoma protuberans. *J Clin Oncol* 20: 3586-91.
- Rutgers EJ, Kroon BB, Albus-Lutter CE, Gortzak E (1992). Dermatofibrosarcoma protuberans: treatment and prognosis. *Eur J Surg Oncol* 18: 241-48.
- Rydholm A (1983). Management of patients with soft tissue tumors: strategy developed at a regional oncology center. *Acta Orthop Scand Suppl* 203: 13-77.
- Rydholm A, Gustafson P, Rooser B, Willen H, Akerman M, Herrlin K, Alvegard T (1991). Limb sparing surgery without radiotherapy based on anatomic location of soft tissue sarcoma. *J Clin Oncol* 9: 1757-65.
- Rydholm A, Rooser B, Persson BM (1986). Primary myectomy for sarcoma. *J Bone Joint Surg (Am)* 68: 586-89.
- Sabanathan S, Shah R, Mearns JA (1997). Surgical treatment of primary malignant chest wall tumours. *Eur J Cardiothor Surg* 11: 1011-16.
- Sadoski C, Suit HD, Rosenberg A, Mankin H, Efirid J (1993). Preoperative radiation, surgical margins, and local control of extremity sarcomas of soft tissues. *J Surg Oncol* 52: 223-30.
- Salemark L (1991). International survey of current microvascular practices in free tissue transfer and replantation surgery. *Microsurgery* 12:308-11.
- Sambrook J, Fritsch EF, Maniatis T (1989). Molecular cloning. A laboratory manual. Cold Spring Harbor Laboratory Press: New York.
- Samuels L, Granick MS, Ramasastry S, Solomon MP, Hurwitz D (1993). Reconstruction of radiation-induced chest wall lesions. *Ann Plast Surg* 31: 399-405.
- Sarcoma Meta-analysis Collaboration (2000). Adjuvant chemotherapy for localized resectable soft tissue sarcoma in adults. *Cochrane Database Syst Rev* (4):CD001419.
- Schwendel A, Langreck H, Reichel M, Schröck E, Ried T, Dietel M, Petersen I (1997). Primary small-cell lung carcinomas are characterized by a recurrent pattern of genetic alterations. *Int J Cancer* 74:86-93.
- Shiba E, Koyama H, Noguchi S, Miyauchi K, Kodama K, Doi O, Nishizawa Y, Iwanaga T, Terasawa T (1988). Reconstruction of the chest wall after full thickness resection: A comparison between myocutaneous flap and acrylic resin plate as reconstructive techniques. *Int Surg* 73: 102-6.
- Shiu MH, Castro EB, Hajdu SI, Fortner JG (1975). Surgical treatment of 297 soft tissue sarcomas of the lower extremity. *Ann Surg* 182: 597-602.
- Siemionow M, Sari A (2004). A contemporary overview of peripheral nerve research from the Cleveland Clinic microsurgery laboratory. *Neurol Res* 26:218-25.
- Simon MP, Pedeutour F, Sirvent N, Grosgeorge J, Minoletti F, Coindre JM, Terrier-Lacombe MJ, Mandahl N, Craver RD, Blin N, Sozzi G, Turc-Carel C, O'Brien KP, Kedra D, Fransson I, Guildbaud C, Dumanski JP (1997). Deregulation of the platelet derived growth factor B-chain via fusion with collagen gene COL1A1 in dermatofibrosarcoma protuberans and giant cell fibroblastoma. *Nat Genet* 15: 95-98.
- Sindelar WF, Kinsella TJ, Chen PW, DeLaney TF, Tepper JE, Rosenberg SA, Glatstein E (1993). Intraoperative radiotherapy in retroperitoneal sarcomas. Final results of a prospective, randomized, clinical trial. *Arch Surg* 128: 402-10.

- Sirvent N, Maire G, Pedeutour F (2003). Genetics of dermatofibrosarcoma protuberans family of tumors: from ring chromosomes to tyrosine kinase inhibitor treatment. *Genes Chromosomes Cancer* 37: 1-19.
- Smeets NW, Krekels GA, Ostertag JU, Essers BA, Dirksen CD, Nieman FH, Neumann HA (2004). Surgical excision vs Mohs' micrographic surgery for basal cell carcinoma of the face: randomised controlled trial. *Lancet* 363:1766-72.
- Smola MG, Soyer HP, Scharnagl E (1991). Surgical treatment of dermatofibrosarcoma protuberans. A retrospective study of 20 cases with review of literature. *Eur J Surg Oncol* 17: 447-53.
- Snow SN, Gordon EM, Larson PO, Bagheri MM, Bentz ML, Sable DB (2004). Dermatofibrosarcoma protuberans: a report on 29 patients treated by Mohs micrographic surgery with long-term follow-up and review of the literature. *Cancer* 101 (1): 28-38
- Spierer MM, Alektiar KM, Zelefsky MJ, Brennan MF, Cordeiro PG (2003). Tolerance of tissue transfers to adjuvant radiation therapy in primary soft tissue sarcoma of the extremity. *Int J Radiat Oncol Biol Phys* 56: 1112-16.
- Stefanovski PD, Bidoli E, De Paoli A, Buonadonna A, Boz G, Libra M, Morassut S, Rossi C, Carbone A, Frustaci S (2002). Prognostic factors in soft tissue sarcomas: a study of 395 patients. *Eur J Surg Oncol* 28:153-64.
- Stewart FW, Treves M (1948). Lymphangiosarcoma in postmastectomy lymphedema. *Cancer* 1: 64-81.
- Strander H, Turesson I, Cavallin-Ståhl E (2003). A systematic overview of radiation therapy effects in soft tissue sarcomas. *Acta Oncologica* 42: 516-31.
- Struski S, Doco-Fenzy M, Cornillet-Lefebvre P (2002). Compilation of published comparative genomic hybridization studies. *Cancer Gen Cytogen* 135: 63-90.
- Sugarbaker PH, Malawer MM (1992). Shoulder girdle resections: The Tikhoff-Linberg procedure and its modifications. P.H. Sugarbaker, and M.M. Malawer (Eds.), *Musculoskeletal surgery for cancer: principles and techniques*, 1st ed. Thieme Medical Publishers: New York p. 346-60.
- Suit HD, Mankin HJ, Wood WC, Gebhardt MC, Harmon DC, Rosenberg A, Tepper JE, Rosenthal D (1988). Treatment of the patient with stage M0 soft tissue sarcoma. *J Clin Oncol* 6: 854-62.
- Tadjalli HE, Evans GRD, Gürlek A, Beller TC, Ang KK, Stephens LC (1999). Skin graft survival after external beam irradiation. *Plast Reconstr Surg* 7: 1902-8.
- Tarkkanen M, Huuhtanen R, Virolainen M, Wiklund T, Asko-Seljavaara S, Tukiainen E, Lepäntalo M, Elomaa I, Knuutila S (1999). Comparison of genetic changes in primary sarcomas and their pulmonary metastases. *Genes Chromosomes Cancer* 25:323-31.
- Thunnissen FB, Peterse JL, van Pel R, Jansen JW, Ladde BE, Arends JW, Volovics A (1993). Reliability of fine needle aspiration cytology for distinguishing between carcinoma, lymphoma and sarcoma; the influence of clinical information. *Cytopathology* 4: 107-14.
- Tran NV, Evans GR, Kroll SS, Miller MJ, Reece GP, Ainslie N, Robb GL (2000). Free flap extremity flap: indications and options for reconstruction. *Plast Reconstr Surg* 105: 99-104.
- Trovik CS, Bauer FCF, Alvegård TA, Andersson H, Blomqvist C, Berlin Ö, Gustafson P, Sæter G, Wallöe A (2000). Surgical margins, local recurrence and metastasis in soft tissue sarcomas: 559 surgically-treated patients from the Scandinavian Sarcoma Group Register. *Eur J Cancer* 36: 710-16.
- Trovik CS, Bauer HCF, Berlin Ö, Tukiainen E, Erlanson M, Gustafson P, Klepp R, Sæter G, Wahlström O (2001). Local recurrence of deep-seated, high-grade, soft tissue sarcoma. *Acta Orthop Scand*. 72: 160-66.
- Trovik CS, Gustafson P, Bauer HCF, Sæter G, Klepp R, Berlin Ö, Erlanson M, Wahlström O, Raabe N (2000). Consequences of local recurrence of soft tissue sarcoma. 205 patients from the Scandinavian Sarcoma Group register. *Acta Orthop Scand* 71: 488-95.

- Tuomisto JT, Pekkanen J, Kiviranta H, Tukiainen E, Vartiainen T, Tuomisto J (2004). Soft-tissue sarcoma and dioxin: A case-control study. *Int J Cancer* 108: 893-900.
- Van Geel AN, Pastorino U, Jauch KW, Judson IR, van Coevorden F, Buesa JM, Nielsen OS, Boudinet A, Tursz T, Schmitz PIM (1996). Surgical treatment of lung metastases. The European Organization for Research and Treatment of Cancer – Soft-Tissue and Bone Sarcoma Group study of 255 patients. *Cancer* 77: 675-82.
- Van Nes CP (1950). Rotationplasty of congenital defects of the femur. *J Bone Joint Surg* 32B: 12-16.
- Van Putte BP, Hendriks JM, Romijn S, Van Schil PE (2003). Isolated lung perfusion for the treatment of pulmonary metastases current mini-review of work in progress. *Surg Oncol* 12:187-93.
- Vandeweyer E, Nogaret JM, Hertens D, De-raemaecker R (2002). Chest coverage and reconstruction after recurrence of breast cancer. *Eur J Plast Surg* 25: 7-10.
- Verazin GT, Warneke JA, Driscoll DL, Karakousis C, Petrelli NJ, Takita H (1992). Resection of lung metastases from soft tissue sarcomas. A multivariate analysis. *Arch Surg* 127: 1407-11.
- Violainen P, Aitasalo K (2002). Effect of postoperative irradiation on free skin flaps: an experimental study in rats. *Scand J Plast Reconstr Surg Hand Surg* 36: 257-61.
- Visakorpi T, Kallioniemi AH, Syvänen A-C, Hyytinen ER, Karhu R, Tammela T, Isola JJ, Kallioniemi O-P (1995). Genetic changes in primary and recurrent prostate cancer by comparative genomic hybridization. *Cancer Res* 55:342-47.
- Voggenreiter G, Assenmacher S, Schmitz-Neuerburg K-P (1999). Tikhoff-Linberg procedure for bone and soft tissue tumors of the shoulder girdle. *Arch Surg* 134: 252-57.
- Vraa S, Keller J, Nielsen OS, Sneppen O, Jurik AG, Jensen OM (1998). Prognostic factors in soft tissue sarcomas: The Aarhus Experience. *Eur J Cancer* 34: 1876-82.
- Wagensteen OH (1934). Repair of recurrent and difficult hernias and other large defects of the abdominal wall employing the iliotibial tract of fascia lata as a pedicled flap. *Surg Gynecol Obstet* 59: 766.
- Waldman FM, DeVries S, Chew KL, Moore II DH, Kerlikowske K, Ljung B-M (2000). Chromosomal alterations in ductal carcinomas in situ and their in situ recurrences. *J Natl Cancer Inst* 92: 313-20.
- Walsh GL, Davis BM, Swisher SG, Vaporciyan AA, Smythe WR, Willis-Merriman K, Roth JA, Putnam JB Jr (2001). A single-institutional, multidisciplinary approach to primary sarcomas involving the chest wall requiring full-thickness resections. *J Thorac Cardiovasc Surg* 121: 48-60.
- Weiss SW, Goldblum JR (Eds.) (2001). *Enzinger and Weiss's Soft Tissue Tumors*. Mosby: United States.
- Welker JA, Henshaw RM, Jelinek J, Shmookler BM, Malawer MM (2000). The percutaneous needle biopsy is safe and recommended in the diagnosis of musculoskeletal masses. *Cancer* 89: 2677-86.
- Weng W, Lerner M, Grandner D, Ahlen J, Villablanca A, Pang S, Wejde J, Lui W, Larsson C (2005). Loss of chromosome 13q is a frequently acquired event in genetic progression of soft tissue sarcomas in the abdominal cavity. *Int J Oncol* 26: 5-16.
- West RB, Harvell J, Linn SC, Liu CL, Prapong W, Hernandez-Boussard T, Montgomery K, Nielsen TO, Rubin BP, Patel R, Goldblum JR, Brown PO, van de Rijn M (2004). Apo D in soft tissue tumors: a novel marker for dermatofibrosarcoma protuberans. *Am J Surg Pathol* 28 (8): 1063-9.
- Wiklund T, Blomqvist C, Rätty J, Elomaa I, Rissanen P, Miettinen M (1991). Postirradiation sarcoma. Analysis of a nationwide cancer registry material. *Cancer* 68: 524-31.
- Wiklund T, Huuhtanen R, Blomqvist C, Tukiainen E, Violainen M, Virkkunen P, Asko-Seljavaara S, Bjorkenheim JM, Elomaa I (1996). The importance of a

- multidisciplinary group in the treatment of soft tissue sarcomas. *Eur J Cancer* 32A: 269-73.
- Wilkens L, Bredt M, Flemming P, Kubicka S, Klempnauer J, Kreipe H (2000). Cytogenetic aberrations in primary and recurrent fibrolamellar hepatocellular carcinoma detected by comparative genomic hybridization. *Am J Clin Pathol* 114: 867-74.
- Williams JK, Carlson GW, Howell RL, Wagner JD, Nahai F, Coleman JJ (1997). The tensor fascia lata free flap in abdominal-wall reconstruction. *J Reconstr Microsurg* 13: 83-90.
- Windhager R, Millesi H, Kotz R (1995). Resection-replantation for primary malignant tumours of the arm. An alternative to fore-quarter amputation. *J Bone Joint Surg Br* 77:176-84.
- Wodajo FM, Bickels J, Wittig J, Malawer M (2003). Complex reconstruction in the management of extremity sarcomas. *Curr Opin Oncol* 15: 304-12.
- Wunder JS, Healey JH, Davis AM, Brennan MF (2000). A comparison of staging systems for localized extremity soft tissue sarcoma. *Cancer* 88: 2721-30.
- Wysocki WM, Komorowski AL, Kolodziejwski LS (2004). Microvascular reconstructions of full-thickness oncological chest wall defects. *Ann Surg* 240:558-9; author reply 559.
- Yang JC, Chang AE, Baker AR, Sindelar WF, Danforth DN, Topalian SL, DeLaney T, Glatstein E, Steinberg SM, Merino MJ, Rosenberg SA (1998). Randomized prospective study of the benefit of adjuvant radiation therapy in the treatment of soft tissue sarcomas of the extremity. *J Clin Oncol* 16: 197-203.
- Zagars GK, Ballo MT, Pisters PW, Pollock RE, Patel SR, Benjamin RS (2003). Prognostic factors for disease-specific survival after first relapse of soft-tissue sarcoma: analysis of 402 patients with disease relapse after initial conservative surgery and radiotherapy. *Int J Radiat Oncol Biol Phys.* 57:739-47.
- Zagars GK, Ballo MT, Pisters PW, Pollock RE, Patel SR, Benjamin RS, Evans HL (2003). Prognostic factors for patients with localized soft-tissue sarcoma treated with conservation surgery and radiation therapy: an analysis of 1225 patients. *Cancer* 97:2530-43.
- Zahm SH, Fraumeni JF Jr (1997). The epidemiology of soft tissue sarcoma. *Semin Oncol* 24: 504-14.
- Örndal C, Mandahl N, Willén H, Carlen B, Heim S, Mitelman F (1993). Cytogenetic heterogeneity and clonal evolution in a recurrent fibrosarcoma. *J Exp Clin Cancer Res* 12:23-31.
- Örndal C, Mandahl N, Willén H, Rydholm A, Mitelman F (1993). Cytogenetic evolution in primary tumors, local recurrences, and pulmonary metastases of two soft tissue sarcomas. *Clin Exp Metastasis* 11:401-8.