



UNIVERSITY OF HELSINKI

<https://helda.helsinki.fi>

## **Long-term outcomes of lymphatic malformations in children : An 11-year experience from a tertiary referral center**

**Hyvönen, Hanna; Salminen, Päivi; Kyrklund, Kristiina**

**2022-12**

W.B. Saunders

<http://hdl.handle.net/10138/354766>

Hyvönen, H, Salminen, P & Kyrklund, K 2022, 'Long-term outcomes of lymphatic malformations in children : An 11-year experience from a tertiary referral center', *Journal of Pediatric Surgery*, vol. 57, no. 12, pp. 1005-1010. <https://doi.org/10.1016/j.jpedsurg.2022.07.024>

Downloaded from Helda, University of Helsinki institutional repository. <https://helda.helsinki.fi>  
This is an electronic reprint of the original article.  
This reprint may differ from the original in pagination and typographic detail.  
Please cite the original version.



# Long-term outcomes of lymphatic malformations in children: An 11-year experience from a tertiary referral center

Hanna Hyvönen<sup>a,\*</sup>, Päivi Salminen<sup>a,b</sup>, Kristiina Kyrklund<sup>a,b</sup>

<sup>a</sup> New Children's Hospital, Department of Pediatric Surgery, Helsinki University Hospital and University of Helsinki, Stenbäckinkatu 9, 00029 HUS, Helsinki, Finland

<sup>b</sup> Rare Disease Centre, Department of Pediatric Surgery, Helsinki University Hospital and University of Helsinki, Finland; VASCERN VASCA European Reference Centre, Stenbäckinkatu 9, 00029 HUS, Helsinki, Finland



## ARTICLE INFO

### Article history:

Received 9 February 2022

Revised 5 July 2022

Accepted 28 July 2022

### Keywords:

Lymphatic malformation

Treatment

Sclerotherapy

Surgery

Spontaneous resolution

## ABSTRACT

**Background:** Lymphatic malformations (LMs) are benign, congenital lesions that display considerable heterogeneity in terms of size, location and characteristics. This study aims to describe the long-term outcomes of current management strategies for patients with simple (cystic) LMs.

**Methods:** The case records of all patients (age  $\leq 16$  years) with simple (cystic) LMs at our tertiary institution between 2008 and 2019 were assessed for clinical features, imaging and details of management, including complications.

**Results:** Of a total of 164 patients (60% male), 66% were diagnosed aged  $< 2$  years. The median follow-up was 5 (0.3–16) years from diagnosis. LMs were located in the head and neck (40%), extremities (27%), trunk (23%), mediastinum (4%), or intra-abdominally (6%). Types were macrocystic in 47%, microcystic in 21% and mixed in 32%. Sclerotherapy was the most common intervention (38%). Primary surgery had been performed in 12%. Symptomatic improvement, reduction in size, or complete regression were observed in 82/102 (80%) of LMs after interventions; complications from treatment were uncommon (Clavien-Dindo grade I–II: 6%; grade III–IIIId: 1%). Sixty-two patients (38%; median age 0.5 (range, 0–12) years) had not required interventions to date; spontaneous regression of the LM occurred in 16 (26%) of these expectantly followed-up cases.

**Conclusions:** Most studies to date have focused on LMs in selected anatomical locations. Herein the outcomes of an entire population from a single tertiary unit of patients are presented, demonstrating the wide heterogeneity of simple (cystic) LMs and highlighting the importance of individualized, multidisciplinary approaches to care in achieving optimal outcomes.

© 2022 The Authors. Published by Elsevier Inc.

This is an open access article under the CC BY-NC-ND license (<http://creativecommons.org/licenses/by-nc-nd/4.0/>)

## 1. Introduction

Lymphatic malformations (LMs) are benign congenital vascular anomalies with an estimated incidence of 1:6000 to 1:16,000 [1]. The International Society for the Study of Vascular Anomalies (ISSVA) classifies LMs into macrocystic, microcystic and mixed macro- and microcystic malformations [2]. The most common sites are in the head and neck region and where there are high num-

bers of lymphatic glands such as the axilla and groin [3]. LMs are usually isolated but may also occur in association with other vascular anomalies such as venous- or capillary anomalies, and rarely as part of specific vascular anomaly syndromes [4]. Although LMs are congenital anomalies, some may only become apparent if they grow or become symptomatic. Bleeding or infection of cysts may cause painful enlargement of the LM, cosmetic or functional impairment, and sometimes compression of vital structures such as the airway. The main interventional options have included sclerotherapy, surgery, medical management, or a combination of these [5]. Owing to the heterogeneity of LMs, management decisions are often individualized based on the size, location, and symptoms related to the LM. At our tertiary referral center, a specialist interdisciplinary team comprising surgeons, physicians, radiologists, pathologists, oncologists, ophthalmologists, otorhinolaryngologists, dermatologists and geneticists are responsible for the management vascular anomalies. In order to further improve ap-

**Abbreviations:** AKT, Protein kinase B; EXIT, Ex-utero intrapartum treatment; ISSVA, International Society for the Study of Vascular Anomalies; LM, Lymphatic malformation; mTOR, Mammalian target of rapamycin; OK-432, Picibanil®; PI3K, Phosphatidylinositol-3-kinase; PIK3CA, Phosphatidylinositol-4,5-bisphosphate-3-kinase, catalytic subunit alpha.

\* Corresponding author at: New Children's Hospital, Department of Pediatric Surgery, Helsinki University Hospital and University of Helsinki, Stenbäckinkatu 9, 00029 HUS, Helsinki, Finland.

E-mail address: [hanna.z.hyvonen@helsinki.fi](mailto:hanna.z.hyvonen@helsinki.fi) (H. Hyvönen).

proaches to management, systematic evaluation of the outcomes of LMs based on current management approaches is needed. This study has aimed to describe the characteristics a, treatment and, outcomes of our pediatric patient population with LMs at a single center over an 11-year follow-up period.

## 2. Materials and methods

### 2.1. Patients

This was a cross-sectional, single tertiary institution series. After institutional review board approval from the Helsinki University Hospital (HUS54/2019 and HUS80/2021), the records of all patients with LMs  $\leq$  16 years of age primarily referred to our institution between January 2008 and September 2019 were retrieved. Based on the ISSVA classification of vascular anomalies [2], the outcomes of simple (cystic) LMs were studied. These were classified into macrocystic (cysts  $\geq$  1 cm), microcystic (cysts  $<$  1 cm), or mixed (macro- and microcystic) types [2].

Clinical details collected included age at presentation, presenting symptoms and signs, location of the LM, imaging studies, management, laboratory findings, and details of outcomes over follow-up. Symptoms were graded according to severity based on records: 1) asymptomatic, 2) mild/occasional symptoms (e.g. skin discoloration, mild pain intermittently) and 3) moderate/severe symptoms limiting activity of daily life and/or compressing vital organs (e.g. airway). Magnetic resonance imaging (MRI) was performed to assess the potential airway involvement prenatally, or prior to sclerotherapy to evaluate the potential risk of tracheal compression after treatment. LM size was determined by measurements from radiological imaging (US and MRI), overall assessment was complemented by clinical examination and follow-up photographs. Dimensional changes were reported as increased, no change, reduced or regressed at the last follow-up visit relative to the original size of the lesion(s) at diagnosis. Complications were classified according to Clavien-Dindo [6]. Localized pain and/or swelling during the first 2 weeks after sclerotherapy was regarded as an effect of treatment rather than a complication, unless unusually severe [7,8]. Recurrence was defined as reappearance of clinically apparent lesions after apparently successful treatment.

### 2.2. Statistics

Data are presented as median (range) unless otherwise specified. Frequencies were compared using

Fisher's exact test. Statistics were calculated using SPSS software version 27.0 (SPSS Inc, Chicago, IL). A  $p$ -value  $<$  0.05 was considered significant.

## 3. Results

### 3.1. Patients

Of a total of 164 patients, the median follow-up was 5 (0.3–16) years from diagnosis (Table 1). Eight cases (5%) were diagnosed prenatally on ultrasound during pregnancy. Thirty-three percent ( $n = 54$ ) of patients presented during the neonatal period, and 66% ( $n = 109$ ) had presented by the age of 2 years (Fig. 1). At the time of the study, 72 (44%) patients were under follow-up, 86 (52%) had been discharged, and 6 (4%) had transitioned to adult care. There was only one mortality in the cohort due to causes unrelated to the LM

### 3.2. Presenting features and primary assessment

The most common presenting feature was a palpable mass or swelling (84%;  $n = 138$ ), followed by pain at the site of the LM

**Table 1**  
Patient demographics and location of LM.

Demographics	n (%)
Male/female	99 (60)/65 (40)
Age at diagnosis, years; median (range)	1.2 (0–15)
<b>Location</b>	
Head and/or neck	66 (40)
Extremities	45 (27)
Trunk	37 (23)
Visceral	10 (6)
Mediastinum (including neck)	6 (4)
<b>Classification</b>	
Macrocystic	77 (47)
Microcystic	34 (21)
Mixed	53 (32)

(27%;  $n = 45$ ). Cutaneous changes (skin vesicles) or signs of infection were found in 9% of patients ( $n = 15$ ) for both. All patients had undergone ultrasound (US) assessment as part of the diagnostic pathway. US showed hemorrhage into cysts in 42 (26%) patients. LMs were found incidentally on imaging performed for other reasons in 11 (7%) cases.

Of 66 patients with head and/or neck LMs, 6 (9%) required tracheostomy due to airway obstruction or impending airway obstruction, either based on anatomy and/or planned sclerotherapy. Four out of these 6 cases had a very large cervical/mediastinal LM with obstruction of the trachea and oropharynx that was diagnosed prenatally. These patients were delivered electively after multidisciplinary assessment via ex-utero intrapartum treatment (EXIT) delivery and successfully intubated, followed by semi-elective tracheostomy at median age of 8 (range, 1–60) days. Of the remaining 2 prenatally diagnosed head and/or neck LMs, one developed symptoms during the first week of life and the second feeding difficulties at 4 months of age from a gradual increase in the size of macrocysts. All 6 patients with tracheostomy have been successfully decannulated at a median age of 3 (range, 0.8–5) years. The two cases of peripheral LMs with prenatal diagnosis underwent normal delivery.

### 3.3. Further imaging

In addition to US assessment in all patients, a total of 172 MRI scans had been conducted in a total of 111 (68%) patients, including 4/8 (50%) fetuses with prenatal diagnosis. MRI had been performed to assess the extent and anatomy of the LM for treatment planning in all ( $n = 111$ ), to define the extent of potential airway involvement in 49 (44%) patients, and/or to follow-up lesions that were not adequately visualized on US (including a mediastinal location) in 15 (14%) patients. Computed tomography (CT) scans had been performed in 5 (3%) cases as an additional imaging to evaluate bone structure or to assess possible lung involvement.

### 3.4. Management

The overall management algorithm within the cohort is summarized in Fig. 2.

#### 3.4.1. Conservative management

Of a total of 163 living patients, 62 (38%) had not undergone/required any interventions to date. The median age was 0.8 (range, 0–12) years at the first visit. LMs were macrocystic in 33 (53%), microcystic in 14 (23%) and mixed in 15 (24%). Thirty-one (50%) were in a head and/or neck location.

Of these patients, 58 (94%) reported no cosmetic/functional impairment and/or pain. The remainder had mild/occasional symptoms (mainly pain). The size of the LM reduced during follow-up

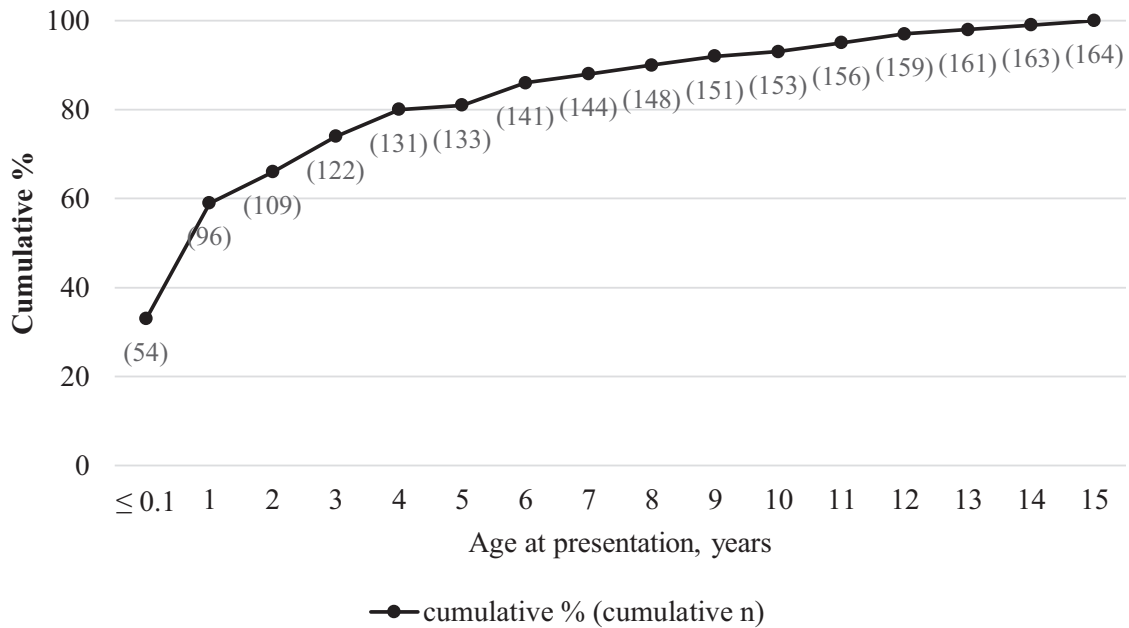
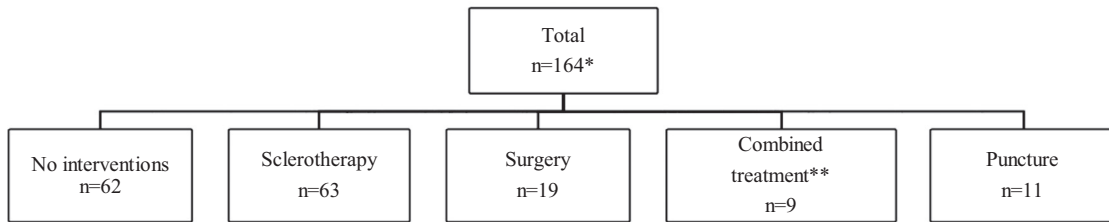


Fig. 1. Cumulative age at presentation of LMs in 164 patients.



\* 163 living, 1 death unrelated to the LM

\*\* a combination of sclerotherapy and/or surgery/puncture and/or medication

Fig. 2. Management.

clinically or on imaging in 42 (68%) patients, in 16 of whom complete resolution (disappearance on clinical examination and imaging) occurred. All these 16 patients had macrocystic LMs; 10/16 (63%) had a head and/or neck location. The median age at resolution was 2 (range, 0.7–8) years; median 13 (range, 1–61) months after appearance. No recurrences were observed in this group during the follow-up period. The LM size remained unchanged in 19 (31%) patients and increased in 1 (2%).

### 3.4.2. Sclerotherapy

Sclerotherapy had been performed in 72 (44%) patients at a median age of 2.5 (range, 0.01–15) years, either in isolation ( $n = 63$ ; 88%) or in combination with surgery ( $n = 9$ ; 12%). A total of 190 (median 2, range, 1–9) sessions had been performed. Thirty-one patients (43%) had undergone one session and 35 (49%) patients 2–5 sessions. Six patients (8%) had undergone >5 sessions, 3 of whom due to large, complex head/neck LMs (mixed type). Indications for sclerotherapy included cosmetic impairment (43%;  $n = 31$ ) pain (25%;  $n = 18$ ), skin problems (17%;  $n = 12$ ), functional impairment (15%;  $n = 11$ ), and/or compression of the trachea (8%;  $n = 6$ ). As shown in Fig. 3. OK-432 (Picibanil®) was the predominant sclerosant that had been used (35%;  $n = 67$ ) although currently doxycycline and bleomycin predominate our sclerotherapy treatment. Macrocysts were most commonly treated with OK-432 and doxycycline, and microcystic LMs with bleomycin. In 21

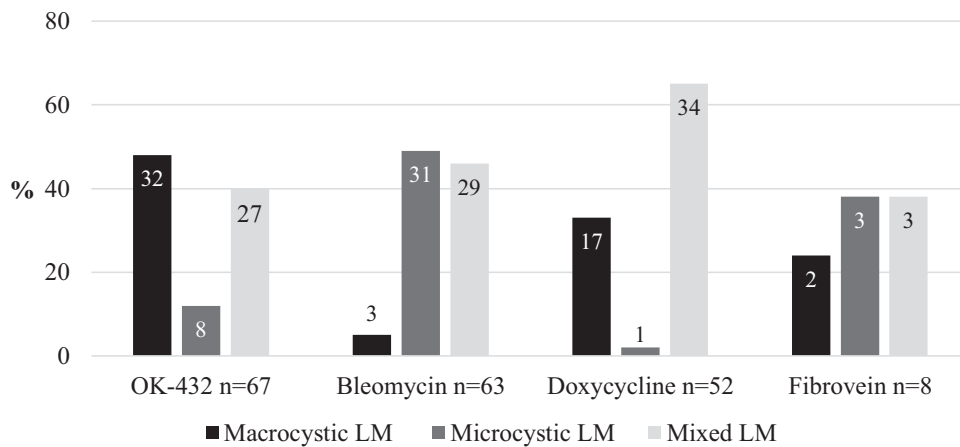
Table 2  
Effects of sclerotherapy on the size of LMs.

LM	n (%)				Total
	Resolved*	Reduced	No change	Increased	
Macrocystic	8 (30)	15 (55)	4 (15)	0 (0)	27
Microcystic	1 (6)	13 (81)	2 (13)	0 (0)	16
Mixed type	1 (5)	14 (70)	5 (25)	0 (0)	20
Total	10 (16)	42 (67)	11 (17)	0 (0)	63

\* Completely resolved either clinically and/or on imaging.

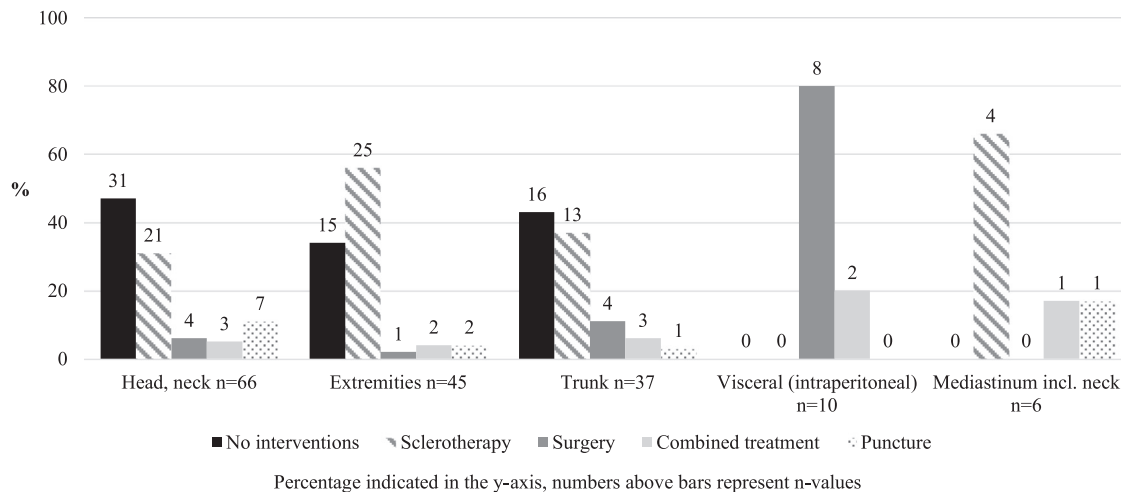
(29%) patients, more than one type of sclerosant had been used in different sessions. Sclerotherapy was performed under general anesthesia in 180 (95%) of sessions. The median hospital stay was 1 (range, 1–21) days; 47% ( $n = 89$ ) patients were discharged on the same day. In 4 patients with large cervical macrocysts, sclerotherapy was performed by first draining macrocysts with a pig-tail catheter and then injecting doxycycline through the drain. This was left in situ for 4 hours and then drained, repeating the procedure until fluid drainage ceased [9]. The median number of procedures was 3 (range, 2–4). Drains were removed after a median of 5 (range, 1–6) days.

The outcomes of primary sclerotherapy ( $n = 63$ ) are presented in Table 2. LMs completely resolved or reduced in size in 83% of patients ( $n = 53$ ) such that in 48% of patients ( $n = 30$ ) no fur-



Percentage indicated in the y-axis, numbers within/above bars represent n-values

Fig. 3. Sclerosants used to treat different types of simple (cystic) LMs in the cohort.



Percentage indicated in the y-axis, numbers above bars represent n-values

Fig. 4. Treatment approach according to the location of the LM.

ther sessions were planned. Two (3%) patients continued to have symptoms limiting daily life: one patient with a microcystic LM with complex involvement of the oropharynx (airway obstruction) and one patient with pain from a microcystic LM of the dominant hand. Further sclerotherapy is planned in these patients.

### 3.4.3. Surgery

Twenty-six (16%) patients underwent surgical resection of the LM at a median age of 4.2 (range, 0.3–12) years, of whom 19 (73%) as the primary treatment and 7 (27%) secondarily or as a form of combined treatment. Fifty-three percent ( $n = 10/19$ ) of primarily operated cases comprised patients with symptomatic intra-abdominal LMs (large mesenteric or omental cysts with pain, including intestinal torsion around a macrocyst) as shown in Fig. 4. In truncal or peripheral lesions ( $n = 16$ ), symptomatic or palpable mass ( $n = 8$ ; 50%), a large LM restricting movement of the head/neck or extremity ( $n = 4$ ; 25%), persistent lymphatic/blood leakage ( $n = 2$ ; 13%) or increasing size of the LM despite sclerotherapy ( $n = 2$ ; 13%) led to surgery.

Total macroscopic excision was performed in 16 (62%) and debulking in 9 (35%) patients, respectively. At operation, one patient was found to have an unresectable visceral LM due to extensive mesenteric involvement. Eighteen (69%) patients needed inpatient care postoperatively with a median hospital stay of 6 (range, 2–10) days. The remainder were performed as day cases. One reop-

eration was conducted after debulking to remove more affected skin. Among patients with total macroscopic excision, recurrences were observed in 2 (13%) patients (both mixed type LMs) 4 and 7 months after resection. These patients have not been reoperated as they had no cosmetic or functional concerns, and the lesions were smaller than before operations.

### 3.4.4. Puncture

Puncture and drainage of macrocysts was conducted in 19 (12%) cases. Eleven patients had growing LMs of the neck extending close to the trachea. The median age at the time of puncture was 4 months (range, 2 days to 4 years). The puncture was conducted to temporarily reduce the size of the LM before further treatment, but no regrowth occurred in 5 (26%) cases, including two patients (macrocytic head/neck LMs) in whom lesions resolved after puncture without need for further interventions. Intralesional bleeding after puncture was noted in two (11%) cases.

### 3.4.5. Medical management

Sirolimus, an mTOR (mammalian target of rapamycin) inhibitor, had been initiated for one (0.6%) patient in the cohort. This patient had a large head and neck LM with mediastinal involvement. The cervical component was initially treated with puncture followed by sclerotherapy and surgery. A somatic PIK3CA (a catalytic subunit alpha of phosphatidylinositol-4,5-bisphosphate-3-kinase) muta-

tion was detected on genetic analysis and sirolimus was initiated as further treatment after multidisciplinary assessment.

### 3.5. Complications according to Clavien-Dindo

The overall incidence of complications after interventions was 7% ( $n = 15/215$ ). Complications after sclerotherapy were 6% ( $n = 12/190$  sessions) and 12% ( $n = 3/25$  procedures) after surgery ( $p = 0.392$ ). After sclerotherapy, prolonged swelling, or pain > 2 weeks (grade I) occurred in 7 (4%) patients, and intralesional hemorrhage and infection of the LM requiring antibiotics (grade II) occurred in 5 (3%) patients. Intubation was required in 1 patient due to localized swelling of the oropharynx after OK-432 sclerotherapy. As this was an anticipated effect of treatment, it was not regarded as a complication. After surgery, the postoperative complications included wound infection requiring additional operations ( $n = 2$ ), and/or temporary neuropraxia ( $n = 1$ ; grades III–IIIId). Complications after surgery ( $n = 3$ , grade III–IIIId) were more severe than after sclerotherapy ( $n = 12$ , grade I–II),  $p = 0.002$ .

## 4. Discussion

LMs are benign lesions that do not require immediate treatment unless vital structures are compromised. These lesions can expand as the child grows and LMs seem to be prone to progression especially during adolescence [10]. Differential diagnosis of LM includes other low-flow vascular malformations, masses of neck (e.g. thyroglossal cysts, plunging ranula, teratoma), (epi)dermoid cysts and seromas. Microcystic LMs with skin involvement may be confused with other skin lesions. Misdiagnosis may potentially lead to delayed or incorrect treatment [11,12].

No mortality directly related LMs occurred in our cohort, and major complications related to treatment were uncommon, supporting the role of multidisciplinary assessment in patient selection for expectant and interventional measures, and in the choice of treatment modality. Based on antenatal MRI, 4 patients with significant airway involvement were delivered by EXIT section, first described for use in large cervical LMs threatening the airway by Laje et al. [13]. As the EXIT procedure carries more potential for complications than a standard cesarean section [13], the risks and potential benefits should be carefully considered. In our cohort, the airway was intubated successfully in all patients selected for EXIT section, and the subsequent need for tracheostomy was later confirmed. The two further patients with prenatally apparent larger head/neck LMs who were normally delivered later went on to require tracheostomy, suggesting that patients with prenatal diagnosis at this location may generally have larger/more complex LMs and there may be a risk of developing airway compromise during follow-up. Of the 66 other patients with head/neck and/or mediastinal LMs that were not prenatally detected, none went on to require tracheostomy and/or intubation during follow-up.

In terms of outcomes, spontaneous resolution was observed in 26% of our patients at an average of 13 months after initial presentation, most of whom had macrocystic LMs as has been observed in other studies [14,15]. These patients were predominantly asymptomatic (94%) and mostly under pre-school age (median 2 years). The previously reported rates of spontaneous regression in LMs have varied between 13% to 58% [14–16], with a median of 7 months from incidence according to one study [15]. Spontaneous resolution was most common among patients with head and neck LMs (63%), although conversely some of our most clinically complicated cases were also in this location. Expectant observation of smaller LMs with minimal or no symptoms during at least the pre-school years is supported by several studies [14,16,17].

In our cohort, interventions were performed for significant cosmetic deformity or pain, functional impairment, or threat to vital

structures such as the airway. Puncture of the LM, described in a few studies [16,18,19] was performed for younger infants who had a growing LM head and/or neck to temporarily reduce lesion size before definitive sclerotherapy, although in some cases regression or lack of re-growth was subsequently observed. The data do not allow assessment of whether this was due to puncture or tendency to natural regression of the LM; all were large macrocystic lesions. In these cases, puncture was performed primarily to delay the need for sclerotherapy (and subsequent secondary airway compromise) in young patients (under 3 months of age).

Among patients requiring interventions, sclerotherapy is often the most common primary treatment performed. Although OK-432 was commonly used in the past, at our institution it has since been superseded by doxycycline (for macrocystic LMs) and bleomycin (for microcystic LMs) in recent years. In mixed type of LMs, our institutional preference involves treatment of the macrocystic component prior to the microcystic components. Sometimes treatment of the macrocystic component suffices, which reduces the need to use bleomycin for microcystic components [20]. Drains were used rarely in selected cases with large macrocystic LMs threatening vital structures or no response to puncture or sclerotherapy. Similar processes for usage of drains have been described in the literature [9,21,22]. As the selection of sclerosants is influenced by the size, type, and location of LMs and multiple sclerosants and/or multiple sessions may be required, comparison of the efficacy of single sclerosing agents by type of LM was not feasible.

Patients underwent on average 2 sclerotherapy sessions, which is in congruent with other studies [17,21,23]. The timing of sclerotherapy was based on the clinical course, symptoms, and the localization of LM. In cervical LMs diagnosed prenatally or in the neonatal period, we often perform MRI within the first two months of life without anesthesia or sedation to evaluate the risk of tracheal compression. If this shows extension near to the trachea but no airway compression or need for tracheostomy, our preferred approach is to postpone the first sclerotherapy, if possible, until the child is around two years old and the consistency of trachea is more rigid [24]. The parents are informed to contact the hospital should any concerns with the child's breathing arise. Even if sclerotherapy is performed at the age of two years or later, patients with LM lesions extending close to trachea are monitored closely in the hospital after the procedure for any signs of tracheal compression from potential swelling. In our data, 50% of patients who underwent more than 5 sclerotherapy sessions were tracheostomized, which describes the complexity of the clinical situation. Based on current knowledge, if sclerotherapy is ineffective after 2–3 sessions, other treatment options such as surgery and/or biopsy for genetic analysis and possible medical treatment should be considered [25,26].

It has been found that somatic PIK3CA mutations are associated with both simple and syndromic LMs [27]. The understanding that activation of the PI3K (phosphatidylinositol-3-kinase)/AKT (protein kinase B)/mTOR pathway may be related to the etiology of LMs has introduced sirolimus into the treatment of complicated vascular anomalies and the current literature suggests that it is well tolerated [26,28]. According to previous studies, sirolimus seems to be effective especially when treating mucosal and microcystic LMs with skin involvement, or cervicofacial LMs [25,29]. In the current cohort, sirolimus had been initiated in one patient, but its use has since increased pending improved understanding of genetic factors in LMs, including the detection of somatic PIK3CA mutations among patients with LMs [30].

In the current cohort, surgery was performed in selected cases, mainly for macroscopic resection of symptomatic intra-abdominal LMs or as a secondary debulking measure for large, mixed-type peripheral or head/neck LMs affecting multiple tissue layers where

sclerotherapy had not been sufficiently effective. Our results suggest that surgery was effective in reducing symptoms and size of the lesion. Dubois et al. proposed that surgery might be adjuvant treatment in cases with poor outcome after primary sclerotherapy [22]. On the contrary, Lee et al. indicated that complete resection of clearly demarcated macrocysts is enough to cure most patients with intra-abdominal LMs [31]. In our series, there were more Clavien-Dino complications grade  $\geq$ III related to surgery than sclerotherapy ( $p = 0.002$ ). These findings may reflect patient selection for different treatment categories, and the complexity of surgically treated cases. By lesion type, patients with macrocystic LMs had the highest rates of clinical resolution or improvement after treatment, which is also supported by the literature [9,15,31].

The limitation of our study is its retrospective design. The patients were selected to different treatment groups by nonrandomized design based on clinical status and imaging findings. Evaluation of outcomes was dependent on the documentation in patient records at the latest follow-up visit and the size of LM is based on subjective measures and/or imaging. However, among the strengths of this study include a large patient cohort and that no cases were lost to follow-up. Further multicenter studies are needed to elucidate the outcomes of treatment and effects of cystic LMs, including health-related quality of life. Genetic analysis for somatic mutations, and the role of medical treatment in the management of LMs remain other important areas for continued research.

## 5. Conclusions

Despite their current classification terminology, simple (cystic) LMs demonstrate wide heterogeneity in terms of size, location, and clinical course. Most previous articles to date have focused on outcomes by location whereas the current work includes an entire population of patients treated at a single tertiary unit over an 11-year time period. Careful, multidisciplinary assessment assists in the planning of management strategies, which include conservative follow-up, and identifies that multiple and sometimes multimodal treatments may be required in symptomatic cases.

## Declaration of Competing Interest

None to declare.

## Source of funding

This research was supported by a grant from the Foundation for Pediatric Research, Finland, and State funding for university-level health research.

## Level of Evidence

III.

## References

- [1] Acevedo JL, Shah RK, Brietzke SE. Nonsurgical therapies for lymphangiomas: a systematic review. *Otolaryngol Head Neck Surg* 2008;138:418–24. doi:10.1016/j.otohns.2007.11.018.
- [2] ISSVA classification for vascular anomalies. Approved at the 20th ISSVA Workshop, Melbourne April 2014, last revision May 2018. <https://www.issva.org/UserFiles/file/ISSVA-Classification-2018.pdf> [accessed 12th January 2022]
- [3] Ghaffarpour N, Burgos CM, Wester T. Surgical excision is the treatment of choice for cervical lymphatic malformations with mediastinal expansion. *J Pediatr Surg* 2018;53:1820–4. doi:10.1016/j.jpedsurg.2017.10.048.
- [4] Wassef M, Blei F, Adams D, et al. Vascular anomalies classification: recommendations from the society for the study of vascular anomalies. *Pediatrics* 2015;136:e203–14. doi:10.1542/peds.2014-3673.

- [5] Bagrodia N, Defnet AM, Kandel JJ. Management of lymphatic malformations in children. *Curr Opin Pediatr* 2015;27:356–63. doi:10.1097/MOP.000000000000209.
- [6] Dindo D, Demartines N, Clavien PA. Classification of surgical complications: a new proposal with evaluation in a cohort of 6336 patients and results of a survey. *Ann Surg* 2004;240:205–13. doi:10.1097/01.sla.0000133083.54934.ae.
- [7] Aronniemi J, Castrén E, Lappalainen K, et al. Sclerotherapy complications of peripheral venous malformations. *Phlebology* 2016;31:712–22. doi:10.1177/0268355515613740.
- [8] Castrén E, Aronniemi J, Klockars T, et al. Complications of sclerotherapy for 75 head and neck venous malformations. *Eur Arch Otorhinolaryngol* 2016;273:1027–36. doi:10.1007/s00405-015-3577-x.
- [9] Burrows PE. Endovascular treatment of slow-flow vascular malformations. *Tech Vasc Intervent Radiol* 2013;16:12–21. doi:10.1053/j.tvir.2013.01.003.
- [10] Hassanein AH, Mulliken JB, Fishman SJ, et al. Lymphatic malformation: risk of progression during childhood and adolescence. *J Craniofac Surg* 2012;23:149–52. doi:10.1097/SCS.0b013e3182413ea8.
- [11] Mattila KA, Kervinen K, Kalajoki-Helmiö T, et al. An interdisciplinary specialist team leads to improved diagnostics and treatment for paediatric patients with vascular anomalies. *Acta Paediatr* 2015;104:1109–16. doi:10.1111/apa.13076. Epub 2015 Jul 28.
- [12] Marler JJ, Fishman SJ, Upton J, et al. Prenatal diagnosis of vascular malformations. *J Pediatr Surg* 2002;37:318–26. doi:10.1053/jpsu.2002.30831.
- [13] Laje P, Peranteau WH, Hedrick HL, et al. Ex utero intrapartum treatment (EXIT) in the management of cervical lymphatic malformation. *J Pediatr Surg* 2015;50:311–4. doi:10.1016/j.jpedsurg.2014.11.024.
- [14] Dasgupta R, Adams D, Elluru R, et al. Noninterventional treatment of selected head and neck lymphatic malformations. *J Pediatr Surg* 2008;43:869–73. doi:10.1016/j.jpedsurg.2007.12.029.
- [15] Perkins JA, Maniglia C, Magit A, et al. Clinical and radiographic findings in children with spontaneous lymphatic malformation regression. *Otolaryngol Head and Neck Surg* 2008;138:772–7. doi:10.1016/j.otohns.2008.02.016.
- [16] Kennedy TL, Whitaker M, Pellitteri P, et al. Cystic hygroma/lymphangioma: a rational approach to management. *Laryngoscope* 2001;111:1929–37. doi:10.1097/00005537-200111000-00011.
- [17] Gilony D, Schwartz M, Shpitzer T, et al. Treatment of lymphatic malformations: a more conservative approach. *J Pediatr Surg* 2012;47:1837–42. doi:10.1016/j.jpedsurg.2012.06.005.
- [18] Lyly A, Castrén E, Aronniemi J, et al. Plunging ranula - patient characteristics, treatment, and comparison between different populations. *Acta Otolaryngol* 2017;137:1271–4. doi:10.1080/00016489.2017.1357082.
- [19] Alqahtani A, Nguyen H, Flageole H, et al. 25 Years' experience with lymphangiomas in children. *J Pediatr Surg* 1999;34:1164–8. doi:10.1016/s0022-3468(99)90590-0.
- [20] Chaundry G, Guevara CJ, Rialon KL, et al. Safety and efficacy of bleomycin in sclerotherapy for macrocystic lymphatic malformation. *Cardiovasc Intervent Radiol* 2014;37:1476–81. doi:10.1007/s00270-014-0932-z.
- [21] Alonmari AI, Karian VE, Lord DJ, et al. Percutaneous sclerotherapy for lymphatic malformations: a retrospective analysis of patient-evaluated improvement. *J Vasc Interv Radiol* 2006;17:1639–48. doi:10.1097/01.RVI.0000239104.78390.E5.
- [22] Dubois J, Thomas-Chaussé F, Soulez G. Common (cystic) lymphatic malformations: current knowledge and management. *Tech Vasc Interv Radiol* 2019;22:100631. doi:10.1016/j.tvir.2019.100631.
- [23] Acord M, Srinivasan AS, Cahill AM. Percutaneous treatment of lymphatic malformations. *Tech Vasc Interv Radiol* 2016;19:305–11. doi:10.1053/j.tvir.2016.10.001.
- [24] Di Cicco M, Kantar A, Masini B, et al. Structural and functional development in airways through childhood: children are not small adults. *Pediatr Pulmonol* 2021;56:240–251. doi:10.1002/ppul.25169.
- [25] Strychowsky JE, Rahbar R, O'Hare MJ, et al. Sirolimus as treatment for 19 patients with refractory cervicofacial lymphatic malformation. *Laryngoscope* 2018;128:269–76. doi:10.1002/lary.26780.
- [26] Lackner H, Karastaneva A, Schwinger W, et al. Sirolimus for the treatment of children with various complicated vascular anomalies. *Eur J Pediatr* 2015;174:1579–84. doi:10.1007/s00431-015-2572-y.
- [27] Luks VL, Kamitaki N, Vivero MP, et al. Lymphatic and other vascular malformative/overgrowth disorders are caused by somatic mutations in PIK3CA. *J Pediatr* 2015;166:1048–54 e1–5. doi:10.1016/j.jpeds.2014.12.069.
- [28] Adams DM, Trenor CC, Hammill AM, et al. Efficacy and safety of sirolimus in the treatment of complicated vascular anomalies. *Pediatrics* 2016;137:e20153257. doi:10.1542/peds.2015-3257.
- [29] Rössler J, Geiger J, Földi E, et al. Sirolimus is highly effective for lymph leakage in microcystic lymphatic malformations with skin involvement. *Int J Dermatol* 2017;56:e72–e75. doi:10.1111/ijd.13419.
- [30] Mäkinen T, Boon LM, Vikkula M, et al. Lymphatic malformations: genetics, mechanisms and therapeutic strategies. *Circ Res* 2021;129:136–154. doi:10.1161/CIRCRESAHA.121.318142.
- [31] Lee S, Jinyoung P. Abdominal lymphatic malformation in children. *Adv Pediatr Surg* 2018;24:60. doi:10.13029/aps.2018.24.2.60.