



UNIVERSITY OF HELSINKI



<https://helda.helsinki.fi>

Helda

Diagnosis, natural course and treatment outcomes of groove pancreatitis

Tarvainen, T.

Elsevier B.V.

2021-08

Tarvainen, T, Nykanen, T, Parviainen, H, Kuronen, J, Kylänpää, L, Siren, J, Kokkola, A & Sallinen, V 2021, 'Diagnosis, natural course and treatment outcomes of groove pancreatitis', HPB, vol. 23, no. 8, pp. 1244-1252. <https://doi.org/10.1016/j.hpb.2020.12.004>

<http://hdl.handle.net/10138/335042>

10.1016/j.hpb.2020.12.004

cc_by

publishedVersion

Downloaded from Helda, University of Helsinki institutional repository.

This is an electronic reprint of the original article.

This reprint may differ from the original in pagination and typographic detail.

Please cite the original version.

ORIGINAL ARTICLE

Diagnosis, natural course and treatment outcomes of groove pancreatitis

T. Tarvainen¹, T. Nykänen², H. Parviainen³, J. Kuronen³, L. Kylänpää¹, J. Sirén¹, A. Kokkola¹ & V. Sallinen^{1,4}

¹Gastroenterological Surgery, University of Helsinki and Helsinki University Hospital, Helsinki²Gastroenterological Surgery, Hyvinkää Hospital, Hyvinkää³Medical Imaging Center, Radiology⁴Transplantation and Liver Surgery, University of Helsinki and Helsinki University Hospital, Helsinki, Finland

Abstract

Background: Groove pancreatitis (GP) is a rare form of chronic pancreatitis with limited data on its diagnostics and treatment outcomes. The aim of this study was to assess its diagnostics, natural course, and treatment options.

Methods: The study is a retrospective population-based study from Southern Finland, including all patients with suspected GP between January 2005 and December 2015. Two certified gastrointestinal radiologists re-reviewed the imaging studies. The radiological re-review, clinical judgment, and final histopathology confirmed the GP diagnoses.

Results: Out of 67 patients with possible GP, 39 patients were considered to have high radiological certainty of GP. Out of these 39, five patients had cancer instead. Thirty-three patients with confirmed GP formed the final study cohort. Patients with GP were mostly middle-aged (median 55 years) men. All had at least moderate alcohol consumption. No intervention was needed in 14 patients. In five-year follow-up all conservatively treated patients became asymptomatic, while 10 out of 16 patients undergoing at least one intervention were asymptomatic at five years.

Conclusion: The radiological diagnosis of GP is difficult, and a low threshold for cancer suspicion should be kept. Symptoms of GP decrease with time and suggest conservative treatment as the first-line option.

Received 13 September 2020; accepted 11 December 2020

Correspondence

Ville Sallinen, Transplantation and Liver Surgery, University of Helsinki and Helsinki University Hospital, Haartmaninkatu 4, 00029, Helsinki, Finland. E-mail: ville.sallinen@helsinki.fi

Introduction

Groove pancreatitis (GP) is a rare type of chronic pancreatitis affecting the so-called groove area between the head of the pancreas, the C-loop of duodenum and the common bile duct.^{1,2} Various other names such as paraduodenal pancreatitis,^{3–7} cystic dystrophy of the duodenal wall^{8,9} and duodenal cystic dystrophy in heterotopic pancreas¹⁰ have been used to describe this entity, but the term groove pancreatitis has established its place as the name for this disease.

GP like any other type of chronic pancreatitis is suggested to affect mostly middle-aged men, with a history of alcohol and tobacco consumption.^{4,10} Typical symptoms are abdominal pain and weight loss.^{4,6,10} GP is divided into two different forms. The

pure form affects only the groove area while the segmental form extends inside the pancreatic head.¹¹ Either one of these two forms can be solid or cystic.¹¹ There are specific radiological findings in GP,^{5,7,11–13} but especially the segmental form can mimic pancreatic neoplasms while extending to pancreatic head.¹¹ The suspicion of cancer may lead to unnecessary pancreatic surgery.^{14,15} Surgery may be needed in GP even without the suspicion of malignancy since the inflammation process in the groove area can lead to obstruction in duodenum, pancreatic duct or bile duct.^{6,10} Due to limited research, the treatment strategies vary from center to center, and there are no treatment guidelines on GP. Most of the literature concentrates on the surgical^{4,7,16–20} or endoscopic^{6,21,22} treatment of GP, and there are only few studies reporting the results of conservative treatment of GP.^{10,14,23}

The aim of this study was to evaluate the diagnostics and the natural course of GP as well as the efficiency and safety of the different treatment strategies.

Methods

This is a retrospective study performed in seven hospitals (Meilahti Tower Hospital, Jorvi Hospital, Peijas Hospital, Lohja Hospital, Porvoo Hospital, Hyvinkää Hospital, and Raasepori Hospital) serving a population of approximately 1.9 million within a geographically defined area in Southern Finland. These seven hospitals are all government-funded and belong administratively to the same hospital district (Helsinki and Uusimaa Hospital District) and use the same electronic patient record system. Private hospitals giving treatment for GP are practically non-existent in Finland. In Finland the incidence of chronic pancreatitis is around 10 to 13,4 cases per hundred thousand per year.²⁴ The data was gathered from the electronic patient records of patients treated between the January 2005 and December 2015.

In order to find the eligible patients, a computerized search from electronic patient record database with the keywords “groove*” and “paraduod*” was ran, latter referring to paraduodenal (pancreatitis), which is one of the most used synonyms of GP. Asterisk (*) indicates that the word could contain any characters after the keyword. Patients’ records identified by the keyword search were then manually analysed. Patients who had a clinical presentation or a radiological suspicion of pancreatitis were included for radiological re-review. The primary CT and/or MRI scans of these patients were individually and blindly assessed by two radiologists (HP and JK) with a certified subspecialty in gastrointestinal imaging. The radiologists categorised these patients in three groups by the certainty of the GP diagnosis: certain GP, possible GP, or other (not GP). The definitions of certain and possible GP were formed based on previously described radiological findings in GP.^{5,25} Three radiological features were highlighted: 1) cysts in the duodenal wall at the C-loop or groove area, 2) duodenal wall thickening more than 10 mm at the C-loop and 3) visible mass in the groove area. If two or three of these features were found, the GP was considered certain and if only one was found, it was considered possible GP. The radiologists (HP and JK) did not have access to patient records, and thus did not know the clinical course of the patient, except for that stated in the imaging referral.

The records of the patients with suspected GP were further assessed to find a group of patients who retrospectively met the criteria for GP. We set four criteria of which at least one had to be met for GP diagnosis. The criteria were: GP confirmed 1) by a pathologist from a surgical specimen, 2) by a multidisciplinary team (MDT) with a statement in patient records, 3) by both reviewing radiologists confirming “certain GP” in imaging and the patient had clinical signs of pancreatitis, or 4) by one radiologist confirming “certain GP”, the other confirming “possible

GP”, and an experienced surgeon confirming GP diagnosis in patient records. These patients formed the final study cohort. Patients who had histological verification of pancreatic cancer or radiological metastatic cancer were excluded from the final study cohort.

The demographic data, symptoms, worst laboratory findings during the course of the disease, radiological findings, treatments and surveillance data up to seven years, final clinical diagnosis and the radiological diagnosis made by the clinical radiologist at the time of the disease were collected from the electronic patient records. The symptoms of GP were evaluated annually from the onset of GP. They were categorized into four categories; the patient was showing either 1) no symptoms, 2) less symptoms than previously, 3) no difference in symptoms or 4) worsening symptoms. If the patient showed no symptoms at a follow-up visit and no further data was found, it was concluded that the patient had stayed asymptomatic during the following years. The deceased patients were censored from the follow-up data after the death. The cause of death was retrieved from the patient records or autopsy reports.

All categorical data were reported as frequency and percentage. Continuous data were reported as mean and standard deviation for normally distributed and as median and interquartile range for non-normally distributed data. Statistical analyses were performed with SPSS 25 (IBM, Armonk, NY). Institutional review board gave permission to conduct the study. Ethical committee approval is not necessary for retrospective studies in Finland. Patients were not contacted during the study.

Results

Patient selection

The keyword search found 192 patients. Out of these, 125 patients were excluded since the keywords were mentioned in completely different context (e.g. patellofemoral groove or perineal groove). The remaining 67 patients had a suspicion of GP during the course of their disease. The radiological images of these patients were re-reviewed by two blinded gastrointestinal radiologists (HP and JK). The certainty of the GP diagnosis was considered high if both of the radiologists (HP and JK) considered the diagnosis “certain” or one considered it “certain” while the other considered it “possible” (Table 1). Radiologically, 39 patients were considered to have high-certainty and 28 patients low-certainty GP (Table 1). Of note, after reviewing the patients reports it turned out that five patients in the high-certainty group and six patients in the low-certainty group had histologically verified pancreatic ductal adenocarcinoma (Table 1). The proportion of cancers were especially high in non-smoking females since five out of 10 non-smoking females (50%) turned out to have cancer instead of GP. There were no cancers among smoking females with GP suspicion (n = 10).

By applying the clinical and radiological criteria described in the methods section, 31 patients in the high-certainty group and

Table 1 The degree of certainty of the radiologists' diagnosis compared to the final diagnosis. Two gastrointestinal radiologists classified radiological images as "certain" or "possible" for groove pancreatitis, or as "other" (not groove pancreatitis)

	High certainty of GP diagnosis		Low certainty of GP diagnosis			
	2 x "certain" n = 18	1 x "certain" 1 x "possible" n = 21	1 x "certain" 1 x "other" n = 6	2 x "possible" n = 3	1 x "possible" 1 x "other" n = 9	2 x "other" n = 10
Groove pancreatitis (n = 33)	17	14	1		1	
Cancer ^a (n = 11)	1	4	2	2	2	
Acute pancreatitis ^b (n = 13)			1		3	9
Other ^c (n = 10)		3	2	1	3	1

GP = groove pancreatitis.

^a Ten pancreatic cancers and one gastric cancer.

^b Excluding groove pancreatitis.

^c Three chronic pancreatitis, three peptic ulcer diseases, two biliary infections, one abdominal trauma, and one spontaneous bacterial peritonitis.

two patients in the low-certainty group received GP diagnosis. These 33 patients formed the final study group.

Patients

Table 2 summarizes the basic characteristics of the study group. Briefly, the patients were mostly middle-aged (median 55 years) men with normal body weight (mean BMI 25 kg/m²). The great majority of them smoked, and all patients used alcohol at least moderately (Table 2).

Table 3 shows the symptoms and the worst laboratory values during the hospitalization. The vast majority of the patients had abdominal pain at the onset of the disease, but only half of the patients had the signs of acute pancreatitis. Only one third of the patients had weight loss. None of the patients had jaundice regardless of the fact that 13 patients had abnormal levels of serum bilirubin. Almost all patients had elevated inflammatory markers (Table 3), but only approximately one third had elevated tumor markers (CA19-9 or CEA) (Table 3).

All patients underwent CT scan, two thirds of the patients underwent MRI scan, and fifth of the patients underwent endoscopic ultrasound (Table 4). The radiological findings were dispersed, and the only relatively consistent findings were cystic lesions, which were detected in 26 patients (Table 4). GP was the primary diagnosis of the original radiological report in 21 cases, but in 14 patients the radiologist reported pancreatic cancer as a potential differential diagnosis (Table 4).

GP was histologically verified after pancreaticoduodenectomy in three patients. In addition, seven patients had a histological diagnosis of chronic pancreatitis out of whom one patient underwent a pancreaticoduodenectomy, one was biopsied during a gastrojejunostomy operation and the rest five had a core needle biopsy performed.

Treatment

Fig. 1 includes the flowchart of different treatment approaches. Conservative treatment was successful in nearly half of the

patients. Pancreaticoduodenectomy was necessary due to suspected pancreatic cancer on four patients (three as primary treatment and one after endoscopic treatments) and there were no other indications for pancreaticoduodenectomy in the final study group. The patients having obstructive symptoms needing an intervention were categorized based on the type of obstruction (Fig. 1). In patients with duodenal obstruction, duodenal dilatation was never sufficient for symptom control, and all five patients underwent gastrojejunostomy (Fig. 1). Duodenal stenting was tried for one patient, but it failed, and the duodenum was only dilated. Endoscopic retrograde cholangiopancreatography (ERCP) was performed on 14 patients (Fig. 1). Out of 19 patients requiring invasive treatment, 14 patients had two or more procedures. These 14 patients underwent a total of 55 endoscopic biliary and/or pancreatic duct stentings (mean 3.9 stentings per patient).

At the time of GP diagnosis, six patients were non-smokers or quit smoking. All of them were free of symptoms already after one year. Out of 26 patients who continued smoking, eight had similar or worse symptoms after one year. After five years five of these patients had still GP related symptoms. Smoking data was missing on one patient. There was not similar trend in symptom relief after quitting alcohol. Out of the 10 patients who quit using alcohol at the time of the diagnosis, two had GP related symptoms after five years. Respectively two out of 14 who continued using alcohol were symptomatic.

Clinical course of GP

Figs. 2–4 show the development of symptoms. Overall, the symptoms were reduced in the follow-up. After five years, 20 of the 26 patients who were still alive were asymptomatic (Fig. 2). This was evident in all patients receiving conservative treatment (Fig. 3) and in only 10 of the 16 patients receiving invasive treatment (Fig. 4). During the seven-year follow-up eight patients died. Nobody died of GP. The causes of death were suicide on two patients, two patients died of cardiac arrest, two patients

Table 2 Patient characteristics

	Groove pancreatitis (n = 33)
Median age - years (IQR)	55 (42–62)
Sex, male - n (%)	26
Mean Body Mass Index (SD) - kg/m ²	24,9 (4,3) ^a
Comorbidities - n	
Coronary disease/Myocardial infarction	0
Congestive heart failure	1
Peripheral vascular disease	2
Cerebrovascular disease	2
Hemiplegia	0
Dementia	0
COPD or asthma	5
Connective tissue disease	2
Liver disease (any grade)	0
Diabetes mellitus	6
Without complications	6
With complications	0
Kidney disease (moderate/severe)	0
Cancer	4
Local	2
Metastatic	2
Leukemia	0
Lymphoma	0
No comorbidities	17
Charlson Comorbidity Index	
Mild (0–2)	29
Moderate (3–4)	2
Severe (>5)	2
Mean Charlson Comorbidity Index (SD)	1.0 (1.7)
Medication, n	
Diabetes medication	6
NSAID, continuous usage	5
Opioids, continuous usage	3
Alcohol and tobacco, n	
Heavy alcohol consumption ^b	22
Moderate alcohol consumption	11
Total abstinence of alcohol	0
Smoker	28
Previous pancreatitis, n (%)	
Any	13
1	3
2	4

Table 2 (continued)

	Groove pancreatitis (n = 33)
3	3
4 or more	3

NSAID = non-steroidal anti-inflammatory drug.

^a Missing data on weight or height or both from seven patients.

^b The limit between a heavy drinker and a moderate user was set at 24 consumed units of alcohol per week when the consumption was reported. If no exact data was available, the patient was considered a heavy user if there were signs of harmful alcohol consumption (i.e. cerebellar degeneration or multiple rehabilitation episodes). One alcohol unit is a glass of wine or 0.33 L (11 oz) of beer.

died of cancer (one had metastatic ovarian cancer and one had metastatic colorectal cancer), and two patients had missing cause of death data.

Discussion

This population-based retrospective study shows that the radiological diagnosis of GP is difficult, the major portion of patients with GP do not require invasive treatment, and the majority of patients become asymptomatic within years with or without specific treatment.

GP can mimic malignant lesions,^{5,14,15,22} which makes its radiological diagnosis difficult. We had two certified gastrointestinal radiologists (HP and JK), who were able to diagnose GP with high certainty in 31 out of 33 of the patients with GP. Despite this five of the patients with radiologically high certainty of GP had cancer instead. An earlier study with similar re-evaluation of radiological images reports similar findings with a 26% cancer rate.¹⁴ The proportion of cancers in current study could have been even higher, if the radiologists analyzing the images had been less experienced or less specialized. If experience in radiological GP diagnostics is insufficient, misdiagnosing GPs as cancers may lead to unnecessary operations.

Previous studies have also shown that there are more cancers mimicking GP especially in non-smokers¹⁴ and in females.^{5,25} We found out that there were considerably more cancers specifically in non-smoking females than there were in smoking females. Thus, if a GP is suspected in a non-smoking female one should truly consider the possibility of cancer instead.

Our findings on the characteristics of GP patients are similar to previously published.^{6,7,10,14,26} GP patients were mostly middle-aged men with alcohol and tobacco consumption. Almost everyone had abdominal pain, whereas other symptoms were quite dispersed. In our cohort only one third of the patients had weight loss, which is less than in most previously published studies.^{5–7,10,14} There are also other reports stating that weight loss affects only a minority of GP patients.²⁶

Table 3 Symptoms and laboratory values

Groove pancreatitis (n = 33)		
Symptoms, n		
Abdominal pain	29	
Acute pancreatitis	17	
Nausea	15	
Vomiting	14	
Weight loss	12	
Jaundice	0	
Diarrhoea	4	
Glucose metabolism disorder	0	
Laboratory values^a		
	Abnormal, n	Median (IQR) of abnormal values
Haemoglobin, g/l ^b	22	104 (92–119)
CRP > 3 mg/l	32	144 (54–260)
Blood leukocytes > 8.2 (x10 ⁹ /l)	27	15.6 (13.5–20.1)
Serum amylase > 360 U/l (2 missing)	12	897 (524–1191)
Serum AFOS > 105 U/l	21	232 (160–478)
Serum ALAT U/l ^c	22	111 (78–267)
Serum bilirubin >20 μmol/l	13	31 (24–62)
Serum CA19-9 > 26 kU/l (5 missing)	10	86 (40–314)
Serum CEA > 5 μg/l (6 missing)	10	6.7 (5.7–10.6)
Serum triglycerides > 1.7 mmol/l (15 missing)	4	3.4 (2.6–40.7)
Serum Ca-ion > 1.3 mmol/l (9 missing)	4	1.50 (1.35–1.53)

CRP = C-reactive protein, AFOS = alkaline phosphatase, ALAT = alanine aminotransferase, CA 19–9 = carbohydrate antigen 19–9, CEA = carcinoembryonic antigen, Ca-ion = ionized calcium.

^a The most deviant laboratory values during the hospitalization are listed.
^b Abnormal level of haemoglobin for female is < 120 g/l and for male < 130 g/l.

^c Abnormal level of serum ALAT for female is > 35 U/l and for male > 50 U/l.

Elevated levels of tumor markers CA19-9 and CEA were observed in a third of the GP patients. Some previous studies suggest that the levels of CA19-9 are significantly higher in pancreatic cancer than in GP, but it has not been possible yet to determine a cut-off value for the differentiation of these two diseases.^{14,26}

Cystic lesions of the head of the pancreas and surroundings was the only radiological sign that was consistently present in most of our GP patients. Previously published papers have shown that cystic lesions are frequent in GP but rare in pancreatic carcinoma.^{5,14,15,27}

Almost half of the GP patients did not require any invasive interventions. All of these patients were asymptomatic after five

Table 4 Imaging modalities and radiological findings

Groove pancreatitis (n = 33)	
Imaging modality, n	
CT	33
MRI	20
PET-CT	3
Endo-US	7
Radiological findings, n	
Gastric retention	9
Biliary duct dilation	12
Pancreatic duct dilation	10
Duct of Santorini dilation	1
Pancreatic calcification	10
Thickening of duodenal wall (>10 mm)	11
Cystic lesions in/around pancreas	26
Pancreatic atrophy	4
Corpus/cauda atrophy	2
Atrophy of the whole pancreas	2
Primary radiological diagnosis, n^a	
Groove pancreatitis	21
Acute pancreatitis (excl. groove pancreatitis)	4
Chronic pancreatitis (excl. groove pancreatitis)	1
Pancreatic cancer	5
Other ^b	2
Radiological suspicion of malignancy, n	
What was the primary diagnosis in these cases?	
Groove pancreatitis	8
Acute pancreatitis (excl. groove pancreatitis)	1
Pancreatic cancer	5

CT = computed tomography, MRI = magnetic resonance imaging, PET-CT = Positron emission tomography–computed tomography, Endo-US = endoscopic ultrasound.

^a Primary diagnosis made by the clinical radiologist at the time of the disease.

^b One intraductal papillary mucinous neoplasm and one sequel of duodenal ulcer.

years. Regardless of the treatment strategy three-quarters of the patients had full resolution in symptoms after five years. Previous studies show a similar rate of symptom relief in surgically treated patients.^{4,7,10,17} In our center, the treatment strategy is a step-up approach based on symptoms. The first line treatment is conservative treatment with pain medication, unless the patient has jaundice or gastric outlet obstruction. A recent study by Lekkerkerker et al. showed that conservative treatment was successful in almost half of their GP patients, which is similar to our rate. Another recent study by Balduzzi et al. also has encouraging findings on the conservative treatment of GP. In

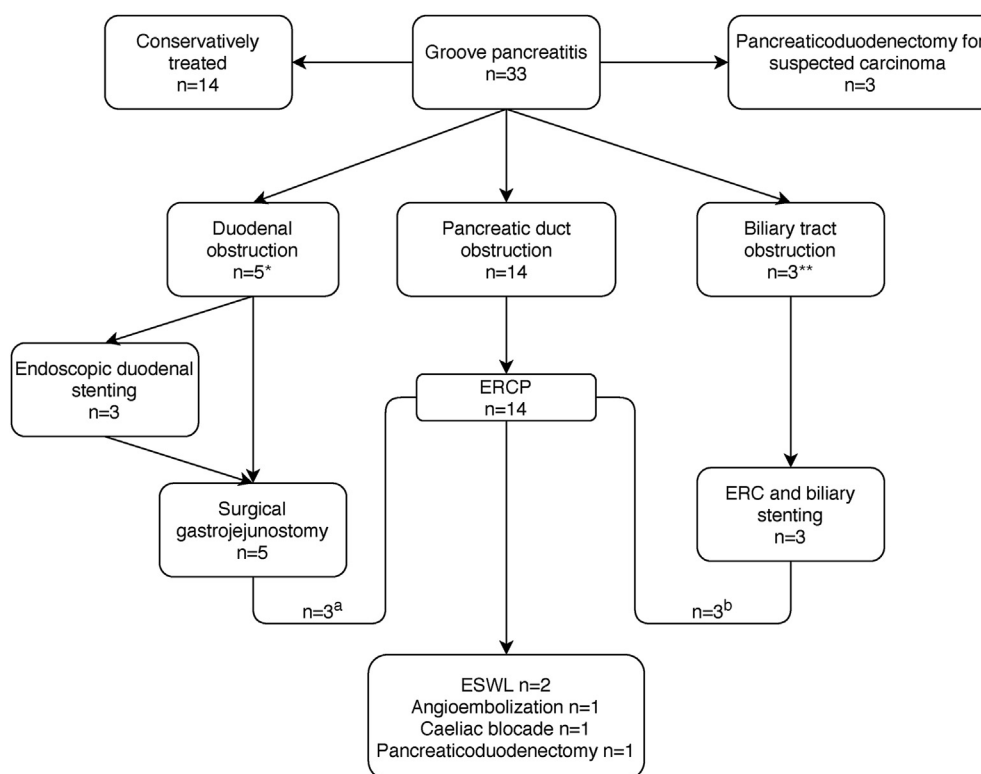


Figure 1 Flowchart of the treatments the patients received based on the type of obstruction. ^a3 patients had both duodenal and pancreatic duct obstruction, ^b3 patients had both biliary and pancreatic duct obstruction

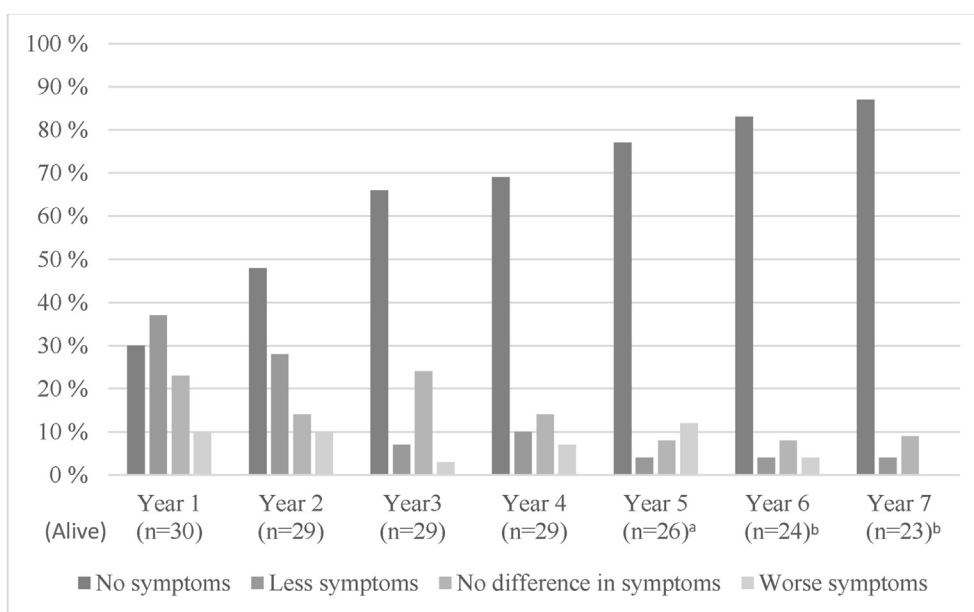


Figure 2 The development of symptoms in patients with groove pancreatitis. The data from deceased patients and missing data are removed. ^aMissing data from one patient. ^bMissing data from two patients

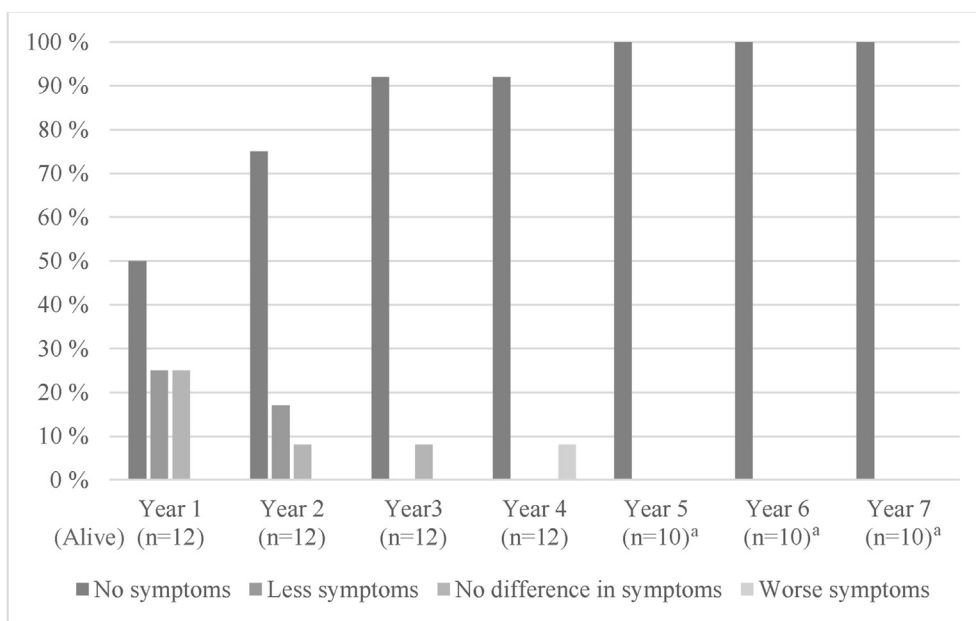


Figure 3 The development of symptoms in patients receiving conservative treatment for groove pancreatitis. The data from deceased patients and missing data are removed. ^aMissing data from one patient

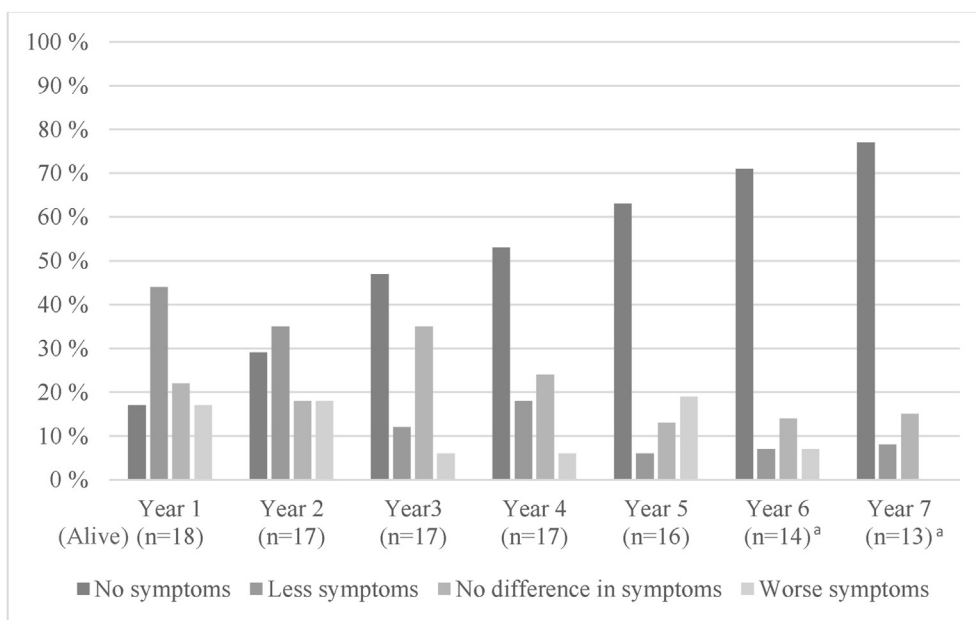


Figure 4 The development of symptoms in surgically or endoscopically treated patients with groove pancreatitis. The data from deceased patients and missing data are removed. ^aMissing data from one patient

their relatively large cohort surgically and conservatively treated patients did not show differences in the quality of life or pain control. These findings also support conservative treatment as the first-line option for GP.

Although conservative treatment is the first-line option, a bit more than half of our patients required invasive treatment at

some point, and three-quarters of them had two or more procedures. Pancreaticoduodenectomies were performed only if there was a cancer suspicion.

Most of the previous studies focus on the surgical treatment of GP and possibly do not report conservatively treated patients,^{4,7,16–18} which makes comparison to our cohort difficult.

Our study has limitations. It is a retrospective series with all its inherited biases, and caution is needed in interpreting the results. The cohort size is small, but still, one of the biggest in the literature. In a recent systematic literature review on GP the authors included eight studies out of 41¹⁷ that had cohorts from 12 to 105 patients (median: 37),^{4,6–8,10,13,16,28} and only four studies had a bigger GP cohort than ours.^{4,6,7,10} The population-based approach and including all GP patients regardless of the treatment strategy is certainly a strength of this study. However, some patients with GP might have been missed, if groove pancreatitis had not been suspected at all and the searched keywords ‘groove’ or ‘paraduod*’ were not used in patient charts.

In conclusion, the diagnosis of GP remains difficult, and cancer must be kept in mind whenever GP is suspected. Conservative treatment is a reasonable first-line treatment, and the natural course of GP is favorable in a major portion of the patients. Invasive interventions are indicated for specific complications such as biliary or gastric outlet obstruction. Surgery is rarely necessary for symptom control.

Funding

Funding for the study was provided through grants from Helsinki University Hospital (Tarvainen T, Sallinen V) and Vatsatautien tutkimussäätiö Foundation, Mary and Georg Ehrnrooth’s Foundation (Sallinen V).

Conflicts of interest

The authors declare the following financial interests/personal relationships which may be considered as potential competing interests: Dr. Sallinen declares research funding of more than £5000 received from Academy of Finland and Finnish Cancer Foundation. Other authors declare having no known competing financial interests or personal relationships that could have appeared to influence the work reported in this paper.

References

- Becker V, Mischke U. (1991) Groove pancreatitis. *Int J Pancreatol* 10: 173–182. <https://doi.org/10.1007/bf02924155>.
- Stolte M, Weiss W, Volkholz H, Rosch W. (1982) A special form of segmental pancreatitis: "groove pancreatitis. *Hepato-Gastroenterology* 29:198–208.
- Adsay NV, Zamboni G. (2004) Paraduodenal pancreatitis: a clinicopathologically distinct entity unifying "cystic dystrophy of heterotopic pancreas", "para-duodenal wall cyst", and "groove pancreatitis. *Semin Diagn Pathol* 21:247–254. <https://doi.org/10.1053/j.semdp.2005.07.005>.
- Casetti L, Bassi C, Salvia R, Butturini G, Graziani R, Falconi M *et al.* (2009) Paraduodenal pancreatitis: results of surgery on 58 consecutive patients from a single institution. *World J Surg* 33:2664–2669. <https://doi.org/10.1007/s00268-009-0238-5>.
- Arora A, Dev A, Mukund A, Patidar Y, Bhatia V, Sarin SK. (2014) Paraduodenal pancreatitis. *Clin Radiol* 69:299–306. <https://doi.org/10.1016/j.crad.2013.07.011>.
- Arvanitakis M, Rigaux J, Toussaint E, Eisendrath P, Bali MA, Matos C *et al.* (2014) Endotherapy for paraduodenal pancreatitis: a large retrospective case series. *Endoscopy* 46:580–587. <https://doi.org/10.1055/s-0034-1365719>.
- Egorov VI, Vankovich AN, Petrov RV, Starostina NS, Butkevich A, Sazhin AV *et al.* (2014) Pancreas-preserving approach to "paraduodenal pancreatitis" treatment: why, when, and how? Experience of treatment of 62 patients with duodenal dystrophy. *Biomed Res Int*, 185265. <https://doi.org/10.1155/2014/185265>.
- Jouannaud V, Coutarel P, Tossou H, Butel J, Vitte RL, Skinazi F *et al.* (2006) Cystic dystrophy of the duodenal wall associated with chronic alcoholic pancreatitis. Clinical features, diagnostic procedures and therapeutic management in a retrospective multicenter series of 23 patients. *Gastroenterol Clin Biol* 30:580–586. [https://doi.org/10.1016/s0399-8320\(06\)73231-6](https://doi.org/10.1016/s0399-8320(06)73231-6).
- Pezzilli R, Santini D, Calculli L, Casadei R, Morselli-Labate AM, Imbrogno A *et al.* (2011) Cystic dystrophy of the duodenal wall is not always associated with chronic pancreatitis. *World J Gastroenterol* 17: 4349–4364. <https://doi.org/10.3748/wjg.v17.i39.4349>.
- Rebours V, Levy P, Vullierme MP, Couvelard A, O’Toole D, Aubert A *et al.* (2007) Clinical and morphological features of duodenal cystic dystrophy in heterotopic pancreas. *Am J Gastroenterol* 102:871–879. <https://doi.org/10.1111/j.1572-0241.2007.01091.x>.
- Mittal PK, Harri P, Nandwana S, Moreno CC, Muraki T, Adsay V *et al.* (2017) Paraduodenal pancreatitis: benign and malignant mimics at MRI. *Abdom Radiol (NY)* 42:2652–2674. <https://doi.org/10.1007/s00261-017-1238-9>.
- Kim DU, Lubner MG, Mellnick VM, Joshi G, Pickhardt PJ. (2017) Heterotopic pancreatic rests: imaging features, complications, and unifying concepts. *Abdom Radiol (NY)* 42:216–225. <https://doi.org/10.1007/s00261-016-0874-9>.
- Zaheer A, Haider M, Kawamoto S, Hruban RH, Fishman EK. (2014) Dual-phase CT findings of groove pancreatitis. *Eur J Radiol* 83: 1337–1343. <https://doi.org/10.1016/j.ejrad.2014.05.019>.
- Lekkerkerker SJ, Nio CY, Issa Y, Fockens P, Verheij J, Busch OR *et al.* (2016) Clinical outcomes and prevalence of cancer in patients with possible groove pancreatitis. *J Gastroenterol Hepatol* 31:1895–1900. <https://doi.org/10.1111/jgh.13376>.
- Triantopoulou C, Dervenis C, Giannakou N, Papailiou J, Prassopoulos P. (2009) Groove pancreatitis: a diagnostic challenge. *Eur Radiol* 19:1736–1743. <https://doi.org/10.1007/s00330-009-1332-7>.
- Rahman SH, Verbeke CS, Gomez D, McMahon MJ, Menon KV. (2007) Pancreatico-duodenectomy for complicated groove pancreatitis. *HPB* 9:229–234. <https://doi.org/10.1080/13651820701216430>.
- Kager LM, Lekkerkerker SJ, Arvanitakis M, Delhaye M, Fockens P, Boermeester MA *et al.* (2017) Outcomes after conservative, endoscopic, and surgical treatment of groove pancreatitis: a systematic review. *J Clin Gastroenterol* 51:749–754. <https://doi.org/10.1097/mcg.0000000000000746>.
- Aguilera F, Tsamalaizde L, Raimondo M, Puri R, Asbun HJ, Stauffer JA. (2018) Pancreaticoduodenectomy and outcomes for groove pancreatitis. *Dig Surg* 35:475–481. <https://doi.org/10.1159/000485849>.
- Manzelli A, Petrou A, Lazzaro A, Brennan N, Soonawalla Z, Friend P. (2011) Groove pancreatitis. A mini-series report and review of the literature. *Jop* 12:230–233.
- Tezuka K, Makino T, Hirai I, Kimura W. (2010) Groove pancreatitis. *Dig Surg* 27:149–152. <https://doi.org/10.1159/000289099>.
- Beaulieu S, Vitte RL, Le Corquille M, Petit Jean B, Eugene C. (2004) [Endoscopic drainage of cystic dystrophy of the duodenal wall: report of three cases]. *Gastroenterol Clin Biol* 28:1159–1164. [https://doi.org/10.1016/s0399-8320\(04\)95198-6](https://doi.org/10.1016/s0399-8320(04)95198-6).

- 22.** Ishigami K, Tajima T, Nishie A, Kakihara D, Fujita N, Asayama Y *et al.* (2010) Differential diagnosis of groove pancreatic carcinomas vs. groove pancreatitis: usefulness of the portal venous phase. *Eur J Radiol* 74:e95–e100. <https://doi.org/10.1016/j.ejrad.2009.04.026>.
- 23.** Balduzzi A, Marchegiani G, Andrianello S, Romeo F, Amodio A, De Pretis N *et al.* (2020) Pancreaticoduodenectomy for paraduodenal pancreatitis is associated with a higher incidence of diabetes but a similar quality of life and pain control when compared to medical treatment. *Pancreatology* 20:193–198. <https://doi.org/10.1016/j.pan.2019.12.014>.
- 24.** Jaakkola M, Nordback I. (1993) Pancreatitis in Finland between 1970 and 1989. *Gut* 34:1255–1260. <https://doi.org/10.1136/gut.34.9.1255>.
- 25.** Kalb B, Martin DR, Sarmiento JM, Erickson SH, Gober D, Tapper EB *et al.* (2013) Paraduodenal pancreatitis: clinical performance of MR imaging in distinguishing from carcinoma. *Radiology* 269:475–481. <https://doi.org/10.1148/radiol.13112056>.
- 26.** Jun JH, Lee SK, Kim SY, Cho DH, Song TJ, Park DH *et al.* (2018) Comparison between groove carcinoma and groove pancreatitis. *Pancreatology* 18:805–811. <https://doi.org/10.1016/j.pan.2018.08.013>.
- 27.** Gabata T, Kadoya M, Terayama N, Sanada J, Kobayashi S, Matsui O. (2003) Groove pancreatic carcinomas: radiological and pathological findings. *Eur Radiol* 13:1679–1684. <https://doi.org/10.1007/s00330-002-1743-1>.
- 28.** Oza VM, Skeans JM, Muscarella P, Walker JP, Sklaw BC, Cronley KM *et al.* (2015) Groove pancreatitis, a masquerading yet distinct clinicopathological entity: analysis of risk factors and differentiation. *Pancreas* 44:901–908. <https://doi.org/10.1097/mpa.0000000000000351>.