



UNIVERSITY OF HELSINKI

<https://helda.helsinki.fi>

Toy gun eye injuries - eye protection needed Helsinki ocular trauma study

Haavisto, Anna-Kaisa; Sahraravand, Ahmad; Puska, Paivi; Leivo, Tiina

2019-06

John Wiley and Sons Inc.

<http://hdl.handle.net/10138/323363>

Haavisto, A-K, Sahraravand, A, Puska, P & Leivo, T 2019, 'Toy gun eye injuries - eye protection needed Helsinki ocular trauma study', *Acta Ophthalmologica*, vol. 97, no. 4, pp. 430-434. <https://doi.org/10.1111/aos.13948>

Downloaded from Helda, University of Helsinki institutional repository. <https://helda.helsinki.fi>
This is an electronic reprint of the original article.
This reprint may differ from the original in pagination and typographic detail.
Please cite the original version.

Toy gun eye injuries – eye protection needed Helsinki ocular trauma study

Anna-Kaisa Haavisto,  Ahmad Sahraravand,  Päivi Puska and Tiina Leivo, 

University of Helsinki and Helsinki University Eye Hospital, Helsinki, Finland

ABSTRACT.

Purpose: We report the epidemiology, findings, treatment, long-term outcome and use of resources for eye injuries caused by toy guns in southern Finland.

Methods: All new patients injured by toy guns in one year (2011–2012) and treated at Helsinki University Eye Hospital were included. Follow-ups occurred at 3 months and 5 years.

Results: Toy guns caused 15 eye traumas (1% of all eye traumas). Most patients were male (n = 14) and children aged under 16 years (n = 13). Toy guns involved were airsoft guns (n = 12), pea shooters (n = 2) and paintball (n = 1). Eleven patients did not use protective eyewear, and four patients discontinued their use during the game. Seven patients were not active participants in the game. Blunt ocular trauma was the primary diagnosis in 13 patients and corneal abrasion in two. Seven patients had retinal findings. In the 5-year follow-up, eight of 15 patients had abnormal ocular findings: three had artificial intraocular lens, two iridodialysis, and one each retinal plumb, mydriasis or iris tear. None had glaucoma. Seven patients had permanent subjective impairment due to pain, lowered visual acuity, blur or difficulty in focusing. Four patients needed seven operations. The number of outpatient visits was 90. One patient required hospitalization.

Conclusion: Toy guns cause serious eye traumas. No glaucoma was found. Proper use of toy guns and protective eyewear during the whole game should be emphasized to both players and bystanders. We recommend that in Finland the selling of airsoft guns be placed under the Firearms Act to make the hazards of airsoft guns known.

Key words: airsoft gun – eye injury – paintball – pea shooter – pellet gun – Toy gun

Acta Ophthalmol.

© 2018 Acta Ophthalmologica Scandinavica Foundation. Published by John Wiley & Sons Ltd

doi: 10.1111/aos.13948

Introduction

Toy guns are popular toys in children's play, likewise paintballs in adults' leisure time. Airsoft guns, also called pellet toy guns, resemble real guns in appearance and shoot 6 mm plastic pellets. Paintball pellets are larger, 17–18 mm spherical balls containing liquid (Nemet et al. 2016). Both can reach a velocity of up to 110 m/s (Duma et al.

2006; Kennedy et al. 2008). Pea shooters are often self-made. Without proper protective eyewear, toy guns pose a danger to eyesight due to their extreme energy.

A hit from a pellet typically causes blunt ocular trauma. Initial findings are often corneal erosion and oedema, bleeding in anterior chamber, vitreous, and retina, traumatic cataract, retinal commotion along with retinal and

irideal tear and changes in intraocular pressure (IOP) (Fleischhauer et al. 1999; Saunte & Saunte 2006; Ramstead et al. 2008; Kratz et al. 2010; Jovanović et al. 2012; Haavisto et al. 2017). Globe ruptures have been reported from paintballs and also a few cases from airsoft guns (Greven & Bashinsky 2006; Adyanthaya et al. 2012; Jovanović et al. 2012; Nemet et al. 2016). Optic neuropathies have also arisen from paintballs (Thach et al. 1999). Traumatic glaucoma may present even years after a blunt ocular trauma (Kaufman & Tolpin 1974; Girkin et al. 2005; Ozer et al. 2007; Lee et al. 2017).

The incidence of toy gun eye injuries has been reported to be 0.3 eye injuries/100 000 population in Denmark (Saunte & Saunte 2006) and 2.5/100 000 in Israel (Kratz et al. 2010). In Hong Kong, 12% of all eye-injured paediatric patients were harmed by toy guns (Poon et al. 1998). Toy guns cause notable morbidity due to the lifelong risk for glaucoma for injured parties.

The few studies of toy gun eye accidents are often case reports or retrospective studies (Fleischhauer et al. 1999; Ramstead et al. 2008; Adyanthaya et al. 2012; Nemet et al. 2016), the follow-up is short (Saunte & Saunte 2006), and airsoft guns are not distinguished from other types of air guns (Lee & Fredrick 2015). To our knowledge, there are no long-term follow-up studies of toy gun-injured patients.

The aim of this study was to present the epidemiology, findings, treatment, long-term outcome and use of resources for eye injuries caused by toy guns in Finland.

Materials and Methods

Patients injured by projectile toy guns were identified in the Helsinki Eye Trauma Study, which comprehends all new eye trauma patients taken into care at the Emergency Clinic of Helsinki University Eye Hospital (HUEH) during a one-year period between May 1, 2011 and April 30, 2012. The HUEH is a tertiary and secondary eye care hospital, with a population base of 1.5 million.

Patients with eye injuries were prospectively identified in the emergency clinic. They were given a questionnaire about the trauma-causing event and circumstances. In the absence of the questionnaire, the information was gathered from hospital records. In addition, to identify all patients with eye injury, the hospital records were accessed and diagnoses indicating eye injury were verified directly or indirectly by ICD-10 diagnoses. Age, gender, laterality, possible amblyopia, detailed status findings at first visit, diagnoses and treatments were recorded from hospital records.

Eye traumas were divided into five primary diagnosis groups: blunt ocular trauma (BOT), wound in eyelid or periorbital area, orbital fracture, open globe trauma (OGT) and mild superficial trauma in the eye or periorbital area. Possible secondary and tertiary diagnoses were recorded. In case of binocular eye injury, the more seriously injured eye was observed.

In the first phase, three months after the trauma, visual acuity (VA), intraocular pressure (IOP) and clinically significant ocular findings were recorded. The need for lifelong follow-up and permanent disability were estimated, and the number of surgical procedures was recorded.

In the second phase, 5–6 years after the trauma, the patients were invited to a thorough eye examination including best corrected visual acuity (BCVA), IOP (ICare and Goldmann applanation tonometry), gonioscopy, slit lamp biomicroscopy and dilated fund examination. All patients underwent visual field (VF) examination by Octopus G dynamic program (Haag-Streit AG, Bern, Switzerland) or Goldmann in case of lack of co-operation. Peripapillary nerve fibre layer (NFL) thickness was measured using optical coherence tomography (OCT)

(Heidelberg Engineering, Heidelberg, Germany). Stereo disc photographs and fundus NFL photographs were taken. In case of lack of co-operation, IOP was measured with Icare (Icare TAOi, Icare Finland Oy, Vantaa, Finland). Two patients were lost to follow-up. One of them was interviewed by telephone.

Resource use was estimated by the number of outpatient visits, duration of hospitalization and medication, number of operations performed, and need for sick leave or activity restriction. If the sick leave or sports restriction was not recorded, their need was estimated based on clinical findings and international recommendations (Recchia et al. 2002; Walton et al. 2002; Tsai et al. 2011; Gerstenblith & Rabinowitz 2012).

Injuries were classified by the Birmingham Eye Trauma Terminology System (BETTS) (Kuhn et al. 2004). Year was divided into four seasons: spring (March, April, May), summer (June, July, August), autumn (September, October, November) and winter (December, January, February).

The epidemiological data were analysed, distribution represented, and percentages calculated from the reported results.

The study protocol was approved by the Ethics Committee of the Helsinki-Uusimaa Hospital district and followed the tenets of the Declaration of Helsinki.

Results

Epidemiology

Fifteen eye injuries, 1% of all eye injuries ($n = 1151$), were caused by a toy gun over a one-year period. The annual incidence was 1.0 eye injuries/100 000 population taking into account all toy guns, 1.9/100 000 in males (0.1/100 000 in females). Taking into account only all airsoft guns the incidence was 0.8/100 000. Patients' age range was from 3 to 47 years (mean 14.7 years), with a male predominance of 93% (14/15). The majority of injuries ($n = 9$) took place during primary school age (7–12 years) (Fig. 1). Nine traumas were in the right and six in the left eye. There were no binocular traumas and none was in an amblyopic eye. No one

had a second eye injury during the follow-up.

Twelve traumas were caused by an airsoft gun, two by a pea shooter and one by a paintball. The location of the hit is seen in Table 1. The main diagnosis was blunt ocular trauma in 13 patients (87%) and mild superficial trauma in two patients (13%). According to BETTS, all traumas were closed.

Most of the accidents occurred in the summer ($n = 7$), less in the autumn ($n = 4$), winter ($n = 3$) or spring ($n = 1$). Four accidents took place inside a house, ten outdoors, four of which occurred in a private courtyard. Information was lacking for one patient. Seven patients were playing a game during the accident, five were handling a toy gun outside an active game, two were bystanders and in one case the circumstances were unknown.

Protective eyewear was used by four (27%) of 15 patients, all during a game. The accident took place when the game ended ($n = 2$), while cleaning the glasses ($n = 1$) or when wrong-sized glasses had fallen ($n = 1$).

First visit and 3-month follow-up

Significant status findings initially and after 5 years are seen in Table 1.

At first visit, eight patients had VA less than 0.5 Snellen equivalent. One could not be defined because of young age. Three patients needed medication for elevated IOP for 2–6 weeks. Medication was started 0–21 days after the accident. The most significant findings were as follows: macroscopic or microscopic hyphema ($n = 13$), iridial trauma ($n = 2$), traumatic cataract ($n = 1$) and posterior findings ($n = 7$).

At the end of the 3-month follow-up, one patient was operated on for retinal tear and three for traumatic cataract. One patient had rebleeding 2 months after the accident and was treated with tranexamic acid. Four patients had VA 0.4 Snellen equivalent or less, and all had normal IOP. Thirteen patients were estimated to need a lifelong follow-up due to elevated risk for glaucoma after BOT. Five patients were estimated to have a permanent disability due to iridodialysis and glare ($n = 2$), lowered VA ($n = 2$), or lack of accommodation in young age because of an IOL (intraocular lens) ($n = 1$). No other operations were estimated to take place in future.

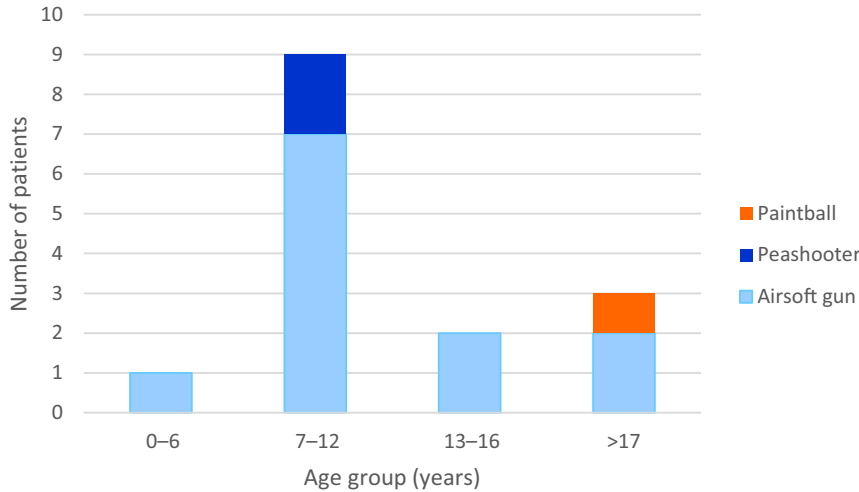


Fig. 1. Distribution of eye injuries and type of toy gun causing injury in different age groups.

5-year follow-up

Findings

At the 5-year follow-up, 8/13 patients had abnormal findings; seven were injured by an airsoft gun and one by a paintball. Pea shooters did not cause subjective impairment or abnormal

findings, although one case was lost to follow-up.

BCVA was normal (0.9–1.5) in all but one patient who was injured by an airsoft gun and had only light perception without clinical explanation.

Of patients injured by airsoft guns, 7/12 (58%) had abnormal findings, including iridodialysis or torn iris (n = 3), IOL (n = 3), pigment in vitreous (n = 2), posterior capsular opacity (PCO) (n = 2), retinal plomb (n = 1) or mydriasis (n = 1).

The only paintball-injured patient had diffuse tearing in the iris stroma.

Glaucoma was not diagnosed in any patient, and IOP was normal (<22 mmHg) in all patients. Four patients had a few relatively nonglaucomatous depressions in Octopus VF testing. One patient had abnormal findings in Goldmann VF testing (suspected malingering); however, no difference was present in optic disc cupping between the injured and the healthy eye. Peripapillary NFL thickness was normal in all patients, and no defects were seen in NFL photographs.

Subjective impairment

Subjective impairment was reported by seven patients (47%), six of whom were injured by airsoft guns. Airsoft trauma caused pain (n = 4), blurred vision (n = 2), lowered VA (n = 1) and glare

Table 1. Significant status findings at first visit and in the 5-year follow-up. Patient number 5 was interviewed by telephone.

	BCVA		First visit				5-year-follow-up					
	Age	Initial	5 year	IOP	Dg	Location	Abnormal findings	IOP elevation	PD	Abnormal findings	Subjective impairment	Operated
Airsoft pellet gun												
1	11	0.1	1.1	17	BOT	Cornea	Iridodialysis	–	Yes	Iridodialysis	–	–
2	9	0.63	1.4	14	Abrasion	Cornea	–	–	–	–	–	–
3	10	0.7	1.1	9	BOT	Cornea	Macular oedema	–	–	–	–	–
4*	3	NA	1.0	17	BOT	Eyelid/sclera	Retinal tear	–	Yes	Retinal plomb	Pain	Yes
5	47	0.5	NA	14	BOT	NA	Berlin oedema	–	–	NA	Blur	–
6	9	0.05	0.9	17	BOT	Cornea	–	–	–	IOL, pigment in vitreous	Pain	Yes
7	14	0.4	1.5	7	BOT	Cornea	Iridodialysis, retinal bleeding and oedema	–	Yes	Iridodialysis, pigment in vitreous	Pain	–
8	9	CF	1.0	21	BOT	Cornea	Cataract	Yes	Yes	IOL, PCO	Blur	Yes
9	14	CF	1.25	21	BOT	Cornea	–	–	–	–	–	–
10	12	0.4	1.25	14	Abrasion	Eyelid/cornea	–	–	–	–	–	–
11	11	0.4	1.1	22	BOT	Cornea	Berlin oedema	Yes	–	IOL, sphincter rupture	–	Yes
12	21	0.1	LP	16	BOT	Cornea	Macular oedema, vitreous bleeding	–	Yes	Mydriasis	Low VA, glare, pain	–
Pea shooter												
13	11	0.8	NA	32	BOT	Limbus	–	Yes	–	NA	NA	–
14	8	1	1.5	12	BOT	Eyelid	–	–	–	–	–	–
Paintball												
15	32	0.6	1.0	18	BOT	Eyelid	Berlin oedema	–	–	Tears in iris	Focus	–

BCVA = best corrected visual acuity; BOT = blunt ocular trauma; CF = counting fingers; Dg = main diagnosis; IOL = intraocular lens; IOP = intraocular pressure; LP = light perception; NA = data not available; PCO = posterior capsule opacity; PD = estimated permanent disability; VA = visual acuity.

* Female.

($n = 1$). Pain was described in three patients to be occasionally recurring, lasting from a few seconds to up to three days. In one patient, pain was more severe and almost constant and along with lowered VA and glare caused impairment. The patient injured by a paintball had difficulty in focusing.

Operations and use of resources

Altogether seven operations were performed on four patients, all of whom were injured by airsoft guns; the operations comprised three cataract surgeries (one additional cataract surgery and PCO opening were needed after the 3-month follow-up), one retinal cryo-coagulation, one retinal plomb insertion and two PCO removals. Traumatic cataracts were operated on 1–7 months, retinal cryo-coagulation 4 weeks and retinal plomb insertion 11 weeks after the trauma. Posterior capsular opacity (PCO) openings were performed 3 and 11 weeks after cataract surgeries. There were 90 outpatient visits and one hospitalization day.

Discussion

This is the first population-based long-term follow-up study of toy gun eye accidents in Finland presenting the epidemiology, clinical findings, diagnoses, treatments, outcomes and resource use for toy gun eye injuries.

Our study reveals that the majority of toy gun accidents are serious. Initially, blunt ocular trauma was diagnosed in 13 (87%), posterior findings in seven (47%), iridodialysis in two (15%) and cataract in one patient (7%). At the 5-year control, eight patients (62%) had abnormal clinical findings: IOL in three (20%), iridodialysis or irideal tearing in four (27%), retinal plomb in one (7%) and mydriasis in one (7%). Subjective impairment was reported by seven patients (54%). Altogether seven operations were performed on four patients.

A weakness of our study is the small number of patients. However, almost all patients (13/15, 87%) attended the 5-year re-examination.

The incidence of airsoft gun accidents has been reported infrequently. In our study, the incidence of 0.8/100 000 patients is in accordance with previous studies. In Israel, the

incidence of 2.5/100 000 (Kratz et al. 2010) is markedly higher than in our study or in Denmark 0.3/100 000 (Saunte & Saunte 2006). According to Kratz et al. (2010), in Israel airsoft guns are purchased without any age restriction, which may explain the higher incidence. We also found that toy guns comprised less (6%) of all children's eye accidents in Finland than reported in Hong Kong (12%) (Poon 1998).

The mean age of airsoft and pea shooter patients (13.5 years) was less than that of the paintball patients (32 years). In previous reports of airsoft patients, the mean age has varied from 9.8 years to 18 years (Fleischhauer et al. 1999; Saunte & Saunte 2006; Ramstead et al. 2008; Kratz et al. 2010). In the studies of Saunte & Saunte (2006) and Fleischhauer et al. (1999), the age, 13 years and 13.9 years, respectively, is similar to ours. In paintball studies, the mean age has been 16–22 years (Thach et al. 1999; Fineman et al. 2000; Greven & Bashinsky 2006; Baath et al. 2007; Nemet et al. 2016). Consequently, the mean age in our study is consistent with earlier reports, and airsoft guns and pea shooters appear to be more popular among younger people than paintballs.

Airsoft guns produced similar clinical findings here as in previous studies: posterior findings in 47% versus 12.5–55.6% and traumatic cataract in 23% versus 1.7–33.3% of patients (Fleischhauer et al. 1999; Saunte & Saunte 2006; Ramstead et al. 2008; Kratz et al. 2010). The follow-up time in earlier studies ranged from a mean of 6.5 days (1–54 days) (Saunte & Saunte 2006) to a mean of 8.8 months (0.5–24 months) (Fleischhauer et al. 1999). The short follow-up time may explain the low incidence (3.0%) of traumatic cataracts found by Saunte & Saunte (2006), although the lowest incidence of 1.7% was reported by Kratz et al. (2010) who had a follow-up of 7.6 months. It is noteworthy that in our study all three cataract patients were operated on when they were aged under 12 years, therefore, lacking normal accommodation.

Irideal trauma was found in 33% of our patients, which is similar to traumatic mydriasis in 25–44% and iris dialysis in 21% of patients in previous

studies (Fleischhauer et al. 1999; Ramstead et al. 2008; Saunte & Saunte 2008; Kratz et al. 2010; Staffieri et al. 2010).

Paintball eye accidents have yielded several devastating findings, from globe ruptures to optic neuropathies (Thach et al. 1999; Greven & Bashinsky 2006; Nemet et al. 2016). Our study included only one paintball-injured patient who was diagnosed with central retinal oedema and irideal tear and had subsequent difficulty in focusing.

Pea shooters induced two traumas. One patient had BOT, hyphema and elevated IOP; this patient was lost to follow-up. Another patient had BOT with normal IOP, and in the 5-year follow-up the status was normal. We found no previous studies concerning pea shooters. However, it is meaningful to note that even pea shooters can produce severe eye trauma.

Interestingly, glaucoma was not found in any of the patients despite thorough examinations and a relatively long follow-up. One patient diagnosed with BOT, hyphema and elevated IOP had a potential risk for glaucoma, but was lost to follow-up. Altogether, 40% ($n = 6$) of patients had either traumatic cataract or injuries to the iris or both. In the study of Sihota et al. (1995), traumatic cataract, especially with iris trauma, was associated with an increased risk for glaucoma. In their prospective review of 100 patients with trauma-associated glaucoma, all patients had two of the following: traumatic cataract, angle recession more than 180 degrees, significant iris trauma or displacement of lens. Glaucoma was diagnosed at 1 month to over 20 years after the trauma. A long follow-up is therefore needed since glaucoma may present even decades after the eye trauma.

With two exceptions, all patients with abnormal clinical findings (five of seven patients) had also subjective impairment. This is two more than estimated at 3 months after the accident. Four patients complained of pain, which is unfortunate, particularly in view of their young age. In one patient, the pain was more intense and presented together with distinctly lowered VA and glare. There was no obvious reason for pain of any of the patients. In one patient, impaired focusing hindered the photography

hobby. Blurry vision was described by two patients: one (interviewed by telephone) while bending and the other in the temporal side of the visual field, possibly due to PCO. Glare was described by only one of five patients with irideal trauma. We found no earlier studies reporting subjective impairment of toy gun-caused eye injuries in long-term follow-up.

Although four patients (27%) in our study used protective eyewear during the game (three airsoft, one paintball), the glasses had been abandoned at the time of the accident because of discomfort; the protective eyeglasses were described as too big, dirty or misty. Similarly, Fineman et al. (2000) had noted that 60% of patients harmed by a paintball had initially been wearing protective eyewear, but 86% had removed them; 33% because of fogging and 17% because of paint splatter. Compliance in using protective eyewear would increase if they were more comfortable.

In our study, 53% (n = 8) of accidents took place outside of organized war games; two of the patients were bystanders and in six cases a toy gun had been used outside of an agreed game. The toy gun had been used, for instance, at home, believing that the gun was not loaded when aimed at someone. In the study of Greven & Bashinsky (2006), 47% of paintball eye injuries occurred outside official or unofficial war games and included also assaults. There were no assaults in our study. The dangerousness of toy guns outside games appears to be unrecognized, leading to their irresponsible use.

In Finland, airsoft guns are classified as airguns, but product marketing and the safety of toy guns and protective equipment are controlled by The Finnish Safety and Chemical Agency. Sellers are advised to inform buyers about the regulations and hazards. If airsoft guns were to fall under the Firearms Act, their hazards might be better understood. In arranged airsoft and paintball games, specific protective eyewear is obligatory (pks-airsoft.net). In Denmark, the law prohibits the use of pellet toy guns by persons aged under 18 years (Saunte & Saunte 2006).

Toy guns cause serious eye traumas, although no glaucoma was found in Finnish patients in the 5-year follow-up. More attention should be paid to improving the usability of protective eyewear. Proper use of toy guns and

protective eyewear throughout the game should be emphasized to both players and bystanders. We recommend that in Finland the selling of airsoft guns be placed under the Firearms Act to make the hazards of airsoft guns known.

References

- Adyanthaya R, Chou T & Parhiz A (2012): Penetrating ocular trauma from airsoft gun. *Arch Ophthalmol* **130**: 944–945.
- Baath J, Ells AL, Kherani A & Williams RG (2007): Severe retinal injuries from paintball. *Can J Ophthalmol* **42**: 620–623.
- Duma S, Kennedy E & Ng T (2006): Evaluating eye injury risk of airsoft pellet guns by parametric risk functions. *ARVO Annual Meeting Abstract. Investigative Ophthalmology & Visual Science* **47**: 4680.
- Fineman M, Ficher D, Jeffers J, Buerger D & Repke C (2000): Changing trend in Paintball-sport related Ocular Injuries. *Arch Ophthalmol* **118**: 60–64.
- Fleischhauer J, Goldblum D, Frueh B & Koerner F (1999): Ocular injuries caused by airsoft guns. *Arch Ophthalmol* **117**: 1437–1439.
- Gerstenblith A & Rabinowitz M (2012): *The Wills Eye Manual*, 6th edn. Office and Emergency Room Diagnosis and Treatment of Eye Disease. Philadelphia, PA: Lippincott Williams & Wilkins.
- Girkin C, McGwin G, Long C, Morris R & Kuhn F (2005): Glaucoma after Ocular Contusion. A Cohort Study of the United States Eye Injury Registry. *J Glaucoma* **14**: 470–473.
- Greven C & Bashinsky A (2006): Circumstances and outcome of ocular paintball injuries. *Am J Ophthalmol* **141**: 393.
- Haavisto AK, Sahraravand A, Holopainen J & Leivo T (2017): Pediatric eye injuries in Finland –Helsinki Eye Trauma Study. *Acta Ophthalmol* **95**: 392–399.
- Jovanović M, Bobić-Radovanović A, Vuković D, Knezević M & Risović C (2012): Ocular injuries caused by airsoft guns –ten-year experience. *Acta Chir Jugosl* **59**: 73–76.
- Kaufman JH & Tolpin DW (1974): Glaucoma after traumatic angle recession: a ten-year prospective study. *Am J Ophthalmol* **78**: 648–654.
- Kennedy E, Stitzer J & Duma S (2008): Matched experimental and computational simulations of paintball eye impacts. *Biomed Sci Instrum* **44**: 243–248.
- Kratz A, Levy J, Cheles D, Ashkenazy Z, Tsumi E & Lifshitz T (2010): Airsoft gun-related ocular injuries: novel findings, ballistics investigation and histopathologic study. *Am J Ophthalmol* **149**: 37–44.
- Kuhn F, Morris R, Witherspoon CD & Mester V (2004): The Birmingham Eye Trauma Terminology system (BETT). *J Fr Ophtalmol* **27**: 206–210.
- Lee R & Fredrick D (2015): Pediatric eye injuries due to nonpowder guns in the United States, 2002-2012. *J AAPOS* **19**: 163–168.
- Lee K, Seery C & Khouri A (2017): Traumatic glaucoma due to paintball injuries: A case series. *J Curr Ophthalmol* **29**: 318–320.
- Nemet A, Asalee L, Lang Y, Briscoe D & Assia E (2016): Ocular paintball injuries. *IMAJ* **18**: 27–31.
- Ozer P, Yalvac I, Satana B, Eksioğlu U & Duman S (2007): Incidence and risk factors in secondary glaucomas after blunt and penetrating ocular trauma. *J Glaucoma* **16**: 685–690.
- Poon A, Ng J, Lam D, Fan D & Leung A (1998): Epidemiology of severe childhood eye injuries that required hospitalisation. *Hong Kong Med J* **4**: 371–374.
- Ramstead C, Ng M & Rudinsky C (2008): Ocular injuries associated with Airsoft guns: a case series. *Can J Ophthalmol* **43**: 584–587.
- Recchia FM, Saluja RK, Hammel K & Jeffers JB (2002): Outpatient management of traumatic microhyphema. *Ophthalmology* **109**: 1465–1470.
- Saunte J & Saunte M (2006): 33 cases of airsoft gun pellet ocular injuries in Copenhagen, Denmark, 1998–2002. *Acta Ophthalmol* **84**: 755–758.
- Saunte JP & Saunte ME (2008): Childhood ocular trauma in the Copenhagen area from 1998 to 2003: eye injuries caused by airsoft guns are twice as common as firework-related injuries. *Acta Ophthalmol* **84**: 345–347.
- Sihota R, Sood N & Agarwal H (1995): Traumatic glaucoma. *Acta Ophthalmol Scand* **73**: 252–254.
- Staffieri E, Ruddell J & Mackey D (2010): Rock, paper, scissors? Traumatic pediatric cataract in Victoria 1992–2006. *Clinical and Experimental Ophthalmology* **38**: 237–241.
- Thach AB, Ward TP, Hollifield RD et al. (1999): Ocular Injuries from Paintball Pellets. *Ophthalmology* **106**: 533–537.
- Tsai R, Denniston A, Murray P, Huang J & Aldad T (2011): *American Handbook of Ophthalmology*. Oxford: Oxford University Press.
- Walton W, Von Hagen S, Grigorian R & Zarbin M (2002): Management of Traumatic hyphema. *Surv Ophthalmol* **47**: 297–334.

Received on September 18th, 2018.

Accepted on September 19th, 2018.

Correspondence:

Anna-Kaisa Haavisto

P.O. Box 220

00290 Helsinki

Finland

Tel: +358 9 4711

Fax: +358 9 47176544

Email: anna-kaisa.haavisto@hus.fi

This study was supported by grants from The Evald and Hilda Nissi Foundation, The Mary and George C. Ehrnrooth Foundation, The Finnish Ophthalmological Foundation and The Finnish Eye and Tissue Bank Foundation.