

Department of Plastic Surgery  
Helsinki University Hospital  
University of Helsinki  
Finland

**SURGICAL RECONSTRUCTION,  
LOCALLY RECURRENT BREAST CANCER  
AND ANGIOSARCOMA**

**Andrew Lindford**

ACADEMIC DISSERTATION

To be publicly discussed, with the permission of the Faculty of Medicine of The University of Helsinki, in the main lecture hall of Töölö Hospital, Helsinki University Hospital, Topeliuksenkatu 5, Helsinki, on the 14<sup>th</sup> June 2013 at 12 noon.

Helsinki 2013

## **Supervised by**

Docent Tiina Jahkola, MD, PhD

and

Professor Erkki Tukiainen, MD, PhD

Department of Plastic Surgery

Helsinki University Hospital

University of Helsinki

Helsinki, Finland

## **Reviewed by**

Docent Paula Mustonen, MD, PhD

Department of Plastic Surgery

Kuopio University Hospital

University of Kuopio

Kuopio, Finland

Docent Riikka Huovinen, MD, PhD

Department of Oncology and Radiotherapy

Turku University Hospital

University of Turku

Turku, Finland

## **Opponent**

Mr Richard Rainsbury, MBBS, BSc, MS, FRCS

President of Association of Breast Surgery, Great Britain and Ireland

Director of Education at The Royal College of Surgeons of England

ISBN 952-10-8857-5 (paperback)

ISBN 978-952-10-8858-2 (PDF)

<http://ethesis.helsinki.fi/>

Helsinki University Print

Helsinki 2013

©**Cover picture:** *A new beginning*. Georges von Swetlick. 1978, egg-oil-tempera 72 x 91

# In Memoriam



Dr Joseph Footitt MBBS, MRCP, BSc, PhD (1975-2012)

Respiratory Physician, Academic Clinical Lecturer and Dear friend

*'Life is what happens to you whilst you're busy making other plans'*

John Lennon (1940-1980)

## CONTENTS

1. Original Publications	7
2. Abbreviations	8
3. Abstract	10
4. Introduction	12
5. Review of the Literature	13
5.1 Current management of primary breast cancer	13
5.2 Locally recurrent breast cancer	14
5.2.1 Risk factors for local recurrence	15
5.2.2 Diagnosis and pre-treatment evaluation	16
5.2.3 Surgical treatment of locally recurrent breast cancer	17
5.2.3.1 Surgical treatment of ipsilateral breast tumour recurrence (IBTR)	17
5.2.3.2 Surgical treatment of an isolated chest wall recurrence, chest wall stabilisation and reconstruction	17
5.2.4 Adjuvant therapy in locally recurrent breast cancer	19
5.2.4.1 Radiotherapy	19
5.2.4.2 Systemic therapy	20
5.2.5 Treatment of axillary recurrence	20
5.2.6 Treatment of supraclavicular recurrence	21
5.2.7 Prognosis of locally recurrent breast cancer	21
5.2.8 The Helsinki protocol for management of locally recurrent breast cancer	21
5.3 Breast reconstruction and locally recurrent breast cancer	22
5.3.1 Timing of breast reconstruction	22
5.3.2 Choice of reconstruction	22
5.3.3 Breast Reconstruction as a risk factor for local recurrence	23
5.3.4 Oncological aspects of skin-sparing mastectomy (SSM)	23
5.3.5 Diagnosis of local recurrence post-breast reconstruction	24
5.3.6 Treatment of local recurrence post-breast reconstruction	24

5.4 Secondary cancer after earlier primary breast cancer	25
5.4.1 Radiation induced sarcoma	25
5.4.2 Angiosarcoma	25
5.4.2.1 Radiation-associated breast angiosarcoma	26
5.4.2.1.1 Clinical features	27
5.4.2.1.2 Histopathology	27
5.4.2.1.3 Diagnosis	27
5.4.2.1.4 Management	28
6. Aims of study	29
7. Patients and Methods (Studies I-IV)	30
7.1 Patients	30
7.2 Surgery	32
7.3 Adjuvant therapy	34
7.4 Follow-up	34
7.5 Statistical methods	35
8. Results	36
8.1 Study I	36
8.2 Study II	38
8.3 Study III	41
8.4 Study IV	44
9. Discussion	46
9.1 Management of locally recurrent breast cancer	46
9.2 The impact of breast reconstruction on oncological outcome	49
9.3 Surgical management and oncological outcome of radiation-associated breast angiosarcoma	50
10. Conclusions	52
11. Acknowledgements	53
12. References	56

## **1. ORIGINAL PUBLICATIONS**

This thesis is based on the following original publications which are referred to in the text by their Roman numerals:

- I** Lindford AJ, Meretoja TJ, von Smitten KA, Jahkola TA. Skin-sparing mastectomy and immediate breast reconstruction in the management of locally recurrent breast cancer. *Ann Surg Oncol.* 2010 Jun;17(6):1669-74.
- II** Lindford AJ, Jahkola TA, Tukiainen E. Late results following flap reconstruction for chest wall recurrent breast cancer. *J Plast Reconstr Aesthet Surg.* 2013 Feb;66(2):165-73.
- III** Lindford AJ, Siponen ET, Jahkola TA, Leidenius MH. The effect of breast reconstruction on breast cancer recurrence and survival. Submitted.
- IV** Lindford A, Böhling T, Vaalavirta L, Tenhunen M, Jahkola T, Tukiainen E. Surgical management of radiation-associated cutaneous breast angiosarcoma. *J Plast Reconstr Aesthet Surg.* 2011 Aug;64(8):1036-42

These articles have been reprinted with the kind permission of their copyright holders.

## 2. ABBREVIATIONS

<b>ALND</b>	Axillary lymph node dissection
<b>AS</b>	Angiosarcoma
<b>BCSS</b>	Breast cancer specific survival
<b>BCT</b>	Breast conserving therapy
<b>CT</b>	Computed tomography
<b>DIEP</b>	Deep inferior epigastric perforator
<b>DM</b>	Distant metastasis
<b>ER</b>	Oestrogen receptor
<b>HER-2</b>	Human epidermal growth factor receptor-2
<b>IBR</b>	Immediate breast reconstruction
<b>IBTR</b>	Ipsilateral breast tumour recurrence
<b>IGAP</b>	Inferior gluteal artery perforator
<b>IMF</b>	Inframammary fold
<b>LD</b>	Latissimus dorsi
<b>LR</b>	Local recurrence
<b>LRR</b>	Locoregional recurrence
<b>MRI</b>	Magnetic resonance imaging
<b>NAC</b>	Nipple-areolar complex
<b>OS</b>	Overall survival
<b>PET</b>	Positron emission tomography
<b>PgR</b>	Progesterone receptor
<b>RT</b>	Radiotherapy
<b>SGAP</b>	Superior gluteal artery perforator
<b>SIEA</b>	Superficial inferior epigastric artery
<b>SLNB</b>	Sentinel lymph node biopsy
<b>SSM</b>	Skin-sparing mastectomy
<b>TAP</b>	Thoracodorsal artery perforator
<b>TFL</b>	Tensor fascia lata



**TMG** Transverse myocutaneous gracilis  
**TRAM** Transverse rectus abdominis myocutaneous  
**VRAM** Vertical rectus abdominis myocutaneous

### 3. ABSTRACT

#### Background

Local recurrence (LR) of breast cancer is defined as any recurrence of tumour in the ipsilateral thoracic wall and locoregional recurrence (LRR) as any recurrence in the ipsilateral thoracic wall or regional lymph nodes following surgery for primary breast cancer. Earlier consensus guidelines have stated that breast conservative therapy should aim to keep the LRR rate less than 15% at 10 years and following mastectomy the LRR rate should be less than 10% at 10 years (Rutgers EJ. 2001). Recent studies from our institution have reported a LR rate of 2.1% following breast conservative therapy with a median follow-up of 57 months (Siponen et al. 2011) and a LR rate of 2.9% following mastectomy with a median follow-up of 89 months (Siponen et al. 2013). The standard of care for LRR has not been established but surgery forms a key part of most accepted strategies. The oncological safety of immediate breast reconstruction for primary breast cancer has been addressed in numerous studies but only a few have considered the oncological safety of delayed autologous breast reconstruction. It is important to remember that women treated for a primary breast cancer are at increased risk of developing a second new primary non-breast cancer. Radiotherapy-induced breast angiosarcoma is now increasingly being recognized in the medical literature and is an aggressive tumour with a poor prognosis.

#### Patients and methods

The first study consisted of 60 consecutive patients treated by skin sparing mastectomy and immediate breast reconstruction between 1995 and 2008 for an ipsilateral breast tumour recurrence. Study II consisted of 40 consecutively operated patients who were treated with wide soft tissue resection and immediate flap reconstruction for an extensive chest wall recurrent breast cancer between 1984 and 2011. In both studies I and II hospital records were analysed for surgical complications and oncological outcome with respect to local control and overall survival. Study III was based on 522 consecutive patients who underwent mastectomy with or without breast reconstruction between January 2000 and December 2003. Data on cancer recurrence and survival were collected from hospital records and the files of the Finnish Cancer Registry. Study IV consisted of 10 patients treated surgically between 1999 and 2010 for a breast angiosarcoma following earlier radiotherapy for primary breast cancer. Surgical notes and pathology reports were reviewed for macroscopic and microscopic resection margins. Data on recurrence and overall survival was obtained from surgical and oncological records.

#### Results

##### *Study I*

60 patients underwent skin sparing mastectomy and immediate breast reconstruction for an ipsilateral breast tumour recurrence. The median follow-up time was 84 months. 11 (18%) patients developed disease relapse and consisted of 6 local re-recurrences (10%), 3 cases of regional lymph node metastasis and 2 cases of distant metastasis. 4 of the 11 (7% overall) patients with disease relapse eventually died. 5 year overall survival (OS) was 94% and 5 year disease-free survival (DFS) was 83%. Nine (15%) cases that suffered a complication required reoperation. These consisted of one microvascular re-anastomosis, one case requiring debridement for wound infection, 4 cases of haematoma drainage and 3 cases of debridement with/without skin grafting for partial flap or fat necrosis. There were no complete flap losses.

### *Study II*

40 patients underwent wide soft tissue resection and immediate flap reconstruction for an extensive chest wall recurrent breast cancer. The median length of follow-up was 31 months. In patients treated with a curative intent tumour-free resection margins (R0) were achieved in 24/31(77%) patients. The median DFS after extensive resection was 31 months and the median OS was 52 months. The 2 and 5 year OS rates were 71% and 32% respectively. In patients treated for symptom palliation clear microscopic margins (R0) were achieved in 3/9 patients. The median OS was 17 months. There were 2 LRRs and 1 relapse in the ipsilateral LD flap donor site. This was subsequently treated with radiotherapy. Multivariate cox regression analysis revealed that resection size was an independent prognostic factor with a threefold increased risk of mortality during follow-up for resections of more than 150 cm<sup>2</sup>. There were 2 deaths (5%) at 30 days post-operation due to medical complications and 2 re-operations (re-excision for non-radical resection and re-grafting of flap donor site). There were neither any complete nor partial flap losses.

### *Study III*

522 consecutive patients underwent mastectomy with (n=131) or without (n=391) breast reconstruction. The median follow-up time was 102 months and the 8-year LRR rate was 5.4% (n=21) in the mastectomy only group, 0.8% (n=1) in the delayed reconstruction group and 23.1% (n=3) in the immediate reconstruction group. Cox multivariate analysis revealed immediate reconstruction to be an independent risk factor for LRR. However Cox multivariate analysis revealed no reconstruction to be an independent risk factor for distant metastasis (DM), poor breast cancer specific survival (BCSS) and poor overall survival (OS).

### *Study IV*

10 patients underwent surgical resection for a breast angiosarcoma following earlier radiotherapy for primary breast cancer. Marked lateral macroscopic margins were at least 3 cm in 9/10 cases and clear histological margins were achieved in all cases. Defect coverage involved direct closure in 2 cases, reconstruction with a pedicled latissimus dorsi flap in 4 cases and skin grafting in 4 cases. Median follow-up was 81 months and 3 patients suffered a recurrence. Two were local skin recurrences and the other was a distant skin recurrence to the contralateral breast. 5 year OS was 70%. There were no complications.

## **Conclusions**

Skin-sparing mastectomy and immediate breast reconstruction is a possible treatment option for selected patients who develop an ipsilateral breast tumour recurrence. In selected patients autologous flap reconstruction enables the resection of extensive chest wall recurrent breast tumours with acceptable morbidity and reasonable local control and survival. Palliative surgery can also be invaluable to improve the quality of life in patients with extensive symptomatic recurrences. In comparison to mastectomy only breast reconstruction does not appear to worsen the prognosis following treatment for primary breast cancer. Increased awareness of radiation-associated angiosarcoma, with no delay in diagnosis and ultimately excision with wide macroscopic margins, is vital in improving survival of this poorly known tumour.

#### 4. INTRODUCTION

Breast cancer has been studied from the very earliest days of surgery. In Hippocrates we read “A woman in Abdera had a carcinoma of the breast and bloody fluid ran from the nipple. When the discharge stopped she died”. Celsus, in the first century AD, recorded early attempts at surgery for this disease: “Some have used caustics, others the cautery, others cut them out with a knife...Notwithstanding they have returned and occasioned death”. We have travelled far since Celsus, Jean Louis Petit (1674-1750), Benjamin Bell (1749-1806), Joseph Pancoast (1805-1882), William Stewart Halsted (1852-1922) and others, but much still remains for us and our successors to achieve in the understanding of breast cancer (Ellis. 1986).

In spite of huge advances in the past 20-30 years, the management of local recurrence of the disease is one such problem where a general consensus is still lacking. This is mostly due to its heterogeneous biological characteristics and lack of well-designed prospective clinical trials. Following breast conserving therapy the rate of local recurrence varies between 2 – 15% at 5 years (Kurtz et al. 1989; Veronesi et al. 1993; Fisher et al. 2002; Clarke et al. 2005). Approximately 5-10 % of patients undergoing mastectomy for breast cancer may suffer a chest wall recurrence within 10 years (Harris et al. 1996; Hsi et al. 1998; Buchanan et al. 2006; Elder et al. 2006; Siponen et al. 2013). The appropriate management of a chest wall recurrence following mastectomy is even less clear due to the nature of the surgical challenge as well as the generally-held view that this subset of patients have a particularly poor prognosis.

Reconstructive surgery is nowadays widely performed in the treatment of breast cancer. For some patients with a locally advanced primary tumour or a locally recurrent tumour reconstruction can enable an adequate resection to be carried out with the intention of cure. In other patients with more advanced recurrent disease and troublesome symptoms reconstruction can enhance the patient's quality of life by providing palliation for bulky, necrotic tumours and allow social reintegration.

Breast reconstruction is now a key part of comprehensive breast cancer treatment and presents several questions in relation to locally recurrent disease. Some studies have suggested that surgery may promote the growth of metastatic lesions (Tagliabue et al. 2003; Demicheli et al. 2008). Thus, could the extra surgery of a major reconstruction induce the reactivation of tumour cells? Is a late reconstruction for a long-time survivor of breast cancer safe for all patients and what kind of selection criteria should be considered? Could a reconstructed breast obscure the early diagnosis of a local relapse? What is the appropriate treatment of a recurrence following reconstruction?

A very rare but increasingly recognised condition is the development of angiosarcoma in the previously irradiated breast. This aggressive tumour is associated with high recurrence and poor survival and at present no standard management guidelines exist.

## 5. REVIEW OF THE LITERATURE

### 5.1 Current management of primary breast cancer

#### *Incidence and Survival*

Between 2006 and 2010 there were on average 4144 new cases of breast cancer diagnosed in Finland per year and the age-adjusted incidence rate was 86.5 per 100,000. The 5 year survival rate for patients followed-up in 2007-2009 was 89% and this figure compares very favourably with other countries. There were 887 deaths due to breast cancer in 2010 (Finnish Cancer Registry 2011).

#### *Primary surgery*

Breast conserving therapy (BCT) is defined as a partial mastectomy (breast conserving surgery) followed by whole breast irradiation. Numerous randomised trials with over 10 years follow-up have shown that BCT is equally efficacious as mastectomy for treating breast cancer. As BCT provides equivalent survival rates it has become the standard of care for women without contraindications to this approach (Fisher et al. 2002; Veronesi et al. 2002). In Helsinki the majority (50-60%) of patients with primary breast cancer are treated with breast-conserving surgery and radiotherapy. The standard resection is performed with the aim of achieving a lateral margin of at least 1 cm, including the underlying fascia as well as a strip of overlying skin (von Smitten. 2008). The addition of oncoplastic techniques has increased the possibilities of BCT (Meretoja et al. 2010). In Helsinki around 40% require mastectomy due to: tumour multifocality, large tumour in relation to breast size, insufficient histological resection margins following wide local excision (<5 mm), patient wishes, high-risk of recurrence (young patients, genetic predisposition or strong family history) and when radiotherapy is contraindicated or the patient non-compliant (Evidence-based medicine guidelines of diagnosis and treatment of breast cancer in Finland. 2007). The modern mastectomy, in contrast to the Halstedian approach, intends to leave as much of the normal anatomy as possible while removing all the breast tissue. The standard simple mastectomy excises the breast and skin envelope and leaves the pectoralis major muscle in place. A more recent modification of the simple mastectomy is the skin-sparing mastectomy (SSM). This aims to leave behind the breast skin envelope for reconstruction with either an implant or autologous tissue (Toth and Lappert. 1991; Rainsbury. 2006). From preservation of the skin, it has been a natural progression to consider preservation of the nipple. Nipple-sparing mastectomy (NSM) has become an acceptable option as a risk-reducing procedure but concerns still persist over its oncological safety and a general consensus has not yet been reached regarding its clinical application (Rusby et al. 2010).

#### *Axillary staging*

After primary tumour staging the next step in the staging of breast cancer is the assessment of the axillary nodal status. Lymph node metastases are the most significant prognostic indicator for patients who have breast cancer. Based on several trials and according to the American Society of Breast Surgeons, sentinel lymph node biopsy (SLNB) is the preferred method of axillary staging for patients with T1-3 invasive breast cancers that are clinically node negative, including multifocal/multicentric disease and prior breast surgery (The American Society of Breast Surgeons. 2005).

## *Adjuvant therapy*

In Finland adjuvant chemo- and radiotherapy are administered according to national and international evidence-based guidelines (Finnish National Breast Cancer Treatment Guidelines, 2007; National Comprehensive Cancer Network, NCCN guidelines®). The choice of systemic adjuvant treatment is based on tumour stage (tumour size, nodal status) and biological subtype of the tumour (estrogen and progesterone receptors, proliferation and HER2 gene expression) (Goldhirsch et al. 2011).

Following breast conserving surgery post-operative radiotherapy consists of a total of 45-50 Gy (gray) for 5 weeks to the whole breast area. Premenopausal women and those with close margins receive a further 10 Gy boost to the tumour bed. Radiotherapy is also administered to the axillary area if there are four or more involved lymph nodes (N2a). Recent studies have shown that achieving local control through adequate surgery and inclusion of radiotherapy for patients with an invasive cancer treated with a lumpectomy not only decreases locoregional recurrence but also positively impacts on survival (Clarke et al. 2005). Radiotherapy is also administered following mastectomy to patients with tumours larger than 5cm, tumours infiltrating skin or pectoralis fascia or inflammatory tumours.

It is widely accepted that all women under 35 years of age with invasive breast cancer or those with node-positive disease, ER-negative disease, HER-2 (human epidermal growth factor receptor-2) positivity or tumours larger than 1 cm should receive some form of chemotherapeutic regimen which usually consists of 6 cycles every 3 weeks.

Five-year endocrine therapy is recommended for all women with ER-positive breast cancer greater than 1 cm in size, regardless of age, lymph node status, HER-2 status or menopausal status. In Helsinki premenopausal women receive tamoxifen and postmenopausal women either tamoxifen or an aromatase inhibitor for 5 years.

HER-2 positive patients tend to have more aggressive disease and trastuzumab (Herceptin®), Genentech BioOncology), a recombinant, humanised IgG monoclonal antibody, is now recommended in combination with a chemotherapeutic regimen.

## **5.2 Locally recurrent breast cancer**

Following surgery for primary breast cancer the disease may recur locally, regionally and/or at distant sites. Patients with a local relapse after primary breast cancer surgery tend to have a poor prognosis (Abner et al. 1993; Courdi A et al. 2006; Fodor et al. 2008). Breast cancer recurrence tends to occur in the first 5 years after treatment with a peak incidence after 2 years (Kimura et al. 2007, Siponen et al. 2011).

After BCT a local recurrence is defined as reappearance of cancer in the ipsilateral preserved breast. Following mastectomy a local recurrence is defined as reappearance of cancer on the ipsilateral chest wall, usually close to the mastectomy scar. In contrast, a regional recurrence denotes tumour involving the regional lymph nodes, usually ipsilateral axillary or supraclavicular, less commonly infraclavicular and/or internal mammary nodes. Local recurrence following breast conserving therapy is an important problem as it necessitates further surgery and endangers the overall survival of the patient.

Thus locoregional breast cancer recurrence is a heterogenous disease entity that encompasses small local recurrences occurring in the remaining breast tissue following primary breast conserving surgery as well as extensive chest wall recurrences following mastectomy occurring in the skin, subcutaneous tissue or musculoskeletal chest wall with or without regional nodal metastases.

#### *Ipsilateral breast tumour recurrence (IBTR)*

IBTR is defined as any subsequent, pathologically confirmed breast cancer in the ipsilateral breast that was originally treated with a lumpectomy (Clemons et al. 2001). The IBTR rate at 5 years varies between 2 – 15% (Kurtz et al. 1989; Veronesi et al. 1993; Fisher et al. 2002; Clarke et al. 2005). Most IBTRs occur near to or at the site of prior resection (Veronesi et al. 1993; Fisher et al. 2002; Siponen et al. 2011). Although clinical trials have shown BCT to be equivalent to mastectomy in terms of overall survival, IBTR remains a significant problem due to several reasons. Further surgery in the form of a mastectomy is recommended which results in quality of life and body image issues. Local recurrences increase mortality and a 20% absolute reduction in 5 year local recurrence risk has been shown to lead to about a 5% absolute reduction in 15-year breast cancer mortality. In other words every fourth recurrence has been fatal (Clarke et al. 2005). Therefore treatment for IBTR should be effective firstly in terms of survival and secondly in terms of functional and aesthetic outcomes and morbidity. In addition any treatment for a local recurrence needs to be cost effective. The specific role of local (surgery and radiotherapy) and systemic (hormonal and chemotherapy) treatment in patients with IBTR remains unclear (Clemons et al. 2003; Chen et al. 2008).

#### *Chest wall recurrence*

Approximately 5-10 % of patients undergoing mastectomy for operable breast cancer may suffer a chest wall or regional recurrence within 10 years (Harris et al. 1996; Hsi et al. 1998; Buchanan et al. 2006; Elder et al. 2006; Siponen et al. 2013). Locally recurrent tumours occurring after an earlier mastectomy may involve only the superficial soft tissues and musculature of the chest wall but often invade the bony/cartilaginous chest wall. Chest wall recurrent breast cancer may be a sign of systemic disease and is considered to have a poor prognosis. The management of these patients is complex and different treatment combinations have been described but surgery is often not offered as primary therapy (Dahlstrøm et al. 1993; Willner et al. 1997; His et al. 1998; Rauschecker et al. 2008).

### **5.2.1 Risk factors for local recurrence**

The risk of locoregional recurrence depends on the initial stage of disease (Harris et al. 1996; Hsi et al. 1998; Buchanan et al. 2006; Elder et al. 2006) and most frequently cited risk factors include a positive resection margin, young age and presence of an extensive intraductal component (Huston and Simmons. 2005, Siponen et al. 2011).

Radiotherapy after breast conserving surgery reduces the risk of locoregional breast recurrence by approximately 70% and improves survival compared to surgery alone in good prognosis breast cancer cases (Clarke et al. 2005; Siponen et al. 2011).

Systemic adjuvant endocrine therapy significantly reduces the risk of local recurrences in oestrogen receptor (ER)-positive disease and similarly adjuvant chemotherapy reduces the local recurrence rate in women under 70 years of age (Early Breast Cancer Trialists' Collaborative Group. 2005).

Risk factors commonly associated with local recurrence after mastectomy include primary axillary lymph node metastasis, high grade tumour, large tumour size, young age at diagnosis and absence of steroid hormone receptors. A recent study from our institution showed hormone receptor negativity and HER2 gene amplification to be associated with local recurrence (Siponen et al. 2013).

### **5.2.2 Diagnosis and pre-treatment evaluation**

A local recurrence may manifest itself as a palpable or visible lesion/ lump near to the previous lumpectomy/mastectomy scar or may be detected on imaging during routine follow-up.

Factors to consider in risk assessment and treatment decision making are listed below: (Cardoso et al. 2011)

#### *Disease-related factors:*

- Disease-free interval
- Previous therapies and response
- Biological factors (hormonal receptors, HER2)
- Need for rapid disease/symptom control

#### *Patient-related factors:*

- Patient's preferences
- Biological age
- Menopausal status
- Co-morbidities and performance status
- Socio-economic and psychological factors
- Available therapies in the patient's country

#### *Imaging*

Magnetic resonance imaging (MRI) has been recommended when other investigations have equivocal findings for its potential to differentiate malignancy from scarring. However a recent systematic review by Quinn et al failed to support its use as a first-line investigation. They concluded that standard triple assessment (clinical assessment, mammography and core-needle biopsy) remained superior for diagnosis of recurrence (Quinn et al. 2012).

Positron emission tomography-computed tomography (PET-CT) may also be useful for identifying the site of relapse, particularly when traditional imaging methods (plain x-rays, ultrasound, CT or



MRI) are equivocal or conflicting. It may also help identify or confirm the situation of an isolated locoregional relapse (Radan et al. 2006; Cardoso et al. 2011).

Locoregional recurrence is frequently associated with distant spread, and such patients should undergo full staging procedures such as a bone scan and whole body CT before undergoing local treatments (Cardoso et al. 2011).

### **5.2.3 Surgical treatment of locally recurrent breast cancer**

At present no standard guidelines exist for the management of a locally recurrent tumour. This is partly due to the heterogenous biological characteristics of local recurrences, coupled with a lack of good clinical trials that would provide evidence in support of a more specific management rationale. Despite this it is generally agreed that an isolated locoregional recurrence should be treated like a new primary tumour with a curative intent (Cardoso et al. 2011).

#### **5.2.3.1 Surgical treatment of ipsilateral breast tumour recurrence (IBTR)**

In a survey by Clemons et al, 97% of clinicians from all breast cancer specialties questioned, believed that an IBTR is curable and 99% recommended surgery (Clemons et al. 2003). Hence it is generally considered that patients with IBTR are candidates for a curative treatment approach including surgery with or without radiotherapy. Most would advocate a salvage completion mastectomy although a few studies have also demonstrated the possibility of repeat lumpectomy (Alpert et al. 2005; Ishitobi et al. 2011). Analysis of the SEER database by Chen and Martinez has however shown superior overall survival rates following salvage mastectomy (Chen and Martinez. 2008). The 5-year survival rate after treatment for IBTR has been around 60-70% (Clemons et al. 2001) and 5-year disease-free survival only about 30-50% (Haffty et al. 1996; van Tienhoven et al. 1999). These figures have most likely been improving in recent years due to the introduction of new oncological treatment modalities.

There are only a few reported series in the literature regarding treatment by SSM and immediate breast reconstruction (IBR) in the setting of a local recurrence. Usually these have been reported as part of larger series consisting of predominantly primary breast tumours treated by SSM and IBR (Carlson et al. 2003; Disa et al. 2003; Meretoja et al. 2007).

Another unresolved issue concerns the management of the axilla in the setting of an IBTR especially when there is no clinical suspicion of tumour involvement of the axilla. If the primary BCT involved a node negative SLNB, should a completion axillary clearance be routine or is there a role for a further SLNB? (Koizumi et al. 2008; Derkx et al. 2010) The concern regarding repeat SLNB is that lymph drainage might be obscured by previous surgery and radiotherapy. One recent study revealed that lymphatic mapping is possible after previous BCT with axillary treatment but is associated with a relatively low identification rate (41% after SLNB and 36% after ALND) (Maaskant-Braat et al. 2012).

#### **5.2.3.2 Surgical treatment of an isolated chest wall recurrence, chest wall stabilisation and reconstruction**

The precise role and timing of surgery remains unclear in chest wall recurrent breast cancer. Extensive recurrences in the skin of the chest wall are frequently regarded as stage 4 disease with a poor prognosis and has traditionally led to a reluctance to treat these cases with a radical surgical

approach. Surgery may also be considered too high-risk. Furthermore clinical decisions may be influenced by the local availability of plastic surgical and/or thoracic surgical expertise in cases where chest wall resection is required. Extensive chest wall resections should aim to achieve local control, improve survival and/or provide good palliation with low morbidity and mortality. Several series have demonstrated the safety of full-thickness chest wall resection (Arnold and Pairolero. 1996; Cohen and Ramasastry. 1996; Faneyte et al. 1997; Toi et al. 1997; Chang et al. 2004; Losken et al. 2004; Pameijer et al. 2005) and favourable outcomes following chest wall resection for recurrent breast cancer have been reported with published 5 year survival rates ranging from of 18% to 71% (Faneyte et al. 1997; Toi et al. 1997; Downey et al. 2000; Chagpar et al. 2003; Pameijer et al. 2005; Friedel et al. 2008; van der Pol et al. 2009; Noble et al. 2010).

Surgery may also be performed as local therapy for disabling symptom palliation. Quality of life issues regarding alleviation of pain, haemorrhage, large malodorous ulcerations, recurrent infections and local control of the disease are important issues to consider. These potential benefits have been highlighted in a recent study (Veronesi et al. 2007).

Effective local control of isolated chest wall recurrences is achieved with a wide excision whenever feasible. Soft tissue coverage can be performed with the use of direct closure, skin grafts, local skin advancement, the thoracoabdominal flap, the breast flap, the omentum flap, pedicled myocutaneous flaps, perforator flaps and free flaps. The choice of reconstruction depends on the location and size of the defect, availability of local and pedicled flap options, previous surgery or radiotherapy and the general condition and prognosis of the patient. Occasionally, small superficial recurrences can be excised leaving a superficial chest wall defect involving only the soft tissues. These can usually be treated with skin grafts and local flaps. More commonly however a more extensive soft tissue resection is required leaving bone or cartilage exposed. These cases warrant coverage with a flap of vascularised tissue (Tukiainen et al. 2003; Friedel et al. 2008; Aukema et al. 2009).

In cases of full-thickness defects of the bony chest wall with exposure of the vital structures, depending on anatomical location and defect size, some form of chest wall stabilisation may be required. Large anterior and antero-lateral thoracic wall defects usually require stabilisation to prevent flail chest and paradoxical breathing and to protect the underlying lungs and/or heart. A synthetic mesh is most commonly employed. Using one or two rib grafts in combination with a mesh a large defect can be divided into smaller defects with adequate stability. Many centres use methylmethacrylate cement embedded between two layers of synthetic mesh which provides proper convexity and rigidity allowing slight movement (Arnold and Pairolero. 1996; Cohen and Ramasastry. 1996; Chang et al. 2004; Losken et al. 2004). Following chest wall stabilisation a vascularised flap reconstruction is then required to provide a water and air tight closure of the chest cavity, control infection, obliterate dead space, cover the synthetic material and close the soft-tissue defect (Losken et al. 2004). Several options for flap reconstruction exist. The breast flap is a local flap that can be used to cover defects located mostly in the midline and is particularly useful in elderly patients who have other serious comorbidities. Regional flaps available include the latissimus dorsi musculocutaneous flap, pectoralis major muscle flap, serratus anterior muscle flap, vertical rectus abdominus myocutaneous (VRAM) flap, transverse rectus abdominis myocutaneous (TRAM) flap, thoracoabdominal flap, external oblique muscle flap and the greater omentum flap (Arnold and Pairolero. 1996). The latissimus dorsi muscle or musculocutaneous flaps are usually large, easy to elevate with a wide arc of rotation and can cover anterior, lateral and posterior regions of the chest as well as upper sternal defects. The use of the latissimus dorsi musculocutaneous flap following mastectomy for breast cancer was first reported by Tansini in 1906

and after a long hiatus was 'rediscovered' and popularized by Neven Olivari (Olivari. 1976). The pectoralis major muscle flap can be based on the thoracoacromial or internal mammary vessels and is the workhorse flap for small to moderate defects over the upper or middle sternum and parasternal region. Pedicled VRAM or TRAM flaps can cover the epigastric and sternal areas as well as the anterolateral chest wall. The omentum flap is based on the right, left or both gastroepiploic vessels and can cover anterolateral chest wall defects. It is a soft and pliable flap and in wide defects requires a mesh to provide necessary stability. The omentum flap is usually covered with a skin graft. A shortcoming of this flap is the possible negative effect on respiration post-operatively and risk of later ventral hernia. The thoracodorsal artery perforator (TAP) flap is another pedicled option. It is a fasciocutaneous flap based on a musculocutaneous perforator or perforators from the thoracodorsal vessel axis and/or its vertical branch derivative. It provides a relatively thin and pliable skin paddle.

Microvascular flaps may sometimes be necessary if local or regional flaps are unavailable or insufficient in size (Losken et al. 2004). The overall condition of the patient should be considered however as microvascular reconstruction is associated with longer operative times and the potential for anastomotic problems. The tensor fascia lata (TFL) myocutaneous, TRAM, deep inferior epigastric perforator (DIEP) and fillet forearm flaps are possible free flap options. The TFL flap is easy and quick to harvest both in the lateral or supine position and can provide a large flap area with a constant and reliable pedicle. The donor site has no influence on respiratory function. The TRAM flap is a reliable and large flap providing bulk which can be exploited in large intrathoracic defects as a filler or providing breast contour. The abdominal donor site may have an adverse affect on respiration post-operatively. Following forequarter amputation the resulting wound can usually be closed using the standard posterior flap but in some cases of more extensive tumour invasion necessitating chest wall resection a free flap reconstruction is indicated. In these cases the amputated extremity can provide a free flap if the forearm and distal upper arm are not affected by disease. This fillet of forearm free flap usually retains the ulna bone and after osteotomy and plate fixation can give stability and some contour to the shoulder.

A recent study evaluated the functional outcome following chest wall reconstruction. They concluded that reconstruction provided adequate chest wall stability to maintain lung function but post-operative pain and sensation disorders were a frequent occurrence (Daigeler et al. 2009).

If there is clinically no axillary lymph node involvement a repeat axillary dissection is probably unnecessary in patients who have previously undergone complete axillary clearance.

#### **5.2.4 Adjuvant therapy in locally recurrent breast cancer**

Evidence-based guidelines for treatment are lacking but most clinicians agree that treatment should be multimodal with a comprehensive multidisciplinary approach. The role of adjuvant therapy after surgery for IBTR is unclear, but one must consider patients with any indicators for poor prognosis as described earlier. It may therefore be appropriate to administer adjuvant therapy to those patients with clearly defined risk factors for disease relapse (Sirohi et al. 2009).

##### **5.2.4.1 Radiotherapy**

In patients who initially underwent breast conserving therapy for their primary tumour radiotherapy cannot be included in the multimodal treatment of the local relapse. However in patients not previously irradiated, full dose radiotherapy to the chest wall and (when indicated)

regional lymph node areas should be given. Sometimes re-irradiation to limited areas in the chest wall may be administered (Cardoso et al. 2011). In addition, the presence of healthy vascular flap tissue may enable the use of further radiotherapy.

One study showed radiotherapy to significantly improve survival after surgery for chest wall recurrence (Chagpar et al. 2003). Radiotherapy has also been reported for its use as the primary treatment modality and in fact similar outcomes have been reported after surgery or radiotherapy for small isolated chest wall recurrences (Lê et al. 2002).

#### **5.2.4.2 Systemic therapy**

The effect of 'secondary or pseudo-adjuvant' systemic treatment is not well proven. Existing data from the literature is difficult to interpret due to non-standardisation of therapies for local recurrences (Sirohi et al. 2009).

The role of chemotherapy is subject to ongoing randomised trials (Wapnir et al. 2008) but these have been problematic due to slow accrual rates. Two earlier reports failed to show any clear benefit of chemotherapy, (Haylock et al. 2000; Rauschecker et al. 2001) the latter being a systemic review of randomised trials.

However a survey revealed that 85% of clinicians advocated commencing systemic therapy if not previously given and 97% suggested a change in systemic therapy if the patient is already receiving some form of medical treatment (Clemons et al. 2003). In deciding whether or not to administer 'pseudo-adjuvant' chemotherapy, factors such as tumour aggressiveness, previous adjuvant systemic therapy given, co-morbidities and preferences should all be considered (Cardoso et al. 2011).

'Pseudo-adjuvant' endocrine therapy despite being unproven, is commonly administered in cases of hormone receptor positive tumours because of its predicted benefit and low toxicity (Sirohi et al. 2009; Cardoso et al. 2011). One study has shown hormonal therapy to be beneficial after locoregional recurrence but not chemotherapy (Halverson et al. 1992).

Similarly 'pseudo-adjuvant' trastuzumab therapy is reasonable in cases where it was not prescribed at the time of initial diagnosis due to unavailability (Sirohi et al. 2009; Cardoso et al. 2011).

#### **5.2.5 Treatment of axillary recurrence**

Ipsilateral axillary nodal recurrence after previous axillary dissection is rare (0.7-1%) (Newman et al. 2000; Walsh et al. 2012; Siponen et al. 2012) but has been associated with a poor outcome (Walsh et al. 2012). Isolated ipsilateral axillary recurrence following an earlier negative SLNB is an even rarer event (0.2%) according to one recent report (Kapoor et al. 2012). In one series distant metastases developed in 50% of patients with an axillary recurrence and were more likely with uncontrolled axillary recurrences. Failure to receive multimodality therapy and failure to undergo surgery for the recurrence correlated with resistant axillary disease (Newman et al. 2000). Treatment should thus be surgical with an axillary dissection whenever possible. The role of post-operative radiotherapy is unclear but is used in some institutions for patients who have not undergone prior axillary radiotherapy (Shikama et al. 2011).

### **5.2.6 Treatment of supraclavicular recurrence**

Ipsilateral supraclavicular lymph node recurrence is also very rare in breast cancer patients with reported rates of 1.3- 1.9% (Fan et al. 2010; Siponen et al. 2012). Prognosis is less favourable than that of patients with axillary recurrence. Surgery is usually not indicated as first-line therapy but instead radiotherapy and/or systemic therapy are favoured (Shikama et al. 2011).

### **5.2.7 Prognosis of locally recurrent breast cancer**

Prognosis is influenced by a number of factors including: patient characteristics at primary treatment, extent of primary treatment and time interval from primary treatment to recurrence. Most IBTRs that occur at the site of prior resection are likely to be 'true recurrences' and are usually diagnosed earlier than recurrent cancers detected in other quadrants which can be considered as 'new primary' tumours. The latter have a better prognosis than true recurrences (Huang et al. 2002; Fredriksson et al. 2002; Nishimura et al. 2005).

Indicators of poor prognosis after treatment for loco-regional failure include patients who were primarily node positive, hormone receptor negative, high nuclear grade (HER positive), short time interval from primary treatment to IBTR, evidence of lymphovascular invasion at time of IBTR, multiple nodules or recurrence in more than one site, young age and insufficient treatment of recurrence (Benson and Querci della Rovere. 2008).

Many studies have shown that IBTR is associated with subsequent distant metastatic disease and worse survival. There is an ongoing debate as to whether IBTR is a cause of later distant metastases (Halstedian paradigm) or merely reflects tumour biology and is a manifestation of risk of distant relapse (Fisherian paradigm). In any case local recurrence within a conserved breast is the single most important predictor of overall survival (Benson and Querci della Rovere. 2008).

With regards to chest wall recurrence a few studies have assessed the impact of prognostic factors on survival. Age >35 years, negative lymph node status at initial presentation, time interval to chest wall recurrence >2 years and use of radiotherapy for the recurrence have been shown to be statistically significant positive prognostic factors for better overall survival (Faneyte et al. 1997; Chagpar et al. 2003; Pameijer et al. 2005; Friedel et al. 2008; van der Pol et al. 2009).

### **5.2.8 The Helsinki protocol for management of locally recurrent breast cancer**

- Salvage mastectomy for a local recurrence following breast conserving surgery. Immediate breast reconstruction possible in selected cases (Jahkola et al. 2003, Lindford et al. 2010, see also Figure 2). Repeat lumpectomy may be possible in rare selected cases (small easily discernible tumour in the scar). Post-operative radiotherapy if not earlier administered for the primary tumour (e.g. in the case of small DCIS).
- Wide resection of a local recurrence following mastectomy with flap coverage when necessary. Post-operative radiotherapy if not earlier administered for the primary tumour.
- Oncological medical therapy delivered according to same principles as for primary management and dependent on earlier administered therapy (Evidence-based medicine guidelines of diagnosis and treatment of breast cancer in Finland. 2007; NCCN guidelines®).

## 5.3 Breast reconstruction and locally recurrent breast cancer

### 5.3.1 Timing of breast reconstruction

Breast reconstruction is now a key part of comprehensive breast cancer treatment. Reconstruction may be performed in conjunction with the mastectomy (immediate reconstruction) or later (delayed reconstruction) after a suitable length of follow-up time (1-2 years). The timing of delayed reconstruction depends on oncological considerations such as mastectomy indication, tumour type and lymph node status and adjuvant therapy. In practice delayed reconstruction is considered at least half a year after the completion of primary oncological therapy and/or once irradiated tissue has had time to recover. Originally most reconstructions were delayed but owing to a gradual paradigm shift in breast cancer treatment the concept of immediate reconstruction has become more accepted (Losken and Jurkiewicz. 2002; Rainsbury. 2006). SSM followed by immediate breast reconstruction (IBR) was first described in 1991 and involves the removal of all the breast tissue, the nipple–areolar complex (NAC) and any biopsy scar (Toth and Lappert. 1991). The dissection plane of SSM progresses between the breast parenchyma and the subcutaneous fat (Figure 1). SSM enables a superior aesthetic result in comparison to either simple mastectomy and IBR or delayed reconstruction. An earlier retrospective study (Al-Ghazal et al. 2000) and a recent prospective study (Elder et al. 2005) have both demonstrated the positive effects of immediate breast reconstruction on the psychological well-being of patients with breast cancer. Other advantages of SSM and IBR include the retention of breast skin sensation and cost effectiveness as only one operation is required. The nipple-sparing mastectomy (NSM) has recently gained in popularity with the aim of further improving the aesthetic result. The incidence of cancer in the retained nipple after risk-reducing mastectomy has been reported to be less than 1 per cent. A recent review concluded that NSM appears to be an acceptable technique for women undergoing risk-reducing mastectomy and in the therapeutic setting may be offered to patients with smaller tumours far from the nipple and favourable pathological features. Women should however be counselled about possible nipple necrosis and the potential for local recurrence (Rusby et al. 2010).

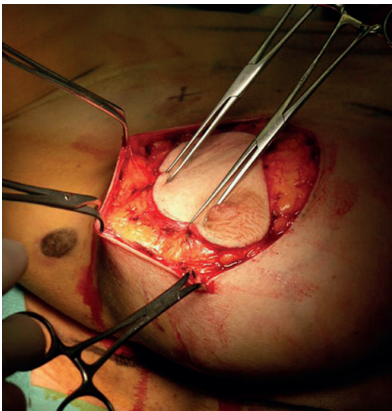


Photo: Juhani Lassander

Figure 1. Skin-sparing mastectomy

### 5.3.2 Choice of reconstruction

The type of reconstruction is individualised and must consider medical comorbidities, body habitus, the oncological treatment plan and patient preference. The reconstruction may be based on implants, autologous tissue or a combination of the two. The donor sites favoured for

autologous reconstruction include the abdomen [the free transverse rectus abdominis myocutaneous (TRAM), deep inferior epigastric artery perforator (DIEP) and superficial inferior epigastric artery (SIEA) flaps], the latissimus dorsi (pedicled musculocutaneous latissimus dorsi flap with or without implant) pedicled thoracodorsal artery perforator (TAP) flap or pedicled intercostal artery perforator (ICAP) flap, the gluteal region [free superior gluteal artery perforator (SGAP) and inferior gluteal artery perforator (IGAP) flaps] and the thigh region [free transverse myocutaneous gracilis (TMG) flap]. In Helsinki the abdomen and back are the favoured donor sites.

### **5.3.3 Breast Reconstruction as a risk factor for local recurrence**

Immediate breast reconstruction (IBR) for the treatment of early stage breast cancer has increased in popularity over the past two decades. The oncological safety of IBR has been addressed in several studies (Meretoja et al. 2007; Vaughan et al. 2007; McCarthy et al. 2008; Yi et al. 2011; Patterson et al. 2012) but only a few have considered the oncological safety of delayed autologous breast reconstruction (Nieminen et al. 1999). Moreover, in most studies a control group with mastectomy only has been lacking.

A few studies directly comparing patients treated with mastectomy only and patients receiving a reconstruction have been recently reported. Isern et al reported a higher incidence of recurrent disease in women treated with delayed autologous tissue (pedicled and microvascular flaps) reconstructions when compared to a matched group of women treated with mastectomy alone (Isern et al. 2011). In contrast to the aforementioned Swedish study (Isern et al. 2011) other studies have reported no significant difference in the locoregional recurrence (LRR) rate (McCarthy et al. 2008; Reddy et al. 2011; Eriksen et al. 2011; Agarwal et al. 2012). However, two of the previous studies have comprised of only implant reconstructions (McCarthy et al. 2008; Eriksen et al. 2011) while a recent comparative study by Nedumpara et al included both LD myocutaneous flaps (60%) and implants only (40%)(Nedumpara et al. 2011). Furthermore a recent meta-analysis demonstrated no evidence for increased LR with IBR compared with mastectomy alone (Gieni et al. 2012).

There have been a few studies that discuss the somewhat contentious possibility of surgery-driven enhancement of metastasis (Tagliabue et al. 2003; Demicheli et al. 2008). In fact the capacity of tumour surgical resection to enhance cancer growth at metastatic sites was a theory postulated already a century ago. Could the additional surgery of a major autologous reconstruction pose a risk in some patients? Low LR and LLR rates have however been earlier reported following free TRAM flap reconstructions (Nieminen et al. 1999; Patterson et al. 2012). The latter study reported a LRR rate of 4.6% with a median follow-up of 69.2 months.

### **5.3.4 Oncological aspects of skin-sparing mastectomy (SSM)**

There had been previously debate over how often the skin itself is involved in patients with breast cancer. Two classic studies by Fisher and Wertheim found rates of non-NAC skin involvement of 4.4% and 11.3%, respectively (Fisher et al. 1975; Wertheim and Ozzello.1980). Thus there is a general consensus that patients with clinically involved skin, including inflammatory breast cancer cases are not candidates for SSM (Rainsbury. 2006). Care should also be taken when offering this procedure to women with large tumours.

The SSM skin-flap should be dissected as thin as possible in order to remove all glandular breast tissue and avoid residual disease. However, the blood supply to the skin flaps should not be

compromised and the perforating arteries should be preserved whenever possible (Jahkola et al. 2004). A study by Torresan RZ et al revealed residual breast tissue in the skin after SSM in 9.5% of cases and was associated with skin flaps greater than 5 mm thick (Torresan et al. 2005). In a recent study residual breast tissue was reported to occur in 6% of SSM cases but with no adverse effect on oncological outcome. However their follow-up time was only 33.5 months (Dreadin et al. 2012).

Another issue that has been debated is the oncological significance of the inframammary fold (IMF). The IMF is a zone of adherence of the superficial fascial system to the underlying chest wall and anatomically denotes where the skin of the inferior pole of the breast parenchyma meets the chest wall forming a groove known as the inframammary crease. Preservation of the IMF during mastectomy facilitates breast reconstruction but there have been concerns regarding the amount of breast tissue that might potentially be left unresected. One study showed that 28% of IMF specimens contained breast tissue and intramammary lymph nodes (Gui et al. 2004) and so concluded that caution should be exercised in minimising the possibility of residual breast tissue.

### **5.3.5 Diagnosis of local recurrence post-breast reconstruction**

As for local recurrences in the non-reconstructed breast early detection is essential for successful management with salvage surgery with good margins and subsequent adjuvant therapies (Langstein et al. 2003; Howard et al. 2006). There is no consensus as to how follow-up after IBR should be conducted. Regular clinical examinations are the basis for all follow-up protocols but much variation exists in their frequency as well as the use of mammography and ultrasound. Helvie et al found that the appearance of recurrent tumour in TRAM flaps on mammography is similar to that of primary breast cancer (Helvie et al. 1998). Some have advocated the use of computed tomography and MRI for follow-up imaging of reconstructed breasts (Lindfors et al. 1985; LePage et al. 1999; Peng et al. 2011). MRI may be superior for visualization of the normal TRAM flap appearance and for differentiating benign from malignant changes (Devon et al. 2004). In one study all LRRs after TRAM flap reconstruction were identified clinically without the use of imaging (Patterson et al. 2012). In fact most recurrences tend to occur superficially in the skin or subcutaneous tissues and often present as a palpable mass or thickening (Newman et al. 1998; Shaikh et al. 2001; Patterson et al. 2012; Lee et al. 2012). Shaikh et al concluded that clinical examination and biopsy is the most reliable method of detection and that other imaging techniques should not be routine (Shaikh et al. 2001). However there have been concerns that a deeply lying chest wall recurrence might be concealed by a TRAM flap leading to a delay in diagnosis. Even though one study disproved this notion (Langstein et al. 2003) there may well be a reasonable argument for imaging as a screening tool at regular intervals. But this is unlikely to be cost-effective as the majority of post reconstruction recurrences are superficial. In Helsinki routine follow-up after IBR consists of mammography and ultrasound as well as clinical examination by a surgeon and/or oncologist at 1,3 and 5 years from surgery (Meretoja et al. 2007).

### **5.3.6 Treatment of local recurrence post-breast reconstruction**

The treatment of locally recurrent breast cancer following reconstruction is not clearly defined but should be multimodal. As for locally recurrent disease in the non-reconstructed breast restaging with CT or PET-CT seems appropriate (Radan et al. 2006; Cardoso et al. 2011). Most institutions carry out a wide surgical resection with removal of as much reconstructed tissue as necessary to achieve negative margins (Chagpar et al. 2004; Howard et al. 2006). Complete flap removal may be necessary. A chest wall recurrence may also be amenable to surgical resection with use of the remaining TRAM flap for subsequent defect closure (Langstein et al. 2003; Howard et al. 2006). However these cases tend to be more complex and chest wall reconstruction and coverage with a



new autologous flap may be indicated. One series reported similar oncological outcomes when comparing chest wall recurrence after reconstruction to recurrence after mastectomy with no breast reconstruction (Chagpar et al. 2004). Adjuvant therapy should be instituted according to previously outlined principles for recurrent disease (Langstein et al. 2003; Howard et al. 2006). Radiotherapy administered to the remaining flap may however incur compromised flap aesthetics from fibrosis and scar contracture as well as fat necrosis and volume loss (Howard et al. 2006).

## **5.4 Secondary cancer after earlier primary breast cancer**

Women treated for a primary breast cancer have a 25% increased risk of developing a second new primary non-breast cancer. These include many different cancer types (stomach, colorectal, lung, soft tissue sarcoma, melanoma, non-melanoma skin, endometrium, ovary, kidney, thyroid gland and leukaemia) that have been reported and may result from shared risk factors such as genetics, environmental factors and breast cancer treatments. In fact a 6-fold increased risk of thorax and upper limb sarcomas has been reported, which suggests that these cancers may be related to radiotherapy (RT) (Mellemkjaer et al. 2006).

### **5.4.1 Radiation induced sarcoma**

Ionizing radiation is known to be a potent carcinogen and malignancy associated with radiation may result from natural sources, a radiation accident or may be a side effect from cancer therapy. The classical definition of radiation induced sarcoma is based on criteria proposed in 1948 by Cahan et al:

1. History of RT.
2. Asymptomatic latency period of several years.
3. Occurrence of sarcoma within a previously irradiated field.
4. Histological confirmation of sarcoma that is histologically unique from the primary cancer.

The most common histological types of radiation induced sarcoma previously reported by the Finnish Cancer Registry were osteosarcoma and malignant fibrous histiocytoma and these were mostly high grade tumours (Wiklund et al. 1991). The actual pathophysiological mechanism of radiation induced sarcoma has not yet been elucidated.

### **5.4.2 Angiosarcoma**

Angiosarcomas (AS) are rare aggressive malignant tumours that usually arise from the endothelial cell lining of vascular or lymphatic channels and have a poor prognosis. They account for only 1% of all soft tissue sarcomas and can arise in any soft-tissue structure or viscera. They most commonly occur in the skin of the scalp and/or face in elderly patients and do not appear to have any clear predisposing factors (Young et al. 2010). Approximately 8% of angiosarcomas arise in the breast. Primary breast AS which is not associated with radiotherapy typically presents as an ill-defined mass in the breast parenchyma in younger women and consists of 1 in 1700-2000 primary breast cancers (Enzinger FM, Weiss SW. 1995).

### 5.4.2.1 Radiation-associated breast angiosarcoma

Secondary breast AS usually occurs in older women with a history of breast cancer and RT, and is mostly cutaneous presenting with multiple closely-related lesions (Monroe et al. 2003; Lucas. 2009). Six cases of secondary angiosarcomas were first reported as arising in the long-standing oedematous upper extremity following mastectomy and axillary clearance and designated the Stewart-Treves syndrome (Stewart and Treves. 1948). Stewart and Treves recognized that an oedematous arm after radical mastectomy for breast cancer may suggest recurrent breast cancer, but that long-standing chronic oedema without recurrent cancer may occasionally produce "a heretofore unrecognized and unreported sequel ... long after the malignant breast neoplasm has apparently been arrested ... a new specific tumor." Stewart and Treves suggested that these angiosarcomas were probably not observed previously because they were mistaken for recurrent, inoperable, cutaneous manifestations of breast cancer. Lymphoedema caused by Milroy's disease and chronic infections, like filariasis, have similarly been associated with the development of angiosarcomas. But over the last 10-20 years cutaneous AS in the irradiated breast after breast conserving therapy (BCT) has been increasingly reported (Fineberg and Rosen. 1994; Karlsson et al. 1998; Strobbe et al. 1998; Cozen et al. 1999; Marchal et al. 1999; Huang and Mackillop. 2001; Yap et al. 2002; de Bree et al. 2002; Feigenberg et al. 2002; Monroe et al. 2003; Billings et al. 2004; Cha et al. 2004; Brenn and Fletcher. 2005; Kirova et al. 2005; West et al. 2005; Vorburger et al. 2005; Hodgson et al. 2007; Lucas. 2009; Mery et al. 2009; Biswas et al. 2009; Hui et al. 2012; Morgan et al. 2012; Seinen et al. 2012; Jallali et al. 2012). The association between RT and AS has been established by a number of studies (Cozen et al. 1999; Huang and Mackillop. 2001; Yap et al. 2002; Mery et al. 2009).

RT induced AS occurring in the breast skin/parenchyma or chest wall following BCT or mastectomy is probably the most common form of RT induced AS. Post RT angiosarcomas have also been described as intraabdominal or abdominal wall masses following RT for cervical, ovarian or uterine carcinoma.

Huang and Mackillop demonstrated that the relative risk of AS doubled after breast cancer surgery even if no RT had been administered (Huang and Mackillop. 2001). This suggests a possible multifactorial aetiology and the increased risk might result from coexisting lymphoedema. Additionally some reports suggest that mutations in the DNA repair genes, BRCA1 and BRCA2, predispose to angiosarcomas after treatment for breast cancer (West et al. 2012). One recent cohort study even failed to show such a strong association between RT and breast AS (Virtanen et al. 2007).

Although AS following BCT is rare with a reported prevalence of 0.05% (Marchal et al. 1999), it is associated with high rates of recurrence and poor overall survival of about 35% at 5 years (Marchal et al. 1999; Monroe et al. 2003; Billings et al. 2004; Cha et al. 2004; Hodgson et al. 2007)(Figure 2).

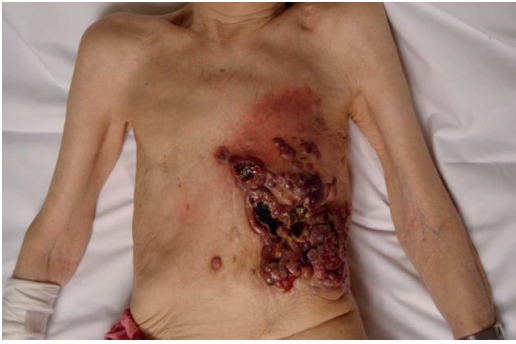

Figure 2. AS is an aggressive tumour with high rates of local recurrence.

#### **5.4.2.1.1 Clinical features**

Radiation-associated AS clinically presents as an erythematous patch, plaque or nodule, often with local oedema. It may initially resemble a bruise. Other early findings include ulcerations, eczema and nonpigmented macules. Pain is uncommon. Differential diagnoses include trauma, infectious pathology, haemangioma-like lesion, or inflammatory carcinoma. Involvement of the breast is frequently extensive and the lesions are commonly multiple (Monroe et al. 2003; Brenn and Fletcher. 2005; West et al. 2005; Lucas. 2009).

#### **5.4.2.1.2 Histopathology**

Histologically AS may be high grade and exhibit varying degrees of nuclear atypia, darkly staining nuclei, large nucleoli and frequent mitoses. Intraluminal 'blood lakes' are a common feature. However histological features can vary between cases and distinguishing between a malignant vascular tumour and a benign lesion can be difficult. Immunohistochemical tests can help diagnostically with factor VIII antigen, CD34 and CD31 markers mostly used (Monroe et al. 2003; Brenn and Fletcher. 2005; Lucas. 2009).

#### **5.4.2.1.3 Diagnosis**

Early diagnosis of AS is of paramount importance due to its aggressive progression. However as it can be mistaken for a simple benign lesion presentation and diagnosis may be delayed. Thorough physical examination and prompt multiple punch biopsies are essential to confirm histology. Other investigations such as mammography and MRI play only a limited role in diagnosing AS, (Monroe et al. 2003; West et al. 2005; Hodgson et al. 2007) although MRI is probably superior.

#### 5.4.2.1.4 Management

##### *Surgical treatment*

Most reports of AS treatment are limited to retrospective case series and no evidence-based guidelines exist. However treatment of choice is radical surgery with complete (R0) resection in view of its high probability of recurrence. Surgery usually consists of a simple/radical mastectomy or wide local excision (Strobbe et al. 1998; Marchal et al. 1999; Feigenberg et al. 2002; Monroe et al. 2003; Billings et al. 2004; Cha et al. 2004; Vorburger et al. 2005; West et al. 2005; Hodgson et al. 2007; Biswas et al. 2009; Young et al. 2010; Hui et al. 2012; Morgan et al. 2012; Seinen et al. 2012; Jallali et al. 2012). Involved margins (R1 and R2 resection) are common because of the invasive and frequently multifocal nature. One study advocated resection of all at-risk irradiated breast skin to reduce local recurrence (Morgan et al. 2012). Following extensive resection options for defect reconstruction include: split-thickness skin grafting, pedicled latissimus dorsi musculocutaneous flap, pedicled vertical rectus abdominis (VRAM) flap, pedicled omental flap or free tissue transfer (Hui et al. 2012; Seinen et al. 2012; Jallali et al. 2012). Skin grafting in an earlier irradiated field may not be the most appropriate option and flap coverage may be preferable. At present there are no standard guidelines concerning surgical margins and choice of reconstruction. Single institution series have reported median overall survival up to 4 years with distant metastasis rates up to 41% (Billings et al. 2004, Vorburger et al. 2005; Morgan et al. 2012; Seinen et al. 2012).

Regional lymph node involvement is uncommon either at presentation or at recurrence; hence routine axillary lymph node dissection is not indicated (Monroe et al. 2003).

##### *Adjuvant therapy*

The use of other adjuvant treatment modalities in the management of AS has yet to be clearly defined. Adjuvant radiotherapy is generally avoided in radiation-associated angiosarcomas as the surrounding tissue has usually already received the maximum dose of radiotherapy (Young et al. 2010).

In one series 67% patients received adjuvant chemotherapy with variable therapeutic regimens (Vorburger et al. 2005). In a phase II trial, promising results with the taxane paclitaxel have been reported (Penel et al. 2008).

C-kit proto-oncogene product (KIT, CD117) is a tyrosine kinase growth factor receptor for stem cell factor. This receptor is important for the development and maintenance of hematopoietic stem cells, mast cells, germ cells, melanocytes, and interstitial cells of Cajal and is constitutively expressed in them. The expression of KIT receptor tyrosine kinase in post-radiation angiosarcoma has been reported and may provide a potential treatment target (Komdeur et al. 2003).

In view of the fact that angiosarcomas are endothelial-cell tumours, there is currently much interest in the role of angiogenesis and angiogenic factors associated with their pathogenesis and how they might be used as therapeutic targets (Young et al. 2010). The potential of antiangiogenic molecules such as the VEGF-A monoclonal antibody, bevacizumab, has been recently reported (Agulnik et al. 2012).

## **6. AIMS OF THE STUDY**

The aim of the present study was to investigate and report the surgical and oncological results of reconstructive surgery in relation to locally recurrent breast malignancy.

The specific aims were:

- I** To investigate whether skin-sparing mastectomy (SSM) and immediate breast reconstruction (IBR) is a suitable treatment option in selected cases of locally recurrent breast cancer after previous breast conserving therapy (BCT).
- II** To assess local control, morbidity, choice of flap reconstruction, patient selection and overall long-term survival following surgical salvage of patients with chest wall recurrent breast cancer.
- III** To evaluate the oncological impact of breast reconstruction in breast cancer patients treated with mastectomy.
- IV** To investigate the surgical management of radiation-associated cutaneous breast angiosarcoma with an emphasis on outcome, surgical margins and choice of reconstruction.

## 7. PATIENTS AND METHODS

### 7.1 Patients (Studies I-IV)

The study was carried out at the Helsinki University Hospital. All of the patients were operated on in the Department of Plastic Surgery and in the Breast Surgery Unit. Study I consisted of 60 consecutively operated patients who were treated by SSM and IBR between 1995 and 2008 for an ipsilateral breast tumour recurrence (IBTR). Study II consisted of 40 consecutively operated patients who were treated with wide soft tissue resection and immediate flap reconstruction for an extensive chest wall recurrent breast cancer between 1984 and 2011. Study III was based on 522 consecutive patients who underwent mastectomy with or without breast reconstruction between January 2000 and December 2003. Study IV consisted of 10 patients diagnosed between 1999 and 2010 with a cutaneous breast angiosarcoma after earlier treatment with radiotherapy for primary breast cancer. The study protocol was approved by the Ethics Committee and Head of Surgery of the Helsinki University Central Hospital and permission was granted for examination of patient records.

#### *Study I*

The patient population consisted of 60 consecutive patients managed by SSM and IBR between 1995 and 2008 for an ipsilateral breast tumour recurrence (IBTR). All these patients had their primary breast cancer earlier treated by breast conserving surgery and radiotherapy. Patients selected for treatment were those who had been diagnosed with a locally recurrent tumour considered to have a favourable prognosis. Our written selection criteria (Jahkola et al. 2003) are shown in Figure 2.

Hospital records were analysed for demographic, oncological and reconstructive data. Pathology reports were also reviewed to obtain tumour characteristics and surgical records were analysed for follow-up data on patterns and timing of re-recurrence and patient outcome. In addition the selection criteria were analysed for each case.

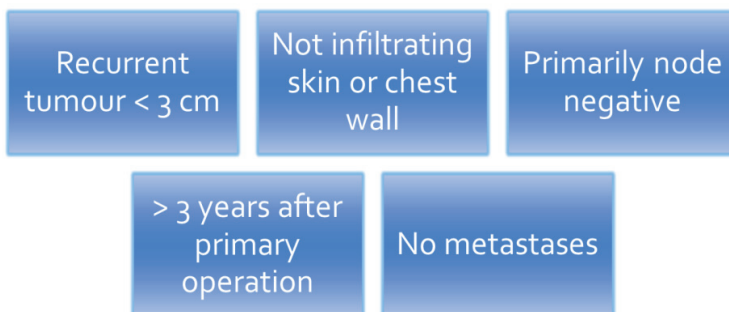


Figure 2. Selection criteria for SSM and IBR (Jahkola et al. 2003).

### *Study II*

40 patients were identified from our surgical database that had been treated with wide soft tissue resection and immediate flap reconstruction with or without a complete full-thickness chest wall resection for an extensive chest wall recurrent breast cancer between 1984 and 2011. Their medical records were retrospectively reviewed for primary breast cancer and recurrent disease data including analysis of surgical and histological records. Oncological outcome was assessed with respect to overall survival (OS) and disease-free survival (DFS).

### *Study III*

The study was based on 522 consecutive patients, younger than 70 years, who underwent mastectomy between January 2000 and December 2003 for invasive breast cancer. Overall, 391 (75%) received mastectomy alone and 131 (25%) underwent a breast reconstruction of which 13 (10%) were immediate and 118 (90%) were delayed reconstructions. Data on cancer recurrence and survival were collected from hospital records and registries, and the files of the Finnish Cancer Registry. Recurrences were classified as local, regional and systemic according to the first site of recurrence. Local recurrence (LR) is defined as any recurrence of tumour in the ipsilateral thoracic wall and LRR as any recurrence in the ipsilateral thoracic wall or regional lymph nodes or in both.

### *Study IV*

10 patients were diagnosed between 1999 and 2010 with a cutaneous breast angiosarcoma after earlier treatment with radiotherapy (RT) for breast cancer. All primary breast tumours were ductal carcinomas staged I-III. RT was delivered in a standard fashion consisting of a tangential external beam field technique with the patient in a supine position. 25 fractions of 2 Grays (Gy) were administered over 5 weeks resulting in a total dose of 50 Gy. All patients received the same regimen and total dose. 1 patient received a further dose of 15/3 Gy to the tumour bed 2 weeks later. 1 patient later underwent skin-sparing mastectomy and immediate reconstruction with a free transverse rectus abdominis myocutaneous (TRAM) flap for an ipsilateral breast tumour recurrence prior to the development of AS.

Clinical features of AS were evaluated using photographs taken at presentation. Surgical operation notes were analysed and pathology reports reviewed to obtain AS tumour characteristics and macroscopic and microscopic resection margins. Follow-up data on recurrence and overall survival was obtained from surgical and oncological records.

All cases were reviewed pre-operatively by the multidisciplinary Helsinki Sarcoma group. This group discusses routinely a management plan for all soft tissue sarcomas and decisions are made regarding:

1. Neoadjuvant therapy
2. Surgery/ macroscopic margins
3. Adjuvant medical therapy
4. Radiotherapy

## 7.2 Surgery (Studies I-III)

### *Study I*

SSM was performed in an established manner by experienced breast surgeons. The nipple-areola complex was removed along with the entire remaining breast parenchyma and previous resection or biopsy scars. In the case of a more superficially recurrent tumour an extended area of skin was also included in the excision. SSM was combined with axillary lymph node dissection in those cases when the axilla had not earlier been treated. In a few cases SLNB was carried out. The SSM was followed by IBR carried out by a team of reconstructive surgeons.

### *Study II*

The resection was considered potentially curative if preoperative staging investigations showed that the resection could be radical. Resection with a palliative intent was carried out in patients who presented with distant metastases and/or an extensive tumour with overwhelming local symptoms in which a radical excision was not considered possible.

The resection and soft tissue / chest wall reconstruction were performed by a team of plastic surgeons. Excision margins were pre-operatively planned in conjunction with a senior radiologist based on CT scan findings. For recurrences limited to the soft tissues of the chest wall the resection was performed down to the bony chest wall including the pectoralis major and minor muscles and the fascia of the serratus anterior and rectus abdominus muscles. The minimum lateral macroscopic margin was 2 to 3 cm. An axillary clearance was carried out if not previously performed or if there was evidence of axillary recurrence. In the full-thickness chest wall resection cases a complete en bloc resection of skin, muscle and full-thickness bony chest wall was performed. The deep margin usually included the parietal pleura. An extended forequarter amputation was indicated when the tumour recurrence was located in the shoulder and axillary region with involvement of the chest wall, axillary vessels and brachial plexus. In these cases resection of ribs as well as removal of the upper limb, scapula and clavicle was performed. Definitive chest wall stabilisation was then carried out followed by immediate soft tissue reconstruction with a pedicled or microvascular flap. If the bony chest wall defect measured up to 5 x 5 cm only a mesh was used, up to 10 x 10 cm a free rib graft and mesh were used and if the defect measured up to 10 x 25 cm two free rib grafts and a mesh were applied. The early cases were treated with fascia lata for chest wall stabilisation.

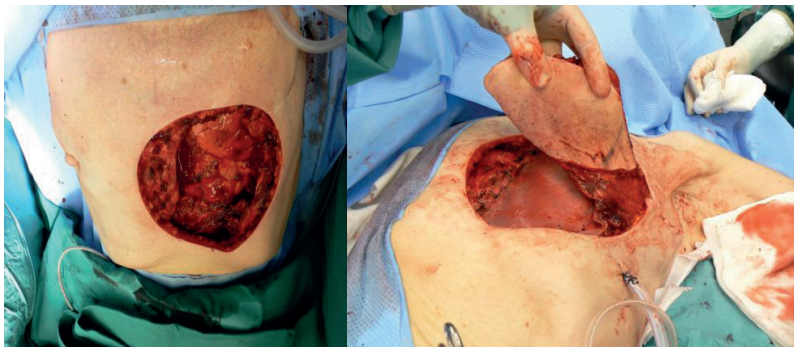


Figure 3. Wide en bloc resection of chest wall recurrence with 3 cm lateral margins. FTCWR of lower sternum and left lower 3 ribs and parietal pleura. Chest wall stabilisation with prolene mesh and defect covered with pedicled musculocutaneous latissimus dorsi flap.



### Study III

The median age at primary diagnosis was 53 years (range 24-69 years). The median follow-up time was 8.5 years (range, 9-130 months) calculated from the date of primary surgery. A skin-sparing or non-skin-sparing mastectomy was performed by experienced breast surgeons. In conjunction with the mastectomy all patients underwent either sentinel lymph node biopsy (SLNB) (n=68), axillary lymph node dissection (ALND) (n=348) or both (n=106). All SLNB patients underwent back-up ALND regardless of the sentinel node status from January 2000 to May 2000. From June 2000, ALND was omitted in sentinel node negative patients with radiologically unifocal breast cancer up to a maximum tumour diameter of 3 cm when evaluated with breast ultrasound. The mastectomy specimens as well as sentinel node and ALND specimens were assessed as described in detail in a previous study (Siponen et al. 2011).

An immediate or delayed breast reconstruction was carried out by a team of reconstructive plastic surgeons. The main indication for immediate reconstruction was extensive DCIS as a preoperative diagnosis. Delayed reconstruction was offered to patients with node negative invasive breast cancer within 1 year after primary surgery and for patients with node positive disease 2-4 years from primary surgery. The median time from mastectomy to delayed breast reconstruction was 34 months. Median follow-up after delayed breast reconstruction was 64 months (range 5-111 months). The reconstruction method was determined by patient anatomy and preferences and a variety of methods were used. (Table 1)

**Table 1. Type of breast reconstruction (Study III)**

Type of breast reconstruction (n=131)	Immediate reconstruction (n=13)	Delayed reconstruction (n=118)
<b>Pedicled flap (n=72)</b>		
LD musculocutaneous flap +/- implant	7	31
TRAM flap		10
Thoracodorsal artery perforator (TAP) flap + implant		1
TAP and intercostal artery perforator (ICAP) flaps		1
<b>Microvascular flap (n=53)</b>		
TRAM flap	6	32
DIEP flap		14
SIEA flap		1
<b>Implant only (n=6)</b>		
		6

### **7.3 Adjuvant therapy (Studies I-IV)**

#### *Studies I and II*

Following surgical treatment of the locally recurrent tumour 'secondary or pseudo' adjuvant therapy was administered according to individual patient risk factors for disease relapse.

#### *Study III*

Following mastectomy, radiotherapy (RT) was given according to hospital guidelines for tumour stage pT3and/or pN2. RT to regional nodes was recommended for all N2-N3 patients and during 2000-2001 also to N1 patients. During 2002-2003 nodal RT was recommended for patients with more than one macrometastatic axillary lymph node.

Systemic adjuvant treatment was administered based on the patient and disease characteristics at the discretion of the treating physician. In general, women with node-positive disease and those considered to have moderate-to-high risk node-negative disease received adjuvant systemic therapy. Premenopausal women with oestrogen receptor (ER)- or progesterone receptor (PgR)-positive cancer received tamoxifen and postmenopausal women either tamoxifen or an aromatase inhibitor for 5 years. Patients  $\leq 65$  years of age with moderate-to-high risk HER2-positive cancer received adjuvant trastuzumab and chemotherapy.

#### *Study IV*

With a lack of a general consensus concerning the benefit of adjuvant therapy in AS it has not been standard practice to administer adjuvant therapy in our institution. However in one case the administration of chemotherapy (paclitaxel) was prompted by the appearance of a local recurrence one month following radical surgery.

### **7.4 Follow-up (Studies I-IV)**

#### *Studies I and III*

Patients were followed-up according to a standard protocol at the same institution, initially at 4-6 weeks after surgery. Thereafter clinical examination, blood cell counts and blood chemistry and bilateral mammography with or without breast ultrasonography at 1-2 yearly intervals was adhered to in all patients. When a recurrence was suspected, an isotope bone scan and computed tomography were usually carried out as the initial staging examinations. After the first 5 years, follow-up was continued at a local health-care centre or at a private health-care company according to patient preference.

#### *Study II*

Following surgery for chest wall recurrent breast cancer follow-up was initially at 4-6 weeks after surgery and then yearly clinical checks with chest x-ray and when indicated CT chest/ MRI examination for 5 years. In some cases (n=8) yearly follow-up occurred in the patient's own district hospital.

#### *Study IV*

All cases were reviewed 1 month post operation by the multidisciplinary Helsinki Sarcoma group. All patients were then followed-up by a standard protocol at the same institution, initially at 4-6 weeks after surgery. Thereafter a protocol of clinical examination at 3 monthly intervals with chest x-ray and 6 monthly CT chest/MRI examination for 2 years was adhered to in all patients. This was followed by yearly clinical examination and CT chest/MRI examination for a further 5 years.

### **7.5 Statistical methods (Studies I-IV)**

#### *Study I*

The Chi-squared test was used to compare disease relapse rates in the two groups of patients who did and did not meet the selection criteria.

#### *Study II*

Kaplan-Meier curves were used to analyse survival. Statistical significance was set at a P value of <0.05. Log-rank analysis was used for univariate analysis of possible prognostic factors. Cox regression analysis was used for factors found significant on univariate analysis. (SPSS® for Windows® version 17.0; SPSS, Chicago, Illinois, USA).

#### *Study III*

Primary tumour characteristics were compared between the reconstruction and no reconstruction groups using the Chi-squared test. The 8-year estimate for LRR was computed using the Kaplan-Meier method. Breast cancer specific survival (BCSS) was calculated from the date of surgery to the date of death considered to be caused by breast cancer, and overall survival (OS) from the date of surgery to the date of death from any cause. Life tables were constructed according to Kaplan-Meier method and LRR free survival, distant metastases (DM) free survival, BCSS and OS between the groups was compared with the log-rank test and Cox proportional hazards models. P values of <0.05 were considered as statistically significant. (SPSS® for windows®version 20.0; SPSS, Chicago, Illinois, USA).

## 8. RESULTS

### 8.1 Study I

59 patients had stage 0-2 disease at primary operation (10 patients stage 0, 36 patients stage 1, 13 patients stage 2) and 1 patient stage 3 disease.

The local recurrence was initially detected by the patient in one third of cases and the remainder during follow-up by clinical and radiographic examination. The median length of time from primary therapy to local recurrence was 48 months (range 12-240 months). In 6 cases (10%) there was a clear difference in the histological type of tumour when comparing the primary tumour to the IBTR.

The reconstruction method was determined by patient anatomy and preferences, and a variety of methods was used as judged appropriate. Forty free flaps were performed. (Table 2) The mean age at surgery was 53 years. Axillary management consisted of axillary clearance (62%), no treatment (31%), SLNB (5%), and SLNB followed by axillary clearance (2%).

Table 2 Type of breast reconstruction (Study I)

Type of breast reconstruction	n=60
Free TRAM flap	31
Pedicled LD flap +/- implant	18
Free DIEP flap	7
Free SIEA flap	2
Implant only	1

#### *Oncological adjuvant therapy*

23 (38%) patients received secondary adjuvant oncological therapy following surgery of the IBTR. (Table 3)

Table 3 Adjuvant therapy for locally recurrent breast cancer (Studies I and II)

Adjuvant therapy for locally recurrent breast cancer	Study I	Study II
	n=23 (38%)	n=35 (88%)
Radiotherapy	0	2
Radiotherapy, chemotherapy	0	4a
Radiotherapy, hormonal therapy	0	1b
Radiotherapy, chemo- hormonal therapy	1	3c
Chemotherapy	3	17*d
Chemo- hormonal therapy	12	2**e
Hormonal therapy	7	6

\*3 cases neoadjuvant; \*\*1 case neoadjuvant; **a** 1 case palliative; **b** palliative; **c** 1 case palliative; **d** 3 cases palliative; **e** 1 case palliative

Complications and reoperations are shown in Table 4. There were no flap losses.

Table 4. Complications and reoperations (Study I)

Complications and reoperations	Number of patients
<b>Reoperations</b>	
Microvascular re-anastomosis	1
Wound infection debridement	1
Haematoma drainage	4
Flap skin/ fat necrosis debridement +/-skin graft	3
<b>Conservatively managed complications</b>	
<i>Flap related</i>	
Wound infection	3
Skin/ fat necrosis	2
<i>SSM</i>	
Minor skin flap necrosis	11
<i>Donor site</i>	
Seroma	2
Minor abdominal wound edge necrosis	4
<i>General</i>	
Pulmonary embolism (mild symptoms)	2

### *Disease relapse*

The median follow-up time after SSM and IBR was 84 months (range 14-190 months). 11 (18%) patients developed disease relapse and 49 (82%) patients remained disease-free. The median time interval to disease relapse was 40 months (range 6-64 months). Disease relapse consisted of 6 local re-recurrences (10%), 3 cases of regional lymph node metastasis and 2 cases of distant metastasis. 4 of the 11 (7% overall) patients with disease relapse eventually died. 5 year OS was 94% and 5 year DFS was 83%.

As many as 26 (43%) patients did not meet our selection criteria; but interestingly only 3 of these suffered a disease relapse (11.5%) compared to 8 (23.5%) of those who did meet the criteria. These 2 groups were compared using a Chi-squared test and no significant difference ( $p=0.234$ ) in disease relapse rates was found. The most common selection criteria not met were: recurrent tumour < 3cm, primarily node negative and recurrence more than 3 years after primary operation.

## 8.2 Study II

The mean age at primary breast cancer diagnosis was 46 years (range 32-67 years). (Table 5) The median disease-free interval after primary treatment to first recurrence was 2.4 years (range 0.3-34 years). Extensive chest wall recurrence was the first local relapse in less than half of the patients. Referral to our department for chest wall resection after failure of oncological therapy or earlier attempts at surgical excision elsewhere occurred in 25 patients.

Table 5 Characteristics of primary tumour and chest wall recurrence (Study II)

Primary breast cancer	n=40	Chest wall recurrence	n=40
<b>Age at primary diagnosis</b>		<b>Age (years)</b>	
<40	28	<60	28
>40	12	>60	12
<b>Primary tumour status</b>		<b>Interval to first recurrence (years)</b>	
T1	15	>2 years	21
T2	12	<2years	19
T3	5		
T4	3		
Unknown	5		
<b>Primary node status</b>		<b>Total no. of recurrences</b>	
No	17	1	18
N>o	18	2	11
Unknown	5	3	6
		4	4
		5	1
<b>Primary metastases</b>		<b>Earlier treatment of chest wall recurrence</b>	
Yes	1	Excision	16
No	35	Radiotherapy	17
Unknown	4	Chemotherapy	15
		Hormonal therapy	11
<b>Primary treatment</b>		<b>Distant metastasis</b>	
BCT	9	Yes	4
Mastectomy	31	No	36
<b>Primary radiotherapy</b>		<b>Ulceration</b>	
Yes	32	Yes	13
No	8	No	27
<b>Primary chemotherapy</b>		<b>Inflammatory signs</b>	
Yes	13	Yes	8
No	27	No	32
<b>Primary hormonal therapy</b>		<b>Intent of surgery</b>	
Yes	5	Curative	31
No	35	Palliative	9

The mean age at surgery was 54 years (range 33-77 years). (Table 6) The mean size of en bloc resection was 303 cm<sup>2</sup> (range 35-1400 cm<sup>2</sup>). A mean of 3.1 ribs (range 2-7) were resected and complete/partial sternal resection was performed in 9 patients. The median length of post-operative hospital stay was 10 days (range 3 - 28 days). The median intensive care stay was 6 days (range 2 – 10) for the FTCWR patients. Clear margins (Ro) were achieved in 27 (68%) cases and bone infiltration of ribs and/or sternum was confirmed histologically in 19 cases. (Neo)adjuvant or palliative oncological therapy was administered to 35 patients following surgery. (Table 3)

Table 6. Surgical resection and chest wall reconstruction data (Study II)

Surgical data	Number of patients
<b>Resected specimen</b>	
Soft tissue only	21
Soft tissue and bone	19
<b>Resection defect size</b>	
>150 cm <sup>2</sup>	27
<150 cm <sup>2</sup>	13
<b>Chest wall stabilisation</b>	
Yes	17
No	23
<b>Method of chest stabilisation</b>	
Synthetic mesh	
• Dacron	7
• Prolene	4
• Premilene	1
• Gore-tex mesh	1
Fascia lata	2
Free rib grafts	1
Dacron mesh and free rib graft	1
<b>Soft tissue reconstruction</b>	
Yes	40
No	0
<b>Method of soft tissue reconstruction</b>	
Pedicled flap (n=33)	
• LD musculocutaneous flap	29
• Bipedicled rectus abdominus musculocutaneous flap	2
• Pectoralis major muscle flap	1
• Scapular fasciocutaneous flap	1
Microvascular flap (n=7)	
• Tensor fascia lata +/- rectus femoris muscle flap	4
• LD musculocutaneous flap	2
• TRAM flap	1
<b>Radicality</b>	
R0	27
R1	3
R2	10
<b>Bone infiltration</b>	
Yes	19
No	21

*Notes:* R0-complete resection with microscopically negative resection margins; R1-macroscopically complete resection but diseased microscopic margins; R2- macroscopic residual disease after attempted resection

### *Complications*

There were no actual in-hospital deaths but 2 deaths occurred at 30 days due to medical complications after transfer to their local district hospital. There were neither any complete nor partial flap losses. (Table 7)

Table 7. Complications and reoperations (Study II)

Complications and reoperations	Number of patients
<b>Reoperations</b>	
Re-excision for R1 resection	1
Re-grafting of flap donor site	1
<b>Surgical complications (minor)</b>	
Delayed flap donor site healing	3
Flap donor site infection	2
Donor site seroma	1
<b>Medical complications</b>	
Pneumonia	2
Pulmonary embolism (mild)	1
Pleural effusion	1
Pneumothorax (small)	1

*Oncological outcome*

Median length of follow-up was 31 months (range 1 - 310). There were no patients lost at follow-up. 23 patients suffered disease relapse and in 13 patients the first recurrence was a locoregional relapse. Six patients lived longer than 10 years.

*Outcome after resection with curative intent*

Tumour-free resection margins (Ro) were achieved in 24/31(77%) patients. 20 patients however developed a relapse and half of these were locoregional. The median DFS after extensive resection was 31 months and the median OS was 52 months (95% CI 32 to 72 months). The 2 and 5 year OS rates were 71% and 32% respectively.

*Outcome after palliative resection*

Clear microscopic margins (Ro) were achieved in 3/9 patients. The median OS after extensive resection was 17 months. Unsurprisingly patients who had palliative surgery had a statistically significant lower survival rate as compared to patients treated with a curative intent. There were 2 locoregional relapses and 1 relapse in the ipsilateral LD flap donor site. This was subsequently treated with radiotherapy.

*Prognostic factors*

Patients aged less than 40 years at primary diagnosis and those with chest wall resections less than 150cm<sup>2</sup> had a higher survival rate that was statistically significant on univariate analysis. Multivariate cox regression analysis revealed that only resection size was still statistically significant with a threefold increased risk of mortality for resections more than 150 cm<sup>2</sup>.



### 8.3 Study III

The patient and tumour characteristics are provided in Table 8.

Table 8 Patient and tumour characteristics (Study III)

	Immediate reconstruction (n=13)	Delayed reconstruction (n=118)	No reconstruction (n=391)	Chi-square P
<b>Age at mastectomy</b>				
<40 yrs	2 (15%)	29 (25%)	13 (3%)	<0.0001
40-55 yrs	8 (62%)	63 (53%)	174 (45%)	
55-69 yrs	3 (23%)	26 (22%)	204 (52%)	
<b>Lymph node status</b>				
No	10 (77%)	47 (40%)	167 (43%)	0.1562
N1	2 (15%)	43 (36%)	138 (35%)	
N2-3	1 (8%)	28 (24%)	86 (22%)	
<b>Histological T-stage</b>				
T1	11 (84.6%)	49 (42%)	192 (49%)	0.0821
T2	1 (7.7%)	59 (50%)	160 (41%)	
T3	1 (7.7%)	6 (5%)	27 (7%)	
T4	0 (0%)	3 (3%)	12 (3%)	
Not available		1		
<b>Histological grade</b>				
1	3 (23%)	17 (14%)	93 (24%)	0.0423
2	7 (54%)	45 (39%)	167 (43%)	
3	3 (23%)	54 (47%)	126 (33%)	
Not available		2	5	
<b>Histological type</b>				
Ductal	7 (54%)	73 (62%)	213 (55%)	0.3106
Lobular	3 (23%)	34 (29%)	112 (29%)	
Other	3 (23%)	11 (9%)	65 (16%)	
Not available			1	
<b>ER status</b>				
Positive	9 (75%)	96 (81%)	310 (80%)	0.8521
Negative	3 (25%)	22 (19%)	78 (20%)	
Not available	1		3	
<b>PgR status</b>				
Positive	8 (67%)	77 (65%)	228 (59%)	0.4086
Negative	4 (33%)	41 (35%)	160 (41%)	
Not available	1		3	
<b>HER-2 status</b>				
Negative	10 (100%)	86 (81%)	293 (83%)	0.3057
Positive	0	20 (19%)	58 (17%)	
Not assessed	3	12	39	
Not available			1	
<b>MIB-1 proliferation index</b>				
Negative or very low	8 (80%)	45 (47%)	176 (53%)	0.213
Medium	0 (0%)	22 (23%)	55 (17%)	
High	2 (20%)	28 (30%)	98 (30%)	
Not available	3	23	62	

<b>Tumour multifocality</b>				
Yes	4 (31%)	39 (33%)	133 (34%)	0.9465
No	9 (69%)	79 (67%)	256 (66%)	
Not available			2	
<b>Extensive intraductal component</b>				
Yes	6 (46%)	27 (23%)	51(13%)	0.0004
No	7 (54%)	91 (77%)	340 (87%)	
<b>Axillary surgery</b>				
SLNB	4 (31%)	16 (14%)	48 (12%)	0.0972
ALND	8 (62%)	71 (60%)	269 (69%)	
Both	1 (7%)	31 (26%)	74 (19%)	
<b>Radiotherapy</b>				
Radiotherapy	2 (15.4%)	76 (64.4%)	230 (58.8%)	0.9476
No radiotherapy	11 (84.6%)	41 (35.6%)	159 (41.2%)	
Thoracic wall only	0	13 (11.0%)	45 (11.5%)	
Thoracic wall and regional nodes	2 (15.4%)	62 (52.5%)	182 (46.5%)	
Regional nodes only	0	1 (0.8%)	3 (0.8%)	
<b>Systemic adjuvant therapy</b>				
Chemotherapy	2 (15.4%)	20 (16.9%)	69 (17.6%)	0.0354
Endocrine therapy	0	15 (12.7%)	91 (23.3%)	
Chemo- and endocrine therapy	3 (23.1%)	72 (61%)	165 (42.2%)	
Chemotherapy and trastuzumab	0	2 (1.7%)	3 (0.8%)	
<b>Events</b>				
LRR	3 (23.1%)	1 (0.8%)	21 (5.4%)	0.1151
Contralateral cancer	0	4 (3.4%)	26 (6.6%)	0.0566
Distant metastasis	0	16 (13.6%)	84 (21.5%)	0.006
Deaths, breast cancer	0	3 (2.5%)	63 (16.1%)	0.0000
Deaths, other	0	0	21 (5.4%)	0.0256
Deaths, unknown cause	0	0	4 (1%)	0.5092

*Abbreviations:* ER=oestrogen receptor, PgR=progesterone receptor, HER2=human epidermal growth factor receptor-2. MIB-1=an antibody against Ki-67, SLNB=sentinel lymph node biopsy, ALND=axillary lymph node dissection

Reconstruction patients were younger, more frequently had EIC and a grade 3 tumour. Other potential prognostic/risk factors were similar between the reconstruction and mastectomy only patient groups (Table 8).

4 LRRs occurred in patients who underwent reconstruction (3.1%) and 21 LRRs occurred in patients treated with mastectomy only (5.4%), ( $P=0.1151$ , Chi square). The median time from primary surgery to LRR was 22 months (range 5-28 months) in the reconstruction group and 15 months (range 1-21 months) in the mastectomy only group. Three LRRs (2 mastectomy scar recurrences and 1 axillary recurrence) followed immediate reconstruction with free TRAM flap ( $n=1$ ) and LD flap ( $n=2$ ) at 5, 22 and 28 months after surgery. The only local recurrence in the delayed reconstruction group occurred 6 years prior to implant reconstruction. Therefore this patient was excluded from further statistical analyses.

Distant metastases were observed in 100 (19.2%) patients. No distant metastases occurred in patients with immediate reconstruction. Distant disease was diagnosed in 16 (13.6%) cases following delayed reconstruction and in 84 (21.5%) cases following mastectomy alone ( $P=0.006$ , Chi square).

Three (2.5%) patients died of breast cancer following reconstruction and 63 (16.1%) patients died following mastectomy alone ( $P=0.000003$ , Chi square). There were no deaths in the immediate reconstruction group from any cause. The cause of death was unknown or other than breast cancer in 25 (6.4%) patients. The 8-year BCSS was 88.7% and OS 84.1% for the entire study population.

#### *Reconstruction status as a risk factor for LRR, DM, BCSS and OS*

The 8-year LRR rate was 5.4% in the mastectomy only group, 0.8% in the delayed reconstruction group and 23.1% in the immediate reconstruction group. ( $P=0.001$ , log rank). Cox multivariate analysis revealed immediate reconstruction (HR 6.339; 95% CI 1.814-22.151,  $P=0.004$ ) to be an independent risk factor for LRR.

Patients who had a reconstruction had a lower 8 year rate of DM (9.2%), when compared to patients without reconstruction (19.9%) ( $P=0.010$ , log rank). Cox multivariate analysis revealed no reconstruction (HR 2.212; 95% CI 1.170-4.202,  $P=0.015$ ) to be an independent risk factor for DM.

In patients with no reconstruction the 8-year BCSS and OS were 85.7% and 79.5% respectively while these were both 98.5% in patients who had a reconstruction, log-rank  $P=0.000$ . In multivariate analysis no reconstruction was an independent risk factor for both poor BCSS (HR 20.408; 95%CI 2.778-142.857,  $P=0.003$ ) and poor OS (HR 28.571; 95%CI 3.968-200,  $P=0.001$ ).

#### *Outcome of patients without early distant recurrences*

The median time from mastectomy to delayed reconstruction was 34 months due to strict selection criteria as well as long waiting times. As delayed reconstruction was not offered to patients with early distant recurrence we decided to exclude all patients who developed distant metastases within 48 months of primary surgery in an attempt to compensate for this selection bias. The rate of distant metastasis now became similar between the reconstruction and no reconstruction groups ( $P=0.613$ , log rank). However the reconstruction group still had statistically significant superior BCSS ( $P=0.028$ ) and OS ( $P=0.000$ ).

## 8.4 Study IV

Angiosarcoma (AS) was diagnosed a median of 5.25 years (range 3.8-12.25 years) following RT. Median age at diagnosis of AS was 60 years (range 46-84 years). In 6 cases there was an apparent delay in establishing the diagnosis of AS. All patients presented with a reddish-purplish or ecchymosed lesion in the skin.

All AS lesions arose in the centre of the previously administered radiation fields. One exception was 1 patient who presented with a synchronous 3cm AS lesion in the lower pole of the normal contralateral breast.

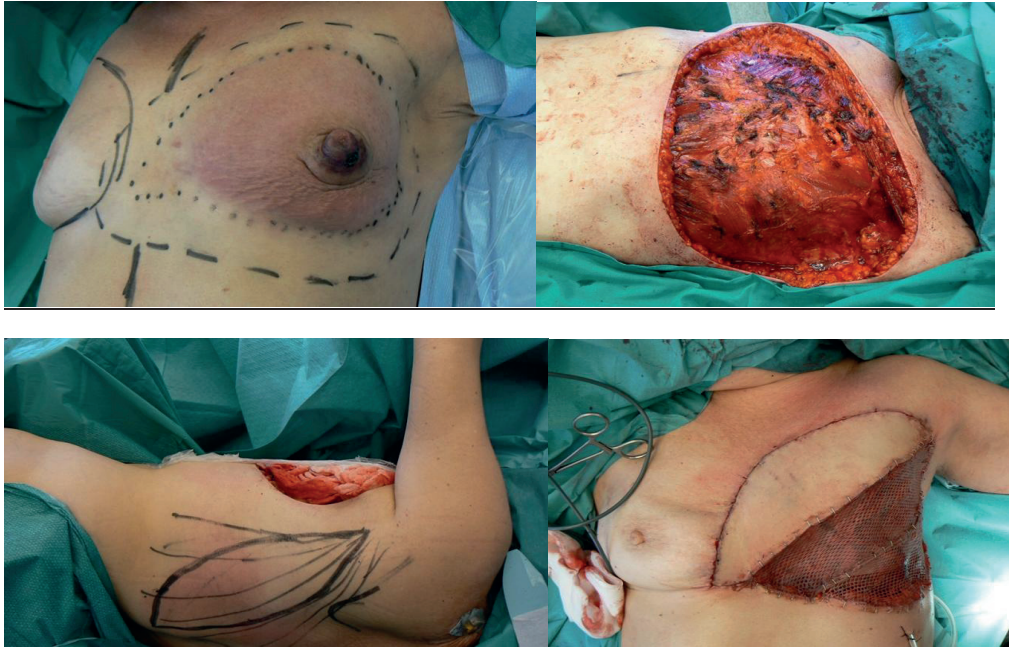All patients except one, underwent excision with a curative intent with a minimum clinical lateral margin of 3 cm. The exception was a case initially operated on in another hospital with a less radical resection and subsequently presented to us with widespread multiple lesions. For the remaining 9 patients however the surgical procedure consisted of radical mastectomy (n=5), simple mastectomy (n=2), wide local excision (n=1) and TRAM flap excision and wide local excision (n=1). Marked lateral and deep excision margins are shown in Table 9.

Table 9 Macroscopic excision margins for angiosarcoma (Study IV)

Macroscopic marked excision margins	Number of patients
<b>Lateral surgical margins</b>	
• >3cm	4
• 4-5cm	5
<b>Deep excision margins</b>	
• removing pectoralis major muscle fascia	3
• removing pectoralis muscle	5
• removing both pectoralis major & minor muscles	1

The post-excision defect was directly closed in 2 cases or reconstructed using a pedicled musculocutaneous LD flap (n=4) or split-thickness skin graft (n=4).

Figure 4 Wide resection of left breast AS and reconstruction with LD flap and skin graft



Following surgery there were no reported wound healing complications. Six cases were classified as high grade AS and all specimens underwent immunohistochemical analysis for factor VIII antigen, CD34 and CD31 markers. Clear histological margins were achieved in all cases. Wide histological margins (> 2cm) were recorded in eight cases and a marginal excision (< 2cm) recorded in two cases.

#### *Oncological outcome*

Median follow-up was 81 months (range 4-143 months). 3 patients suffered a recurrence. Two of these were local skin recurrences (1 and 3 months following surgery) and the other was a distant skin recurrence to the contralateral breast (37 months following surgery). One of the two local recurrences was initially treated by an extended course of chemotherapy and later by palliative surgical resection. She eventually died from disseminated AS disease. Surgical resection was planned for the other case of local recurrence but the patient was medically unfit for surgery and consequently managed palliatively. She died one month later from disseminated disease. The case of a distant recurrence in the contralateral breast followed earlier treatment for stage 1 primary breast cancer (mastectomy, axillary clearance but no adjuvant radiotherapy). This recurrence was treated by wide local excision and the patient was alive and disease-free at the end of the study period. 7 patients were alive and disease-free at the end of the study period. 3 patients died at 4, 8 and 13 months following surgery. 2 of these died from disseminated AS. The other case died from an unrelated cause. 5 year overall survival was 70%.

## 9. DISCUSSION

### 9.1 Management of locally recurrent breast cancer

Locoregional breast cancer recurrence is a heterogeneous disease entity that encompasses small ipsilateral breast tumour recurrences following primary breast conserving surgery as well as extensive chest wall recurrences following mastectomy occurring in the skin, subcutaneous tissue or musculoskeletal chest wall with or without regional nodal metastases. Patients with a local relapse after primary breast cancer surgery tend to have a poor prognosis (Abner et al.1993; Courdi A et al. 2006 Fodor et al. 2008). At present no standard guidelines exist for the management of a locally recurrent tumour. This is coupled with a lack of good clinical trials that would provide evidence in support of a more specific management rationale.

For an IBTR most would agree that salvage mastectomy is most appropriate (Chen and Martinez. 2008) and in exceptional cases a re-lumpectomy is possible (Ishitobi et al. 2011). In Helsinki we opt in nearly all cases for a salvage mastectomy for a local recurrence following breast conserving surgery. Immediate breast reconstruction is possible in those selected cases considered to have a good prognosis. In study I our follow-up time was fairly short but our local re-recurrence rate of 10% compares well with that following salvage mastectomy for locally recurrent breast cancer (Dalberg et al. 1998; Chen and Martinez. 2008). Our 5 year overall survival was 94% which compares very well with other reported figures of around 60-70% after treatment for IBTR (Clemons et al. 2001). Our 5 year disease free survival was 83% which also compares extremely well with long term reported rates of only 30-50% (Haffty et al. 1996; van Tienhoven et al.1999). Of course our markedly superior rates can be accounted for by the fact that our subset of IBTR patients were highly selected as those having a better prognosis. The introduction of new oncological treatment modalities since those older studies were performed is another possible contributory factor. However the good survival figures in our series show that IBTR was offered to women who could recover and benefit from the breast reconstruction.

Our selection criteria were originally intended to select those patients considered to have a more favourable prognosis; this was mainly in view of then limited resources. As many as 26 (43%) patients did not ultimately meet our selection criteria but these patients seemed to fare comparably well to those who did meet the criteria. This suggests that we should perhaps widen our selection criteria or use other predictive factors that may better identify patients at risk of further recurrence. In our patient series it appeared that a recurrent tumour > 3cm, primarily node positive or a recurrence less than 3 years after primary operation were risk factors that did not necessarily predict a poorer outlook. Positron emission tomography-computed tomography (PET-CT) is increasingly being used in tumour surveillance. It could perhaps have a valuable role to play in selecting those patients with IBTR who are most appropriate for SSM and IBTR by improved staging of the local recurrence and exclusion of distant disease (Radan et al. 2006).

In addition should one attempt to classify a local recurrence as a new primary tumour, a true recurrence or as persistence of disease? Each of these would then maybe require a slightly different management strategy as for example new primary tumours are associated with a better prognosis than a true recurrence (Veronesi et al. 1995; Huang et al. 2002; Nishimura et al.2005).

There is an ongoing debate as to whether IBTR is a cause of later distant metastases (Halstedian paradigm) or merely reflects tumour biology and is a manifestation of risk of distant relapse

(Fisherian paradigm). The Halstedian paradigm describes the sequential spread of breast cancer from a single focus within the breast and that lymph node involvement is necessary for haematogenous dissemination. In contrast the Fisherian paradigm states that the spread of tumour cells into the bloodstream occurs early in tumourigenesis and precedes lymph node infiltration. In any case local recurrence within a conserved breast is the single most important predictor of overall survival (Benson and Querci della Rovere. 2008).

Whereas there is general agreement that IBTR is potentially curable by surgery and secondary adjuvant therapy (when indicated); the same cannot be said for patients with a more extensive chest wall recurrence. These patients tend to have a poor prognosis and therefore there is some debate over the cost effectiveness of pursuing a curative approach in all cases. In fact in many institutions surgery is probably not the first line option taken. This notwithstanding the potential benefits of palliative surgery should be emphasized.

Extensive chest wall resections should aim to achieve local control, improve survival and/or provide good palliation with low morbidity and mortality. Reconstruction is then necessary to cover exposed vital structures, bring about timely wound closure and avoid delay in the administration of adjuvant therapy. Several series have demonstrated the safety of full-thickness chest wall resection (Arnold and Pairolero. 1996; Cohen and Ramasastry. 1996; Faneyte et al. 1997; Toi et al. 1997; Tukiainen et al. 2003; Chang et al. 2004; Losken et al. 2004; Pameijer et al. 2005). Our operative mortality rate of 5% is acceptable in comparison. (Operative mortality was defined as any death occurring within 30 days after surgery in or out of the hospital).

If bone or cartilage is exposed following resection then a flap of vascularised tissue is required to cover the defect. In cases of full-thickness defects of the bony chest wall with exposure of the vital structures, depending on anatomical location and defect size, some form of chest wall stabilisation may be required. Large anterior and antero-lateral thoracic wall defects usually require stabilisation to prevent flail chest (or lung herniation) and paradoxical breathing and to protect the underlying lungs and/or heart (Arnold and Pairolero. 1996; Cohen and Ramasastry. 1996; Chang et al. 2004; Losken et al. 2004). A synthetic mesh is most commonly employed. We tend to always use mesh stabilisation for defects up to 10 by 10 cm in size. For larger defects we include a rib graft or cement to further increase stability. We have found the critical areas in terms of flail movement risk to be the pleural dome area after extended forequarter amputation with rib resections and the sternal area. Following chest wall stabilisation a vascularised flap reconstruction is then required to provide a water and air tight closure of the chest cavity, control infection, obliterate dead space, cover the synthetic material and close the soft-tissue defect (Losken et al. 2004).

Several options for flap reconstruction exist. In our protocol we prefer to use a pedicled flap when possible; usually the pedicled latissimus dorsi flap when available due to its proximity to the defect, ease of mobilisation, large size and reliable pedicle. Other pedicled flap options include the pectoralis major muscle and VRAM flaps. Microvascular flaps may sometimes be necessary if local muscle flaps are unavailable or insufficient in size. We frequently use the free tensor fascia lata (TFL) or extended TFL musculocutaneous flap as this can provide a very large flap and allow a 2 team approach. The inclusion of the rectus femoris muscle enables an even larger flap with extra bulk to be harvested (Tukiainen et al. 2003). The TFL flap is also advantageous when considering donor site morbidity as there is minimal interference with respiratory function in contrast to other flap options from the thoraco-abdominal area. Other free flap options that we consider include the anterolateral thigh (ALT) and TRAM flaps. Occasionally we might use the omentum flap or breast flap. The use of flap reconstruction enables radical resections with wide excision margins.

The median disease-free interval after extensive resection for curative intent in our series was 2.5 years which compares well to a recent report by Aukema et al whose group recorded a 2 year median disease-free survival (Aukema et al. 2009). Overall survival rates vary widely between different published series and our 5 year survival rate of 32% is to the lower end of published 5 year survival rates that range from 18% to 71% (Faneyte et al. 1997; Toi et al. 1997; Downey et al. 2000; Chagpar et al. 2003; Pameijer et al. 2005; Friedel et al. 2008; van der Pol et al. 2009; Noble et al. 2010). Patient selection and the fact that all our cases had extensive recurrences may partly account for our lower comparative survival rate. Also our study covers a long time period in which treatment modalities have changed and staging improved with the use of better quality CT imaging in recent years. A RO resection was achieved in 68% of our cases which is similar to previous reports (Pameijer et al. 2005; Friedel et al. 2008; van der Pol et al. 2009).

Palliative surgery can be indicated for several reasons such as pain, haemorrhage, large malodorous ulceration, recurrent infection and local control of the disease. Quality of life benefits have been highlighted in a recent study (Veronesi et al. 2007). Our median survival of 1.4 years after palliative surgery compares well with other reports (Veronesi et al. 2007; Aukema et al. 2009). Only one third of these patients developed a local relapse. Furthermore many patients were very satisfied after surgery as they could now re-engage socially with family and friends.

Surgery may also have a useful role to play when oncological therapy cannot be continued due to extensive tumour ulceration. In this scenario radical resection and wound closure with a flap facilitates the provision of further oncological therapy.

A few studies have assessed the impact of prognostic factors on survival after chest wall recurrence (Faneyte et al. 1997; Chagpar et al. 2003; Pameijer et al. 2005; Friedel et al. 2008; van der Pol et al. 2009). In our study patients aged less than 40 years at primary diagnosis and those with chest wall resections less than 150cm<sup>2</sup> had a statistically significant higher survival rate on univariate analysis. Only resection size remained significant on multivariate analysis.

Our patients had extensive recurrences and in the majority of cases multiple earlier recurrences or unsuccessful oncological therapy. In spite of this we have achieved reasonable local control and overall survival through surgical intervention. A multidisciplinary approach should be emphasised with early consultation of the plastic surgeon. Patient selection is however critical and should be individualised with thorough pre-operative assessment of the possible benefits of surgery weighed against the risks. Two groups of patients appear to benefit the most from surgery. Curative resection and prolonged survival is possible in patients with a small chest wall recurrent tumour and palliative surgery should be considered in patients for whom quality of life issues are of paramount importance and social re-integration should be the aim of surgery.

The management of locally recurrent breast cancer should be multimodal with a multidisciplinary approach. The close co-operation of surgeons and oncologists is vital. The precise role of adjuvant therapy after surgery for both IBTR and chest wall recurrent breast cancer is unclear, but one must consider patients with any indicators for poor prognosis as described earlier. It may therefore be appropriate to administer adjuvant therapy to those patients with clearly defined risk factors for disease relapse (Sirohi et al. 2009).

We have analysed the results of reconstructive surgery in the setting of a locally recurrent breast cancer but maybe we should consider further the possibilities of preventing LRR. Following a diagnosis of primary breast cancer one should carefully plan, ideally in a multidisciplinary team, the appropriate management. The extent of surgery should be tailored to the 3 dimensional



features of the primary tumour and possible DCIS with the help of suitable imaging and preoperative histology in order to enable complete excision with sufficient margins and ultimately choosing between mastectomy and BCT. The importance of radiotherapy in improving prognosis has been re-appraised (Clarke et al. 2005; Darby et al. 2011).

## **9.2 The impact of breast reconstruction on oncological outcome**

Breast reconstruction is now a fundamental part of the overall management of patients with breast cancer. Numerous studies have reported very low recurrence rates following immediate and delayed breast reconstruction (Nieminen et al. 1999; Meretoja et al. 2007; Vaughan et al. 2007; McCarthy et al. 2008; Yi et al. 2011; Patterson et al. 2012). However in most studies a mastectomy only control group has been lacking.

A recent Swedish study by Isern et al. reported a higher rate of local and distant recurrences after delayed reconstruction when compared to mastectomy alone in a matched cohort of patients. This study comprised of only delayed flap reconstructions, all of which were pedicled or microvascular flaps (Isern et al. 2011). There have been a few studies that discuss the somewhat contentious possibility of surgery-driven enhancement of metastasis (Demicheli et al. 2008). Thus could the additional surgery of a major autologous reconstruction pose a risk in some patients? Our study consisted of mostly delayed autologous flap reconstructions and in contrast showed that breast reconstruction does not increase the DM rate nor worsen survival. This is also in agreement with several other studies (McCarthy et al. 2008; Eriksen et al. 2011; Nedumpara et al. 2011; Reddy et al. 2011; Agarwal et al. 2012). When considering free autologous reconstructions we recorded only one LR and 7 DMs following 63 microsurgical breast reconstructions. Similarly low LR and LLR rates have been reported following free TRAM flap reconstructions (Nieminen et al. 1999; Patterson et al. 2012). A possible explanation for the contradictory results of our study and the Swedish study lies in the different study settings. We had a slightly shorter follow-up time (median 102 months versus 146 months), although our DM rate does not appear to accelerate with time after reconstruction. Additionally the Swedish study involved patients operated primarily in ten different hospitals and the reconstructive surgery was performed between 1982 and 2001. Our series was a single institution experience from more recent times.

We found a higher rate of LRR after IBR than previously reported in other studies (Vaughan et al. 2007; McCarthy et al. 2008; Yi et al. 2011; Patterson et al. 2012). In nearly all our immediate cases a skin-sparing mastectomy (SSM) was performed and this group also had a higher frequency of extensive intraductal component. In addition mastectomy margins were not routinely assessed by a histopathologist during the study period. It is therefore possible that some breast tissue may have been left behind in the skin flaps of the SSM. Previous studies have reported the finding of residual breast tissue in the skin after SSM in up to 9.5% of cases (Torresan et al. 2005; Dreadin et al. 2012). This was associated with skin flaps greater than 5 mm thick (Torresan et al. 2005) but with no detrimental effect on oncological outcome (Dreadin et al. 2012). Our IBR group was however very small (n=13, 2 LR and 1 LRR) due to the fact that the main indication for immediate reconstruction was extensive DCIS as the pre-operative diagnosis. A larger series of IBRs from our unit has been published and the rate of LRR was 5.8% in patients with stage 0-2 disease and 31% in women with stage 3 disease after a mean follow-up of 70 months (Meretoja et al. 2007). Thus it is difficult to draw reliable conclusions from our results. A recent meta-analysis demonstrated no evidence for increased LR with IBR compared with mastectomy alone (Gieni et al. 2012).

In order to compensate for selection bias we excluded patients with an early distant recurrence. This resulted in a similar DM rate between the reconstruction and no reconstruction groups but BCSS and OS remained superior in reconstruction patients. This could be due to the fact that patients selected for reconstruction were younger and most likely had less severe co-morbidities. Patients with poorer general health may not be fit enough for chemotherapy which in turn may result in a poorer BCSS as well as an inferior OS.

In summary the strengths of study III were the presence of a control group and a reasonable follow-up time but the main limitations included the lack of randomization and being retrospective in nature. No prospective randomized trials comparing mastectomy with or without breast reconstruction have been published. This can be attributed to several factors: ethical reasons, the need for individualized therapies and unique patient anatomy. Therefore randomization would be almost impossible.

#### **9.4 Surgical management and oncological outcome of radiation-associated breast angiosarcoma**

In addition to the risk of breast cancer relapse there is another threat to the survival of the patient following treatment of the primary disease. Of those patients who have received radiotherapy around 0.05% will develop an aggressive secondary breast/ chest wall soft-tissue sarcoma which is associated with a poor prognosis: angiosarcoma (Marchal et al. 1999). This entity was first reported by Stewart and Treves in 1948 as a consequence of upper extremity chronic lymphoedema following mastectomy and axillary clearance (Stewart and Treves. 1948).

All the cases of AS in our series were diagnosed during the last 10 years which may reflect the increasing use of RT in breast cancer management. Every case developed in the centre of the radiation field which correlates with the area receiving the full prescribed radiation dose of 50 Gy. The median latency period for the development of AS in our study was 5 years. This is comparable to other studies (2-9 years), and shorter than the traditional latency period for other RT induced sarcomas of more than 10 years (Fineberg and Rosen. 1994; Strobbe et al. 1998; Monroe et al. 2003; Hodgson et al. 2007; Feigenberg et al. 2002; Seinen et al. 2012; Hui et al. 2012; Morgan et al. 2012; Jallali et al. 2012). A recent study shows that the risk of AS only decreases to the normal non-RT risk after 20 years (Mery et al. 2009).

We saw two bilateral cases of breast AS and very few bilateral cases have been reported in the literature. One case consisted of a synchronous AS occurring in the contralateral previously normal non-irradiated breast and the other case consisted of a metachronous tumour occurring in the contralateral breast previously treated for breast cancer but without RT. This suggests the possibility of another contributing, maybe genetic, factor (de Bree et al. 2002; West et al. 2012).

Early diagnosis of AS is essential due to its aggressive course. We observed difficulty in making an early diagnosis of AS and this may be due to several reasons; lack of awareness of this rare condition, non-specific clinical signs with often benign-looking lesions. Additionally the histological diagnosis of AS may not always be straightforward (Fineberg and Rosen. 1994). Thus clinicians need to be vigilant with regards to the possibility of AS in breast cancer patients earlier treated with radiotherapy. Thorough physical examination and prompt multiple punch biopsies are essential. Other investigations such as mammography and MRI play only a limited role in diagnosing AS (Monroe et al. 2003; West et al. 2005; Hodgson et al. 2007).

The main treatment modality is surgery in the form of a wide excision that usually encompasses a simple/radical mastectomy (Strobbe et al. 1998; Marchal et al. 1999; Feigenberg et al. 2002; Monroe et al. 2003; Billings et al. 2004; Cha et al. 2004; Vorburger et al. 2005; West et al. 2005; Hodgson et al. 2007; Biswas et al. 2009; Young et al. 2010; Hui et al. 2012; Morgan et al. 2012; Seinen et al. 2012; Jallali et al. 2012). Regional lymph node involvement is uncommon either at presentation or at recurrence; hence routine axillary lymph node dissection is not indicated (Monroe et al. 2003). Based on the results of our study we recommend performing the resection with macroscopic lateral margins greater than 3cm, preferably 4-5 cm and deep margins including at least the pectoralis fascia. We achieved wide (>2cm) histological margins in all but one case. One recent report noted that incomplete excisions in their series usually involved the deep margin when pectoralis major muscle was not included (Jallali et al. 2012) and another report emphasized the need for radical removal of both pectoralis major and minor muscles (Hui et al. 2012). The extent of the irradiated field should also be considered when planning the surgical margin widths and another recent study recommended resection of all at-risk irradiated breast skin (Morgan et al. 2012). There is an argument for deferring immediate flap reconstruction until a later date due to high rates of local recurrence. The post-excision defect can then be satisfactorily covered with a split-thickness skin graft in the interim. However we now tend to cover the defect immediately with a pedicled LD flap instead of grafting. Other recent reports have similarly described the use of flaps for immediate closure (Hui et al. 2012; Jallali et al. 2012).

Seven patients were alive and disease-free at the end of the study period (median follow-up 81 months). In comparison with other studies that report very poor overall survival, our experience has been more encouraging (Marchal et al. 1999; Monroe et al. 2003; Billings et al. 2004; Cha et al. 2004; Hodgson et al. 2007; Hui et al. 2012; Seinen et al. 2012; Jallali et al. 2012).

We are likely to see the incidence of AS rise as more women are treated by BCT for early stage breast cancer. Consequently, education of the patient, general practitioner, oncologist and surgeon is necessary to raise awareness of this condition. Although routine follow-up for breast cancer is 5 years in many centres we would recommend surveillance for up to 20 years following RT.

## 10. CONCLUSIONS

- I Skin-sparing mastectomy and immediate breast reconstruction is a feasible treatment option for selected patients who develop a local recurrence following earlier breast conserving therapy.
- II In selected patients autologous flap reconstruction enables the resection of extensive chest wall recurrent breast tumours with acceptable morbidity and reasonable local control and survival. Palliative surgery can also be invaluable to improve the quality of life in patients with extensive symptomatic recurrences.
- III Breast reconstruction does not appear to adversely influence disease progression in forms of locoregional recurrences or distant metastases when compared to patients treated with mastectomy only.
- IV Early diagnosis and excision with wide macroscopic margins is vital in improving survival in cases of radiation-associated angiosarcoma

## 11. ACKNOWLEDGEMENTS

A Finnish mother and yearly summers spent by the sea in beautiful Rauma on the west-coast of Finland provided enough incentive to realise a long-held dream of mine and finally make the move from the UK to this northern corner of Europe six years ago. However, I met Professor Erkki Tukainen for the first time in the summer of 2004. By this time I had already decided on a career pathway in Plastic surgery. This meeting proved to be a pivotal moment in my life. The possibility of working in Helsinki in an internationally highly-regarded Department of Plastic surgery and combine a PhD program was too tempting to ignore. The necessary Finnish language tests and doctor licensing processes were completed and I eventually arrived in Helsinki (via a short and unforgettable stint in Kittilä, Lapland) in early June 2007. The generosity and friendliness of the Plastics department in Töölö quickly made me feel very welcome. In spite of some initially sticky (and sometimes hilarious) moments with the Finnish language I quickly felt at home. So I would like to take this opportunity from the outset to thank Erkki and Sinikka S for giving me the chance to come to Helsinki in the first place.

The idea for the thesis came from Docent Tiina Jahkola, a remarkable woman and the very essence of altruism. As the chief supervisor she constantly provided help and assistance, always with such positivity and enthusiasm. Thank you so much.

Professor Erkki Tukainen was my other chief supervisor and his surgical expertise is of course unparalleled. He has been a truly inspiring figure with his fascinating insights into chest wall reconstruction and has always been at hand to help and advise at all stages of the thesis. He offers hope to many patients in Finland diagnosed with an advanced tumour that in most centres worldwide would be deemed inoperable and a lost cause. We should all be grateful.

I would also like to thank Docent Karl von Smitten for his advice and input for the first paper. I very much enjoyed our visit to Sarajevo for a Balkan breast meeting when we presented the results of Study I. With his vast surgical experience and expertise in treating breast cancer I learnt immensely during my time on the Breast unit.

Docent Marjut Leidenius (and current Head of the Breast unit) also provided a fantastic training in scientific research and writing. I particularly appreciated her quick responses to any questions I had and also her clear and methodical approach to research in general. Thank you Marjut.

I would also like to thank Docent Tom Böhling for his help and always positive disposition in relation to the pathology in Study IV.

A special thanks goes to Dr Tuomo Meretoja, a co-author on the first paper, for his expert help and for setting a fine example with his own impressive PhD thesis on immediate breast reconstruction.

Other key research collaborators who should be acknowledged include Dr Leila Vaalavirta and Mikko Tenhunen for their help in addressing the radiation therapy aspects of angiosarcoma, Dr Elina Siponen for her help in Study III, Docent Johan Lundin for granting me access to the Helsinki Cancer database, Petteri Grönhölm for his indispensable assistance in locating the patients for study II, Tuija YK and Susanna K for many useful words of advice and Jukka Alstela for his tireless help in providing many of the photographs as well as a few sips of whisky along the way.

Next I would like to make a special mention of certain colleagues from the Plastics Töölö family. Docent Patrik Lassus has from the very beginning of my time in Helsinki been a continual figure of support and advice, much like an older brother, with whom I look forward to a long future

collaboration. Docent Jyrki Vuola and head of the Helsinki Burn Centre has also been a constantly supportive senior figure. I have really enjoyed our work together on the Burns unit and I have learnt so much from his vast Burns and Plastic surgical experience. I must also thank all the Burns staff who have made my 2 year period in Burns so memorable. Likewise I would like to thank the Kenya team of girls for what was a unique experience for us all. The short time in Nairobi had an important impact on me personally as well as career-wise. Continuing the Burns theme I would also like to thank all the Plastics trainees who have worked with me in Burns over the past couple of years. It has sometimes been sweaty but a lot of fun too!

Penstcho Popov and Kalle Ståhlberg have been as well as work colleagues, also very good friends from the time since I arrived in Helsinki. Docent Virve Koljonen and Junnu Leikola also belong to the latter category. Thank you.

Thanks also to Mikko V a fellow Rööperiläinen for being a solidly nice chap and friend outside of work who shares my passion for football.

A big thank you to Jaana, our department's extraordinary secretary who has always been a huge help in all work matters as well as flat-hunting in Helsinki.

Outside of work I would like to acknowledge some significant others.

Firstly I have to mention an old friend from my medical school days in London who tragically lost his life last year. Joseph Footitt was one of life's unique characters, a one-off personality who shared with me a passion for life and had a fantastic sense of humour. We spent our medical elective in Argentina and once ended up on live national Argentine radio answering questions about 'Islas Malvinas'. He was a respiratory physician and keen researcher. A terrible loss.

I wish to thank the Munsterhjelm family and Margareta von Swetlik for their great kindness and hospitality. Thanks especially to Berent for many fantastic outdoor adventures such as the hike to the northernmost end of Europe. My next goal is to improve my Swedish!

Thanks also to Nina who was always very supportive and truly understood what this PhD means to me. The piano has also been a loyal ally to whom I have turned to in moments of frustration. A few recurring songs come to mind that have alleviated the occasional moments of despair (Blind Willie McTell by Bob Dylan, Sabali by Amadou & Mariam, Green Fields by the Good, The Bad and the Queen). I would also like to thank my cousin Assi, my relatives and friends in Rauma, and Iris. Apologies for being too busy to visit in recent times but you have always been in my thoughts.

All that I am and everything that I have achieved in life I owe to my parents and their abiding love and support. If not for skype I probably would have stayed in the UK. My sister equally, more like a best friend, has always been there for me. Janne and little Isabella deserve a very special mention too. Thank you all so much.

Lastly I want to sincerely thank someone very close to me. From the first moment we met she has woken me up and revealed to me the bigger picture in this world. Ultimately, Teresa provided me with the inspiration to make it across the finishing line.

Andrew Lindford

Helsinki, May 2013

*'Kun kettu kaivaa aina jotain löytyy'*

A British/Finnish proverb

## 12. REFERENCES

- Abner AL, Recht A, Eberlein T, Come S, Shulman L, Hayes D, Connolly JL, Schnitt SJ, Silver B, Harris JR. Prognosis following salvage mastectomy for recurrence in the breast after conservative surgery and radiation therapy for early-stage breast cancer. *J Clin Oncol.* 11(1):44-8; 1993
- Agarwal J, Agarwal S, Pappas L, Neumayer L. A population-based study of breast cancer-specific survival following mastectomy and immediate or early-delayed breast reconstruction. *Breast J.* May;18(3):226-32; 2012
- Agulnik M, Yarber JL, Okuno SH, von Mehren M, Jovanovic BD, Brockstein BE, Evens AM, Benjamin RS. An open-label, multicenter, phase II study of bevacizumab for the treatment of angiosarcoma and epithelioid hemangioendotheliomas. *Ann Oncol.* Aug 21; 2012 [Epub ahead of print]
- Al-Ghazal SK, Sully L, Fallowfield L, Blamey RW. The psychological impact of immediate rather than delayed breast reconstruction. *Eur J Surg Oncol.* Feb;26(1):17-9; 2000
- Alpert TE, Kuerer HM, Arthur DW, Lannin DR, Haffty BG. Ipsilateral breast tumor recurrence after breast conservation therapy: outcomes of salvage mastectomy vs. salvage breast-conserving surgery and prognostic factors for salvage breast preservation. *Int J Radiat Oncol Biol Phys.* Nov 1;63(3):845-51; 2005
- Arnold PG, Pairolero PC. Chest-wall reconstruction: an account of 500 consecutive patients. *Plast Reconstr Surg.* 98(5):804-10; 1996
- Aukema TS, Russell NS, Wesseling J, Rutgers EJ. Extensive soft tissue resection with autologous tissue closure for locally recurrent breast cancer: lasting local control and acceptable morbidity. *Eur J Surg Oncol.* 35(5):469-74; 2009
- Benson JR, Querci della Rovere G. Ipsilateral breast cancer recurrence. *The Breast.* 17(1):12-18; 2008
- Billings SD, McKenney JK, Folpe AL, Hardacre MC, Weiss SW. Cutaneous angiosarcoma following breast-conserving surgery and radiation: an analysis of 27 cases. *Am J Surg Pathol.* Jun;28(6):781-8; 2004
- Biswas T, Tang P, Muhs A, Ling M. Angiosarcoma of the breast: a rare clinicopathological entity. *Am J Clin Oncol.* Dec;32(6):582-6; 2009
- Brenn T, Fletcher CD. Radiation-associated cutaneous atypical vascular lesions and angiosarcoma: clinicopathologic analysis of 42 cases. *Am J Surg Pathol.* Aug;29(8):983-96; 2005
- Buchanan CL, Dorn PL, Fey J, Giron G, Naik A, Mendez J, Murphy C, Sclafani LM. Locoregional recurrence after mastectomy: incidence and outcomes. *J Am Coll Surg.* 203(4):469-74; 2006
- Cahan WG, Woodard HQ. Sarcoma arising in irradiated bone; report of 11 cases. *Cancer.* May;1(1):3-29; 1948



- Cardoso F, Fallowfield L, Costa A, Castiglione M, Senkus E. ESMO Guidelines Working Group. Locally recurrent or metastatic breast cancer: ESMO Clinical Practice Guidelines for diagnosis, treatment and follow-up. *Ann Oncol.* Sep;22Suppl 6:vi25-30; 2011
- Carlson GW, Styblo TM, Lyles RH, Jones G, Murray DR, Staley CA, Wood WC. The use of skin sparing mastectomy in the treatment of breast cancer: The Emory experience. *Surg. Oncol.* 12(4):265-269; 2003
- Cha C, Antonescu CR, Quan ML, Maru S, Brennan MF. Long-term results with resection of radiation-induced soft tissue sarcomas. *Ann Surg.* Jun;239(6):903-9; 2004
- Chagpar A, Langstein HN, Kronowitz SJ, Singletary SE, Ross MI, Buchholz TA, Hunt KK, Kuerer HM. Treatment and outcome of patients with chest wall recurrence after mastectomy and breast reconstruction. *Am J Surg.* Feb;187(2):164-9; 2004
- Chagpar A, Meric-Bernstam F, Hunt KK, Ross MI, Cristofanilli M, Singletary SE, Buchholz TA, Ames FC, Marcy S, Babiera GV, Feig BW, Hortobagyi GN, Kuerer HM. Chest wall recurrence after mastectomy does not always portend a dismal outcome. *Ann Surg Oncol.* 10(6):628-34; 2003
- Chang RR, Mehrara BJ, Hu QY, Disa JJ, Cordeiro PG. Reconstruction of complex oncologic chest wall defects: a 10-year experience. *Ann Plast Surg.* 52(5):471-9; 2004
- Chen SL, Martinez SR. The survival impact of the choice of surgical procedure after ipsilateral breast cancer recurrence. *Am J Surg.* 196(4):495-9; 2008.
- Clarke M, Collins R, Darby S, Davies C, Elphinstone P, Evans E, Godwin J, Gray R, Hicks C, James S, MacKinnon E, McGale P, McHugh T, Peto R, Taylor C, Wang Y. Effects of radiotherapy and of differences in the extent of surgery for early breast cancer on local recurrence and 15-year survival: an overview of the randomised trials. Early Breast Cancer Trialists' Collaborative Group (EBCTCG). *Lancet.* 366(9503):2087-106; 2005.
- Clemons M, Hamilton T, Goss P. Does treatment at the time of locoregional failure of breast cancer alter prognosis? *Cancer Treat Rev.* 27(2):83-97; 2001
- Clemons M, Hamilton T, Mansi J, Lockwood G, Goss P. Management of recurrent locoregional breast cancer: oncologist survey. *Breast.* 12(5):328-37; 2003.
- Cohen M, Ramasastry SS. Reconstruction of complex chest wall defects. *Am J Surg.* 172(1):35-40; 1996
- Courdi A, Largillier R, Ferrero JM, Lallement M, Raoust I, Ettore F, Peyrottes I, Chamorey E, Balu-Maestro C, Chapellier C. Early versus late local recurrences after conservative treatment of breast carcinoma: differences in primary tumor characteristics and patient outcome. *Oncology.* 71(5-6):361-8; 2006
- Cozen W, Bernstein L, Wang F, Press MF, Mack TM. The risk of angiosarcoma following primary breast cancer. *Br J Cancer.* Oct;81(3):532-6; 1999
- Dahlstrøm KK, Andersson AP, Andersen M, Krag C. Wide local excision of recurrent breast cancer in the thoracic wall. *Cancer.* 72(3):774-7; 1993

- Daigeler A, Druecke D, Hakimi M, Duchna HW, Goertz O, Homann HH, Lehnhardt M, Steinau HU. Reconstruction of the thoracic wall-long-term follow-up including pulmonary function tests. *Langenbecks Arch Surg.* Jul;394(4):705-15; 2009
- Dalberg K, Mattsson A, Sandelin K, Rutqvist LE. Outcome of treatment for ipsilateral breast tumor recurrence in early-stage breast cancer. *Breast Cancer Res Treat.* 49(1):69-78; 1998.
- de Bree E, van Coevorden F, Peterse JL, Russell NS, Rutgers EJ. Bilateral angiosarcoma of the breast after conservative treatment of bilateral invasive carcinoma: genetic predisposition? *Eur J Surg Oncol.* Jun;28(4):392-5; 2002
- Demicheli R, Retsky MW, Hrushesky WJ, Baum M, Gukas ID. The effects of surgery on tumor growth: a century of investigations. *Ann Oncol.* Nov;19(11):1821-8; 2008
- Demicheli R, Biganzoli E, Boracchi P, Greco M, Retsky MW. Recurrence dynamics does not depend on the recurrence site. *Breast Cancer Res.* 10(5):R83; 2008
- Derckx F, Maaskant-Braat AJ, van der Sangen MJ, Nieuwenhuijzen GA, van de Poll-Franse LV, Roumen RM, Voogd AC. Staging and management of axillary lymph nodes in patients with local recurrence in the breast or chest wall after a previous negative sentinel node procedure. *Eur J Surg Oncol.* Jul;36(7):646-51; 2010
- Devon RK, Rosen MA, Mies C, Orel SG. Breast reconstruction with a transverse rectus abdominis myocutaneous flap: spectrum of normal and abnormal MR imaging findings. *RadioGraphics.* 24:1287-1299; 2004
- Disa JJ, Cordeiro PG, Heerdt AH, Petrek JA, Borgen PJ, Hidalgo DA. Skin-sparing mastectomy and immediate autologous tissue reconstruction after whole-breast irradiation. *Plast Reconstr Surg.* 111(1):118-24; 2003
- Downey RJ, Rusch V, Hsu FI, Leon L, Venkatraman E, Linehan D, Bains M, van Zee K, Korst R, Ginsberg R. Chest wall resection for locally recurrent breast cancer: is it worthwhile? *J Thorac Cardiovasc Surg.* 119(3):420-8; 2000
- Dreadin J, Sarode V, Saint-Cyr M, Hynan LS, Rao R. Risk of residual breast tissue after skin-sparing mastectomy. *Breast J.* May-Jun;18(3):248-52; 2012
- Early Breast Cancer Trialists' Collaborative Group (EBCTCG). Effects of chemotherapy and hormonal therapy for early breast cancer on recurrence and 15-year survival: an overview of the randomised trials. *Lancet.* May 14-20;365(9472):1687-717; 2005
- Early Breast Cancer Trialists' Collaborative Group (EBCTCG), Darby S, McGale P, ym. Effect of radiotherapy after breast-conserving surgery on 10-year recurrence and 15-year breast cancer death: meta-analysis of individual patient data for 10,801 women in 17 randomised trials. *Lancet.* 378:1707-16;2011
- Elder EE, Brandberg Y, Björklund T, Rylander R, Lagergren J, Jurell G, Wickman M, Sandelin K. Quality of life and patient satisfaction in breast cancer patients after immediate breast reconstruction: a prospective study. *Breast.* Jun;14(3):201-8; 2005
- Elder EE, Kennedy CW, Gluch L Carmalt HL, Janu NC, Joseph MG, Donellan MJ, Molland JG, Gillett DJ. Patterns of breast cancer relapse. *Eur J Surg Oncol.* 32(9):922-7; 2006

Ellis H. The treatment of breast cancer: a study in evolution. The Bradshaw Lecture. Royal College of Surgeons of England; Dec. 12<sup>th</sup>1986

Enzinger FM, Weiss SW. Soft tissue tumors. St. Louis: Mosby. 641-677; 1995

Eriksen C, Frisell J, Wickman M, Lidbrink E, Krawiec K, Sandelin K. Immediate reconstruction with implants in women with invasive breast cancer does not affect oncological safety in a matched cohort study. *Breast Cancer Res Treat.* Jun;127(2):439-46; 2011

Evidence-based medicine guidelines of diagnosis and treatment of breast cancer in Finland. Käypähoito.[www.kaypahoito.fi](http://www.kaypahoito.fi)

Fan Y, Xu B, Liao Y, Yao S, Sun Y. A retrospective study of metachronous and synchronous ipsilateral supraclavicular lymph node metastases in breast cancer patients. *Breast.* Oct;19(5):365-9; 2010

Faneyte IF, Rutgers EJ, Zoetmulder FA. Chest wall resection in the treatment of locally recurrent breast carcinoma: indications and outcome for 44 patients. *Cancer.* 80(5):886-91; 1997

Feigenberg SJ, Mendenhall NP, Reith JD, Ward JR, Copeland EM, 3<sup>rd</sup>. Angiosarcoma after breast-conserving therapy: experience with hyperfractionated radiotherapy. *Int J Radiat Oncol Biol Phys.* Mar 1;52(3):620-6; 2002

Fineberg S, Rosen PP. Cutaneous angiosarcoma and atypical vascular lesions of the skin and breast after radiation therapy for breast carcinoma. *Am J Clin Pathol.* Dec;102(6):757-63; 1994

Finnish Cancer Registry. [www.cancerregistry.fi/eng](http://www.cancerregistry.fi/eng)

Fisher B, Anderson S, Bryant J, Margolese RG, Deutsch M, Fisher ER, Jeong JH, Wolmark N. Twenty-year follow-up of a randomized trial comparing total mastectomy, lumpectomy, and lumpectomy plus irradiation for the treatment of invasive breast cancer. *NEngl J Med.* Oct 17;347(16):1233-41; 2002

Fisher ER, Gregorio RM, Fisher B, Redmond C, Vellios F, Sommers SC. The pathology of invasive breast cancer. A syllabus derived from findings of the National Surgical Adjuvant Breast Project (protocol no. 4). *Cancer.* Jul;36(1):1-85; 1975

Fodor J, Major T, Polgár C, Orosz Z, Sulyok Z, Kásler M. Prognosis of patients with local recurrence after mastectomy or conservative surgery for early-stage invasive breast cancer. *Breast.* 17(3):302-8; 2008

Fredriksson I, Liljegren G, Arnesson LG, Emdin SO, Palm-Sjövall M, Fornander T, Holmqvist M, Holmberg L, Frisell J. Local recurrence in the breast after conservative surgery--a study of prognosis and prognostic factors in 391 women. *Eur J Cancer.* Sep;38(14):1860-70; 2002

Friedel G, Kuipers T, Dippon J, Al-Kammash F, Walles T, Kyriss T, Veit S, Greulich M, Steger V. Full-thickness resection with myocutaneous flap reconstruction for locally recurrent breast cancer. *Ann Thorac Surg.* 85(6): 1894-900; 2008

Gieni M, Avram R, Dickson L, Farrokhyar F, Lovrics P, Faidi S, Sne N. Local breast cancer recurrence after mastectomy and immediate breast reconstruction for invasive cancer: a meta-analysis. *Breast.* Jun;21(3):230-6; 2012

- Goldhirsch A, Wood WC, Coates AS, ym. Strategies for subtypes - dealing with the diversity of breast cancer: highlights of the St Gallen International Expert Consensus on the Primary Therapy of Early Breast Cancer. *Annals of Oncology*. 22:1736–1747; 2011
- Gui GP, Behranwala KA, Abdullah N, Seet J, Osin P, Nerurkar A, Lakhani SR. The inframammary fold: contents, clinical significance and implications for immediate breast reconstruction. *Br J Plast Surg*. Mar;57(2):146-9; 2004
- Haffty BG, Reiss M, Beinfield M, Fischer D, Ward B, McKhann C. Ipsilateral breast tumour recurrence as a predictor of distant disease: implications for systemic therapy at the time of local relapse. *J Clin Oncol*. 14(1):52-7; 1996
- Halverson KJ, Perez CA, Kuske RR, Garcia DM, Simpson JR, Fineberg B. Survival following locoregional recurrence of breast cancer: univariate and multivariate analysis. *Int J Radiat Oncol Biol Phys*. 23(2):285-91; 1992
- Harris JR, Lippman ME, Morrow M; Hellman S: *Diseases of the Breast*. Philadelphia, PA, Lippincott-Raven 1996
- Haylock BJ, Coppin CM, Jackson J, Basco VE, Wilson KS. Locoregional first recurrence after mastectomy: prospective cohort studies with and without immediate chemotherapy. *Int J Radiat Oncol Biol Phys*. Jan 15;46(2):355-62; 2000
- Helvie MA, Wilson TE, Roubidoux MA, Wilkins EG, Chang AE. Mammographic appearance of recurrent breast carcinoma in six patients with TRAM flap breast reconstructions. *Radiology*. Dec;209(3):711-5; 1998
- Hodgson NC, Bowen-Wells C, Moffat F, Franceschi D, Avisar E. Angiosarcomas of the breast: a review of 70 cases. *Am J Clin Oncol*. Dec;30(6):570-3; 2007
- Howard MA, Polo K, Pusic AL, Cordeiro PG, Hidalgo DA, Mehrara B, Disa JJ. Breast cancer local recurrence after mastectomy and TRAM flap reconstruction: incidence and treatment options. *Plast Reconstr Surg*. Apr 15;117(5):1381-6; 2006
- Hsi RA, Antell A, Schultz DJ, Solin LJ. Radiation therapy for chest wall recurrence of breast cancer after mastectomy in a favorable subgroup of patients. *Int J Radiat Oncol Biol Phys*. 42(3):495-9; 1998
- Huang E, Buchholz TA, Meric F, Krishnamurthy S, Mirza NQ, Ames FC, Feig BW, Kuerer HM, Ross MI, Singletary SE, McNeese MD, Strom EA, Hunt KK. Classifying local disease recurrences after breast conservation therapy based on location and histology: new primary tumors have more favorable outcomes than true local disease recurrences. *Cancer*. 95(10):2059-67; 2002
- Huang J, Mackillop WJ. Increased risk of soft tissue sarcoma after radiotherapy in women with breast carcinoma. *Cancer*. Jul 1;92(1):172-80; 2001
- Hui A, Henderson M, Speakman D, Skandarajah A. Angiosarcoma of the breast: a difficult surgical challenge. *Breast*. Aug;21(4):584-9; 2012
- Huston TL, Simmons RM. Locally recurrent breast cancer after conservation therapy. *Am J Surg*. Feb;189(2):229-35; 2005

- Isern AE, Manjer J, Malina J, Loman N, Mårtensson T, Bofin A, Hagen AI, Tengrup I, Landberg G, Ringberg A. Risk of recurrence following delayed large flap reconstruction after mastectomy for breast cancer. *Br J Surg.* May;98(5):659-66; 2011
- Ishitobi M, Komoike Y, Nakahara S, Motomura K, Koyama H, Inaji H. Repeat lumpectomy for ipsilateral breast tumour recurrence after breast-conserving treatment. *Oncology.* 81(5-6):381-6; 2011
- Jahkola T, Asko-Seljavaara S, von Smitten K. Immediate breast reconstruction. *Scand J Surg.* 92(4):249-56; 2003
- Jahkola T, Asko-Seljavaara S, von Smitten K. Safety of immediate breast reconstruction. *Handchir Mikrochir Plast Chir.* 2004 Dec;36(6):355-61; 2004
- Jallali N, James S, Searle A, Ghattaura A, Hayes A, Harris P. Surgical management of radiation-induced angiosarcoma after breast conservation therapy. *Am J Surg.* Feb;203(2):156-61; 2012
- Kapoor NS, Sim MS, Lin J, Giuliano AE. Long-term Outcome of Patients Managed With Sentinel Lymph Node Biopsy Alone for Node-Negative Invasive Breast Cancer. *Arch Surg.* Jul 16:1-7; 2012
- Karlsson P, Holmberg E, Samuelsson A, Johansson KA, Wallgren A. Soft tissue sarcoma after treatment for breast cancer--a Swedish population-based study. *Eur J Cancer.* Dec;34(13):2068-75; 1998
- Kimura M, Yanagita Y, Fujisawa T, Koida T. Study of time-course changes in annual recurrence rates for breast cancer: data analysis of 2,209 patients for 10 years post-surgery. *Breast Cancer Res Treat.* Dec;106(3):407-11; 2007
- Kirova YM, Vilcoq JR, Asselain B, Sastre-Garau X, Fourquet A. Radiation-induced sarcomas after radiotherapy for breast carcinoma: a large-scale single-institution review. *Cancer.* Aug 15;104(4):856-63; 2005
- Koizumi M, Koyama M, Tada K, Nishimura S, Miyagi Y, Makita M, Yoshimoto M, Iwase T, Horii R, Akiyama F, Saga T. The feasibility of sentinel node biopsy in the previously treated breast. *Eur J Surg Oncol.* 34(4):365-8; 2008
- Komdeur R, Hoekstra HJ, Molenaar WM, Van Den Berg E, Zwart N, Pras E, Plaza-Menacho I, Hofstra RM, Van Der Graaf WT. Clinicopathologic assessment of postradiation sarcomas: KIT as a potential treatment target. *Clin Cancer Res.* Aug 1;9(8):2926-32;2003
- Kurtz JM, Amalric R, Brandone H, Ayme Y, Jacquemier J, Pietra JC, Hans D, Pollet JF, Bressac C, Spitalier JM. Local recurrence after breast-conserving surgery and radiotherapy. Frequency, time course, and prognosis. *Cancer* 63: 1912-1917; 1989.
- Langstein HN, Cheng MH, Singletary SE, Robb GL, Hoy E, Smith TL, Kroll SS. Breast cancer recurrence after immediate reconstruction: patterns and significance. *Plast Reconstr Surg.* Feb;111(2):712-20; 2003
- Lê MG, Arriagada R, Spielmann M, Guinebretière JM, Rochard F. Prognostic factors for death after an isolated local recurrence in patients with early-stage breast carcinoma. *Cancer.* 1;94(11):2813-20; 2002

- Lee TJ, Hur WJ, Kim EK, Ahn SH. Outcome of management of local recurrence after immediate transverse rectus abdominis myocutaneous flap breast reconstruction. *Arch Plast Surg.* Jul;39(4):376-83; 2012
- LePage MA, Kazerooni EA, Helvie MA, Wilkins EG. Breast reconstruction with TRAM flaps: normal and abnormal appearances at CT. *Radiographics.* Nov-Dec;19(6):1593-603; 1999
- Lindford AJ, Meretoja TJ, von Smitten KA, Jahkola TA. Skin-sparing mastectomy and immediate breast reconstruction in the management of locally recurrent breast cancer. *Ann Surg Oncol.* 17(6):1669-74; 2010
- Lindfors KK, Meyer JE, Busse PM, Kopans DB, Munzenrider JE, Sawicka JM. CT evaluation of local and regional breast cancer recurrence. *AJR Am J Roentgenol.* Oct;145(4):833-7; 1985
- Losken A, Jurkiewicz MJ. History of breast reconstruction. *Breast Dis.* 16: 3-9; 2002
- Losken A, Thourani VH, Carlson GW, Jones GE, Culbertson JH, Miller JI, Mansour KA. A reconstructive algorithm for plastic surgery following extensive chest wall resection. *Br J Plast Surg.* 57(4):295-302; 2004
- Lucas DR. Angiosarcoma, radiation-associated angiosarcoma, and atypical vascular lesion. *Arch Pathol Lab Med.* Nov;133(11):1804-9; 2009
- Maaskant-Braat AJ, de Bruijn SZ, Woensdregt K, Pijpers H, Voogd AC, Nieuwenhuijzen GA. Lymphatic mapping after previous breast surgery. *Breast.* Aug;21(4):444-8; 2012
- Marchal C, Weber B, de Lafontan B, Resbeut M, Mignotte H, du Chatelard PP, Cutuli B, Reme-Saumon M, Broussier-Leroux A, Chaplain G, Lesaunier F, Dilhuydy JM, Lagrange JL. Nine breast angiosarcomas after conservative treatment for breast carcinoma: a survey from French comprehensive Cancer Centers. *Int J Radiat Oncol Biol Phys.* Apr 1;44(1):113-9; 1999
- McCarthy CM, Pusic AL, Sclafani L, Buchanan C, Fey JV, Disa JJ, Mehrara BJ, Cordeiro PG. Breast cancer recurrence following prosthetic, postmastectomy reconstruction: incidence, detection, and treatment. *Plast Reconstr Surg.* 121(2):381-8; 2008
- Mellemkjaer L, Friis S, Olsen JH, Scélo G, Hemminki K, Tracey E, Andersen A, Brewster DH, Pukkala E, McBride ML, Kliever EV, Tonita JM, Kee-Seng C, Pompe-Kirn V, Martos C, Jonasson JG, Boffetta P, Brennan P. Risk of second cancer among women with breast cancer. *Int J Cancer.* May 1;118(9):2285-92; 2006
- Meretoja TJ, Rasia S, von Smitten KA, Asko-Seljavaara SL, Kuokkanen HO, Jahkola TA. Late results of skin-sparing mastectomy followed by immediate breast reconstruction. *Br J Surg.* 94(10):1220-5; 2007
- Meretoja T, von Smitten K, Leidenius M, Svarvar C, Asko-Seljavaara S, Heikkilä P, Jahkola T. Local recurrence of stage 1 to 2 breast cancer after skin-sparing mastectomy and immediate breast reconstruction in a 15-year series. *Eur J Surg Oncol.* 33: 1142-5; 2007
- Meretoja TJ, Svarvar C, Jahkola TA. Outcome of oncoplastic breast surgery in 90 prospective patients. *Am J Surg.* Aug;200(2):224-8; 2010
- Mery CM, George S, Bertagnolli MM, Raut CP. Secondary sarcomas after radiotherapy for breast cancer: sustained risk and poor survival. *Cancer.* Sep 15;115(18):4055-63; 2009

- Monroe AT, Feigenberg SJ, Mendenhall NP. Angiosarcoma after breast-conserving therapy. *Cancer*. Apr 15;97(8):1832-40; 2003
- Morgan EA, Kozono DE, Wang Q, Mery CM, Butrynski JE, Baldini EH, George S, Nascimento AF, Raut CP. Cutaneous radiation-associated angiosarcoma of the breast: poor prognosis in a rare secondary malignancy. *Ann Surg Oncol*. Nov;19(12):3801-8; 2012
- National Comprehensive Cancer Network. NCCN guidelines®. [www.nccn.org](http://www.nccn.org)
- Nedumpara T, Jonker L, Williams MR. Impact of immediate breast reconstruction on breast cancer recurrence and survival. *Breast*. Oct;20(5):437-43; 2011
- Newman LA, Kuerer HM, Hunt KK, Kroll SS, Ames FC, Ross MI, Feig BW, Singletary SE. Presentation, treatment, and outcome of local recurrence after skin-sparing mastectomy and immediate breast reconstruction. *Ann Surg Oncol*. Oct-Nov;5(7):620-6; 1998
- Newman LA, Hunt KK, Buchholz T, Kuerer HM, Vlastos G, Mirza N, Ames FC, Ross MI, Singletary SE. Presentation, management and outcome of axillary recurrence from breast cancer. *Am J Surg*. Oct;180(4):252-6; 2000
- Nieminen T, Asko-Seljavaara S, Suominen E, Kuokkanen H, von Smitten K. Free microvascular tram flaps: report of 185 breast reconstructions. *Scand J Plast Reconstr Surg Hand Surg*. 33(3):295-300; 1999
- Nishimura S, Takahashi K, Akiyama F, Oguchi M, Tada K, Makita M, Iwase T, Yoshimoto M, Yamashita T, Sakamoto G, Kasumi F. Classification of ipsilateral breast tumor recurrence after breast-conserving therapy: new primary cancer allows a good prognosis. *Breast Cancer*.12(2):112-7; 2005
- Noble J, Sirohi B, Ashley S, Ladas G, Smith I. Sternal/para-sternal resection for parasternal local recurrence in breast cancer. *Breast*. 19(5):350-4; 2010
- Olivari N. The latissimus flap. *Br J Plast Surg*. Apr;29(2):126-8;1976
- Pameijer CR, Smith D, McCahill LE, Bimston DN, Wagman LD, Ellenhorn JD. Full-thickness chest wall resection for recurrent breast carcinoma: an institutional review and meta-analysis. *Am Surg*. 71(9):711-5; 2005
- Patterson SG, Teller P, Iyengar R, Carlson GW, Gabram-Mendola SG, Losken A, Styblo T, Torres M, Wood WC, Perez SD, Mosunjac M, Rizzo M. Locoregional Recurrence after Mastectomy with Immediate Transverse Rectus Abdominis Myocutaneous (TRAM) Flap Reconstruction. *Ann Surg Oncol*. Aug;19(8):2679-84; 2012
- Penel N, Bui BN, Bay JO, Cupissol D, Ray-Coquard I, Piperno-Neumann S, Kerbrat P, Fournier C, Taieb S, Jimenez M, Isambert N, Peyrade F, Chevreau C, Bompas E, Brain EG, Blay JY. Phase II trial of weekly paclitaxel for unresectable angiosarcoma: the ANGIOTAX Study. *J Clin Oncol*. Nov 10;26(32):5269-74; 2008
- Peng C, Chang CB, Tso HH, Flowers CI, Hylton NM, Joe BN. MRI appearance of tumor recurrence in myocutaneous flap reconstruction after mastectomy. *AJR Am J Roentgenol*. Apr;196(4):W471-5; 2011

Quinn EM, Coveney AP, Redmond HP. Use of magnetic resonance imaging in detection of breast cancer recurrence: a systematic review. *Ann Surg Oncol.* Sep;19(9):3035-41; 2012

Radan L, Ben-Haim S, Bar-Shalom R, Guralnik L, Israel O. The role of FDG-PET/CT in suspected recurrence of breast cancer. *Cancer.* 107(11):2545-51; 2006

Rainsbury RM. Skin-sparing mastectomy. *Br J Surg.* Mar;93(3):276-81;2006

Rauschecker HHF, Clarke MJ, Gatzemeier W, Recht A. Systemic therapy for treating locoregional recurrence in women with breast cancer (Review). *Cochrane review, The Cochrane Library, Issue 4;* 2008

Reddy S, Colakoglu S, Curtis MS, Yueh JH, Ogunleye A, Tobias AM, Lee BT. Breast cancer recurrence following postmastectomy reconstruction compared to mastectomy with no reconstruction. *Ann Plast Surg.* May;66(5):466-71; 2011

Rusby JE, Smith BL, Gui GP. Nipple-sparing mastectomy. *Br J Surg.* Mar;97(3):305-16;2010

Rutgers EJ; EUSOMA Consensus Group. Quality control in the locoregional treatment of breast cancer. *Eur J Cancer.* Mar;37(4):447-53; 2001

Seinen JM, Styring E, Verstappen V, Vult von Steyern F, Rydholm A, Suurmeijer AJ, Hoekstra HJ. Radiation-associated angiosarcoma after breast cancer: high recurrence rate and poor survival despite surgical treatment with RO resection. *Ann Surg Oncol.* Aug;19(8):2700-6; 2012

Shaikh N, LaTrenta G, Swistel A, Osborne FM. Detection of recurrent breast cancer after TRAM flap reconstruction. *Ann Plast Surg.* Dec;47(6):602-7; 2001

Shikama N, Sekiguchi K, Nakamura N. Management of locoregional recurrence of breast cancer. *Breast Cancer.* Oct;18(4):252-8; 2011

Siponen ET, Vaalavirta L, Joensuu H, Vironen J, Heikkilä P, Leidenius MH. Ipsilateral breast recurrence after breast conserving surgery in patients with small ( $\leq 2$ cm) breast cancer treated with modern adjuvant therapies. *Eur J Surg Oncol.* Jan;37(1):25-31; 2011

Siponen ET, Vaalavirta LA, Joensuu H, Leidenius MH. Axillary and supraclavicular recurrences are rare after axillary lymph node dissection in breast cancer. *World J Surg.* Feb;36(2):295-302; 2012

Siponen ET, Joensuu H, Leidenius MH. Local recurrence of breast cancer after mastectomy and modern multidisciplinary treatment. *Acta Oncol.* Jan;52(1):66-72; 2013

Sirohi B, Leary A, Johnston SR. Ipsilateral breast tumor recurrence: is there any evidence for benefit of further systemic therapy? *Breast J.* May-Jun;15(3):268-78; 2009

Stewart FW, Treves N. Lymphangiosarcoma in postmastectomy lymphedema; a report of six cases in elephantiasis chirurgica. *Cancer.* May;1(1):64-81; 1948

Strobbe LJ, Peterse HL, van Tinteren H, Wijnmaalen A, Rutgers EJ. Angiosarcoma of the breast after conservation therapy for invasive cancer, the incidence and outcome. An unforeseen sequela. *Breast Cancer Res Treat.* Jan;47(2):101-9; 1998



Tagliabue E, Agresti R, Carcangiu ML, Ghirelli C, Morelli D, Campiglio M, Martel M, Giovanazzi R, Greco M, Balsari A, Ménard S. Role of HER2 in wound-induced breast carcinoma proliferation. *Lancet*. Aug 16;362(9383):527-33; 2003

The American Society of Breast Surgeons. Consensus Statement on Guidelines for Performing Sentinel Lymph Node Dissection in Breast Cancer. December 2005.

Toi M, Tanaka S, Bando M, Hayashi K, Tominaga T. Outcome of surgical resection for chest wall recurrence in breast cancer patients. *J Surg Oncol*. 64(1):23-6; 1997

Torresan RZ, dos Santos CC, Okamura H, Alvarenga M. Evaluation of residual glandular tissue after skin-sparing mastectomies. *Ann Surg Oncol*. Dec;12(12):1037-44; 2005

Toth BA, Lappert P. Modified skin incisions for mastectomy: the need for plastic surgical input in preoperative planning. *Plast Reconstr Surg*. Jun;87(6):1048-53; 1991

Tukiainen E, Popov P, Asko-Seljavaara S. Microvascular reconstructions of full-thickness oncological chest wall defects. *Ann Surg*. 238(6):794-801; 2003

van der Pol CC, van Geel AN, Menke-Pluymers MB, Schmitz PI, Lans TE. Prognostic factors in 77 curative chest wall resections for isolated breast cancer recurrence. *Ann Surg Oncol*. 16(12):3414-21; 2009

van Tienhoven G, Voogd AC, Peterse JL, Nielsen M, Andersen KW, Mignolet F, Sylvester R, Fentiman IS, van der Schueren E, van Zijl K, Blichert-Toft M, Bartelink H, van Dongen JA. Prognosis after treatment for loco-regional recurrence after mastectomy or breast conserving therapy in two randomised trials (EORTC 10801 and DBCG-82TM). EORTC Breast Cancer Cooperative Group and the Danish Breast Cancer Cooperative Group. *Eur J Cancer*. 35(1):32-8; 1999

Vaughan A, Dietz JR, Aft R, Gillanders WE, Eberlein TJ, Freer P, Margenthaler JA. Scientific Presentation Award. Patterns of local breast cancer recurrence after skin-sparing mastectomy and immediate breast reconstruction. *Am J Surg*. 194(4):438-43; 2007

Veronesi U, Luini A, Del Vecchio M, Greco M, Galimberti V, Merson M, Rilke F, Sacchini V, Saccozzi R, Savio T, Zucali R, Zurrida S, Salvadori B. Radiotherapy after breast-preserving surgery in women with localized cancer of the breast. *N Engl J Med*. 328(22):1587-91; 1993

Veronesi U, Marubini E, Del Vecchio M, Manzari A, Andreola S, Greco M, Luini A, Merson M, Saccozzi R, Rilke F. Local recurrences and distant metastases after conservative breast cancer treatments: partly independent events. *J Natl Cancer Inst*. Jan 4;87(1):19-27; 1995

Veronesi U, Cascinelli N, Mariani L, Greco M, Saccozzi R, Luini A, Aguilar M, Marubini E. Twenty-year follow-up of a randomized study comparing breast-conserving surgery with radical mastectomy for early breast cancer. *N Engl J Med*. Oct 17;347(16):1227-32; 2002

Veronesi G, Scanagatta P, Goldhirsch A, Rietjens M, Colleoni M, Pelosi G, Spaggiari L. Results of chest wall resection for recurrent or locally advanced breast malignancies. *Breast*. 16(3):297-302; 2007

- Virtanen A, Pukkala E, Auvinen A. Angiosarcoma after radiotherapy: a cohort study of 332,163 Finnish cancer patients. *Br J Cancer*. Jul 2;97(1):115-7; 2007
- von Smitten K. Margin status after breast-conserving treatment of breast cancer: how much free margin is enough? *J Surg Oncol*. 98(8):585-7; 2008
- Vorburger SA, Xing Y, Hunt KK, Lakin GE, Benjamin RS, Feig BW, et al. Angiosarcoma of the breast. *Cancer*. Dec 15;104(12):2682-8; 2005
- Walsh N, Kiluk JV, Sun W, Khakpour N, Laronga C, Lee MC. Ipsilateral nodal recurrence after axillary dissection for breast cancer. *J Surg Res*. Sep;177(1):81-6; 2012
- Wapnir IL, Aebi S, Gelber S, Anderson SJ, Láng I, Robidoux A, Mamounas EP, Wolmark N. Progress on BIG 1-02/IBCSG 27-02/NSABP B-37, a prospective randomized trial evaluating chemotherapy after local therapy for isolated locoregional recurrences of breast cancer. *Ann Surg Oncol*. Nov;15(11):3227-31; 2008
- Wertheim U, Ozzello L. Neoplastic involvement of nipple and skin flap in carcinoma of the breast. *Am J Surg Pathol*. Dec;4(6):543-9; 1980
- West JG, Qureshi A, West JE, Chacon M, Sutherland ML, Haghghi B, et al. Risk of angiosarcoma following breast conservation: a clinical alert. *Breast J*. Mar-Apr;11(2):115-23; 2005
- West JG, Weitzel JN, Tao ML, Carpenter M, West JE, Fanning C. BRCA mutations and the risk of angiosarcoma after breast cancer treatment. *Clin Breast Cancer*. Dec;8(6):533-7; 2008
- Wiklund TA, Blomqvist CP, Råty J, Elomaa I, Rissanen P, Miettinen M. Postirradiation sarcoma. Analysis of a nationwide cancer registry material. *Cancer*. Aug 1;68(3):524-31; 1991
- Willner J, Kiricuta IC, Kölbl O. Locoregional recurrence of breast cancer following mastectomy: always a fatal event? Results of univariate and multivariate analysis. *Int J Radiat Oncol Biol Phys*. 37(4):853-63; 1997
- Yap J, Chuba PJ, Thomas R, Aref A, Lucas D, Severson RK, Hamre M. Sarcoma as a second malignancy after treatment for breast cancer. *Int J Radiat Oncol Biol Phys*. Apr 1;52(5):1231-7; 2002
- Yi M, Kronowitz SJ, Meric-Bernstam F, Feig BW, Symmans WF, Lucci A, Ross MI, Babiera GV, Kuerer HM, Hunt KK. Local, regional, and systemic recurrence rates in patients undergoing skin-sparing mastectomy compared with conventional mastectomy. *Cancer*. Mar 1;117(5):916-24; 2011
- Young RJ, Brown NJ, Reed MW, Hughes D, Woll PJ. Angiosarcoma. *Lancet Oncol*. Oct;11(10):983-91; 2010