Faculty of Medicine
Department of Plastic Surgery
University of Helsinki
Dissertationes Universitatis Helsingiensis
342/2026

Supporting Technologies in the Assessment and Reconstruction of Bony Orbit

Eeva Kormi

ACADEMIC DISSERTATION
To be presented, with the permission of the faculty of medicine of the University of Helsinki, for public examination in Niilo Hallman Auditorium, Park Hospital, on 21 August 2026, at 12 noon.

Helsinki 2026

Supervisors

Associate Professor Juho Suojanen
Cleft Palate and Craniofacial Centre, Department of Plastic Surgery
Helsinki University Hospital
Helsinki, Finland

Department of Oral and Maxillofacial Surgery
Päijät-Häme Central Hospital
Lahti, Finland.

Professor Junnu Leikola
Cleft Palate and Craniofacial Centre, Department of Plastic Surgery
Helsinki University Hospital,
Helsinki, Finland

Reviewers

Professor Roman Khonsari
Department of Maxillo-Facial Surgery and Plastic Surgery
Necker-Enfants Malades University Hospital
Assistance Publique – Hôpitaux de Paris
Université de Paris
Paris, France

Craniofacial Growth and Form Laboratory
Imagine Institute
Paris, France

Associate Professor Pertti Patinen
University of Oulu
Oulu, Finland

Opponent

Associate professor Daniel Nowinski

Department of Surgical Sciences

Plastic Surgery

University of Uppsala

Uppsala, Sweden

Department of Plastic and Maxillofacial Surgery

Uppsala University Hospital

Uppsala, Sweden

Custos

Professor Virve Koljonen

Department of Plastic Surgery

Helsinki University Hospital

Helsinki, Finland

University of Helsinki

Helsinki, Finland

Publisher: University of Helsinki
Series: Dissertationes Universitatis Helsingiensis 342/2026
Cover Image: Eeva Kormi

ISBN 978-952-84-2797-1 (paperback)
ISBN 978-952-84-2796-4 (PDF)
ISSN 2954-2898 (print)
ISSN 2954-2952 (online)

PunaMusta, Joensuu 2026

To Armi and Asta

Abstract

The anatomy of the bony orbit is a challenge in maxillofacial surgery. Orbital blow-out fractures are common in facial trauma and need both clinical and radiological assessment. Esthetics and function are the aim when opting for reconstruction. Facial asymmetry is evident in patients with unilateral cleft lip and palate (UCLP), not only adjacent to the cleft but also extending to the level of the bony orbits. This should be considered when planning surgery. Assessing radiological orbital volume asymmetry is time consuming, and automatization is available to facilitate this. Emerging technologies of computer assisted design and computer assisted manufacturing (CAD/CAM) enable virtual surgical planning (VSP) and patient-specific implants (PSI) in reconstruction. Three-dimensional (3D) planning in orthognathic surgery, such as the surgical correction of cleft patients, challenges conventional planning landmarks because of the asymmetry of the facial structures and even the orbits.

This thesis assesses novel technologies of personalized medicine in orbital trauma and cleft patients. The retrospective studies investigate the accuracy and cost-effectiveness of PSI in blow-out fracture surgery and the usefulness of automated segmentation in volumetric measurement of orbital vault. The studies also show the asymmetry of the orbits of UCLP patients and its connection to VSP.

The main findings were that PSI is accurate in reconstructing blow-out fractures and fits well in their planned position (Study I). The use of PSI also reflects the volume of the contralateral bony orbit better than conventional titanium meshes or pre-bent plates, and reduced operating time compensates for higher implant costs (Study IV). The automated segmentation tool is a repeatable method for assessing the orbital volume and can be used especially in thin computed tomography (CT) slices, but it is not similar to manual segmentation and cannot be used interchangeably (Study III). A novel finding is that facial asymmetry is evident at an orbital level in UCLP patients, and this should be considered in 3D VSP (Study II).

This series of studies shows that novel technologies are useful and accurate but cannot be used interchangeably with conventional methods. Adopting novel methods requires new approaches in both planning and performing.

Keywords: bony orbit, orbital asymmetry, cleft lip and palate, blow-out fracture, virtual surgical planning, patient specific implants, automated segmentation, orbital imaging, cost of care

Tiivistelmä

Luisen silmäkuopan anatomia on monimutkainen ja muodostaa kasvoluiden kirurgiassa haasteen. Kasvoluiden murtumat ovat yleisiä ja niiden korjaaminen niin toiminnan palauttamisen kuin estetiikankin osalta on haastavaa. Tavanomaisesti silmäkuopat ovat symmetriset, ja tämä on myös kirurgian tavoite estetiikan ja funktion saavuttamiseksi. Luisen silmäkuopan murtumissa kliininen ja radiologinen arviointi on oleellista leikkausta suunnitellessa. Traumapotilaiden lisäksi myös toispuoleisesta huulisuulakihalkiosta kärsivillä potilailla on epäsymmetriaa silmäkuoppien alueella.

Uudet teknologiat kuten kolmiulotteisen kuvantamisen mahdollistama tietokoneavusteinen diagnosointi, suunnittelu ja tuotanto ovat avanneet uuden maailman. Virtuaalinen kirurginen suunnittelu ennen leikkausta ja potilaskohtaiset istutteet lisäävät leikkausten ennustettavuutta ja tarkkuutta. Uusi tapa suunnitella ja toteuttaa leikkauksia kuitenkin vaatii uusien lähtökohtien omaksumista myös suunnittelussa.

Silmäkuopan luisen pohjan murtumissa arvioidaan symmetriaa niin ennen leikkausta kuin leikkauksen jälkeen. Virtuaalinen suunnittelu mahdollistaa ehjän puolen peilaamisen ja korjausleikkauksen suunnittelun potilaskohtaisine istutteineen. Silmäkuopan tilavuuden arviointi on oleellinen asia arvioitaessa, hyötyykö potilas leikkauksesta ja myös leikkauksen jälkeen onko leikkaustulos tyydyttävä. Kuitenkin tilavuuden arviointi manuaalisesti on työlästä, ja voi vaihdella radiologikohtaisesti. Automaattinen segmentointi on uusi teknologia, joka automatisoi prosessin.

Myös halkiopotilaiden kohdalla asymmetrian arviointi on tärkeä osa suunnittelussa ennen leikkausta. Aiemmin leukojen epäsuhdan arviointiin on käytetty kaksiulotteisia kuvantamisia, ja myös kolmiulotteinen virtuaalisuunnittelu on pohjannut näihin maamerkkeihin. Kasvojen epäsymmetria on merkittävää potilailla, joilla on toispuolinen halkio, mutta kolmiulotteinen kuvantaminen mahdollistaa tarkemman arvion, ja antaa uuden näkökulman myös leikkaussuunnitteluun.

Tämä väitöstutkimus tutkii, vastaako luisen silmäkuopan murtumissa virtuaalisuunniteltu potilaskohtainen istute todellista leikkauksessa toteutunutta asemaa, vastaako potilaskohtaisella istutteella toteutettu silmäkuopan murtuman korjaus vastapuolen silmäkuopan tilavuutta paremmin kuin perinteisesti titaaniverkolla korjattu, ja onko tämä taloudellisesti kannattavaa ottaen huomioon potilaskohtaisen istutteen korkeampi hinta. Silmäkuoppien tilavuuden suhteen arvioidaan, onko automaattinen segmentointi luotettava murtumapotilaiden silmäkuoppien tilavuuslaskennassa, ja minkälaisin rajoituksin tätä voi hyödyntää. Toispuolisten halkiopotilaiden osalta tutkimusaiheena on asymmetrian arviointi silmäkuoppien alueella ottaen huomioon ortognaattisen kirurgian virtuaalisuunnittelun. Kolmiulotteista kuvantamista hyödyntävät teknologiat mahdollistavat uudet diagnostiikka-, suunnittelu- ja leikkaustavat. Väitöskirja tarkastelee luisten silmäkuoppien alueen osalta näiden mahdollisuuksia ja rajoituksia sekä kustannustehokkuutta.

List of abbreviations

2D Two-dimensional
3D Three-dimensional
AI Artificial intelligence
Bimax Bimaxillary osteotomy
BSSO Bilateral sagittal split osteotomy
CAD/CAM Computer assisted design and computer assisted manufacturing
CBCT Computed Cone Beam Tomography
CLP Cleft lip and palate
CPCC Cleft Palate and Craniofacial Centre
CT Computed Tomography
DICOM Digital imaging and communications in medicine
DL Deep learning
HTA Health technology assessment
HU Hounsfield units
HUH Helsinki University Hospital
ML Machine learning
MMF Maxillomandibular fixation
MRI Magnetic resonance imaging
NOE Naso-orbitoethmoid
OECD Organization for Economic Co-operation and Development
PDS Polydioxanone
PEEK Polyetheretherketone
PGA Polyglycolic acid
PHCH Päijät-Häme Central Hospital
PICO Population, intervention, comparison and outcomes
PLA Polylactic acid
PSI Patient specific implants
QOL Quality of life
SNA Sella-nasion-A point
STL Standard Tessellation language
TPI Treatment priority index
UCLP Unilateral cleft lip and palate
VSP Virtual surgical planning
ZTE Zero echo time

Index

Abstract v

List of abbreviations vii

List of original publications xi

1 Introduction 1

2 Review of the literature 4

2.1 Anatomy and development 4

2.1.1 Anatomy of the bony orbit 4

2.1.2 Development of the face 6

2.1.3 Cleft development and growth 6

2.2 Imaging of the facial skeleton 7

2.2.1 2D imaging 7

2.2.2 3D imaging 8

2.2.2.1 Computed tomography and cone beam computed tomography 8

2.2.2.2 Black bone magnetic resonance imaging 8

2.2.2.3 Zero echo-time MRI 8

2.3 Facial trauma 8

2.3.1 Blow-out fracture 9

2.3.1.1 Assessment of blow-out fractures 9

2.3.1.2 Surgery of blow-out fracture 10

2.3.1.3 Reoperations of blow-out fractures 11

2.3.2 Materials for reconstruction 12

2.3.2.1 Autologous materials 12

2.3.2.2 Allogenic materials 12

2.3.2.3 Alloplastic materials 12

2.3.2.4 Resorbable materials 13

2.3.2.5 Permanent materials 13

2.4 Cleft lip and palate treatment 14

2.4.1 Aim of the treatment of cleft lip and palate 15

2.4.2 Primary surgery 16

2.4.3 Alveolar bone grafting 16

2.4.4 Orthognathic surgery 16
2.4.4.1 Le Fort 1 osteotomy 17
2.4.4.2 Bilateral sagittal split osteotomy 18
2.4.4.3 Complications and risks 18
2.4.4.4 Treatment assessment 19
2.4.4.5 Aesthetics assessment 19
2.5 Novel technologies 20
2.5.1 VSP and CAD/CAM 20
2.5.1.1 Orbital trauma CAD/CAM protocol 21
2.5.1.2 Orthognathic VSP and PSI 23
2.5.2 Intraoperative imaging 25
2.5.3 Augmented reality and navigation 25
2.5.4 Artificial intelligence 25
2.5.5 Automated segmentation 26
2.6 Health Technology Assessment (HTA) 26
2.6.1 Cost of care 27
2.6.2 Cost of care in orthognathic surgery and maxillofacial trauma 27
3 Aims of the studies 29
4 Materials and methods 30
4.1 Population 31
4.1.1 Study I 31
4.1.2 Study II 31
4.1.3 Study III 32
4.1.4 Study IV 32
4.2 Methods 32
4.2.1 Data collection 32
4.2.2 Treatment protocols 32
4.2.3 Volumetric analyses 33
4.2.4 Spatial analyses 33
4.2.5 Cost analysis 34
4.3 Statistics 34
4.4 Ethics 35
5 Results 36
5.1 Study I 37
5.2 Study II 38
5.3 Study III 41
5.4 Study IV 43
6 Discussion 46
6.1 Symmetry and asymmetry of the bony orbits 46

6.2 Volume assessment 46
6.3 The cleft patients and orthognathic surgery 47
6.4 PSI and blow-out fracture reconstruction 49
6.5 The cost of care 49
6.6 Limitations 49
6.7 Future perspectives 50
7 Conclusions 52
Acknowledgements 53
References 55

List of original publications

This thesis is based on the following publications:

I Kormi E, Männistö V, Lusila N, Naukkarinen H, Suojanen J. Accuracy of Patient-Specific Meshes as a Reconstruction of Orbital Floor Blow-Out Fractures. J Craniofac Surg. 2021 Mar-Apr 01;32(2):e116-e119. doi: 10.1097/SCS.0000000000006821. PMID: 33705044.

II Kormi E, Peltola E, Lusila N, Heliövaara A, Leikola J, Suojanen J. Unilateral Cleft Lip and Palate Has Asymmetry of Bony Orbits: A Retrospective Study. J Pers Med. 2023 Jun 29;13(7):1067. doi: 10.3390/jpm13071067. PMID: 37511680; PMCID: PMC10381611.

III Kormi E, Lusila N, Mäntynen P, Männistö V, Suojanen J. Volumetric Assessment of Blow-Out Fractures with Automated Segmentation Benefits Thinner Computed Tomography Slice Thickness: A Retrospective Case-Control Study. J Craniofac Surg. 2026 Apr 13. doi: 10.1097/SCS.0000000000012681. Epub ahead of print. PMID: 41972406.

IV Kormi E, Lusila N, Mäntynen P, Männistö V, Suojanen J. Patient-specific Implants are Accurate and Cost-effective for Blow-out Fracture Reconstruction. A Retrospective Case-Control Study. Submitted.

The publications are referred to in the text by their roman numerals.
These publications have been printed with permission from their copyright holders.
Some additional unpublished material is also presented

1 Introduction

The bony orbits are important for both function and aesthetics of the face. These paired structures are usually symmetric in the normal population, and symmetry assumption is utilized in many new technologies considering the facial skeleton. Radiological development has made it possible to accurately image this area. Three-dimensional (3D) imaging is the foundation for both personalized medicine and emerging technologies developed to facilitate the diagnosis and analysis of the facial structures and for planning maxillofacial surgery operations.

The assessment of novel methods should always be compared to a gold standard. The new method should not be inferior to the standard method and should offer superiority in some aspect, e.g., an easier or faster process, a better outcome, or a lower cost. Sometimes the new method is not comparable to previous ones, and the old standards are not of use. The assessment then requires different settings. Critical assessment of novel technologies is needed, such as whether they can be used to replace the gold standards interchangeably, to facilitate a current process or to create something completely new. Former processes may need re-evaluation or altering according to the findings in the case of a completely new technology.

We need to ask the price even if the novel method provides excellent results. Public health care in Finland is under strict budgetary pressure. Assessing what we gain with the cost is necessary before introducing new technologies to health care. The cost of care is an important factor in the decision to implement or de-implement technologies in ever-expanding health care.

The bony orbital area offers landmarks in planning, symmetry assessment and cephalometric analyses. The complicated anatomy challenges diagnostics and surgery. Orbits are symmetric in a normal population, and symmetry is often the foundation of an assessment or the aim of the treatment. Symmetry is often considered both attractive and functional. Symmetry plays the key role in diagnostics, in virtual surgical planning (VSP) and in postoperative assessment of the treatment results. However, the asymmetry of bony orbits among the unilateral cleft lip and palate (UCLP) population is not a known fact.

VSP may be used to assess the need for surgery, to visualize, or to plan an upcoming operation. Computer-aided design and manufacturing (CAD/CAM) is an extension of VSP for customized anatomical models, cutting guides, wafers, and

patient-specific implants (PSI). PSI in orbital trauma are designed by mirroring the contralateral fractured side to restore its pretraumatic volume and function. 3D fitting and three-point support facilitate unambiguous positioning with the aim of a straight-forward surgery and a stable result.

VSP, in addition to reconstructive trauma surgery, has gained popularity in orthognathic surgery. Orthognathic surgery is often needed to correct skeletal and dental discrepancies in connection with the orthodontic treatment of cleft patients. Orofacial cleft is a common anomaly affecting the development and growth of facial structures. The aim of treatment is both functional and aesthetic outcomes with a harmonious face, good oral function and psychological wellbeing. The cleft patients undergo multiple corrective surgeries, but orthognathic surgery is also often needed. Treatment planning is traditionally based on two-dimensional cephalometric analyses of two-dimensional (2D) radiographs. 3D imaging is a standard today, and the VSP is in wide use to facilitate achieving a balanced outcome. The planning is based on landmarks originating from 2D cephalometrics, with standardized virtual positioning of the skull. The median plane uses *Sella* and paired structures, for example, orbits, and the horizontal plane is positioned parallel to the Frankfort horizontal plane from *Porion* to *Orbitale*. Thus, bony orbits are reference structures, even if surgery is not reaching the orbital area. Facial asymmetry is obvious in a unilateral cleft, and this challenges VSP, because traditional landmarks may be distorted if even orbits are not symmetric.

Clinical features steer and radiological features assist in VSP. The volume in the 3D world is playing a part in assessing orbital symmetry, and novel automated segmentation tools enable fast measurement instead of manual slice-by-slice volumetric calculation. Volume comparison is one factor in orbital trauma for assessing the need for an operation and evaluating whether postoperatively acceptable results are achieved. Asymmetrical volume also cautions to discard traditional landmarks in planning. The volume difference or other radiological measures should always be utilized in all cases, whether trauma or orthognathic, only in connection with meticulous clinical examination.

The focus of this series of studies was to assess novel technologies developed to facilitate diagnostics, planning and treatment of maxillofacial surgery patients, with emphasis on the bony orbit. The studies covered novel technology applications in blow-out fracture and unilateral cleft lip and palate patients. Of trauma, investigation of VSP and PSI of blow-out fracture traumas with the comparisons of planned and achieved results, and the results and costs of PSI compared to standard stock implants to assess whether PSI could be recommended method in reconstruction of fractures of bony orbital floor. Automated segmentation in diagnostics was compared to manual orbital volume measuring in blow-out fracture patients. Of the cleft patients, the symmetry of the bony orbits of unilateral cleft

patients was measured to critically assess whether traditional orbital area landmarks are also applicable in VSP of cleft patients.

2 Review of the literature

2.1 Anatomy and development

2.1.1 Anatomy of the bony orbit

The orbit is a paired bony structure protecting the eye globe and the soft tissues surrounding the eye: muscles, adipose tissue, nerves, blood vessels and lacrimal apparatus. The orbital vault comprises seven bones: The superior rim and most of the roof is frontal bone that also protects the supraorbital nerve canal, the lateral and part of the inferior rim and wall; the lateral floor is zygomatic bone; the rest of the inferior rim and medial and the floor and part of the medial wall are maxilla that also surround the infraorbital canal. Deeper in the conical vault is lacrimal and ethmoidal bone medially and a small area of palatine bone. Sphenoid bone surrounds the superior orbital fissure and optic canal and the postero-lateral side of the inferior orbital fissure, with zygomatic, maxillary, and palatine bone taking part medially around the fissure (Netter 2022) (Picture 1). The volumes of the bony orbit are usually symmetrical (Jeon 2020, Sigron 2024, Kontio 2024). Males have slightly larger volume than females (Shyu 2015, Walker 2022, Kontio 2024, Sigron 2024, Furuta 2001).

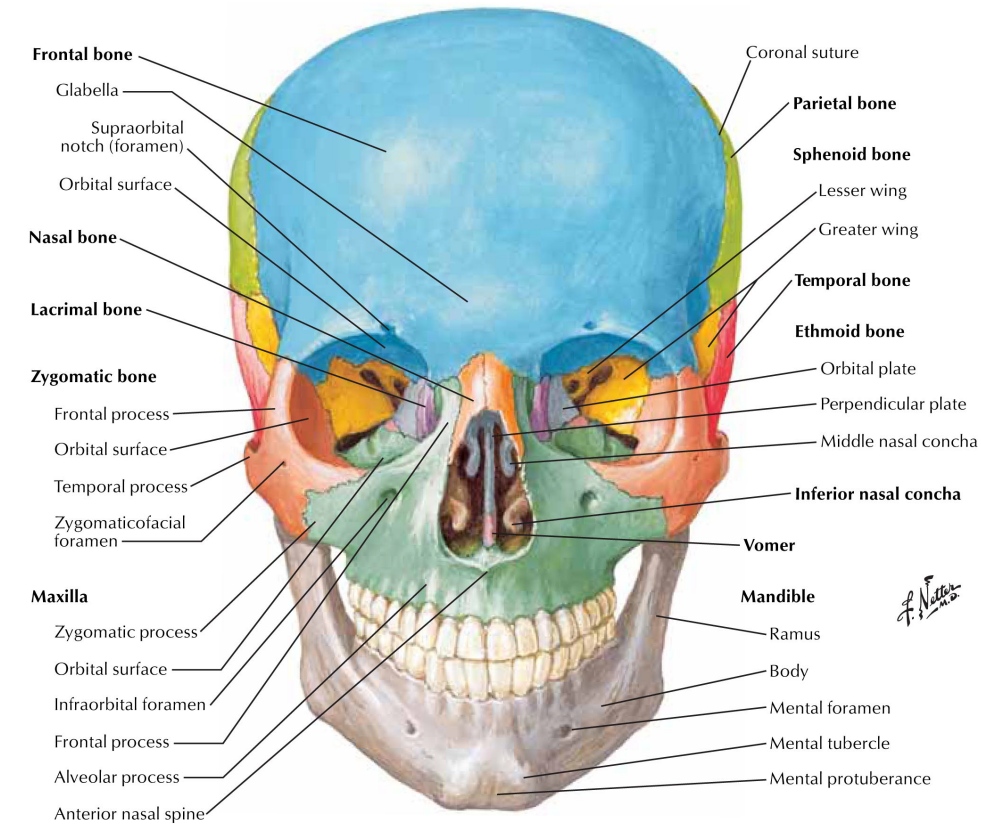

Right orbit: frontal and slightly lateral view

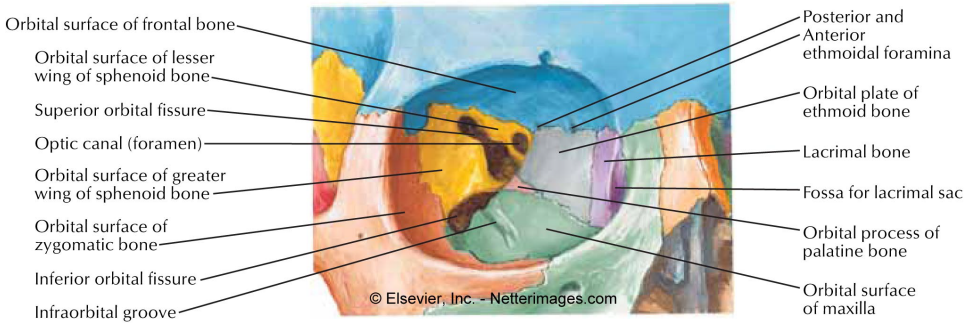

Picture 1 The anatomy of the facial skeleton and bony orbit. Used with permission of Elsevier. All rights reserved. ©Elsevier. Netter illustration used with permission of Elsevier Inc. All rights reserved. www.netterimages.com

2.1.2 Development of the face

Development of the face begins very early in pregnancy. The frontonasal process of ectodermal origin, anteriorly, and maxillary processes of mesenchymal origin, laterally of the stomodeum, enlarge and come closer in week 4. The frontonasal process is responsible for the forehead and the dorsum of the nose and, thus, the upper and medial part of orbital cavities as well. The medial and lateral nasal processes form nasal grooves and further develop the nasal pits on both sides of the frontonasal process. Their floor forms the lateral growth of the medial nasal processes, that are then medially pushed by the maxillary processes during weeks 5 to 6. The maxillary processes are later migrated medially to form the lateral upper lip, and the medial nasal processes the philtrum and medial part and fuse to maxillary processes. Maxillary processes form most of the maxilla and zygoma as well, and thus the inferior and lateral part of orbits. The midline part forms the intermaxillary segment. The intermaxillary segment forms the primary palate in week 6 and later the premaxilla and merges to the lateral palatine processes of the maxillary processes in weeks 8-10. The palatine processes fuse in the midline and form the secondary palate (Som 2013, Som 2014, Bender 2000). The orbital bones ossify between the sixth and seventh months of gestation (Berger 2012).

The face and jaws continue growing after primary development. The growing is functional, and soft tissues, teeth and function direct the volume and direction of the growth. Asymmetrical positioning of the facial muscles diverts the bony growth, and in the mandible, the asymmetry in the glenoid fossa directs the mandibular movement. The cranium, maxilla and mandible interact, and dentition in part compensate for the asymmetries but also affect each other's growth (Poikela 1995, Choi 2019, Hayashi 2023).

The expanding eye globe of the orbital area shapes the orbital vault, and half of the adult size is reached in 2 years of rapid growth in girls, ceasing around 10.9 years of age, and boys in 14.9 (Berger 2012, Furuta 2001). Aging remodels the shape of the orbital aperture, lengthening the oblique distance from the superomedial to the inferolateral rim evident in a Caucasian population (Kahn 2008, Jeon 2020). The orbital vault volume in adults has no or only a slight tendency to increase over the decades, but there are no longitudinal studies considering this (Ching 2020, Jeon 2020, Sigron 2024, Furuta 2001).

2.1.3 Cleft development and growth

Cleft lip and palate are common birth defects and have either a syndromic or non-syndromic background. The etiology is multifactorial, including some discovered environmental factors and risks, e.g., sex, smoking, nutrition, and alcohol (Frederick 2022). Genetic etiology may be sporadic, Mendelian inheritance, or chromosomal. A cleft may be unilateral or bilateral and consists of lip, palate or

both (Babai 2023). The prevalence of cleft lip and palate is 0.45, cleft lip 0.3, and palate 0.33 in 1000 live births (Salari 2022), but it varies in different populations. All congenital malformations have been registered since 1963 in Finland. The incidence of clefts is 1.74 per 1000 live births, of them 0.97 (55.8%) cleft palate and 0.77 (44.2%) cleft lip with or without palate, patients with cleft palate being exceptionally high compared to other countries (Rintala 1982). Boys are more affected than girls by cleft lip and palate, but cleft palate predominates in girls. The left side is more often affected in UCLP (Derijcke 1996, Pool 2021).

The face develops away from the expected course in weeks 4 to 7 of embryonic development in the case of cleft lip, when the maxillary prominence and medial nasal process do not fuse. Intermaxillary prominences fail to merge for the hard palate by week 10 for a cleft palate, and secondary growth centers in the soft palate and uvula by week twelve (Pool 2021).

The cleft also affects the postnatal growth of the face. It is debated whether the cleft itself or the correcting operations and scarring are the main reasons for hindering the postnatal development of the face, resulting not only in creating asymmetry, crossbite and retrognathic maxilla but also in affecting the surrounding facial structures. Non-operated cleft adults present narrower maxillary transversal width, mostly present near the cleft, and some vertical and anteroposterior variation, referring to intrinsic growth deficiency (Latief 2010, Latief 2020, Da Silva 1998). An isolated cleft palate affects midface growth whether operated or not, but non-operated cleft lip and palate patients have more prognathic maxilla compared to operated cleft patients and non-cleft controls in cephalometric analysis (Wlodarczyk 2022). Literature is lacking on the orbital area development in non-operated cleft patients. Clefts usually undergo corrective surgery, at least to some extent, but the variety of different treatment protocols make it difficult to evaluate an iatrogenic impact on development. Asymmetry is present not only near the cleft but also in the mandible (Lin 2015).

2.2 Imaging of the facial skeleton

2.2.1 2D imaging

Two-dimensional cephalograms are conventionally used to measure the facial skeleton and its dimensions. Lateral and antero-posterior cephalograms are used to evaluate asymmetry and the vertical and postero-anterior relationship of dentition and the skeleton in orthodontic analysis and orthognathic surgery planning (Boeddinghaus 2018). 2D imaging was previously used for pre- and postoperative assessment not only of orthognathic surgery but also of trauma. 2D images may reveal the fracture in an orbital trauma but not the pattern or the extent of displacement; thus, it is no longer in routine use for imaging.

2.2.2 3D imaging

2.2.2.1 Computed tomography and cone beam computed tomography

Computed Tomagraphy (CT) is at present readily available, provides high resolution and is considered the gold standard in orbital trauma imaging. Its advantage is visualization of both soft and hard tissue (Winegar 2015), and the imaging area is as wide as needed. The disadvantage is more radiation, longer imaging time, and higher cost than 2D radiographs (Loubele 2006). Computed Cone Beam Tomography (CBCT) can be used for reliable hard tissue imaging (Hatcher 2012). CBCT and CT both work well for orthognathic purposes if CBCT also has a wide enough field. CBCT provides a lower radiation dose, and the imaging data can be reconstructed to thin slice thickness when needed. Newer CBCT technology can also provide whole skull imaging. Low dose and ultra-low dose imaging have further decreased the effective patient dose and are recommended for clinical use (Ihlis 2022, Charuakkra 2023, Koivisto 2024).

2.2.2.2 Black bone magnetic resonance imaging

Traditional magnetic resonance imaging (MR)I provides excellent soft tissue visualization but only indirect bone information (Griffin 2018). Ionizing radiation should especially be avoided in children and if multiple examinations are required. So-called black bone MRI has the advantage of being a nonionizing technique. Soft tissue contrast is minimized to make the bone-soft tissue boundary more visible (Eley 2012). This enables bone to be segmented from the surrounding soft tissues, and this can be used in 3D planning and printing anatomical models, as in CT or CBCT (Eley 2017 1, Eley 2017 2, Vyas 2022). However, MRI is not as readily available and requires longer imaging time, so it is not gaining popularity but should be used in selected cases only, for example, pediatric patients in whom radiation should be limited to a minimum.

2.2.2.3 Zero echo-time MRI

The Zero Echo Time (ZTE) MRI uses very short T2 signals to image bone and can be converted to CT-like images. Maxillofacial trauma is also visible in these images, but this MRI technique is rarely used and is not widely available (Wiesinger 2022).

2.3 Facial trauma

Facial trauma may occur in isolation or with associated injuries (Färkkilä 2024, Huang 2017, Gassner 2003). The trauma and risk factors vary between populations.

Young adults and male patients are usually the most affected along with a lower socioeconomical status also associating with trauma risk (Gassner 2003, Wusiman 2020, Juncar 2021). The other peak in age is seniors, the leading cause usually a fall. Females in this age group are overtaking males (Al-Dajani 2015, Brucoli 2020, Possebon 2017, Werlinger 2019, Gassner 2003). Interpersonal violence is a major problem in younger populations. Males are attacked by strangers, but domestic violence affects females more (Lamberg 1978, Juncar 2021). Other prominent causes are daily life, especially a fall, traffic and sports (Pabbati 2024, Gassner 2003). The leading cause of facial trauma in pediatric patients is play (58.2%), followed by sports (31.8%), traffic (5%) and violence (3.9%) (Gassner 2004).

2.3.1 Blow-out fracture

Of the facial fractures, the orbital area is the most common fracture site comprising nearly one third of the fractures (Pabbati 2024, Gassner 2003). The blow-out fracture is a fracture of the orbital vault's thin bone. The term "blow-out fracture" was introduced by Smith and Regan in 1957. A pure blow-out fracture affects the floor or wall only, and the rims of the orbit remain intact. The older hypothesis describes the force to transmit from the bony structures, usually the orbital rim, to the thinnest part of the bony orbit, making it to buckle (Le Fort 1901). Another hypothesis was later introduced claiming that the fracture originates from a blunt impact on the globe, resulting in a sudden increase in pressure on the orbital vault. The pressure causes the paper-thin orbital floor to give in, thus often saving the soft tissues from serious damage (Pfeiffer 1943). The latter hypothesis gained support decades later from CT scan assessments (Erling 1999). The fractures of the bony orbit may be isolated but are also caused by fractures of the surrounding bones. The fractures of the surrounding bones that may affect the orbital vault are Le Fort II, Le Fort III and zygomatic complex and naso-orbitoethmoid (NOE) fractures, but other fractures of the cranial base and sinuses may also harm the orbital area. Other common associated injuries affect from 20 to 50% of the patients. The most common associated injuries are to the facial soft tissue and teeth as well as cranial, spinal and vascular trauma (Färkkilä 2024, Färkkilä 2023, Mijiti 2014).

2.3.1.1 Assessment of blow-out fractures

Blow-out fractures should be assessed clinically within a few hours of the trauma to rule out indications for emergency surgery, that is, muscle entrapment, retrobulbar hematoma, or oculocardiac reflex. Complications of the optic nerve following retrobulbar hematoma, are compression, stretching of the optic nerve or ischemia due to intraorbital pressure overpowering intraorbital blood pressure, and the duration of the harmful effect is crucial in irreversible vision damage (Gellrich

2002). A clinical examination revealing infraorbital nerve hypoesthesia, subcutaneous emphysema, palpable step-off, soft tissue laceration, open fracture, swelling, asymmetry, and zygomatic bone flattening, and for ocular region subconjunctival hemorrhage, hyphema, diplopia, extra-ocular movement limitation or pain, or globe position and visual acuity alteration should lead to an imaging decision. An absence of these findings opts out imaging, because it also excludes the possibility of midfacial fractures (Rozema 2022). Traumatic edema is the reason for some of the symptoms. Delaying the operation decision until resolution of the edema facilitates not only a clinical assessment but also a surgery (Patel 2022). Ophthalmologist consultation is needed for precise assessment of the vision, globe, and possible associated injuries to it. Progressive and persistent symptoms for two weeks after trauma weights towards surgical intervention, but sometimes the symptoms may develop even later (Rinna 2005). However, surgical guidelines are still under debate, with the nonsurgical approach leading to acceptable results in most cases even in large defects (Young 2018, Jansen 2020). Surgically treated patients have lower quality of life in the long run compared to a nonsurgical treatment group, but severe cases and persistent symptoms usually opt for surgery, which may affect the results (Jansen 2020). High-resolution CT is the gold standard for radiologic imaging. However, clinical symptoms are not always in line with radiological findings for example, retrobulbar hematoma diagnosed in CT rarely leads to emergency surgery (Kondoff 2019).

2.3.1.2 Surgery of blow-out fracture

The aim of blow-out fracture surgery is to regain the globe's function and restore the aesthetics. The primary surgery must be performed without delay in the case of emergency surgery, i.e., symptomatic retrobulbar hematoma, muscle entrapment, or oculocardiac reflex as a sequel of soft tissue entrapment and pressure on the globe. In retrobulbar hematoma leading to orbital compartment syndrome, e.g., stretching or compression of the optical nerve, the pressure must be released, either by enlarging the volume of the bony orbit by fracturing the orbital floor, drainage of the blood through an incision through the eyelid, or canthotomy of the lateral canthal tendon and cantholysis of the inferior crus of the tendon (Park 2021). Releasing the incarcerated muscle is usually all that is necessary in muscle entrapment. This fracture type is common in pediatric patients, due to flexible bone, and the entrapment is not always radiologically visualized, because muscle may be trapped in a closed fracture line of a so-called trap door fracture (Chung 2017).

The timing of the non-emergency surgery is under debate, but resolution of the traumatic edema helps in clinical assessment, because some symptoms may relieve, and decreased swelling simplify, the surgery (Patel 2022). Diplopia and

duction usually shows improvement within 2 weeks, but resolution of the complaints continues after that (Jansen 2020). It may be advisable to proceed to operative treatment in the case of no improvement signs or if a worsening of symptoms occurs after two weeks.

Surgery can be performed via a transconjunctival or transcutaneous lower eyelid approach or transantrally with an endoscope. Transcutaneous options are through a subciliar, subtarsal and infraorbital approach. The subciliar approach is associated with a higher risk of ectropium (Gosau 2010). The transconjunctival approach bears lower risk for complications (Ridgway 2009). Regardless of the chosen approach, the infraorbital rim is accessed, then the orbital floor is further exposed to identify the fracture extent for blow-out fracture reconstruction. The paper-thin bone is replaced with reconstruction material and spanned over the defect. At least a three-point support of the implant is needed for a stable outcome, usually anteriorly and on the posterior ledge. Duction test assessing movement of the globe ensures there is no soft tissue entrapment.

Perioperative navigation or perioperative or postoperative CT imaging verifies the adequate position of the reconstruction material and correction of the volume and shape of the orbit, although routine imaging has been questioned (Carpenter 2018). An optimal implant shape and position leads to volume correction, soft tissue support and reconstruction of anatomical contours of the bone but does not always correlate with postoperative complaints (Jansen 2020).

2.3.1.3 Reoperations of blow-out fractures

The usual reason leading to a decision for revision surgery of blow-out fracture reconstruction is malposition of the implant with clinical symptoms (Schlittler 2018). The implant is too small in many cases and does not provide adequate support to soft tissues. The complication rate is higher in complex fractures, and more reoperations are needed for larger defects and complex fractures (Schlittler 2020). The threshold for repositioning the implant is lower if intraoperative feedback is available, but this naturally lacks information of subjective symptoms (Jansen 2020). Patient specific implants (PSI) compared to preformed stock implants require fewer revisions intraoperatively (26.6% vs. 11%) and postoperatively (13% vs. 0%) (Pietzka 2023). Secondary surgery may occur even after a long time. PSI is recommended for a customized design for revision surgery, and the surgery is considered difficult due to scarring, soft tissue atrophy, need for previous implant removal and lack of usual anatomical landmarks (Schreurs 2022).

2.3.2 Materials for reconstruction

A wide selection of materials is available for orbital floor reconstruction. The materials may be artificial or biological, autologous, allografts or xenografts. These each have different advantages and disadvantages.

2.3.2.1 Autologous materials

Autologous tissues for orbital floor reconstruction may be of bone or cartilage, and even dermis, dura mater and fascia are used. The donor sites for bone are iliac crest, calvarium, rib, maxillary wall, symphysis of the mandible, and coronoid process. Cartilage may be harvested from rib, nasal septum, or ear. The disadvantages of the autologous grafts are donor-site morbidity, which adds to a patient's discomfort, and two operation sites that prolong the operation or bring about the need for two operation teams. Tissue may also be difficult to shape to fit exactly, and resorption is somewhat unpredictable. Of the bone option, cancellous bone is brittle and bulky for the orbital floor, although it revascularizes rapidly, which makes cortical bone a better option for the orbital floor, although it is not easily shaped. Of the cartilage option, and depending on bone donor site, the availability of donor tissue may be limited. Cartilage is also too flexible for large defects and may warp. The advantage is that the tissues are naturally biocompatible and do not elicit host response. The tissue optimally vascularizes and integrates fully, and cartilage may calcify over time. Integration is especially an advantage in pediatric patients, because the graft does not interfere with the growth. Autologous materials are rarely in use anymore because of the disadvantages (Kontio 2009, Mok 2002).

2.3.2.2 Allogenic materials

Allografts used for orbital reconstruction are human dura, fascia lata, lyophilized cartilage, and bank bone. The advantage over autografts is no donor site morbidity, the possibility of preparing the material to the required shape, and availability. The main disadvantage is the risk for infection transmission (Takashima 1997).

2.3.2.3 Alloplastic materials

Alloplastic reconstruction materials can be divided into resorbable materials and permanent materials, and the permanent materials further divided into metallic and non-metallic ones.

2.3.2.4 Resorbable materials

Resorbable biomaterials offer a variety of options and profiles. They are not radio-opaque; thus, intraoperative or postoperative imaging may not be beneficial for evaluating the implant. Bioactive glass is biocompatible but hard and brittle. It is osteoconductive and resorbs slowly (Stoor 2015). Coral hydroxyapatite has some similar properties, serving as an osteoconductive scaffold with some osteoinductive properties (Wahyudi 2025). Different kinds of polylactides have also been used in trauma surgery. Compared to titanium, no need exists for osteosynthesis removal, but this naturally is not an issue in orbital blow-out surgery. Polydioxanone (PDS) deforms quickly and may be adequate for small orbital defects (Baumann 2002), but some claim it is not recommended due to quick softening, because small defects do not need any reconstruction (Kontio 2009). Polylactic acid (PLA) and polyglycolic acid (PGA) may be used alone or as a copolymer, but these reportedly cause an immune response, sometimes persisting for a long time, results are although usually good in blow-out surgery (Suuronen 1993, Young 2017). The benefits of the resorbable materials are evident in pediatric patients, because it does not interfere with the growing anatomy (Schumann 2013). Resorbable polymers may also be 3D printed for customized design (Maintz 2024).

2.3.2.5 Permanent materials

Polyetheretherketone (PEEK) is mechanically strong, easily manufactured and trimmed, but becomes brittle if bent, and causes only mild tissue reactions (Nieminen 2008). It is radiologically translucent and non-magnetic. Its use in maxillofacial surgery is today mainly for onlay implants to correct the contours of facial bones (Järvinen 2019).

Silicone is easy to handle, but the risk for capsule formation and infection even after years postoperatively make it a non-preferred material (Dedhia 2015).
Titanium has been considered the gold standard in blow-out fracture surgery, because it is easily molded, rather biocompatible, does not disturb an MRI and offers better outcomes compared to bone graft (Ellis 2003, Gear 2002). Titanium promotes some fibrosis and may, in that case, interfere with the globe's free motility, and postoperative infection has also been reported. Titanium is available in mesh, preformed plates, screws and PSI (Picture 2). Titanium meshes used for blow-out fracture surgery can be cut, shaped, and molded during surgery as preferred. However, this needs skill and experience and lengthens operation time. Preoperative molding has been also suggested to facilitate the operation, and this can be performed on a generic skull model or a patient-specific 3D model (Singh 2023, Sigron 2020). Preformed orbital plates molded according to generic orbital

vault are also widely available and can be further cut and adjusted to provide needed support to reconstruct the fractured area.

PSI are also often made of titanium, either by milling or laser sintering/additive manufacturing or 3D printing to the preferred shape. The design can be virtually anything needed (Stoor 2014).



Picture 2. Titanium mesh, stock implant and PSI for orbital blow-out reconstruction. Picture Eeva Kormi.

2.4 Cleft lip and palate treatment

Cleft lip and palate (CLP) may lead to difficulties in feeding and to compromised speech, hearing, maxillary growth, facial aesthetics, and, especially in unilateral cleft, symmetry. The defect itself and the burden of care may also cause psychosocial difficulties. People in some remote areas may reach adulthood with unoperated clefts, but it is assumed that this often results in hearing loss due to repeated otitis media and lowers their life expectancy (Latief 2010). The cleft usually requires correction at least to some extent, and several protocols have been proposed (Naidu 2025).

The treatment algorithm for cleft patients varies across countries and hospitals (Naidu 2022, Talmant 2016, Urbanova 2016, Park 2018, Xu 2019). Multicenter consortiums, e.g., Scandcleft, Eurocleft and Americleft, have added to the knowledge regarding different protocols and outcomes (Semb 2017, Shaw 2001,

Long 2011). Consensus has not been reached regarding any protocol's superiority (Naidu 2025). Figure 1 shows the cleft surgery timing in Helsinki University Hospital (HUH).

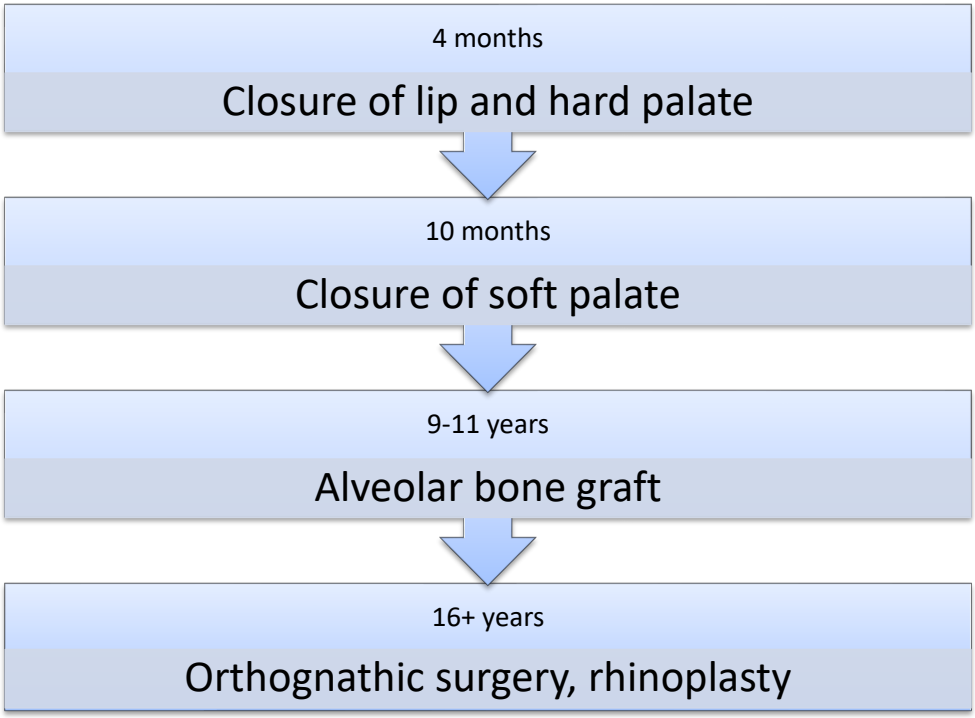

Figure 1. Cleft lip and palate surgery protocol in Helsinki University Hospital Cleft Palate and Craniofacial Centre.

2.4.1 Aim of the treatment of cleft lip and palate

The treatment aims for cleft patients are functional and psychosocial well-being including good speech, hearing, maxillary growth, and symmetrical and aesthetic appearance. Small children's health-related quality of life (QOL) is not affected by cleft, but speech difficulties were causing QOL decrease (Wogelius 2009, Damiano 2007). Surgeries should be kept to a minimum, because more surgeries are associated with lower well-being (Kramer 2008, Broder 2017). Adolescents and adults with CLP or malformation have decreased QOL, and younger adults are affected more (Marcusson 2001, Strauss 2007, Defabianis 2022, Mani 2010). Self-

reported satisfaction with facial appearance was the key element (Oosterkamp 2007). Cleft patients with surgery recommendations also had lower health-related QOL than those without a recommended surgery. However, incremental QOL improvement was reported after surgery. Thus, burden of care should be considered when planning treatment for cleft patients, and the main aim should be normalizing facial appearance to avoid stigmatization.

2.4.2 Primary surgery

Several CLP protocols have been proposed for soft tissue surgery timing. A common protocol is to perform lip and soft palate closure at 3-4 months, and hard palate closure at 12 months, but several variations occur. No statistical difference was found between different protocols in the Scandcleft study, but the possible influence of the learning curve and the surgeon's individual skills were discussed (Semb 2017, Rautio 2017, Heliövaara 2017).

2.4.3 Alveolar bone grafting

Alveolar bone grafting is performed to fill a gap in the alveolar ridge, thus enabling function and aesthetics and making the alveolar ridge complete for teeth alignment and rehabilitation. Timing is usually at 9 to 11 years of age, when the canine is about to erupt (Freihofer 1993). Maxillary growth is usually complete then, and the operation does not affect growth. Autologous bone is usually used, because other materials bear risk for infection, graft failure, eruption failure or immune reactions (McCrary 2021). Mandibular symphysis or the iliac crest are the best options in most cases, with the iliac crest offering more bone and no risk for teeth roots but a different donor site morbidity. The success rate for bone grafting is usually quite high, with poor oral health affecting the outcome (Lundberg 2021).

2.4.4 Orthognathic surgery

The cleft is treated by a multidisciplinary team from birth, but orthognathic surgery is often required to correct a skeletal discrepancy and crossbite. The planning has traditionally been performed with 2D imaging, i.e., cephalograms, panoramic radiographies and anteroposterior x-rays. Retrognathic maxilla may be caused by genetics, the cleft itself, or prior surgeries. Maxilla was found to be orthognathic or prognathic in an untreated cleft lip and palate, probably because of no hindering lip scars and a non-continuous orbicularis oris muscle. However, 2D cephalometric analysis may pose difficulty marking the *Sella-nasion-A point* (SNA) angle correctly, especially in unilateral clefts. An anterior open bite is a consequence of

the upward pull of the cleft and tongue thrust in an unoperated cleft. Maxillary retrognathia is evident in operated clefts (Wlodarczyk 2022).

Le Fort I osteotomy may be sufficient alone if only maxillary hypoplasia is the concern, but for severe cases and asymmetry correction, a bimaxillary osteotomy (bimax) is needed, and Le Fort I is combined with sagittal split osteotomy or vertical ramus osteotomy.

2.4.4.1 Le Fort 1 osteotomy

Le Fort 1 osteotomy is named after a typical maxillary fracture pattern described by Le Fort (Le Fort 1901). This surgery may be utilized for advancement, setback, asymmetry correction, clockwise or counterclockwise rotation and thus occlusal plane correction, or to correct a vertical discrepancy. Its use in orthognathic purposes was already described in 1921 by Wassmund, combined with traction, and later in 1934 by Axhausen, who mobilized the maxilla (Buchanan 2013).

The operation is performed under general anesthesia. The maxilla is approached intraorally with incision through the maxillary vestibular mucoperiosteum. An osteotomy may be performed freehand or with cutting guides. An osteotomy is performed anteriorly from the lateral nasal aperture through anterior wall of maxillary sinuses and zygomatic buttress to the pterygoid plates. Vomer is dissected anteriorly from the nasal septum, or an osteotomy may be performed subspinally leaving the nasal spina untouched to avoid nasal changes. The maxilla is down fractured and fully mobilized. Osteotomies may also be performed segmentally to correct a transversal discrepancy, and the maxilla is cut into two or several pieces. Palatal osteotomies performed from a superior approach leave the palatal mucoperiosteum untouched (Buchanan 2013). The new position is determined by an occlusal wafer and maxillomandibular fixation (MMF) and autorotation of the mandible and fixed with miniplates and monocortical screws. The position is defined with an osteotomy line and PSI positioning marked with a surgical guide if VSP and PSI are utilized, and fixation is performed with PSI and monocortical screws to pre-drilled holes. The VSP and PSI is performing well in Le Fort I osteotomies both in normal population (Suojanen 2017, Kotaniemi 2019) and in cleft patients (Merta 2023).

Patients usually undergo the operation after there no more growth is expected to avoid relapse. An early osteotomy may be a better option for patients with severe cases, with the caution that secondary surgery may be needed after facial growth is completed (Wolford 2008).

2.4.4.2 Bilateral sagittal split osteotomy

Bilateral sagittal split osteotomy (BSSO) was introduced by Obwegeser, and further modified by Dalpont, Hunsuck and Epker (Obwegeser 1954, Obwegeser 1963, Hunsuck 1968, Epker 1977). BSSO is used for mandibular advancement or setback, asymmetry correction or changing the occlusal plane angle.

The operation is performed under general anesthesia. The mandible is approached intraorally, with a mucoperiosteal incision from the anterior ramus to the external oblique ridge. The bone is exposed, and a horizontal osteotomy is performed medially superior to the *lingula*, then along the external oblique ridge and then a vertical osteotomy buccally in the molar area to the inferior border of mandible. The segments are carefully separated to avoid damage to the inferior alveolar nerve. The osteotomy may be performed by freehand, or with surgical guides, if VSP and PSI are utilized. MMF is usually performed with an intermediate or final wafer, according to whether the mandible or maxilla is operated on first. The operation may be performed without the occlusal wafer in case of VSP and PSI, but in BSSO this bears a risk of inaccuracy (Suojanen 2017). The condylar segment is repositioned to the glenoid fossa, and segments are fixed with bicortical screws, miniplates and monocortical screws or PSI and monocortical screws according to plan.

There are no data on the general population that consider the need for orthognathic surgery, probably because it is considered a QOL issue. Some cases may be corrected with orthodontics only, others are considered mainly aesthetic and may be partially corrected with soft tissue surgery, and some have no other option besides orthognathic surgery. The treatment opportunities depend on the health care system. Cleft patients are usually involved in health care, and different health care providers show unilateral cleft patients undergoing orthognathic surgery varying between 15.6–50.4% (Good 2007, Daskalogiannakis 2009, Heliövaara 2011, Voshol 2012, Meazzini 2015, Ore 2017). The treatment choice depends on the preferences and the aim, which is decided by the orthodontist, surgeon, and patient. The treatment in Finland of syndromic and cleft patients is concentrated in two university hospitals, Helsinki and Oulu, and orchestrated there from birth to adulthood by a multidisciplinary team comprising the plastic surgeon, oral and maxillofacial surgeon, orthodontist, prosthodontist, pedodontist, ENT specialist, speech therapist, and specialized nurses. Other medical specialties are consulted when needed.

2.4.4.3 Complications and risks

Orthognathic surgery bears many known risks and complications. In Le Fort 1 surgery, before the PSI era, it was common not to reach the desired results, although intraoperatively facial bony landmarks were used to measure the movements.

Patients are usually informed of changes in appearance beforehand, and the changes are usually considered favorable. The complication rate was 6.4% in a prospective 1000 patients' series, consisting of deviation of the nasal septum (2.6%) and non-union (1.1%), extensive bleeding (1.1%), significant infections (1.1%), ischemic complications (1.0%) and insufficient fixation (0.5%). The risk for complications was higher if extensive movement or transversal segmentation was performed, and with patients with anatomical irregularities, e.g., cleft patients (Kramer 2004). Complications are usually not severe in the Clavien-Dindo classification, PSI and standard implants have a statistically similar complication rate and stability, although standard plates need reoperation more often (Dindo 2004, Suojanen 2018, Kotaniemi 2019).

Inferior alveolar nerve damage is quite common in sagittal split osteotomy, resulting in transient or permanent numbness of the lower lip and alveolar process or in chronic pain. The osteotomy may not follow the planned line during the operation, and bone fractures unfavorably, resulting in a so-called bad split. That lengthens the operation time, may cause suboptimal positioning of the jaw, and may require postoperative maxillo-mandibular fixation. PSI and standard plates do not differ regarding complications, but PSI is not accurate in mandibular osteotomies (Suojanen 2019, Suojanen 2017).

PSI versus screws or standard plates were found to have a higher risk for postoperative complications in syndromic patients, but PSI was rather reliable in Finnish subjects (Kalmar 2020, Merta 2022).

2.4.4.4 Treatment assessment

Finland's public health care is regulated by the Ministry of Social Affairs and Health. The treatment criteria for orthodontic and orthodontic-surgical treatment are based mainly on dental discrepancy. The occlusion is assessed with the treatment priority index (TPI), a 10-step classification. Developing dentition classes 7+ or worse are treated in public health care, and in developed dentition classes 9 and 10, and class 8 if associated with other health issues. TPI for discrepancies related to clefts score 10 in Uniform criteria for access to non-emergency care (STM 2019).

2.4.4.5 Aesthetics assessment

The concept of aesthetics is difficult to define. Beauty standards vary from culture to culture and from time to time (Singer 2024). Today it is evident that social media play an important role in influencing beauty standards and, thus, patients' expectations (Rahman 2024). This is parallel to finding that a perception of attractiveness recalibrates with recent experiences (Jones 2008).

Symmetry is usually set as a goal for orthognathic surgery and is considered attractive. Facial asymmetry may be dynamic or static, function influencing perception. Nasal tip and chin asymmetry can be perceived nearly similarly by laymen and professionals, but nasal asymmetry was rated significantly more asymmetric, and, interestingly, left/right bias exists (Meyer-Marcotty 2011). Of the face, eyelid positioning is most sensitive to revealing asymmetry, a 2 mm difference being obvious to most observers (Hohman 2013). According to psychological studies, the most appealing face is average. Averageness or facial normality seem, interestingly, more important to attractiveness than symmetry, and symmetry only adds to this (Zheng 2021). This is more evident in females (Komori 2009).

2.5 Novel technologies

Widespread and accurate 3D imaging has been crucial for developing novel technologies in maxillofacial surgery, reliable. These technologies emerged to further assist in challenging cases preoperatively, intraoperatively and postoperatively.
Adaptations of advanced 3D technologies in maxillofacial surgery may be divided into diagnostics, VSP, CAD/CAM, virtually assisted surgery, and evaluation. This division is rather arbitrary, because these technologies overlap and the terms are used interchangeably. VSP covers image analysis, and surgical and outcome simulation. CAD/CAM means 3D-modelling and manufacturing custom models, guides, splints and implants. Virtually assisted surgery refers usually to navigation, intraoperative imaging and augmented reality. Artificial intelligence (AI) and automation in planning, identification, diagnostics and segmentation are also emerging technologies (Sabelis 2022).

2.5.1 VSP and CAD/CAM

Bony structures are essential in maxillofacial surgery, and CT or CBCT are usually used for imaging. A thinner slice thickness provides better quality and fitting, so it is recommended to have 1 mm or less slice thickness and 0 degrees gantry tilt to prevent distortion (Li 2023).

The radiologic data are converted to Digital Imaging and Communications in Medicine (DICOM) data and uploaded via secure transfer to the company, or if performed in-house, to the program used for VSP. The data are processed to a standard tessellation language (STL) file and further prepared, e.g., bones are segmented virtually, dental models are fused to radiologic images, or images of the contralateral side are mirrored. Segmentation may be automated (Sillman 2025).

A simple way to utilize 3D planning is to have individual 3D skull model printed. Preoperative molding of a titanium mesh or porous polyethylene implant on an anatomical 3D model of the patient facilitates surgery for orbital fractures by reducing operation time (Singh 2023, Pang 2018). The disadvantage is that preoperative molding is time consuming, needs skill, and lacks the advantage of virtual mirroring, overcorrection and visualization. Thus, PSI provides an even better outcome.

In interactive VSP, usually in cooperation with an engineer or technician and a clinician, the patient's current anatomy and areas of interest are revised and the segments are moved to a planned position. The intact side is used as a reference in trauma cases and mirrored to reconstruct the affected area, or the fragments are moved virtually to their original positions. Guides for cutting, drilling, and positioning are planned virtually. The custom medical hardware for surgery is designed and manufactured according to the plan.

PSI fabrication may be subtractive or additive. Subtractive fabrication is milling, and limitations for medical use are the size of the prefabricated material block, and the milling machinery may have restrictions for intricate designs. Additive fabrication means laser sintering or other additive layering, depending on the material and the product. This can even be performed in-house, because 3D printers are widely available. PSIs in maxillofacial surgery are usually made of titanium or PEEK, the guides may be titanium or plastic, and the models and wafers are plastic.

2.5.1.1 Orbital trauma CAD/CAM protocol

VSP for orbital reconstruction (Figure 2) utilizes orbital symmetry (Sabelis 2022, Sigron 2024). The protocol is not usually utilized in growing patients, because resorbable material is preferred. This method is especially recommended for complicated blow-out fractures and revision surgery (Holmes 2021, Schreurs 2022). Two-part implants are proposed for complicated cases with large defects or when more than one wall is affected, because the insertion without harming surrounding soft tissues may be difficult for larger implants (Holmes 2021).

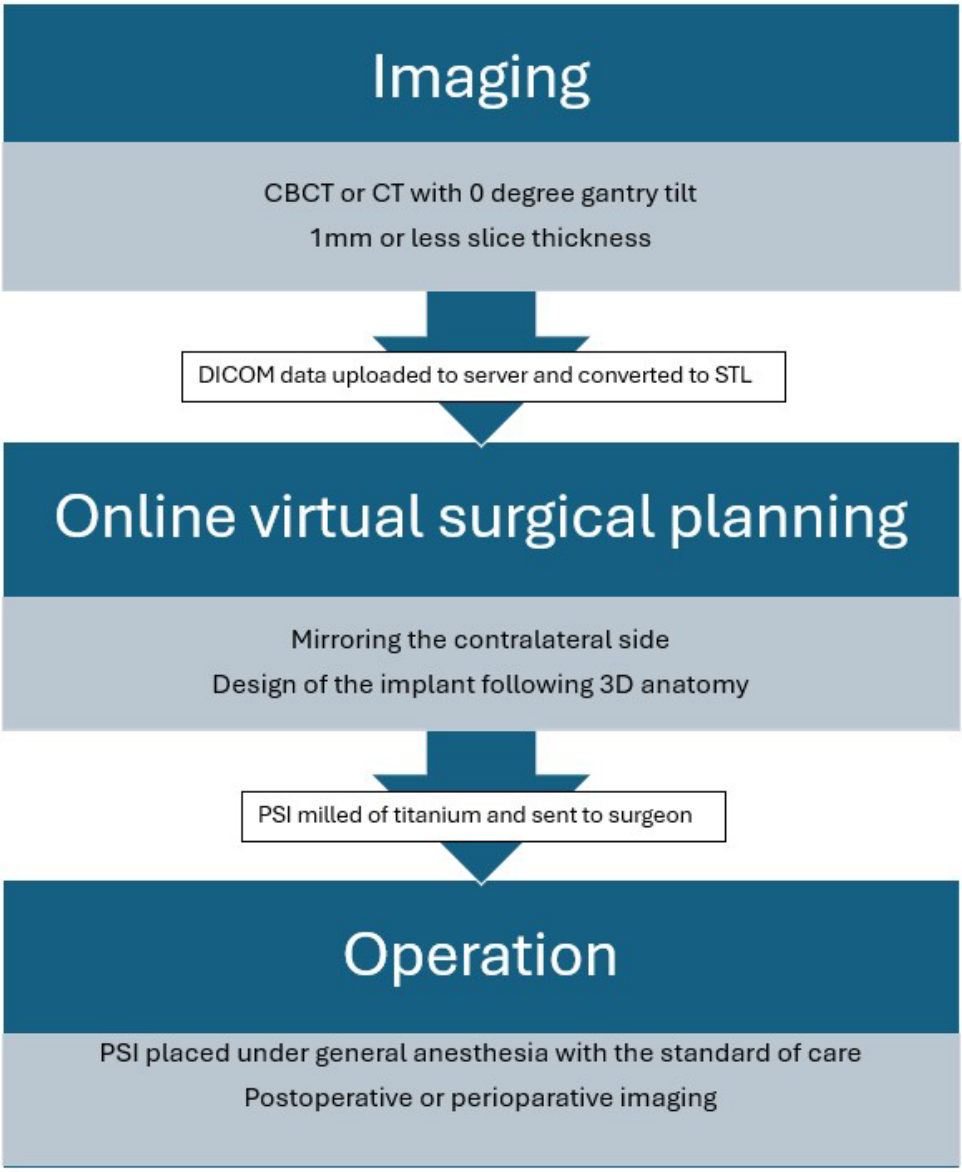

Figure 2. Blow-out fracture PSI workflow.

2.5.1.2 Orthognathic VSP and PSI

Skull positioning is crucial in orthognathic surgery VSP. The mid- sagittal plane is usually set according to paired structures, for example orbits (Swennen 2006). This cannot be trusted in asymmetrical faces, and several methods have been proposed. Some utilize traditional landmarks, usually Frankfort horizontal, porions, or orbits, and some utilize a more complex semiautomated or automated analysis of cephalometric or morphometric analysis (Ajmera 2024).

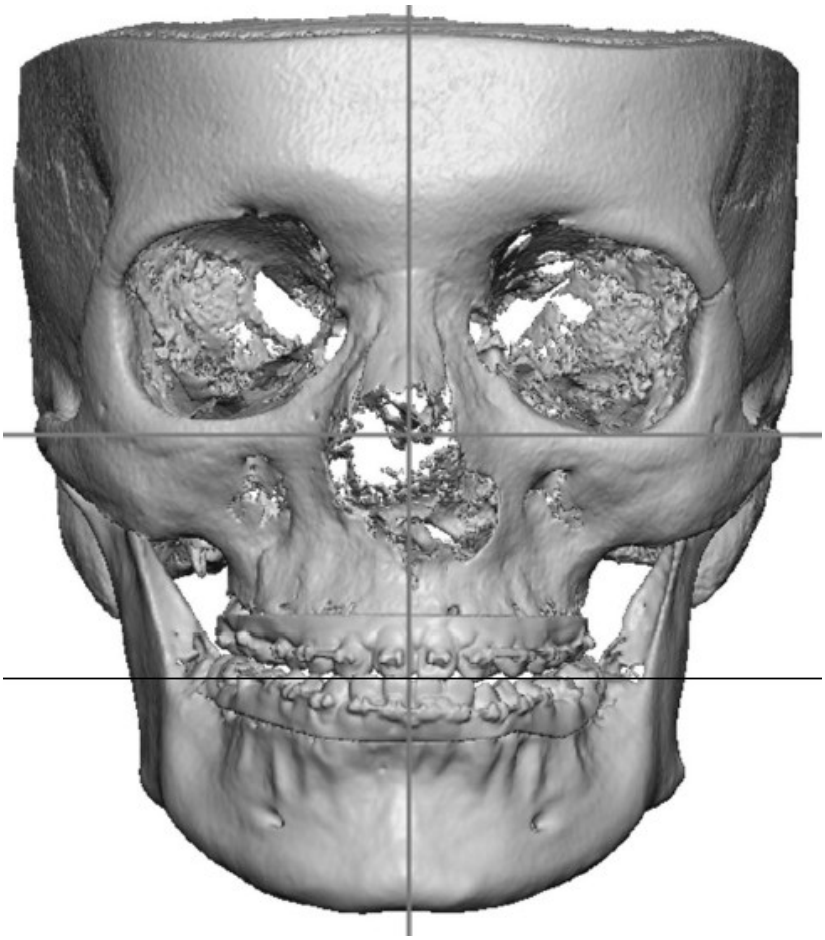

Picture 3 Preoperative three-dimensional computed tomography of unilateral cleft lip and palate patient for virtual surgical planning.

VSP and PSI provide accurate results compared to preoperative planning for orthognathic surgery in normal populations, in Le Fort I osteotomies, (Suojanen 2016, Kraeima 2016, Järvinen 2021). Waferless surgery compared to traditional

surgery is more accurate and benefits stand out in bigger movements (Kraeima 2020). The PSI is equally stable and does not bear a higher risk for postoperative complications (Kotaniemi 2019, Van der Wel 2023). The method also provides precise results in Le Fort 1 osteotomies of cleft patients, but restricted maxillary movement due to extensive scarring and large advancement may exclude the possibility of utilizing PSI in the surgery (Merta 2022). The PSI is not as accurate in BSSO and may need additional adjusting but bears no higher risk for postoperative infection (Suojanen 2017, Suojanen 2019). Schwartz 2014).

VSP and the utilization of CAD/CAM wafers only do not have the same accuracy as customized guides and osteosynthesis implants and, thus, cannot be recommended (Sanchez-Jauregui 2022). PSI follows the VSP better than the wafer only in segmental Le Fort 1 osteotomies (Kuehle 2023).

VSP and PSI provide not only accuracy but a shorter (or at least similar) operation time for orthognathic surgery compared to traditional surgery (Schneider 2019,

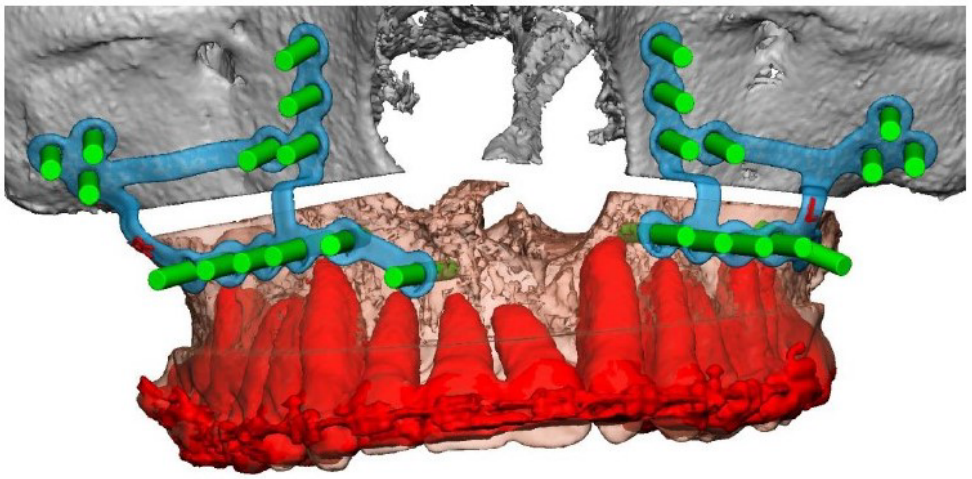

Picture 4 VSP for Le Fort I osteotomy of a unilateral cleft patient. Dental models fused into STL image; teeth segmented to visualize root positions. Osteotomy lines marked and segments moved to desired position with the guidance of the target occlusion (not shown). PSI designed and screw positions planned.

2.5.2 Intraoperative imaging

Intraoperative imaging enables immediate revision of the implant if its position is deemed to be inadequate (Jansen 2020). The threshold for revision is low if no separate operation is needed; up to 50% of implants are repositioned if intraoperative imaging was utilized (Blumer 2015, Borad 2017, Jansen 2020). Merging intraoperative images with preoperative planning is also possible. Intraoperative imaging is more precise if radio-opaque reconstruction material is used. Evaluation of the implant position intraoperatively and immediate correction reduce the later revision surgeries, but radiological findings do not correlate with clinical symptoms, and revision may not have been necessary in the first place (Blumer 2015).

2.5.3 Augmented reality and navigation

Navigation is used to facilitate surgery. The preoperative 3D image is fused to the patient's real-life anatomy with fiducial markers, or dental models are fused to a 3D image, and a dental splint is used for reference (Schreurs 2021). Optical or electromagnetic tracking gives haptic or visual guidance. Navigation can be used with customized or stock implants or to track the movement of the bony segments. Compared to other emerging technologies in orthognathic surgery, the results of navigation are not as good as with VSP and CAD/CAM guides and PSI that provide 0.39mm accuracy (Heufelder 2017), the navigation fitting accuracy being 0.5-1.52mm, which should not be accepted as adequate (Suojanen 2017, Naujokat 2017). The use of navigation in trauma surgery facilitates accurate implant positioning in orbital blow-out fractures (Cai 2012, Zong 2021). Intraoperative imaging similarly enables verifying and possible intraoperative repositioning, but navigation gives simultaneous feedback without additional radiation. Augmented reality similarly provides dynamic feedback, either visual or haptic, to facilitate a planned surgery (Sabelis 2020).

2.5.4 Artificial intelligence

The term artificial intelligence (AI) is used to describe data processing, which is traditionally thought to need humans, e.g., learning, decision making and problem solving. Of artificial learning, machine learning (ML) uses predesigned features and is supervised but capable of learning over time. Its subcategory, deep learning (DL), is based on artificial neural networks and is non-supervised. It learns from hidden layers of a multilayered network and is self-learning, creating output based not only on input but also on self-learning, subtle and complex interconnections (Patel 2023). Convolutional neural networks are utilized in radiological use, or radiomics,

to process data or automate segmentation, classification, diagnosis, treatment planning, or detection (Leite 2020). Limitations of the system are the possible input bias, the available data and the testing accuracy (Tampu 2022, Kermany 2018).

2.5.5 Automated segmentation

The term automated segmentation is not used consistently in the literature. Sometimes semi-automated and automated segmentation refers to a similar protocol, and sometimes automated segmentation is used to mean an AI-based method and not a program using prescribed threshold values or image processing protocols. Automated segmentation generally refers to technology used to automate identification and virtual separation of different tissues or contours or segments in medical imaging and, thus, to make the process faster and less dependent on observer preferences or experience (Sillman 2025, Deng 2023).

The automated segmentation in our studies uses Hounsfield units (HU) to differentiate contours and separate tissues in CT. The technology is introduced to assess the orbital vault's volume and the fracture's size (Hsung 2017). It is assessed to be reliable and repeatable but not comparable to freehand volume measuring (Chepurnyi 2020). The difference from manual segmentation may be because of different interpretations of the orbit's anterior opening, because the rim is not in a level but a more saddle-like in contour or hyperbolic paraboloid, as Osaki described (Osaki 2013). Because of the conical shape, the anterior part adds to volume more than the posterior part.

2.6 Health Technology Assessment (HTA)

New innovations emerge with accelerating speed in health care. The new innovations may add to the cost of health care, which is already taking a great share of gross domestic product (GDP). The total health expenditure in Finland for both public and private health care was 9.7% of GDB or 5676 international dollars per capita in 2022, scoring 16th among Organization for Economic Co-operation and Development (OECD) countries (OECD 2024). HTA is widely known widely by health care professionals in Finland for the nationally published Current Care Guidelines (Current Care Guidelines 2024). The Choosing Wisely initiative between 2012 to 2023 spread worldwide with many opt-out recommendations and even de-implementation of interventions, also sparking recommendations in Finland (Sipilä 2019, Choosing Wisely 2023).

Evaluating new innovations should be a routine practice for all health care professionals. Old habits die hard, and new innovations should offer better outcomes, a simpler process, or a lower cost of care, the latter without compromising the former. Current care, or the gold standard, is always the base line

to which the novel technologies should be compared, and the outcome should not be inferior to this.

2.6.1 Cost of care

Cost of care can be assessed in various ways depending on what is considered in the evaluation. A full evaluation comprises two or more alternatives — cost data and consequence data — but partial analysis may also be useful. Public health care procurements in Finland are to be tendered if exceeding a certain amount of money, and this has an influence on cost data. Bidding usually considers both quality and cost.

Cost-minimization analysis may be sufficient when evaluating the cost of care if comparing two or more alternatives with similar outcomes, but if different outcomes must be considered, a cost-effectiveness or incremental cost-effectiveness analysis is to be performed to assess whether added cost means added health in certain procedures. A cost-utility analysis is useful when comparing different diseases, for example, utility being measured as QOL (Robison 1993 1, Kumar 2006).

The Choosing Wisely initiative focuses on anticipated improvement in or reduction of the QOL itself, but it should be noted that this has an economical aspect as well (Choosing Wisely 2023, Levinson 2018). Overdiagnostics or overtreatment do not benefit patients and are costly (Sipilä 2019). A cost-benefit analysis uses money as an outcome measure (Kumar 2006). The treatment outcome in clinical care is usually the main interest, but if different options are found to be equivalent in the clinical results, the cost-minimization analysis is useful (Robinson 2 1993).

The operating theater comprises approximately 35-40% of hospital costs (Healey 2015). The operating theater is also the most expensive part of the surgical treatments, and optimization of the operating time is the key to control expenses (Healey 2015). The total operating cost comprises the routine cost of usual equipment, routine staff, anesthesia and overhead, and the patient-specific costs of non-routine equipment, drugs and staff. The operating time is cost intensive; from an economical viewpoint, non-routine aspects, such as new technologies' incremental costs, can be balanced with shorter operating times or reductions in the number of revision surgeries.

2.6.2 Cost of care in orthognathic surgery and maxillofacial trauma

The operating theater often assumes the greatest share of the costs of treating maxillofacial trauma; prosthodontic reconstruction is another expensive part of

the care in some cases. The time-consuming orthodontic care in orthognathic surgery skews the costs more to outpatient care, but the operation is still the biggest expense. Thus, the operating theatre time is the crux of the matter in evaluating expenses.

PSI shortens operating time of maxillofacial trauma in mandibular fractures, and for orbital trauma, the preoperative bending of the titanium mesh on the 3D model shortened the surgery time significantly. Those costs were not calculated, although a lower cost is implied (Taalab 2023, Singh 2023, Pang 2018).

VSP has been adopted widely in orthognathic surgery. The cost of the traditional planning, including 2D cephalometric analysis, model surgery and manual wafer fabrication, was more costly and time consuming than VSP and 3D printing of the wafers the vendor provided. This cost analysis also included salaries, fringe costs and the overhead for the staff involved, but PSI was not used, and the operating time was not calculated (Resnick 2016). Another study claims a shorter operating time but similar costs using different methods (Schneider 2019). Oral and maxillofacial surgeons were, interestingly, unaware of the actual costs of VSP and PSI, although they used the novel technologies in daily practice (Goodson 2021).

3 Aims of the studies

The aim of the thesis was to evaluate the use of virtual surgical planning (VSP), patient specific implants (PSI) and automated segmentation in the context of the bony orbit. The specific study aims were the following:

I. To assess the accuracy of PSI in blow-out fractures with postoperative reconstruction compared to a planned position in VSP.

II. To investigate asymmetry of the bony orbits in unilateral cleft lip and palate patients.

III. To assess and validate automated segmentation in a volumetric assessment of blow-out fractures.

IV. To evaluate the cost-effectiveness and orbital volume correction in reconstruction of blow-out fractures with PSI versus stock implants.

4 Materials and methods

Table 1 summarizes population, intervention, comparison, and outcome (PICO) of the Studies I to IV.

Table 1 PICO summary of the study questions in Studies I to IV.

	Study I	**Study II**	**Study III**	**Study IV**
Population	Blow-out fracture patients	Unilateral cleft lip and palate patients	Blow-out fracture patients	Blow-out fracture patients
Intervention/area of interest	PSI reconstruction	Symmetry and position of the orbits	Automated segmentation	PSI reconstruction
Comparison	Preoperative VSP	Non-cleft maxillary hypoplasia patients	Manual segmentation	Titanium stock implant reconstruction
Outcomes	Position of the PSI compared to VSP	Asymmetry of the bony orbits	Orbital volume measuring, repeatability, and reliability, CT slice thickness	Operation duration, postoperative orbital volume, reoperations, cost-effectiveness

4.1 Population

The Study I population consisted of blow-out fracture patients reconstructed with patient specific implants (PSI). The Study II the population was non-syndromic unilateral cleft lip and palate (UCLP) patients with VSP for orthognathic purposes, and comparative group was non-cleft maxillary hypoplasia patients with virtual surgical planning (VSP). Study III comprised patients diagnosed with a unilateral blow-out fracture and Study IV's patients had blow-out fracture reconstruction with either PSI or a stock implant.

4.1.1 Study I

Study I's study population comprised a 1-year cohort of blow-out fracture patients with PSI reconstruction in Päijät-Häme Central Hospital (PHCH). Of these 8 patients, 4 were female and 4 male. The average age was 39 years with a range of 17 to 61 years. The patients' operations were performed in 2019. The operation was planned with 3D virtual planning and fractures were reconstructed with PSI (Planmeca Promodel, Planmeca Ltd, Helsinki, Finland). Computed Tomography (CT) with 0 degrees gantry tilt and 1mm or less slice thickness is utilized for PSI (GE Revolution CT, Siemens SOMATOM Definition AS+).

4.1.2 Study II

Study II's study population comprised 15 UCLP patients from the Cleft Palate and Craniofacial Centre (CPCC), Department of Plastic Surgery, Helsinki University Hospital (HUH), and for comparison group, 16 non-cleft Class 3 patients from PHCH. Of the UCLP patients, 8 were male and 7 female: Five were to undergo a bimaxillary osteotomy and 10 the Le Fort 1 osteotomy. These different osteotomies were used as subgroups for further analysis. The average age was 18.82 years with a range from 12 years 5 months to 27 years 8 months. The patients were scheduled for preoperative VSP by the end of 2021. CT or Computed Cone Beam Tomography (CBCT) with 1mm or less slice thickness and 0-degree gantry tilt was also taken in this study. The orbital volume was measured with automated segmentation tool (CMF Orbital Software, Disior Ltd., Helsinki, Finland) in cleft patients, and linear measurements were made manually (Syngo software, Siemens Healthineers, Erlangen, Germany). Measuring was performed with manual segmentation in the non-cleft group, and linear measurements were also performed manually (GE HealthCare AW Server software, Chicago, Illinois, USA).

4.1.3 Study III

Study III's population was 34 patients surgically treated for orbital blow-out fractures in PHCH from 2008 to 2020. The inclusion criteria were pre- and postoperative CT or CBCT taken from both orbits with imaging of the whole orbital vault to enable volumetric analysis. Of the 34 patients, 13 were female and 21 male, with an average age of 45,0 years with a range from 16.1 to 89.4 years. The population was, in part, the same as Study IV's.

4.1.4 Study IV

Study IV's population comprised 49 surgically treated blow-out fracture patients presented in PHCH from 2008 to 2020. Of this cohort, 36 were reconstructed with stock implants and 13 with PSI. In all, 17 patients were female and 32 male. The average age was 42.7 years, with a range from 16.1 to 89.4 years.

4.2 Methods

4.2.1 Data collection

Data for all studies were collected from patient archives in the Excel application (Microsoft Co., Redmond, WA, USA), from which it was moved to the statistics software SPSS (IBM®, Armonk, NY, USA) for statistical analysis.

4.2.2 Treatment protocols

CT or CBCT of the patients was taken for all Studies I-IV. The imaging was taken for VSP purposes in Studies I and II. The imaging protocol for VSP was high quality CT or CBCT with 0-degree gantry tilt and slice thickness of 1mm or less. Study III imaging was for diagnostics. In Studies III and IV, for orbital volume analysis, all patients with preoperative and postoperative CT or CBCT were enrolled regardless of imaging's slice thickness.

VSP and CAD/CAM were utilized for Studies I and IV. Imaging data were anonymized, and DICOM data were uploaded to a commercial partner. CT was processed to a standard tessellation language (STL) file. Studies I and IV blow-out fracture reconstruction mirrored contralateral intact orbit on the fractured side. Virtual interactive planning was conducted online in collaboration with surgeons and an engineer. The implant was designed to fit passively in order to reconstruct the fractured bony orbit. 3D contouring following the bony shape and three-point support, with two extensions anteriorly over the inferior orbital rim and a third extension on the posterior ledge, were utilized to prevent tilting and to facilitate

unambiguous positioning. The PSI was manufactured of milled titanium in computer assisted manufacturing (CAM).

4.2.3 Volumetric analyses

An automated segmentation tool was utilized for the volumetric measurements in Studies II, III, and IV (CMF Orbital Software, Disior Ltd, Helsinki, Finland). Using this tool, the DICOM data of CT is transferred to the software, a radiologist chooses one seed point inside the orbital vault, and a virtual triangle mesh starts expanding until it meets the orbit's bony walls (recognition based on Hounsfield units [HU]) and the anterior orbital rims. Limits for expansion are formed perpendicularly from the fragment to the fractured rim in the case of a fracture.

This method was used In Study II's cleft patients to avoid observer-related bias, because the cleft side was obvious in the radiographs. Automated segmentation does not allow any alterations once the seed point is chosen, and the seed point location does not affect the measurements.

The contours of the bony orbit were defined and confirmed slice by slice in Study II for the control group of non-cleft patients and in Study III for manual segmentation. 3D segmentation was then made by interpolation, and the volume was measured. GE HealthCare AW Server software was used for the analysis.

4.2.4 Spatial analyses

The postoperative CT was transferred to 3D software for Study I to analyze the PSI position (Romexis, Planmeca Ltd, Helsinki, Finland). Using the same HU value determined preoperatively for VSP, the bony surface was defined and converted to an STL file. The preoperative and postoperative skull models were then matched using the unchanged anatomical areas. PSI was extracted from postoperative CT based on a higher HU, and the STL model was imported into the preoperative virtual plan using transformation from the registration of the skull models. There were some artifacts due to metal in the postoperative CTs, causing some inaccuracies in implant shape. Thus, some adjustments were made manually. Anterolateral, anteromedial, and posterior reference points were placed on preoperatively designed PSI, and a new copy of this was superimposed according to the postoperative CT of the implant position. The copy was manually placed into the very middle of this thicker postoperative image to reduce error because of metal artifacts in postoperative CT. The shortest distance of the reference points was then computed.

The orbital area was assessed with volumetric and linear measurements for Study II. For linear measurements, the width and height were measured from the most anterior coronal slice to fully show the orbital rim. The depth was assessed as

the distance from the fronto-zygomatic suture to the optic canal. For position we used the distance from the craniolateral border of the infraorbital canal opening to the inner postero-caudal wall of the *Sella turcica*, measured from the oblique sagittal plane. For Helsinki University Hospital patients, Helsinki University Hospital radiologist workstations and Syngo software (Siemens Healthineers, Erlangen, Germany) were used for the analysis according to the manufacturer's instructions for quantitative analysis. For PHCH patients, PHCH radiologist workstations and GE HealthCare AW Server software (Chicago, Illinois, USA) were used according to the manufacturers' instructions for quantitative analysis.

4.2.5 Cost analysis

The difference in cost of the care in PSI or stock implants was calculated for Study IV based on implants price, operation time drawn from the patient registry, general and specialty specific costs per operation, hospital ward days and expenses, imaging and reoperation costs. The average cost of the operating theatre per minute and other economic data were obtained from the hospital controller.

4.3 Statistics

The statistical analyses for Studies II to IV are summarized in Table 2.

Table 2 Summary of the statistics used in Studies I to IV.

	Study I	***Study II***	***Study III***	***Study IV***
Statistics	Descriptive and visual analysis, mean, range (position of the implant)	Two-tailed paired *t*-test (sides) Mann–Whitney U-test (osteotomy type) Cohen's Kappa (Intrarater reliability)	Interclass correlation coefficients (interrater reliability) Intraclass correlation coefficients (repeatability) Mann-Whitney test (volume)	Mann-Whitney test (volume difference, days and operation time) Two-sided chi-square test (reoperations)

Study I is descriptive and mean and range were calculated with Excel (Microsoft co., Redmond, WA, USA).

The statistical analysis for Studies II to IV was made with SPSS software (IBM®, Armonk, NY, USA), except for Study III that utilized NCSS statistical software (Utah, USA) to calculate the interclass correlation coefficients for interrater reliability, and intraclass correlation coefficients for intrarater reliability. Statistical significance was set to p=0.05 in Studies II to IV (* indicating statistical significance). The Shapiro-Wilks test was utilized to assess distribution of data in continuous variables. We used parametric tests if the test showed no evidence of non-normality; otherwise, non-parametric tests were used.

The cleft side was compared to the intact side in Study II to assess asymmetry; the normal right and left side were compared with two-tailed T-test for the maxillary hypoplasia population. We used the Mann-Whitney U-test for further analysis of different osteotomy types. Cohen's Kappa was utilized for intrarater reliability.

We used the Mann-Whitney U-test for volume analysis in Study III. We measured interrater reliability with interclass correlation coefficients to assess different methods. Intrarater repeatability was analyzed with intraclass correlation coefficients.

The Mann-Whitney test was used in Study IV for the volume difference, ward days and the operation time; the two-sided X^2 was used for the reoperation rate.

4.4 Ethics

All the studies were retrospective. The study protocols of PHCH were approved by Päijät-Häme Central Hospital (Permission D/18/07.01.04.05/2018 and D/2929/07.01.04.05/2020). The study protocol of patients in CPCC, HUH was approved by Helsinki University Hospital (HUS/234/2020). The research adhered to the principles outlined in the Declaration of Helsinki.

5 Results

The results of the Studies I to IV are summarized in Table 3.

Table 3 Summary of the results in Studies I to IV

	Study I	***Study II***	***Study III***	***Study IV***
Results	PSI follows virtually planned position in blow-out fracture reconstruction	Asymmetry extends to the orbital level in UCLP patients, position of the orbit and volume are different Class III non-cleft population has no asymmetry	Automated segmentation is a reliable and repeatable method for orbital volume assessment especially in CT slices of 1mm or less, but does not provide same results as manual segmentation	Total cost of PSI is lower compared to stock implants in blow-out fractures, and PSI has better volume correction and no reoperations
Conclusions	VSP and PSI are reliable methods in blow-out fracture reconstruction	Asymmetry must be considered in VSP, and traditional landmarks cannot be trusted in UCLP	Thin CT slices should be used for automated segmentation, and it is a reliable and repeatable method	PSI reconstruction is superior in volume correction and cost-effective for blow-out fracture reconstruction

5.1 Study I

Eight patients, 4 of them female, with orbital blow-out fracture reconstruction were analyzed to assess the spatial fitting of PSI compared to VSP and postoperative volume correction compared to the contralateral side.

Table 4 Age and sex of each patient.

Patient	***Sex***	***Age (years)***
1	*F*	*48*
2	*F*	*52*
3	*M*	*24*
4	*M*	*19*
5	*F*	*34*
6	*F*	*17*
7	*M*	*56*
8	*M*	*61*
	(4 females, 4 males)	*Mean 38.9*
		Range 17-61

Study I's results show good spatial accuracy in achieved position compared to planned position for VSP and PSI in orbital blow-out fracture surgery. The mean difference was 1.5 mm (0.4–4.0 mm) in the anterolateral reference point, 1.3 mm (0.4–2.4 mm) in the anteromedial reference point, and 1.8 mm (0.4–4.8 mm) in the cranial reference point. Table 5 shows the details of the spatial measurements.

Table 5 Postoperative versus planned position of the PSI.

Patient	***Difference***	***(mm)***	
	Lateral	*Medial*	*Posterior*
1	*0.6*	*0.7*	*0.5*
2	*4*	*0.5*	*4.8*
3	*1.3*	*1.4*	*0.7*
4	*2.2*	*2.4*	*3.2*
5	*0.5*	*1*	*1.3*
6	*0.4*	*0.4*	*0.4*
7	*2.6*	*2.4*	*0.6*
8	*0.5*	*1.6*	*2.9*
Mean	*1.5*	*1.3*	*1.8*
Range	*0.4-4.0*	*0.4-2.4*	*0.4-4.8*

Preoperative mean orbital volume was 26.86 cm^3 (21.09–31.77 cm3) on the fractured side and 24.11 cm3 (19.69–28.08 cm3) on the not-fractured side. Postoperative orbital volume was 23.78 cm3 (19.36–27.81 cm3) on the fractured side and 24.21 cm3 (20.28–27.33 cm3) on the contralateral side. Postoperative volume of the bony orbit was slightly smaller than contralaterally (Table 6).

Table 6 The orbital volumes in cm3 preoperatively and postoperatively

Patient	***Fractured***			***Contralateral***		
	Pre (cm3)	***Post (cm3)***	***Difference***	***Pre (cm3)***	***Post (cm3)***	***Difference***
1	28	26.53	-1.47	26.95	26.82	-0.13
2	31.77	27.81	-3.96	28.08	27.33	-0.75
3	26.09	23.84	-2.25	24.68	24.69	0.01
4	26.47	24.41	-2.06	23.44	24.2	0.76
5	22.58	19.79	-2.79	21.25	20.79	-0.46
6	21.09	19.36	-1.73	19.69	20.28	0.59
7	28.72	23.61	-5.11	24.38	24.14	-0.24
8	30.12	24.85	-5.27	24.43	25.44	1.01
Mean	26.86	23.78	-3.08	24.11	24.21	0.09875
Range	21.09–31.77	19.36-27.81		19.69–28.08	20.28-27.33	

5.2 Study II

Study II included 15 non-syndromic UCLP patients with preoperative CT for VSP in the Cleft Palate and Craniofacial Centre, Department of Plastic Surgery, Helsinki University Hospital. The comparison group had 16 non-cleft Class II maxillary hypoplasia patients. The side of the cleft was left in 11 and right in 4 patients, and 10 were to undergo Le Fort 1 osteotomy and 5 bimax. Table 7 presents UCLP patient characteristics.

Table 7 Patient characteristics of UCLP patients.

Age	***Sex***	***Cleft side***	***Ocular pathology***	***Osteotomy***	***Previous operations***
20y 7mo	M	Left	No	Le Fort 1	Primary lip repair and soft palate closure 4mo. Hard palate closure 11mo. Alveolar bone graft 9y 6mo.
18y 3mo	M	Right	Myopia Astigmatism	Bimax	Primary lip repair 3mo and soft palate closure 3mo. Hard palate closure 9mo. Alveolar bone graft 11y 2mo.
18y 10mo	M	Left	No	Le Fort 1	Primary lip repair 4mo. One-stage palatal closure 11mo. VPI surgery (Furlow Z-plasty) 6y 7mo. Alveolar bone graft 10y 10mo. Early Le Fort 1 osteotomy 14y 4mo.
20y 7mo	M	Left	No	Bimax	Primary lip repair and soft palate closure 4mo. Hard palate closure 11 mo. Secondary lip repair 6y 9mo. Secondary lip repair and rhinoplasty 11y 9mo. Alveolar bone graft 11y 7mo.
13y 4mo	F	Left	No	Le Fort 1	Primary lip repair 3mo. One-stage palatal closure 1y 2mo. Alveolar bone graft and fistula closure 9y 2mo.
12y 5mo	F	Left	No	Le Fort 1	Primary lip repair 4mo. One-stage palatal closure 8mo. Fistula closure 5y 4mo. Alveolar bone graft 9y 3mo.
16y 2mo	F	Left	No	Le Fort 1	Primary lip repair 3mo. One-stage palatal closure 1y. Previous operations abroad, no specific data. Alveolar bone graft 10y 8mo. Early Le Fort 1 osteotomy 13y 3mo.
16y 2mo	F	Left	No	Le Fort 1	Primary lip repair and palatal closure around 1y. Previous operations abroad, no specific data. Alveolar bone grafts 9y 2mo and 10y 2mo. Fistula closure 11y 3mo.

Age	*Sex*	*Cleft side*	*Ocular pathology*	*Osteotomy*	*Previous operations*
27y 8mo	F	Left	No	Bimax	Primary lip repair 3mo. One-stage palatal closure 9mo. Secondary lip repair 8y 9mo. Alveolar bone graft 9y 1mo. Rhinoplasty 17y 7mo.
18y 2mo	F	Right	No	Le Fort 1	Primary lip repair and soft palate closure 3mo. Hard palate closure 8mo. VPI surgery (muscular repair of soft palate) 7y 2 mo. Alveolar bone graft 16y 7mo.
18y 10mo	M	Left	No	Le Fort 1	Primary lip repair and soft palate closure 3mo. Hard palate closure 1y. Fistula closure 5y 6mo. Alveolar bone graft 9y 4mo.
21y 6mo	M	Left	No	Bimax	Primary lip repair 3mo. One-stage palatal closure 9mo. VPI-surgery (pharyngeal flap, Hogan) 5y 6mo. Alveolar bone graft 9y 5mo.
24y 3mo	M	Right	No	Le Fort 1	Primary lip repair 3mo. One-stage palatal closure 10 mo. Alveolar bone graft 10y 3mo.
16y 8mo	F	Left	No	Bimax	Primary lip repair 7mo. One-stage palatal closure 1y 1mo. Alveolar bone graft 11y 7mo.
18y 10mo	M	Right	No	Le Fort 1	Primary lip repair 3mo. One-stage palatal closure 1y. Alveolar bone graft 10y 1mo.
Mean 18.82y	*8M, 7F*	*11 left, 4 right*		*10 Le Fort 1; 5 Bimax*	

The aim was to assess laterality of the bony orbits in UCLP patients. Volume, spatial and linear measurements of the orbits showed minor but constant asymmetry in the cleft side, with statistical significance in the orbit position assessed as distance from the *Sella turcica* to the infraorbital canal on the left side, the orbit being more medio-posterior (p= 0,012), and orbital volume, measuring smaller than that of unaffected contralateral side (p=0,013). As a comparison we

had the same measurements in non-cleft Class III maxillary hypoplasia patients planned for orthognathic surgery. The differences between the orbits were non-significant in the control group (Table 8).

Table 8 Radiological measurements and comparisons of the cleft side and contralateral side of the unilateral cleft lip and palate patients and left and right side of the non-cleft Class III patients.

	N	*Cleft side*	*Contra lateral*	*Difference*	*95 % CI*		*DF*	*p*	
					Lower	*Upper*			
Height, cm	n=14	3.793	3.793	0	-0.0751	0.0751	13	1.00	NS
Width, cm	n=14	3.300	3.343	-0.0429	-0.0970	0.0113	13	0.111	NS
Depth, cm	n=15	4.520	4.567	-0.0467	-0.1326	0.0393	14	0.264	NS
Position, cm	n=15	6.660	6.888	-0.1733	-0.3129	-0.0338	14	0.019	*
Volume, mm3	n=12	25596.825	26433.167	-836.3417	-1464.8051	-207.8782	11	0.014	*
	N	*Right side*	*Left*	*Difference*	*95 % CI*		*DF*	*p*	
					Lower	*Upper*			
Height, cm	n=14	3.836	3.867	-0.0214	0.09	0.0472	13	0.512	NS
Width, cm	n=15	3.49333	3.507	-0.0113	-0.0545	-0.0545	14	0.499	NS
Depth, cm	n=16	4.919	4.875	0.0438	-0.0177	0.1052	15	0.15	NS
Position, cm	n=16	7.19375	7.169	0.025	-0.0465	0.0965	15	0.468	NS
Volume, mm3	n=14	24591.429	24448	143.571	-78.928	366.071	13	0.187	NS

The asymmetry of the UCLP patients' orbits was even more evident in patients undergoing bimax versus Le Fort I osteotomy of the orbit's position (p=0.040) but not in other measurements, including orbital volume. However, the choice between bimax or Le Fort I osteotomy considers several factors besides skeletal discrepancies; thus, the treatment method may reflect more clinicians' or patients' preferences than anatomical landmarks.

5.3 Study III

Study III validates the automated segmentation tool for orbital volume assessment, measuring both fractured and intact orbits of 34 patients preoperatively and postoperatively.

The automated process provides excellent intra-rater repeatability (ICC= 0.92) and manual segmentation by an experienced radiologist ICC=0.83).

A novel finding is that slice thickness affects the results of the automated segmentation. The intact orbits examined with the same CT slice thickness preoperatively and postoperatively were compared in two groups, with a cutting point of 2 mm. 2 mm or more provides less accuracy compared to 1 mm or less slice thickness in repeatability between pre- and postoperative imaging (p=0.0288) (Table 9).

Table 9 Computed tomography slice thickness and repeatability of automated segmentation

Slice thickness	***Median difference***	***CI***	
		Lower	***Upper***
1mm or less	-0.1465	-0.513	-0.0172
2mm or more	0.7285	0.003	1.056
	p=0.0288*		

We used interrater reliability (AC_1) to compare automated segmentation to manual segmentation by an experienced radiologist. Both automated and manual segmentation are repeatable methods, although different methods give different results. The correlation of automated segmentation and manual segmentation was moderate in both intact (AC_1 0.57) and fractured orbits (AC_1 0.50), in preoperative and intact (AC_1 0.41) and fractured (AC_1 0.67) in postoperative orbits (Table 10). The difference is clinically relevant, automated segmentation providing 12.4 to 16.3 % larger median volumes.

Table 10 Inter-rater correlation in manual versus automated segmentation and median volumes (cm3).

Group	*AC_1*	*CI*	*Manual*	*Automated*	*Difference*
Preoperative intact	0.57	0.32 – 0.75	24.68	28.697	4.017
Postoperative intact	0.5	0.20 – 0.71	24.26	28.11	3.85
Preoperative trauma	0.41	0.11 – 0.64	27.3	30.68	3.38
Postoperative trauma	0.67	0.44 – 0.82	23.61	26.822	3.212

5.4 Study IV

Study IV consisted of 49 patients suffering from a blow-out fracture. The study employs PSI for orbital blow-out reconstruction and compares it to a stock implant. The volume correction was better with PSI, using the intact contralateral side as a reference, the stock implant showing 9.65 % difference compared to 4.09 % of PSI (p=0.001).

A better clinical outcome was not achieved with higher cost, although a PSI itself is more expensive. The cost of the PSI during the study period was 917.60 € and for stock implants the average was 653.62 €. Mainly due to the shorter operation time, the PSI method is cost-effective. The operation theater cost per minute was estimated to 38 €. The stock implants needed an average of 122.69 min and PSI 89.77 min operation time, totaling 32.92 min less in favor of PSI.

Table 11 Operation total cost in each group.

	PSI (n=12)	***Time***	***Stock (n=36)***	***Time***	***p***
Operation cost (38 € per min)	4328.86		5315.84		
Operation time (minutes)		89.77		122.69	0.008*
Implant (€)	917.6		653.62		
Other specialty-specific materials and laboratory (€ per operation)	619		619		
General materials (€ per operation)	260		260		
Hospital ward and laboratory cost (844 € per day)	1233.54		1027.33		
Hospital ward (days)		1.46		1.28	0.603 NS
Imaging (107 € per CT)	214		214		
Reoperation risk cost			698.42		
Total cost (€)	7573		8788.15		

Four reoperations (11.1 %) in the stock implant group compared to none in the PSI group is not statistically significant, although the finding is clinically relevant, and the cost of the reoperation (6292,11 € in this study) adds to total cost of patients treated with stock implants.

Table 12 Reoperation total cost per patient, n=4.

Operation cost (38 € per min)	3676.5
Implant (2 PSI, 2 stock)	785.61
Other specialty specific materials (per operation)	619
General materials (per operation)	260
Hospital ward (844 € per day)	844
Imaging (107 € per CT)	107
Total cost (€)	6292.11

6 Discussion

6.1 Symmetry and asymmetry of the bony orbits

The symmetry of the non-affected bony orbits in normal populations is the fundament of this series of studies for this thesis. The exact assessment of symmetry is possible only because of the development of 3D imaging. Computed Tomography (CT) is the gold standard in imaging of the bony orbit, because the anatomy is complicated and delicate (Shao 2025). The symmetry is proven in several studies and populations (Kontio 2024, Sigron 2024, Walker 2022, Shyu 2015, Ji 2010, Furuta 2001, Forbes 1985). The aim of facial bone surgery is to restore or gain the function and aesthetics. The symmetry usually goes hand-in-hand with these. Thus, laterality is a finding of interest in trauma or congenital deformity, whether in diagnostics, surgery planning or evaluation, and this is utilized in all Studies I-IV.

6.2 Volume assessment

The orbital area image interpretation is rather time consuming when performed by a radiologist and is prone to individual interpretations of the data. Study III compared orbital volume measuring with manual and automated segmentation in both intact and fractured bony orbits to streamline the process. The orbital vault volume measures in the study were repeatable with automated segmentation, which reflects an earlier trauma study (Chepurnyi 2021). This also parallels findings confirmed in non-traumatic populations even in both bone and soft tissue windows (Sigron 2024).

The main finding of CT slice thickness affecting the results is not presented in the earlier literature. The slice thickness of 1mm or less is recommended in the PSI protocol, but the origin for this claim was not found (Li 2023). Manual segmentation of the orbit by an experienced radiologist was also proven reliable and repeatable, but the automated results are not similar. The manual segmentation is also prone to individual interpretations of the anatomical features; thus. automated segmentation should be preferred for consistent results in cases of repeated measures, several radiologists, irregular anatomy or study purposes, because the segmentation is fully automated and error due to individual interpretations is omitted. This was furthered in unilateral cleft patients' orbit analysis in Study II to

omit diagnosis error in volume assessment of this unusual anatomy, because the cleft side could not be blinded from the observing radiologist.

6.3 The cleft patients and orthognathic surgery

The asymmetry of the orbits of the unilateral clefts was evident in Study II. facial asymmetry is quite a common feature among Class III non-cleft patients, usually Menton point deviating from the sagittal midline (Li 2024). We had Class III patients of non-cleft background undergoing orthognathic treatment as a comparison group, and the finding of orbital symmetry among them in contrast to the cleft patients strengthens the results. This orbital asymmetry of unilateral cleft patients is a new finding not previously reported in the literature. Otherwise, the asymmetry is especially obvious around the cleft (Lin 2015) but may also reach the cranium and skull base (Hayashi 2023). A smaller volume and posterior position of the orbit on the cleft side was a constant although minor feature. Picture 5 shows preoperative CT scans of two UCLP patients showing asymmetry of facial skeleton.

VSP in orthognathic surgery was introduced 20 years ago (Swennen 2006, Swennen 2009, Li 2013, Philippe 2013, Mazzoni 2015). Orthognathic patients are more likely to be satisfied with the decision to undergo surgery and the outcome if VSP is applied (Bueno 2023). However, according to Study II, some widely used VSP protocols (Swennen 2006) employ landmarks, which are not symmetrical in cleft patients. Some of the landmarks are inherited from a treatment planning protocol based on 2D imaging. 3D CBCT provides more accurate landmarking than cephalograms in cleft patients (Kochhar 2021). Considering the overall asymmetry, to assess, e.g., the need of roll in occlusal cant, *orbitale* should not be used in UCLP patients, but the symmetry should be verified in other ways. This may challenge automated skull positioning and should be considered in VSP in cleft patients.

The soft tissue compensation should not be leaned on either, because soft tissues usually follow the hard tissue asymmetry (Li 2024). The soft tissue response calculation in orthognathic treatment is also still quite unpredictable (Philip 2023, Singh 2024). This is even more evident in cleft patients, because sequelae from previous operations affect the movement of the facial soft tissues.

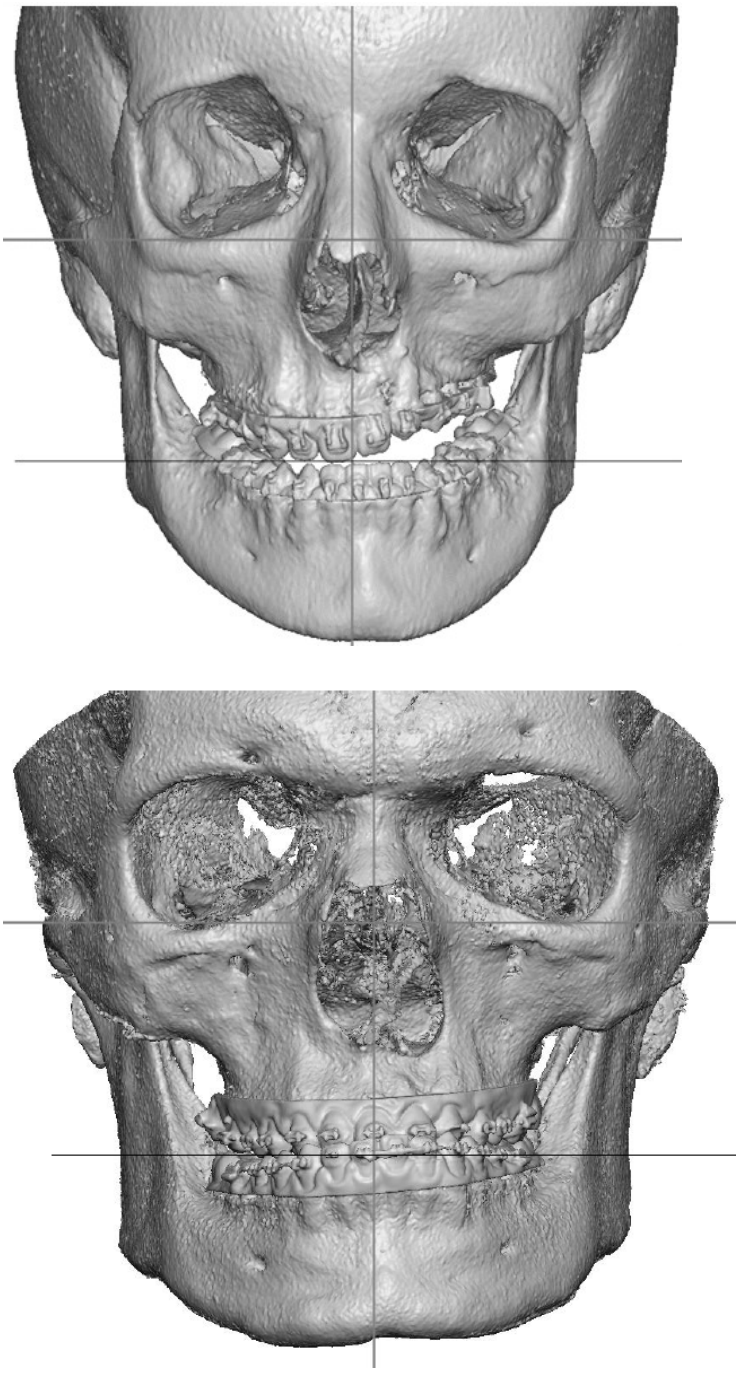

Picture 5 Preoperative computed tomography scans of two unilateral cleft lip and palate patients showing asymmetry on different levels of facial skeleton.

6.4 PSI and blow-out fracture reconstruction

Studies I and IV show that a PSI provides exact positioning and better volume correction than stock implants in blow-out fracture reconstruction. The PSI in orbital floor reconstruction is currently in wide use with the studies supporting its use. The favorite application of a printed titanium PSI is the orbital floor (89%) in Britain (Goodson 2021 I). Of the cost of VSP and PSI, the surgeons don't know the actual expense and predict that to be higher (Goodson 2021 II). The PSI orbital reconstruction has been assessed cost-effective in the Study IV, and this is mainly due to shorter operation time. The predictable next step in cost minimization is in-house VSP and PSI (Au 2023).

6.5 The cost of care

The operating theater is costly, already estimated between 22 to 133 dollars per minute in the USA in 2005, excluding surgeon or anesthesiologist fees or special supplies (Tan 2008, Shippert 2005). Orbital surgery operation time was significantly shorter in a study considering implants bent on a custom 3D model compared to intraoperative adjustment (Sigron 2020) This supports the shift towards preoperative planning or manufacturing to minimize surgery time. Similar results concerning knee arthroplasty with PSI, navigation or stock supports the PSI approach (Watters 2011). The shorter operation time combined with no revisions is parallel to a study confirming a 14 % increase in complications per every 30-minute increase in anesthesia time (Cheng 2018). Thus, the operation time minimization is a benefit not only economically but should also be every surgeon's aim.

6.6 Limitations

The limitation of this series of studies is that it was retrospective; thus, not all factors could be controlled, and the data are not as comprehensive as a prospective study. For example, some radiographs were missing or inadequate for analysis.

The one-year Study I cohort provided preliminary results only because of the small study population. It provides good visual information with superimposition and the maximum deviations of chosen points, but the fitting on the anatomical landmarks was not assessed, because only the planned and achieved position was in focus.

Selection bias exists among Study II's non-syndromic UCLP patients, because not all the cleft patients are taken for CT or CBCT. Thus, the inclusion criteria were for the subjects aimed at orthognathic surgery, who may be those with the most difficult asymmetry. Other surgical protocols of the cleft patients may also

affect their growth differently. The results are thus not to be generalized to all cleft patients and all hospitals. The measurements between the groups are not comparable due to the different imaging and measuring protocols, but they show the cleft affecting asymmetry not evident in the control group. This is still a large series considering the highly specific group of patients, and a comparison to a non-cleft population strengthens the results.

Study III did not take the CT for study purposes, and the imaging protocols differed, making the data heterogenous. However, this variation of the imaging protocols provided valuable sources for the effect of slice thickness on automated segmentation.

Considering the cost-effectiveness, the retrospective nature of Study IV limits the available data. A prospective study could take more factors into account. The stock implants were used in earlier years of this cohort, and the gradual shift to use VSP and PSI was due to positive clinical experiences and availability. Thus, the groups compared may not be fully similar, although the cohort comprises consecutive patients. An ophthalmologic check-up on blow-out fracture patients was not a routine protocol, resulting in limited information about ocular trauma and the patients' recovery process; for example, diplopia and astigmatism data are missing. The PSI and stock implant prices are subject to changes, due, for example, to competitive procurement in public health care; the costs vary in different providers and countries as well. The range of operation theater expenses is wide across different hospitals and countries. The results are to be generalized with caution for other circumstances, and Study IV's main purpose is merely to bear in mind that we need a wide, comprehensive way of thinking for expenses. The other expenses concerning patient care, e.g., outpatient follow-up controls or sick leave, would strengthen the results, but these may be more affected by other features of the patient, and due to variation would need a large cohort to statistically control this.

6.7 Future perspectives

3D imaging and automated segmentation is redefining diagnostics and anatomy landmarking in maxillofacial surgery. Technology validation needs evaluation in even specific patient groups like cleft patients. For example, up to which level the asymmetry is evident it is still to be investigated in cleft patients. The impact of these findings on VSP and clinical work for surgery is to be considered in a prospective study. AI is learning from the available data, and inclusive databases are key to producing trustworthy results.

The PSI is becoming the gold standard in blow-out fracture surgery. Available planning programs and more affordable 3D printers shift the field towards in-house protocols. This may reduce the cost and enable a swift CAD/CAM

process. However, this leads to fragmented know-how, because the field is no longer in the hands of a few vendors but in individual surgeons' hands. The liability aspects are also to be discussed, and the regulatory development should stay abreast of this.

Health care is constantly expanding with new possibilities. Limiting expenses has become more crucial. The future of prospective studies is to cover not only novel innovations' quality and benefits from the viewpoint of the patient and provider but also the cost-effectiveness from the viewpoint of the payer and society. Knowledgeable patients and demanding cases are building up the field for personalized medicine. Expenses may hinder the use of individualized options, but the whole process must be considered to avoid partial optimization and swollen overall expenses. The trend of technology development is leaning toward AI based methods to make this an affordable option.

7 Conclusions

I. Patient-specific implants (PSI) follow virtual surgical planning (VSP) position accurately in blow-out surgery.

II. Unilateral cleft patients have asymmetry in orbital position and volume.

III. Automated segmentation benefits from thinner CT slices and is a repeatable and reliable method in orbital trauma volume measuring. It should not be used interchangeably with manual measures.

IV. PSI in blow-out surgery is cost-effective due to shorter operation times and fewer reoperations and provides better volume correction than stock implants.

Acknowledgements

This thesis project was a long journey. It was carried out at Päijät-Häme Central Hospital and at the Cleft Palate and Craniofacial Center, Helsinki University Hospital, and University of Helsinki, Finland. I gratefully acknowledge the financial support from Eemil Aaltonen Foundation, Päivikki and Sakari Sohlberg Foundation, University of Helsinki research funds, Finnish Dental Society Apollonia and VTR Research funding. This thesis would have been impossible without numerous professionals, colleagues, co-workers, friends and my family. I want to thank you all.

I owe my greatest gratitude to my supervisors, Professor Junnu Leikola and Associate Professor Juho Suojanen. After I tumbled and fumbled around in different projects, you reassured me about accomplishing this thesis and supported me throughout. You made it easier to navigate even when I was not sure of my goal. Junnu, thank you for your guidance. I appreciate your expertise and your straightforward attitude. Juho, thank you for pushing me forward, answering my endless questions and helping me with all the challenges. I appreciate your witty remarks and surprisingly patient attitude.

I sincerely thank Professor Virve Koljonen for guiding me through the process and acting as the custos. Your experience and advice were invaluable.

I thank Associate Professor Daniel Nowinski, it was a great honor to have you as my opponent.

The reviewers, Associate Professor Pertti Patinen and Professor Roman Khonsari, I thank for your invaluable effort. Your comments made this thesis a lot better.

I express my gratitude to my co-authors who have contributed to my academic development. The article considering clefts taught me many new things and most importantly, revived my urge for scientific work. It was great to work with a team of excellent professionals. My special thanks go to Arja Heliövaara: The article would have been impossible without your meticulous work. I also thank Elina Peltola for radiological work. The maxillofacial trauma studies in Päijät-Häme Central Hospital evolved from fracture management. I thank the co-authors: Niilo Lusila for your patience with the surgeons and your radiological expertise in these

studies as well, Hanna Naukkarinen for clarifying the engineering, Ville Männistö for your ideas through the process, and Pilvi Mäntynen for your part.

My sincere thanks to wonderful colleagues I have met during my journey: Karri Mesimäki, Patricia Stoor and Tommy Wilkman. I know whom to call when I get lost in surgery.

A big thank-you to all my co-workers, present and previous, in Päijät-Häme Central Hospital. It is a privilege to work with such a skillful, motivated and fun team. Even when hitting turbulence, it is good to know I can take your support for granted. Special thanks I owe to Kati Kiiliäinen for managing the circus under whatever circumstances. I also thank Minna Merta and Esa Färkkilä for your peer support, which has made the thesis project easier to carry on.

My friends have lived my journey with me. Reetta, Immi and Tuuli, thanks for your support during life's ups and downs. Kirsi, I really appreciate our friendship and your knowledge of maxillofacial surgery education, thank you. Some of my friends I meet once a year, some of you I share my life by everyday messaging. You are all important.

My parents have been of great help in bringing up the kids when I have immersed myself in this project. It would have been impossible to manage all this without you. Thank you.

Juho, our lives intertwine in so many ways. Professionally, I would not be here without you as my copilot. Scientifically, your support is immeasurable. As a friend, you know me better than anyone. The life is better with you by my side. Thanks for being you.

Last, I want to thank my children Armi and Asta. Together we walk in sunshine and through the storms. You are my life.

It really has been quite a journey.

Helsinki, June 2026

Eeva Kormi

References

Ahn HB, Ryu WY, Yoo KW, Park WC, Rho SH, Lee JH, Choi SS. Prediction of enophthalmos by computer-based volume measurement of orbital fractures in a Korean population. Ophthalmic Plast Reconstr Surg. 2008 Jan-Feb;24(1):36-9. doi: 10.1097/IOP.0b013e31815eb7ce. PMID: 18209638

Al-Dajani M, Quiñonez C, Macpherson AK, Clokie C, Azarpazhooh A. Epidemiology of maxillofacial injuries in Ontario, Canada. J Oral Maxillofac Surg. 2015 Apr;73(4):693.e1-9. doi: 10.1016/j.joms.2014.12.001. Epub 2014 Dec 27. PMID: 25661507.

Andrews BT, Jackson AS, Nazir N, Hromas A, Sokol JA, Thurston TE. Orbit fractures: Identifying patient factors indicating high risk for ocular and periocular injury. Laryngoscope. 2016 Feb;126 Suppl 4:S5-11. doi: 10.1002/lary.25805. Epub 2015 Dec 22. PMID: 26690301.

Andriola FO, Haas Junior OL, Guijarro-Martínez R, Hernández-Alfaro F, Oliveira RB, Pagnoncelli RM, Swennen GR. Computed tomography imaging superimposition protocols to assess outcomes in orthognathic surgery: a systematic review with comprehensive recommendations. Dentomaxillofac Radiol. 2022 Mar 1;51(3):20210340. doi: 10.1259/dmfr.20210340. Epub 2021 Sep 14. PMID: 34520241; PMCID: PMC8925870.

Andriola FO, Weinberg Y, Grosjean L, Pagnoncelli RM, Pottel L, Swennen GRJ. Mandibular autorotation: a critical virtual parameter in clinical decision-making regarding maxilla-first versus mandible-first sequence. Int J Oral Maxillofac Surg. 2024 Aug;53(8):698-706. doi: 10.1016/j.ijom.2024.01.010. Epub 2024 Feb 12. PMID: 38350796.

Au SW, Li DTS, Su YX, Leung YY. Accuracy of self-designed 3D-printed patient-specific surgical guides and fixation plates for advancement genioplasty. Int J Comput Dent. 2022 Nov 25;25(4):369-376. doi: 10.3290/j.ijcd.b2599791. PMID: 35072416.

Ayoub A, Pulijala Y. The application of virtual reality and augmented reality in Oral & Maxillofacial Surgery. BMC Oral Health. 2019 Nov 8;19(1):238. doi: 10.1186/s12903-019-0937-8. PMID: 31703708; PMCID: PMC6839223.

Babai A, Irving M. Orofacial Clefts: Genetics of Cleft Lip and Palate. Genes (Basel). 2023 Aug 9;14(8):1603. doi: 10.3390/genes14081603. PMID: 37628654; PMCID: PMC10454293.

Berger AJ, Kahn D. Growth and development of the orbit. Oral Maxillofac Surg Clin North Am. 2012 Nov;24(4):545-55. doi: 10.1016/j.coms.2012.08.001. PMID: 23107427.

Boeddinghaus R, Whyte A. Trends in maxillofacial imaging. Clin Radiol. 2018 Jan;73(1):4-18. doi: 10.1016/j.crad.2017.02.015. Epub 2017 Mar 21. PMID: 28341434.

Broder HL, Wilson-Genderson M, Sischo L. Oral health-related quality of life in youth receiving cleft-related surgery: self-report and proxy ratings. Qual Life Res. 2017 Apr;26(4):859-867. doi: 10.1007/s11136-016-1420-5. Epub 2016 Oct 3. PMID: 27699557; PMCID: PMC5336514.

Brucoli M, Boffano P, Romeo I, Corio C, Benech A, Ruslin M, Forouzanfar T, Starch-Jensen T, Rodríguez-Santamarta T, de Vicente JC, Snäll J, Thorén H, Aničić B, Konstantinovic VS, Pechalova P, Pavlov N, Daskalov H, Doykova I, Kelemith K, Tamme T, Kopchak A, Shumynskyi I, Corre P, Bertin H, Goguet Q, Anquetil M, Louvrier A, Meyer C, Dovšak T, Vozlič D, Birk A, Tarle M, Dediol E. Epidemiology of maxillofacial trauma in the elderly: A European multicenter study. J Stomatol Oral Maxillofac Surg. 2020 Sep;121(4):330-338. doi: 10.1016/j.jormas.2019.09.002. Epub 2019 Sep 15. PMID: 31533064.

Buchanan EP, Hyman CH. LeFort I Osteotomy. Semin Plast Surg. 2013 Aug;27(3):149-54. doi: 10.1055/s-0033-1357112. PMID: 24872761; PMCID: PMC3805729.

Bueno S, Hammad Y, Schlieve T. Does the type of planning in orthognathic surgery influence patient satisfaction? Oral Maxillofac Surg. 2023 Dec;27(4):685-692. doi: 10.1007/s10006-022-01114-6. Epub 2022 Sep 19. PMID: 36121522.

Burnstine MA. Clinical recommendations for repair of isolated orbital floor fractures: an evidence-based analysis. Ophthalmology. 2002 Jul;109(7):1207-10; discussion 1210-1; quiz 1212-3. doi: 10.1016/s0161-6420(02)01057-6. PMID: 12093637.

Cai EZ, Koh YP, Hing EC, Low JR, Shen JY, Wong HC, Sundar G, Lim TC. Computer-assisted navigational surgery improves outcomes in orbital reconstructive surgery. J Craniofac Surg. 2012 Sep;23(5):1567-73. doi: 10.1097/SCS.0b013e318260ef33. PMID: 22976663.

Carpenter D, Shammas R, Honeybrook A, Brown CS, Chapurin N, Woodard CR. The Role of Postoperative Imaging after Orbital Floor Fracture Repair. Craniomaxillofac Trauma Reconstr. 2018 Jun;11(2):96-101. doi: 10.1055/s-0038-1625949. Epub 2018 Feb 5. PMID: 29892323; PMCID: PMC5993665.

Charuakkra A, Mahasantipiya P, Lehtinen A, Koivisto J, Järnstedt J. Comparison of subjective image analysis and effective dose between low-dose cone-beam computed tomography machines. Dentomaxillofac Radiol. 2023 Jan;52(2):20220176. doi: 10.1259/dmfr.20220176. Epub 2022 Oct 24. PMID: 36168973; PMCID: PMC9974239.

Cheng H, Clymer JW, Po-Han Chen B, Sadeghirad B, Ferko NC, Cameron CG, Hinoul P. Prolonged operative duration is associated with complications: a systematic review and meta-analysis. J Surg Res. 2018 Sep;229:134-144. doi: 10.1016/j.jss.2018.03.022. Epub 2018 Apr 24. PMID: 29936980.

Chepurnyi Y, Chernohorskyi D, Prykhodko D, Poutala A, Kopchak A. Reliability of orbital volume measurements based on computed tomography segmentation: Validation of different algorithms in orbital trauma patients. J Craniomaxillofac Surg. 2020 Jun;48(6):574-581. doi: 10.1016/j.jcms.2020.03.007. Epub 2020 Mar 29. PMID: 32291132.

Chepurnyi Y, Chernohorskyi D, Prykhodko D, Poutala A, Kopchak A. Reliability of orbital volume measurements based on computed tomography segmentation: Validation of different algorithms in orbital trauma patients. J Craniomaxillofac Surg. 2020 Jun;48(6):574-581. doi: 10.1016/j.jcms.2020.03.007. Epub 2020 Mar 29. PMID: 32291132.

Ching JA, Ford JM, Decker SJ. Aging of the Adult Bony Orbit. J Craniofac Surg. 2020 Jun;31(4):1082-1085. doi: 10.1097/SCS.0000000000006311. PMID: 32149982.

Chung SY, Langer PD. Pediatric orbital blowout fractures. Curr Opin Ophthalmol. 2017 Sep;28(5):470-476. doi: 10.1097/ICU.0000000000000407. PMID: 28797015.

Current Care Guidelines 2024 https://www.kaypahoito.fi/en/ Accessed 10th January 2025

da Silva Filho OG, de Castro Machado FM, de Andrade AC, de Souza Freitas JA, Bishara SE. Upper dental arch morphology of adult unoperated complete bilateral cleft lip and palate. Am J Orthod Dentofacial Orthop. 1998 Aug;114(2):154-61. doi: 10.1053/od.1998.v114.a86380. PMID: 9714280.

Dalle Ore C, Schoenbrunner A, Brandel M, Kronstadt N, McIntyre J, Jones M, Gosman A. Incidence of Le Fort Sur-gery in a Mature Cohort of Patients With Cleft Lip and Palate. Ann Plast Surg. 2017 May;78(5 Suppl 4):S199-S203. doi: 10.1097/SAP.0000000000001049. PMID: 28399025.

Daskalogiannakis J, Mehta M. The need for orthognathic surgery in patients with repaired complete unilateral and complete bilateral cleft lip and palate. Cleft Palate Craniofac J. 2009 Sep;46(5):498-502. doi: 10.1597/08-176.1. Epub 2009 Feb 28. PMID: 19929100.

Daskalogiannakis, J.; Mehta, M.; Meazzini, M.C.; Capello, A.V.; Ventrini, F.; Autelitano, L.; Morabito, A.; Garattini, G.; Brusati, R.; Wu, Y.; et al. The Need for Orthognathic Surgery in Patients with Repaired Complete Unilateral and Complete Bilateral Cleft Lip and Palate. Cleft Palate-Craniofacial J. 2009, 46, 498–502.

Dedhia R, Tollefson TT. Delayed Periorbital Abscess after Silicone Implant to Orbital Floor Fracture. Craniomaxillofac Trauma Reconstr. 2016 Jun;9(2):185-7. doi: 10.1055/s-0035-1570075. Epub 2015 Dec 21. PMID: 27162580; PMCID: PMC4858424.

Defabianis P, Cogo C, Massa S, Romano F. Oral-Health-Related Quality of Life among Non-Syndromic School-Age Children with Orofacial Clefts: Results from a Cross-Sectional Study in Northern Italy. Children (Basel). 2022 Jul 21;9(7):1098. doi: 10.3390/children9071098. PMID: 35884082; PMCID: PMC9321112.

Deng HH, Liu Q, Chen A, Kuang T, Yuan P, Gateno J, Kim D, Barber JC, Xiong KG, Yu P, Gu KJ, Xu X, Yan P, Shen D, Xia JJ. Clinical feasibility of deep learning-based automatic head CBCT image segmentation and landmark detection in computer-aided surgical simulation for orthognathic surgery. Int J Oral Maxillofac Surg. 2023 Jul;52(7):793-800. doi: 10.1016/j.ijom.2022.10.010. Epub 2022 Nov 10. PMID: 36372697; PMCID: PMC10169531.

Derijcke A, Eerens A, Carels C. The incidence of oral clefts: a review. Br J Oral Maxillofac Surg. 1996 Dec;34(6):488-94. doi: 10.1016/s0266-4356(96)90242-9. PMID: 8971440.

Dindo D, Demartines N, Clavien PA. Classification of surgical complications: a new proposal with evaluation in a cohort of 6336 patients and results of a survey.

Ann Surg. 2004 Aug;240(2):205-13. doi: 10.1097/01.sla.0000133083.54934.ae. PMID: 15273542; PMCID: PMC1360123.

Ed-Dhahraouy M, Riri H, Ezzahmouly M, Bourzgui F, El Moutaoukkil A. A new methodology for automatic detection of reference points in 3D cephalometry: A pilot study. Int Orthod. 2018 Jun;16(2):328-337. doi: 10.1016/j.ortho.2018.03.013. Epub 2018 Apr 6. PMID: 29628421.

Eley KA, Watt-Smith SR, Golding SJ. "Black Bone" MRI: a novel imaging technique for 3D printing. Dentomaxillofac Radiol. 2017 Mar;46(3):20160407. doi: 10.1259/dmfr.20160407. Epub 2017 Jan 27. PMID: 28128636; PMCID: PMC5606274.

Eley KA, Watt-Smith SR, Golding SJ. "Black bone" MRI: a potential alternative to CT when imaging the head and neck: report of eight clinical cases and review of the Oxford experience. Br J Radiol. 2012 Nov;85(1019):1457-64. doi: 10.1259/bjr/16830245. PMID: 23091288; PMCID: PMC3500787.

Eley KA, Watt-Smith SR, Golding SJ. Three-Dimensional Reconstruction of the Craniofacial Skeleton With Gradient Echo Magnetic Resonance Imaging ("Black Bone"): What Is Currently Possible? J Craniofac Surg. 2017 Mar;28(2):463-467. doi: 10.1097/SCS.0000000000003219. PMID: 28114217.

Ellis E 3rd, Tan Y. Assessment of internal orbital reconstructions for pure blowout fractures: cranial bone grafts versus titanium mesh. J Oral Maxillofac Surg. 2003 Apr;61(4):442-53. doi: 10.1053/joms.2003.50085. PMID: 12684961.

Epker BN. Modifications in the sagittal osteotomy of the mandible. J Oral Surg. 1977 Feb;35(2):157-9. PMID: 264514.

Erling BF, Iliff N, Robertson B, Manson PN. Footprints of the globe: a practical look at the mechanism of orbital blowout fractures, with a revisit to the work of Raymond Pfeiffer. Plast Reconstr Surg. 1999 Apr;103(4):1313-6; discussion 1317-9. PMID: 10088527.

Färkkilä EM, Kaban LB, Boos-Lima FBDJ, Peacock ZS. Association of craniomaxillofacial fractures and blunt cerebrovascular injuries. Int J Oral Maxillofac Surg. 2023 Aug;52(8):847-853. doi: 10.1016/j.ijom.2022.12.003. Epub 2022 Dec 21. PMID: 36564270.

Färkkilä EM, Oksanen E, Kormi E, Suojanen J. What Is the Relationship Between Maxillofacial Injury Location and Associated Injuries? J Oral Maxillofac Surg. 2024 Mar 27:S0278-2391(24)00207-6. doi: 10.1016/j.joms.2024.03.025. Epub ahead of print. PMID: 38621665.

Fontenele RC, Gerhardt MDN, Picoli FF, Van Gerven A, Nomidis S, Willems H, Freitas DQ, Jacobs R. Convolutional nEural network-based automated maxillary alveolar bone segmentation on cone-beam computed tomography images. Clin Oral Implants Res. 2023 Jun;34(6):565-574. doi: 10.1111/clr.14063. Epub 2023 Mar 23. PMID: 36906917.

Forbes G, Gehring DG, Gorman CA, Brennan MD, Jackson IT. Volume measurements of normal orbital structures by computed tomographic analysis. AJR Am J Roentgenol. 1985 Jul;145(1):149-54. doi: 10.2214/ajr.145.1.149. PMID: 3873836.

Frederick R, Hogan AC, Seabolt N, Stocks RMS. An Ideal Multidisciplinary Cleft Lip and Cleft Palate Care Team. Oral Dis. 2022 Jul;28(5):1412-1417. doi: 10.1111/odi.14213. Epub 2022 May 4. PMID: 35429208.

Freihofer HP, Borstlap WA, Kuijpers-Jagtman AM, Voorsmit RA, van Damme PA, Heidbüchel KL, Borstlap-Engels VM. Timing and transplant materials for closure of alveolar clefts. A clinical comparison of 296 cases. J Craniomaxillofac Surg. 1993 Jun;21(4):143-8. doi: 10.1016/s1010-5182(05)80102-7. PMID: 8335724.

Furuta M. Measurement of orbital volume by computed tomography: especially on the growth of the orbit. Jpn J Ophthalmol. 2001 Nov-Dec;45(6):600-6. doi: 10.1016/s0021-5155(01)00419-1. PMID: 11754901.

Gassner R, Tuli T, Hächl O, Moreira R, Ulmer H. Craniomaxillofacial trauma in children: a review of 3,385 cases with 6,060 injuries in 10 years. J Oral Maxillofac Surg. 2004 Apr;62(4):399-407. doi: 10.1016/j.joms.2003.05.013. PMID: 15085503.

Gassner R, Tuli T, Hächl O, Rudisch A, Ulmer H. Cranio-maxillofacial trauma: a 10 year review of 9,543 cases with 21,067 injuries. J Craniomaxillofac Surg. 2003 Feb;31(1):51-61. doi: 10.1016/s1010-5182(02)00168-3. PMID: 12553928.

Gear AJ, Lokeh A, Aldridge JH, Migliori MR, Benjamin CI, Schubert W. Safety of titanium mesh for orbital reconstruction. Ann Plast Surg. 2002 Jan;48(1):1-7; discussion 7-9. doi: 10.1097/00000637-200201000-00001. PMID: 11773723.

Gellrich NC, Schramm A, Rustemeyer J, Schön R, Theodor Eysel U. Quantification of the nEurodegenerative impact on the visual system following sudden retrobulbar expanding lesions - an experimental model. J Craniomaxillofac Surg. 2002 Aug;30(4):230-6. doi: 10.1054/jcms.2002.0312. PMID: 12231204.

Glover MJ. The Economic Evaluation of Surgical Interventions. Eur J Vasc Endovasc Surg. 2016 May;51(5):750. doi: 10.1016/j.ejvs.2016.01.015. Epub 2016 Mar 2. PMID: 26947539.

Gokharman FD, Kadirhan O, Celik Aydin O, Yalcin AG, Kosar P, Aydin S. A Comprehensive Look at Maxillofacial Traumas: On the Basis of Orbital Involvement. Diagnostics (Basel). 2023 Nov 11;13(22):3429. doi: 10.3390/diagnostics13223429. PMID: 37998566; PMCID: PMC10670346.

Good PM, Mulliken JB, Padwa BL. Frequency of Le Fort I osteotomy after repaired cleft lip and palate or cleft palate. Cleft Palate Craniofac J. 2007 Jul;44(4):396-401. doi: 10.1597/06-075.1. PMID: 17608550.

Good, P.M.; Mulliken, J.B.; Padwa, B.L. Frequency of Le Fort I osteotomy after repaired cleft lip and palate or cleft palate. Cleft Palate-Craniofacial J. 2007, 44, 396–401.

Goodson AMC, Parmar S, Ganesh S, Zakai D, Shafi A, Wicks C, O'Connor R, Yeung E, Khalid F, Tahim A, Gowrishankar S, Hills A, Williams EM. Printed titanium implants in UK craniomaxillofacial surgery. Part I: access to digital planning and perceived scope for use in common procedures. Br J Oral Maxillofac Surg. 2021 Apr;59(3):312-319. doi: 10.1016/j.bjoms.2020.08.087. Epub 2020 Aug 21. PMID: 33280946.

Goodson AMC, Parmar S, Ganesh S, Zakai D, Shafi A, Wicks C, O'Connor R, Yeung E, Khalid F, Tahim A, Gowrishankar S, Hills A, Williams EM. Printed titanium implants in UK craniomaxillofacial surgery. Part II: perceived performance (outcomes, logistics, and costs). Br J Oral Maxillofac Surg. 2021 Apr;59(3):320-328. doi: 10.1016/j.bjoms.2020.08.088. Epub 2020 Aug 21. PMID: 33280945.

Gosau M, Schöneich M, Draenert FG, Ettl T, Driemel O, Reichert TE. Retrospective analysis of orbital floor fractures--complications, outcome, and review of literature. Clin Oral Investig. 2011 Jun;15(3):305-13. doi: 10.1007/s00784-010-0385-y. Epub 2010 Feb 18. PMID: 20165966.

Gosau M, Schöneich M, Draenert FG, Ettl T, Driemel O, Reichert TE. Retrospective analysis of orbital floor fractures--complications, outcome, and review of literature. Clin Oral Investig. 2011 Jun;15(3):305-13. doi: 10.1007/s00784-010-0385-y. Epub 2010 Feb 18. PMID: 20165966.

Grammer K, Thornhill R. Human (Homo sapiens) facial attractiveness and sexual selection: the role of symmetry and averageness. J Comp Psychol. 1994 Sep;108(3):233-42. doi: 10.1037/0735-7036.108.3.233. PMID: 7924253.

Griffin AS, Hoang JK, Malinzak MD. CT and MRI of the Orbit. Int Ophthalmol Clin. 2018 Spring;58(2):25-59. doi: 10.1097/IIO.0000000000000218. PMID: 29517644.

Harrar H, Myers S, Ghanem AM. Art or Science? An Evidence-Based Approach to Human Facial Beauty a Quantitative Analysis Towards an Informed Clinical Aesthetic Practice. Aesthetic Plast Surg. 2018 Feb;42(1):137-146. doi: 10.1007/s00266-017-1032-7. Epub 2018 Jan 8. PMID: 29313062; PMCID: PMC5786654.

Hatcher DC. CT & CBCT imaging: assessment of the orbits. Oral Maxillofac Surg Clin North Am. 2012 Nov;24(4):537-43. doi: 10.1016/j.coms.2012.07.003. Epub 2012 Sep 13. PMID: 22981080.

Hayashi Y, Tachiki C, Morikawa T, Aihara Y, Matsunaga S, Sugahara K, Watanabe A, Kawamata T, Nishii Y. Three-Dimensional Analysis of the Cranial Base Structure in Patients with Facial Asymmetry. Diagnostics (Basel). 2023 Dec 22;14(1):24. doi: 10.3390/diagnostics14010024. PMID: 38201333; PMCID: PMC10795710.

Hayashi Y, Tachiki C, Morikawa T, Aihara Y, Matsunaga S, Sugahara K, Watanabe A, Kawamata T, Nishii Y. Three-Dimensional Analysis of the Cranial Base Structure in Patients with Facial Asymmetry. Diagnostics (Basel). 2023 Dec 22;14(1):24. doi: 10.3390/diagnostics14010024. PMID: 38201333; PMCID: PMC10795710.

Healey T, El-Othmani MM, Healey J, Peterson TC, Saleh KJ. Improving Operating Room Efficiency, Part 1: General Managerial and Preoperative Strategies. JBJS Rev. 2015 Oct 20;3(10):e3. doi: 10.2106/JBJS.RVW.N.00109. PMID: 27490788.

Heliövaara A, Küseler A, Skaare P, Shaw W, Mølsted K, Karsten A, Brinck E, Rizell S, Marcusson A, Sæle P, Hurmerinta K, Rønning E, Najar Chalien M, Bellardie H, Mooney J, Eyres P, Semb G. Scandcleft randomised trials of primary surgery for unilateral cleft lip and palate: 6. Dental arch relationships in 5 year-olds. J Plast Surg Hand Surg. 2017 Feb;51(1):52-57. doi: 10.1080/2000656X.2016.1221352. Epub 2016 Oct 25. PMID: 27778528.

Heliövaara A, Rautio J. A comparison of craniofacial cephalometric morphology and the later need for orthognathic surgery in 6-year-old cleft children. J Craniomaxillofac Surg. 2011 Apr;39(3):173-6. doi: 10.1016/j.jcms.2010.03.020. Epub 2010 Apr 27. PMID: 20427194.

Heliövaara, A.; Rautio, J. A comparison of craniofacial cephalometric morphology and the later need for orthognathic surgery in 6-year-old cleft children. J. Craniomaxillofacial Surg. 2011, 39, 173–176.

Hohman MH, Kim SW, Heller ES, Frigerio A, Heaton JT, Hadlock TA. Determining the threshold for asymmetry detection in facial expressions. Laryngoscope. 2014 Apr;124(4):860-5. doi: 10.1002/lary.24331. Epub 2013 Oct 2. PMID: 23900726; PMCID: PMC4392713.

Holmes S, Schlittler FL. Going beyond the limitations of the non-patient-specific implant in titanium reconstruction of the orbit. Br J Oral Maxillofac Surg. 2021 Nov;59(9):1074-1078. doi: 10.1016/j.bjoms.2021.03.017. Epub 2021 Jun 2. PMID: 34284883.

Hsung TC, Lo J, Chong MM, Goto TK, Cheung LK. Orbit Segmentation by Surface Reconstruction With Automatic Sliced Vertex Screening. IEEE Trans Biomed Eng. 2018 Apr;65(4):828-838. doi: 10.1109/TBME.2017.2720184. Epub 2017 Jun 29. PMID: 28682243.

Huang LK, Wang HH, Tu HF, Fu CY. Simultaneous head and facial computed tomography scans for assessing facial fractures in patients with traumatic brain injury. Injury. 2017 Jul;48(7):1417-1422. doi: 10.1016/j.injury.2017.04.046. Epub 2017 Apr 24. PMID: 28455003.

Hunsuck EE. A modified intraoral sagittal splitting technic for correction of mandibular prognathism. J Oral Surg. 1968 Apr;26(4):250-3. PMID: 5237786.

Hwang K, Park CY. The Divine Proportion: Origins and Usage in Plastic Surgery. Plast Reconstr Surg Glob Open. 2021 Feb 22;9(2):e3419. doi: 10.1097/GOX.0000000000003419. PMID: 33680667; PMCID: PMC7929632.

Ihlis RL, Kadesjö N, Tsilingaridis G, Benchimol D, Shi XQ. Image quality assessment of low-dose protocols in cone beam computed tomography of the anterior maxilla. Oral Surg Oral Med Oral Pathol Oral Radiol. 2022 Apr;133(4):483-491. doi: 10.1016/j.0000.2021.10.001. Epub 2021 Oct 11. PMID: 34742681.

Jacob L, Fahradyan A, Paulson P, Wlodarczyk JR, Wolfswinkel EM, Jimenez C, Urata MM, Hammoudeh JA. Orthognathic Surgery Rate in Cleft Care. J Craniofac Surg. 2022 Jan-Feb 01;33(1):87-92. doi: 10.1097/SCS.0000000000008002. PMID: 34967515.

Jansen J, Dubois L, Maal TJJ, Mourits MP, Jellema HM, Neomagus P, de Lange J, Hartman LJC, Gooris PJJ, Becking AG. A nonsurgical approach with

repeated orthoptic evaluation is justified for most blow-out fractures. J Craniomaxillofac Surg. 2020 Jun;48(6):560-568. doi: 10.1016/j.jcms.2020.03.005. Epub 2020 Mar 30. PMID: 32295722.

Jansen J, SchrEurs R, Dubois L, Maal TJJ, Gooris PJJ, Becking AG. Intraoperative imaging in orbital reconstruction: how does it affect the position of the implant? Br J Oral Maxillofac Surg. 2020 Sep;58(7):801-806. doi: 10.1016/j.bjoms.2020.04.018. Epub 2020 May 4. PMID: 32381387.

Järvinen S, Suojanen J, Kormi E, Wilkman T, Kiukkonen A, Leikola J, Stoor P. The use of patient specific polyetheretherketone implants for reconstruction of maxillofacial deformities. J Craniomaxillofac Surg. 2019 Jul;47(7):1072-1076. doi: 10.1016/j.jcms.2019.03.018. Epub 2019 Apr 24. PMID: 31103433.

Järvinen S, Suojanen J, Suomalainen A, Stoor P. Virtual Surgical Planning Combined With Intraoperative Navigation in Mandibular Bilateral Sagittal Split Osteotomy for Accurate Placement of Patient Specific Implants. J Craniofac Surg. 2021 Nov-Dec 01;32(8):2666-2670. doi: 10.1097/SCS.0000000000007937. PMID: 34260465.

Jeon A, Lee UY, Kwak DS, Lee JH, Ra H, Han SH. Aging of the bony orbit in East Asians: a three-dimensional computed tomographic study. Surg Radiol Anat. 2020 May;42(5):617-626. doi: 10.1007/s00276-019-02410-9. Epub 2020 Jan 20. PMID: 31960087.

Ji Y, Qian Z, Dong Y, Zhou H, Fan X. Quantitative morphometry of the orbit in Chinese adults based on a three-dimensional reconstruction method. J Anat. 2010 Nov;217(5):501-6. doi: 10.1111/j.1469-7580.2010.01286.x. Epub 2010 Aug 30. PMID: 20807268; PMCID: PMC3035858.

Jones, B. C., DeBruine, L. M., & Little, A. C. (2008). Adaptation reinforces preferences for correlates of attractive facial cues. Visual Cognition, 16(7), 849–858. https://doi.org/10.1080/13506280701760811

Juncar M, Tent PA, Juncar RI, Harangus A, Mircea R. An epidemiological analysis of maxillofacial fractures: a 10-year cross-sectional cohort retrospective study of 1007 patients. BMC Oral Health. 2021 Mar 17;21(1):128. doi: 10.1186/s12903-021-01503-5. PMID: 33731083; PMCID: PMC7968332.

Kahn DM, Shaw RB Jr. Aging of the bony orbit: a three-dimensional computed tomographic study. Aesthet Surg J. 2008 May-Jun;28(3):258-64. doi: 10.1016/j.asj.2008.02.007. PMID: 19083535.

Kalmar CL, Humphries LS, Zimmerman CE, Vu GH, Swanson JW, Bartlett SP, Taylor JA. Orthognathic Hardware Complications in the Era of Patient-Specific Implants. Plast Reconstr Surg. 2020 Nov;146(5):609e-621e. doi: 10.1097/PRS.0000000000007250. PMID: 32826735.

Kermany DS, Goldbaum M, Cai W, Valentim CCS, Liang H, Baxter SL, McKeown A, Yang G, Wu X, Yan F, Dong J, Prasadha MK, Pei J, Ting MYL, Zhu J, Li C, Hewett S, Dong J, Ziyar I, Shi A, Zhang R, Zheng L, Hou R, Shi W, Fu X, Duan Y, Huu VAN, Wen C, Zhang ED, Zhang CL, Li O, Wang X, Singer MA, Sun X, Xu J, Tafreshi A, Lewis MA, Xia H, Zhang K. Identifying Medical Diagnoses and Treatable Diseases by Image-Based Deep Learning. Cell. 2018 Feb 22;172(5):1122-1131.e9. doi: 10.1016/j.cell.2018.02.010. PMID: 29474911.

Kermany DS, Goldbaum M, Cai W, Valentim CCS, Liang H, Baxter SL, McKeown A, Yang G, Wu X, Yan F, Dong J, Prasadha MK, Pei J, Ting MYL, Zhu J, Li C, Hewett S, Dong J, Ziyar I, Shi A, Zhang R, Zheng L, Hou R, Shi W, Fu X, Duan Y, Huu VAN, Wen C, Zhang ED, Zhang CL, Li O, Wang X, Singer MA, Sun X, Xu J, Tafreshi A, Lewis MA, Xia H, Zhang K. Identifying Medical Diagnoses and Treatable Diseases by Image-Based Deep Learning. Cell. 2018 Feb 22;172(5):1122-1131.e9. doi: 10.1016/j.cell.2018.02.010. PMID: 29474911.

Klassen AF, Riff KWW, Longmire NM, Albert A, Allen GC, Aydin MA, Baker SB, Cano SJ, Chan AJ, Courtemanche DJ, Dreise MM, Goldstein JA, Goodacre TEE, Harman KE, Munill M, Mahony AO, Aguilera MP, Peterson P, Pusic AL, Slator R, Stiernman M, Tsangaris E, Tholpady SS, Vargas F, Forrest CR. Psychometric findings and normative values for the CLEFT-Q based on 2434 children and young adult patients with cleft lip and/or palate from 12 countries. CMAJ. 2018 Apr 16;190(15):E455-E462. doi: 10.1503/cmaj.170289. PMID: 29661814; PMCID: PMC5903887.

Klassen AF, Tsangaris E, Forrest CR, Wong KW, Pusic AL, Cano SJ, Syed I, Dua M, Kainth S, Johnson J, Goodacre T. Quality of life of children treated for cleft lip and/or palate: a systematic review. J Plast Reconstr Aesthet Surg. 2012 May;65(5):547-57. doi: 10.1016/j.bjps.2011.11.004. Epub 2011 Nov 25. PMID: 22118856.

Kochhar, A.S.; Nucci, L.; Sidhu, M.S.; Prabhakar, M.; Grassia, V.; Perillo, L.; Kochhar, G.K.; Bhasin, R.; Dadlani, H.; d'Apuzzo, F. Reliability and Reproducibility of Landmark Identification in Unilateral Cleft Lip and Palate Patients: Digital Lateral Vis-A-Vis CBCT-Derived 3D Cephalograms. J. Clin. Med. 2021, 10, 535. https://doi.org/10.3390/jcm10030535

Koivisto J, Wolff J, Pauwels R, Kaasalainen T, Suomalainen A, Stoor P, Horelli J, Suojanen J. Assessment of cone-beam CT technical image quality indicators and radiation dose for optimal STL model used in visual surgical planning. Dentomaxillofac Radiol. 2024 Sep 1;53(6):423-433. doi: 10.1093/dmfr/twae026. PMID: 38913866; PMCID: PMC11358642.

Komori M, Kawamura S, Ishihara S. Averageness or symmetry: which is more important for facial attractiveness? Acta Psychol (Amst). 2009 Jun;131(2):136-42. doi: 10.1016/j.actpsy.2009.03.008. Epub 2009 Apr 25. PMID: 19394585.

Kontio R, Lindqvist C. Management of orbital fractures. Oral Maxillofac Surg Clin North Am. 2009 May;21(2):209-20, vi. doi: 10.1016/j.coms.2008.12.012. PMID: 19348987.

Kontio R, Wilkman T, Mesimäki K, Chepurnyi Y, Asikainen A, Haapanen A, Poutala A, Mikkonen M, Slobodianiuk A, Kopchak A. Automated 3-D Computer-Aided Measurement of the Bony Orbit: Evaluation of Correlations among Volume, Depth, and Surface Area. J Pers Med. 2024 May 11;14(5):508. doi: 10.3390/jpm14050508. PMID: 38793092; PMCID: PMC11122174.

Koskela A, Neittaanmäki A, Rönnberg K, Palotie A, Ripatti S, Palotie T. The relation of severe malocclusion to patients' mental and behavioral disorders, growth, and speech problems. .Eur J Orthod. 2021 Apr 3;43(2):159-164. doi: 10.1093/ejo/cjaa028.

Kotaniemi KVM, Heliövaara A, Kotaniemi M, Stoor P, Leikola J, Palotie T, Suojanen J. Comparison of postoperative skeletal stability of maxillary segments after Le Fort I osteotomy, using patient-specific implant versus mini-plate fixation. J Craniomaxillofac Surg. 2019 Jul;47(7):1020-1030. doi: 10.1016/j.jcms.2019.04.003. Epub 2019 Apr 27. PMID: 31085061.

Krahn M. Principles of economic evaluation in surgery. World J Surg. 1999 Dec;23(12):1242-8. doi: 10.1007/s002689900656. PMID: 10552115.

Kramer FJ, Baethge C, Swennen G, Teltzrow T, Schulze A, Berten J, Brachvogel P. Intra- and perioperative complications of the LeFort I osteotomy: a prospective evaluation of 1000 patients. J Craniofac Surg. 2004 Nov;15(6):971-7; discussion 978-9. doi: 10.1097/00001665-200411000-00016. PMID: 15547385.

Kuehle R, SchEurer M, BoufflEur F, Fuchs J, Engel M, Hoffmann J, Freudlsperger C. Accuracy of Patient-Specific Implants in Virtually Planned Segmental Le Fort I Osteotomies. J Clin Med. 2023 Sep 18;12(18):6038. doi: 10.3390/jcm12186038. PMID: 37762977; PMCID: PMC10532412.

Kumar S, Williams AC, Sandy JR. How do we evaluate the economics of health care? Eur J Orthod. 2006 Dec;28(6):513-9. doi: 10.1093/ejo/cjl046. Epub 2006 Oct 11. PMID: 17035484.

Lamberg MA. Maxillo-facial fractures. An epidemiological and clinical study on hospitalized patients. Proc Finn Dent Soc. 1978;74(5-6):113-35. PMID: 733748.

Latief BS, Kuijpers MAR, Stebel A, Kuijpers-Jagtman AM, Fudalej PS. Pattern of Morphological Variability in Unrepaired Unilateral Clefts With and Without Cleft Palate May Suggest Intrinsic Growth Deficiency. Front Cell Dev Biol. 2020 Dec 11;8:587859. doi: 10.3389/fcell.2020.587859. PMID: 33363145; PMCID: PMC7759528.

Latief BS, Lekkas C, Kuijpers MA. Maxillary arch width in unoperated adult bilateral cleft lip and alveolus and complete bilateral cleft lip and palate. Orthod Craniofac Res. 2010 May;13(2):82-8. doi: 10.1111/j.1601-6343.2009.01479.x. PMID: 20477967.

Le Fort, R. Étude expérimentale sur les fractures de la machoire supériEure. Rev. Chir. Paris 1901, 23, 208–227.

Le Fort, R. Étude expérimentale sur les fractures de la machoire supériEure. Rev. Chir. Paris 1901, 23, 208–227.

Leite AF, Vasconcelos KF, Willems H, Jacobs R. Radiomics and Machine Learning in Oral Healthcare. Proteomics Clin Appl. 2020 May;14(3):e1900040. doi: 10.1002/prca.201900040. Epub 2020 Jan 29. PMID: 31950592.

Levinson W, Born K, Wolfson D. Choosing Wisely Campaigns: A Work in Progress. JAMA. 2018;319(19):1975–1976. doi:10.1001/jama.2018.2202

Li B, Zhang L, Sun H, Yuan J, Shen SG, Wang X. A novel method of computer aided orthognathic surgery using individual CAD/CAM templates: a combination of osteotomy and repositioning guides. Br J Oral Maxillofac Surg. 2013 Dec;51(8):e239-44. doi: 10.1016/j.bjoms.2013.03.007. Epub 2013 Apr 6. PMID: 23566536.

Li DTS, Leung YY. Patient-Specific Implants in Orthognathic Surgery. Oral Maxillofac Surg Clin North Am. 2023 Feb;35(1):61-69. doi: 10.1016/j.coms.2022.06.004. Epub 2022 Nov 3. PMID: 36336593.

Li DTS, Leung YY. Patient-Specific Implants in Orthognathic Surgery. Oral Maxillofac Surg Clin North Am. 2023 Feb;35(1):61-69. doi: 10.1016/j.coms.2022.06.004. Epub 2022 Nov 3. PMID: 36336593.

Li J, Wu S, Mei L, Wen J, Marra J, Lei L, Li H. Facial asymmetry of the hard and soft tissues in skeletal Class I, II, and III patients. Sci Rep. 2024 Feb 29;14(1):4966. doi: 10.1038/s41598-024-55107-4. PMID: 38424179; PMCID: PMC10904784.

Lin Y, Chen G, Fu Z, Ma L, Li W. Cone-Beam Computed Tomography Assessment of Lower Facial Asymmetry in Unilateral Cleft Lip and Palate and Non-Cleft Patients with Class III Skeletal Relationship. PLoS One. 2015 Aug 3;10(8):e0130235. doi: 10.1371/journal.pone.0130235. PMID: 26237311; PMCID: PMC4523208.

Loubele M, Maes F, Schutyser F, Marchal G, Jacobs R, Suetens P. Assessment of bone segmentation quality of cone-beam CT versus multislice spiral CT: a pilot study. Oral Surg Oral Med Oral Pathol Oral Radiol Endod. 2006 Aug;102(2):225-34. doi: 10.1016/j.tripleo.2005.10.039. Epub 2006 Apr 21. PMID: 16876067.

Lundberg J, Levring Jäghagen E, Sjöström M. Outcome after secondary alveolar bone grafting among patients with cleft lip and palate at 16 years of age: a retrospective study. Oral Surg Oral Med Oral Pathol Oral Radiol. 2021 Sep;132(3):281-287. doi: 10.1016/j.oooo.2021.04.057. Epub 2021 May 4. PMID: 34130938.

Ma L, Cheng S, Ji X, Zhou Y, Zhang Y, Li Q, Tan C, Peng F, Zhang Y, Huang W. Immobilizing magnesium ions on 3D printed porous tantalum scaffolds with polydopamine for improved vascularization and osteogenesis. Mater Sci Eng C Mater Biol Appl. 2020 Dec;117:111303. doi: 10.1016/j.msec.2020.111303. Epub 2020 Jul 28. PMID: 32919664.

Macario A. What does one minute of operating room time cost? J Clin Anesth. 2010 Jun;22(4):233-6. doi: 10.1016/j.jclinane.2010.02.003. PMID: 20522350.

Maintz M, Tourbier C, de Wild M, Cattin PC, Beyer M, Seiler D, Honigmann P, Sharma N, Thieringer FM. Patient-specific implants made of 3D printed bioresorbable polymers at the point-of-care: material, technology, and scope of surgical application. 3D Print Med. 2024 Apr 19;10(1):13. doi: 10.1186/s41205-024-00207-0. PMID: 38639834; PMCID: PMC11031859.

Mani M, Carlsson M, Marcusson A. Quality of life varies with gender and age among adults treated for unilateral cleft lip and palate. Cleft Palate Craniofac J. 2010 Sep;47(5):491-8. doi: 10.1597/08-281. PMID: 20180705.

Marcusson A, Akerlind I, Paulin G. Quality of life in adults with repaired complete cleft lip and palate. Cleft Palate Craniofac J. 2001 Jul;38(4):379-85. doi: 10.1597/1545-1569_2001_038_0379_qoliaw_2.0.co_2. PMID: 11420018.

Marquardt SR. Dr. Stephen R. Marquardt on the Golden Decagon and human facial beauty. Interview by Dr. Gottlieb. J Clin Orthod. 2002 Jun;36(6):339-47. PMID: 12101544.

Marsh JL, Vannier MW. The "third" dimension in craniofacial surgery. Plast Reconstr Surg. 1983 Jun;71(6):759-67. doi: 10.1097/00006534-198306000-00002. PMID: 6687945.

Mazzoni S, Bianchi A, Schiariti G, Badiali G, Marchetti C. Computer-aided design and computer-aided manufacturing cutting guides and customized titanium plates are useful in upper maxilla waferless repositioning. J Oral Maxillofac Surg. 2015 Apr;73(4):701-7. doi: 10.1016/j.joms.2014.10.028. Epub 2014 Nov 29. PMID: 25622881.

McCrary H, Skirko JR. Bone Grafting of Alveolar Clefts. Oral Maxillofac Surg Clin North Am. 2021 May;33(2):231-238. doi: 10.1016/j.coms.2021.01.007. Epub 2021 Mar 2. PMID: 33663951.

Meazzini, M.C.; Capello, A.V.; Ventrini, F.; Autelitano, L.; Morabito, A.; Garattini, G.; Brusati, R. Long-Term Follow-Up of UCLP Patients: Surgical and Orthodontic Burden of Care during Growth and Final Orthognathic Surgery Need. Cleft Palate-Craniofacial J. 2015, 52, 688–697. [Google Scholar] [CrossRef]

Merta M, Heliövaara A, Leikola J, Suojanen J. Early experience of wafer-free Le Fort I osteotomy with patient-specific implants in cleft lip and palate patients. J Plast Reconstr Aesthet Surg. 2023 Feb;77:78-86. doi: 10.1016/j.bjps.2022.10.051. Epub 2022 Nov 2. PMID: 36563638.

Meyer-Marcotty P, Stellzig-Eisenhauer A, Bareis U, Hartmann J, Kochel J. Three-dimensional perception of facial asymmetry. Eur J Orthod. 2011 Dec;33(6):647-53. doi: 10.1093/ejo/cjq146. Epub 2011 Feb 25. PMID: 21355063.

Mijiti A, Ling W, Tuerdi M, Maimaiti A, Tuerxun J, Tao YZ, Saimaiti A, Moming A. Epidemiological analysis of maxillofacial fractures treated at a university hospital, Xinjiang, China: A 5-year retrospective study. J Craniomaxillofac Surg. 2014 Apr;42(3):227-33. doi: 10.1016/j.jcms.2013.05.005. Epub 2013 Jun 19. PMID: 23791439.

Miragall MF, Knoedler S, Kauke-Navarro M, Saadoun R, Grabenhorst A, Grill FD, Ritschl LM, Fichter AM, Safi AF, Knoedler L. Face the Future-Artificial Intelligence in Oral and Maxillofacial Surgery. J Clin Med. 2023 Oct 30;12(21):6843. doi: 10.3390/jcm12216843. PMID: 37959310; PMCID: PMC10649053.

Mok D, Lessard L, Cordoba C, Harris PG, Nikolis A. A review of materials currently used in orbital floor reconstruction. Can J Plast Surg. 2004 Fall;12(3):134-40. doi: 10.1177/229255030401200302. PMID: 24115885; PMCID: PMC3792801.

Naujokat H, Rohnen M, Lichtenstein J, Birkenfeld F, Gerle M, Flörke C, Wiltfang J. Computer-assisted orthognathic surgery: evaluation of mandible registration accuracy and report of the first clinical cases of navigated sagittal split ramus osteotomy. Int J Oral Maxillofac Surg. 2017 Oct;46(10):1291-1297. doi: 10.1016/j.ijom.2017.05.003. Epub 2017 May 28. PMID: 28566140.

Netter F. Netter Atlas of Human Anatomy: Classic Regional Approach 2022

Nieminen T, Kallela I, Wuolijoki E, Kainulainen H, Hiidenheimo I, Rantala I. Amorphous and crystalline polyetheretherketone: Mechanical properties and tissue reactions during a 3-year follow-up. J Biomed Mater Res A. 2008 Feb;84(2):377-83. doi: 10.1002/jbm.a.31310. PMID: 17618477.

Obwegeser H. Neue Methoden der Alveolarkammplastik [New methods of alveolar crest plastic surgery]. Osterr Z Stomatol. 1954 Nov;51(11):592-6. German. PMID: 14356666.

Obwegeser H., The indications for surgical correction of mandibular deformity by the sagittal splitting technique, British Journal of Oral Surgery, 1963:1; 157-171. doi:10.1016/S0007-117X(63)80067-0.

OECD 2024 https://data-explorer.oecd.org -> Health expenditure and financing. Accessed 07 October 2024

Ore, C.D.; Schoenbrunner, A.; Brandel, M.; Kronstadt, N.; McIntyre, J.; Jones, M.; Gosman, A. Incidence of Le Fort Surgery in a Mature Cohort of Patients With Cleft Lip and Palate. Ann. Plast. Surg. 2017, 78 (Suppl. S4), S199–S203. [Google Scholar] [CrossRef]

Osaki TH, de Castro DK, Yabumoto C, Mingkwansook V, Ting E, Nallasamy N, Curtin H, Fay A. Comparison of methodologies in volumetric orbitometry. Ophthalmic Plast Reconstr Surg. 2013 Nov-Dec;29(6):431-6. doi: 10.1097/IOP.0b013e31829d028a. PMID: 24217474.

Pabbati S, Thomson P, Sharma D, Bhandari S. The aetiology of maxillofacial trauma in Australia: A scoping review. Aust Dent J. 2024 Jun;69(2):146-156. doi: 10.1111/adj.13009. Epub 2024 Feb 13. PMID: 38348522.

Pang SSY, Fang C, Chan JYW. Application of three-dimensional printing technology in orbital floor fracture reconstruction. Trauma Case Rep. 2018 Sep 24;17:23-28. doi: 10.1016/j.tcr.2018.09.006. PMID: 30310843; PMCID: PMC6178145.

Park JH, Kim I, Son JH. Incidence and management of retrobulbar hemorrhage after blowout fracture repair. BMC Ophthalmol. 2021 Apr 22;21(1):186. doi: 10.1186/s12886-021-01943-1. PMID: 33888073; PMCID: PMC8063338.

Patel AA, Schwab JH, Amanatullah DF, Divi SN. AOA Critical Issues Symposium: Shaping the Impact of Artificial Intelligence within Orthopaedic Surgery. J Bone Joint Surg Am. 2023 Sep 20;105(18):1475-1479. doi: 10.2106/JBJS.22.01330. Epub 2023 May 12. PMID: 37172106.

Pfeiffer, R.L. Traumatic enophthalmos. Arch. Ophthalmol. 39: 718, 1943

Philip MR, AlFotawi R. The accuracy of soft tissue movement using virtual planning for non-syndromic facial asymmetry cases-a systematic review. Oral Maxillofac Surg. 2023 Jun;27(2):187-200. doi: 10.1007/s10006-022-01059-w. Epub 2022 Apr 18. PMID: 35434758.

Philippe B. Custom-made prefabricated titanium miniplates in Le Fort I osteotomies: principles, procedure and clinical insights. Int J Oral Maxillofac Surg. 2013 Aug;42(8):1001-6. doi: 10.1016/j.ijom.2012.12.013. Epub 2013 Apr 18. PMID: 23602483.

Pietzka S, Wenzel M, Winter K, Wilde F, Schramm A, Ebeling M, Kasper R, SchEurer M, Sakkas A. Comparison of Anatomical Preformed Titanium Implants and Patient-Specific CAD/CAM Implants in the Primary Reconstruction of Isolated Orbital Fractures-A Retrospective Study. J Pers Med. 2023 May 17;13(5):846. doi: 10.3390/jpm13050846. PMID: 37241016; PMCID: PMC10222691.

Pietzka S, Wenzel M, Winter K, Wilde F, Schramm A, Ebeling M, Kasper R, SchEurer M, Sakkas A. Comparison of Anatomical Preformed Titanium Implants and Patient-Specific CAD/CAM Implants in the Primary Reconstruction of Isolated Orbital Fractures-A Retrospective Study. J Pers Med. 2023 May 17;13(5):846. doi: 10.3390/jpm13050846. PMID: 37241016; PMCID: PMC10222691.

Poikela A, Kantomaa T, Tuominen M, Pirttiniemi P. Effect of unilateral masticatory function on craniofacial growth in the rabbit. Eur J Oral Sci. 1995

Apr;103(2 (Pt 1)):106-11. doi: 10.1111/j.1600-0722.1995.tb00126.x. PMID: 7767704.

Ponce-Garcia C, Ruellas ACO, Cevidanes LHS, Flores-Mir C, Carey JP, Lagravere-Vich M. Measurement error and reliability of three available 3D superimposition methods in growing patients. Head Face Med. 2020 Jan 27;16(1):1. doi: 10.1186/s13005-020-0215-7. PMID: 31987041; PMCID: PMC6983972.

Pool SMW, der Lek LMV, de Jong K, Vermeij-Keers C, Mouës-Vink CM. Embryologically Based Classification Specifies Gender Differences in the Prevalence of Orofacial Cleft Subphenotypes. Cleft Palate Craniofac J. 2021 Jan;58(1):54-60. doi: 10.1177/1055665620935363. Epub 2020 Jun 30. PMID: 32602363; PMCID: PMC7739112.

Possebon APDR, Granke G, Faot F, Pinto LR, Leite FRM, Torriani MA. Etiology, diagnosis, and demographic analysis of maxillofacial trauma in elderly persons: A 10-year investigation. J Craniomaxillofac Surg. 2017 Dec;45(12):1921-1926. doi: 10.1016/j.jcms.2017.09.002. Epub 2017 Sep 19. PMID: 29054310.

Prakasam, M.; Locs, J.; Salma-Ancane, K.; Loca, D.; Largeteau, A.; Berzina-Cimdina, L. Biodegradable Materials and Metallic Implants—A Review. J. Funct. Biomater. 2017, 8, 44. https://doi.org/10.3390/jfb8040044

Rahman E, Webb WR, Rao P, Yu N, Garcia PE, Ioannidis S, Sayed K, Philipp-Dormston WG, Carruthers JD, Mosahebi A. A Systematic Review on the Reinforcement Loop in Aesthetic Medicine and Surgery: The Interplay of Social Media, Self-Perception, and Repeat Procedures. Aesthetic Plast Surg. 2024 May 9. doi: 10.1007/s00266-024-04016-y. Epub ahead of print. Erratum in: Aesthetic Plast Surg. 2024 Jul;48(13):2610. doi: 10.1007/s00266-024-04140-9. PMID: 38724639.

Rautio J, Andersen M, Bolund S, Hukki J, Vindenes H, Davenport P, Arctander K, Larson O, Berggren A, Åbyholm F, Whitby D, Leonard A, Lilja J, Neovius E, Elander A, Heliövaara A, Eyres P, Semb G. Scandcleft randomised trials of primary surgery for unilateral cleft lip and palate: 2. Surgical results. J Plast Surg Hand Surg. 2017 Feb;51(1):14-20. doi: 10.1080/2000656X.2016.1254646. PMID: 28218552.

Resnick CM, Inverso G, Wrzosek M, Padwa BL, Kaban LB, Peacock ZS. Is There a Difference in Cost Between Standard and Virtual Surgical Planning for Orthognathic Surgery? J Oral Maxillofac Surg. 2016 Sep;74(9):1827-33. doi: 10.1016/j.joms.2016.03.035. Epub 2016 Apr 22. PMID: 27181623.

Ridgway EB, Chen C, Colakoglu S, Gautam S, Lee BT. The incidence of lower eyelid malposition after facial fracture repair: a retrospective study and meta-analysis comparing subtarsal, subciliary, and transconjunctival incisions. Plast Reconstr Surg. 2009 Nov;124(5):1578–1586.doi:10.1097/PRS.0b013e3181babb3d. PMID: 20009844.

Rinna C, Ungari C, Saltarel A, Cassoni A, Reale G. Orbital floor restoration. J Craniofac Surg. 2005 Nov;16(6):968-72. doi: 10.1097/01.scs.0000186308.16795.8b. PMID: 16327541.

Rintala A, Stegars T. Increasing incidence of clefts in Finland: reliability of hospital records and central register of congenital malformations. Scand J Plast Reconstr Surg. 1982;16(1):35-40. doi: 10.3109/02844318209006568. PMID: 7112036.

Robinson R. Costs and cost-minimisation analysis. BMJ. 1993 Sep 18;307(6906):726-8. doi: 10.1136/bmj.307.6906.726. PMID: 8401098; PMCID: PMC1678700.

Robinson R. Economic evaluation and health care. What does it mean? BMJ. 1993 Sep 11;307(6905):670-3. doi: 10.1136/bmj.307.6905.670. PMID: 8401057; PMCID: PMC1678982.

Rozema R, Doff MHJ, Delli K, Spijkervet FKL, van Minnen B. Diagnostic accuracy of physical examination findings for midfacial fractures: a systematic review and meta-analysis. Clin Oral Investig. 2022 Apr;26(4):3405-3427. doi: 10.1007/s00784-022-04423-y. Epub 2022 Mar 17. PMID: 35298710; PMCID: PMC8979892.

Sabelis JF, SchrEurs R, Essig H, Becking AG, Dubois L. Personalized Medicine Workflow in Post-Traumatic Orbital Reconstruction. J Pers Med. 2022 Aug 24;12(9):1366. doi: 10.3390/jpm12091366. PMID: 36143151; PMCID: PMC9500769.

Sahlsten J, Järnstedt J, Jaskari J, Naukkarinen H, Mahasantipiya P, Charuakkra A, Vasankari K, Hietanen A, Sundqvist O, Lehtinen A, Kaski K. Deep learning for 3D cephalometric landmarking with heterogeneous multi-center CBCT dataset. PLoS One. 2024 Jun 25;19(6):e0305947. doi: 10.1371/journal.pone.0305947. PMID: 38917161; PMCID: PMC11198780.

Salari N, Darvishi N, Heydari M, Bokaee S, Darvishi F, Mohammadi M. Global prevalence of cleft palate, cleft lip and cleft palate and lip: A comprehensive systematic review and meta-analysis. J Stomatol Oral Maxillofac Surg. 2022

Apr;123(2):110-120. doi: 10.1016/j.jormas.2021.05.008. Epub 2021 May 24. PMID: 34033944.

Sánchez-Jáuregui E, Baranda-Manterola E, Ranz-Colio Á, Bueno de Vicente Á, Acero-Sanz J. Custom made cutting guides and osteosynthesis plates versus CAD/CAM occlusal splints in positioning and fixation of the maxilla in orthognathic surgery: A prospective randomized study. J Craniomaxillofac Surg. 2022 Aug;50(8):609-614. doi: 10.1016/j.jcms.2022.05.010. Epub 2022 Jun 11. PMID: 35760659.

Schlittler F, Schmidli A, Wagner F, Michel C, Mottini M, Lieger O. What Is the Incidence of Implant Malpositioning and Revision Surgery After Orbital Repair? J Oral Maxillofac Surg. 2018 Jan;76(1):146-153. doi: 10.1016/j.joms.2017.08.024. Epub 2017 Aug 23. PMID: 28916325.

Schlittler F, Vig N, Burkhard JP, Lieger O, Michel C, Holmes S. What are the limitations of the non-patient-specific implant in titanium reconstruction of the orbit? Br J Oral Maxillofac Surg. 2020 Nov;58(9):e80-e85. doi: 10.1016/j.bjoms.2020.06.038. Epub 2020 Jul 26. PMID: 32723575.

Schneider D, Kämmerer PW, Hennig M, Schön G, Thiem DGE, Bschorer R. Customized virtual surgical planning in bimaxillary orthognathic surgery: a prospective randomized trial. Clin Oral Investig. 2019 Jul;23(7):3115-3122. doi: 10.1007/s00784-018-2732-3. Epub 2018 Nov 15. PMID: 30443778. Operation time lower, costs otherwise similar ort kir

Schreurs R, Baan F, Klop C, Dubois L, Beenen LFM, Habets PEMH, Becking AG, Maal TJJ. Registration-free workflow for electromagnetic and optical navigation in orbital and craniofacial surgery. Sci Rep. 2021 Sep 10;11(1):18080. doi: 10.1038/s41598-021-97706-5. PMID: 34508161; PMCID: PMC8433137.

Schreurs R, Klop C, Gooris PJJ, Maal TJJ, Becking AG, Dubois L. Critical appraisal of patient-specific implants for secondary post-traumatic orbital reconstruction. Int J Oral Maxillofac Surg. 2022 Jun;51(6):790-798. doi: 10.1016/j.ijom.2021.08.027. Epub 2021 Nov 8. PMID: 34763984.

Schulze, M., Juergensen, L., Rischen, R. et al. Quality assurance of 3D-printed patient specific anatomical models: a systematic review. 3D Print Med 10, 9 (2024). https://doi.org/10.1186/s41205-024-00210-5

Schumann P, Lindhorst D, Wagner ME, Schramm A, Gellrich NC, Rücker M. Perspectives on resorbable osteosynthesis materials in craniomaxillofacial surgery. Pathobiology. 2013;80(4):211-7. doi: 10.1159/000348328. Epub 2013 May 6. PMID: 23652285.

Schwartz HC. Does computer-aided surgical simulation improve efficiency in bimaxillary orthognathic surgery? Int J Oral Maxillofac Surg. 2014 May;43(5):572-6. doi: 10.1016/j.ijom.2013.10.018. Epub 2013 Dec 11. PMID: 24332585. Planning shorter, operation similar, claim more difficult operations

Semb G, Enemark H, Friede H, Paulin G, Lilja J, Rautio J, Andersen M, Åbyholm F, Lohmander A, Shaw W, Mølsted K, Heliövaara A, Bolund S, Hukki J, Vindenes H, Davenport P, Arctander K, Larson O, Berggren A, Whitby D, Leonard A, Neovius E, Elander A, Willadsen E, Bannister RP, Bradbury E, Henningsson G, Persson C, Eyres P, Emborg B, Kisling-Møller M, Küseler A, Granhof Black B, Schöps A, Bau A, Boers M, Andersen HS, Jeppesen K, Marxen D, Paaso M, Hölttä E, Alaluusua S, Turunen L, Humerinta K, Elfving-Little U, Tørdal IB, Kjøll L, Aukner R, Hide Ø, Feragen KB, Rønning E, Skaare P, Brinck E, Semmingsen AM, Lindberg N, Bowden M, Davies J, Mooney J, Bellardie H, Schofield N, Nyberg J, Lundberg M, Karsten AL, Larson M, Holmefjord A, Reisæter S, Pedersen NH, Rasmussen T, Tindlund R, Sæle P, Blomhoff R, Jacobsen G, Havstam C, Rizell S, Enocson L, Hagberg C, Najar Chalien M, Paganini A, Lundeborg I, Marcusson A, Mjönes AB, Gustavsson A, Hayden C, McAleer E, Slevan E, Gregg T, Worthington H. A Scandcleft randomised trials of primary surgery for unilateral cleft lip and palate: 1. Planning and management. J Plast Surg Hand Surg. 2017 Feb;51(1):2-13. doi: 10.1080/2000656X.2016.1263202. Erratum in: J Plast Surg Hand Surg. 2017 Apr;51(2):158. doi: 10.1080/2000656X.2017.1302182. PMID: 28218559.

Semb G, Enemark H, Friede H, Paulin G, Lilja J, Rautio J, Andersen M, Åbyholm F, Lohmander A, Shaw W, Mølsted K, Heliövaara A, Bolund S, Hukki J, Vindenes H, Davenport P, Arctander K, Larson O, Berggren A, Whitby D, Leonard A, Neovius E, Elander A, Willadsen E, Bannister RP, Bradbury E, Henningsson G, Persson C, Eyres P, Emborg B, Kisling-Møller M, Küseler A, Granhof Black B, Schöps A, Bau A, Boers M, Andersen HS, Jeppesen K, Marxen D, Paaso M, Hölttä E, Alaluusua S, Turunen L, Humerinta K, Elfving-Little U, Tørdal IB, Kjøll L, Aukner R, Hide Ø, Feragen KB, Rønning E, Skaare P, Brinck E, Semmingsen AM, Lindberg N, Bowden M, Davies J, Mooney J, Bellardie H, Schofield N, Nyberg J, Lundberg M, Karsten AL, Larson M, Holmefjord A, Reisæter S, Pedersen NH, Rasmussen T, Tindlund R, Sæle P, Blomhoff R, Jacobsen G, Havstam C, Rizell S, Enocson L, Hagberg C, Najar Chalien M, Paganini A, Lundeborg I, Marcusson A, Mjönes AB, Gustavsson A, Hayden C, McAleer E, Slevan E, Gregg T, Worthington H. A Scandcleft randomised trials of primary surgery for unilateral cleft lip and palate: 1. Planning and management. J Plast Surg Hand Surg. 2017 Feb;51(1):2-13. doi: 10.1080/2000656X.2016.1263202. Erratum in: J Plast Surg Hand Surg. 2017 Apr;51(2):158. PMID: 28218559.

Shao Y, Ma JM, Huang XM; Expert Workgroup of Guidelines for the use of imaging equipment in orbital diseases (2024); Ophthalmic Imaging and Intelligent Medicine Branch Chinese Medicine Education Association; Ocular Oncology Committee of the Ophthalmology Branch of the Chinese Medical Doctor Association; Ophthalmology Committee of International Association of Translational Medicine; Chinese Ophthalmic Imaging Study Groups. Guidelines for standard operation of imaging modalities in orbital diseases (2024). Int J Ophthalmol. 2025 Jan 18;18(1):51-66. doi: 10.18240/ijo.2025.01.06. PMID: 39829618; PMCID: PMC11672101.

Shetye PR, Evans CA. Midfacial morphology in adult unoperated complete unilateral cleft lip and palate patients. Angle Orthod. 2006 Sep;76(5):810-6. doi: 10.1043/0003-3219(2006)076[0810:MMIAUC]2.0.CO;2. PMID: 17029515.

Shippert RD. A Study of Time-Dependent Operating Room Fees and How to save $100 000 by Using Time-Saving Products. The American Journal of Cosmetic Surgery. 2005;22(1):25-34. doi:10.1177/074880680502200104

Shyu VB, Hsu CE, Chen CH, Chen CT. 3D-assisted quantitative assessment of orbital volume using an open-source software platform in a Taiwanese population. PLoS One. 2015 Mar 16;10(3):e0119589. doi: 10.1371/journal.pone.0119589. PMID: 25774683; PMCID: PMC4361687.

Sigron GR, Britschgi CL, Gahl B, Thieringer FM. Insights into Orbital Symmetry: A Comprehensive Retrospective Study of 372 Computed Tomography Scans. J Clin Med. 2024 Feb 12;13(4):1041. doi: 10.3390/jcm13041041. PMID: 38398354; PMCID: PMC10889405.

Sigron GR, Britschgi CL, Gahl B, Thieringer FM. Insights into Orbital Symmetry: A Comprehensive Retrospective Study of 372 Computed Tomography Scans. J Clin Med. 2024 Feb 12;13(4):1041. doi: 10.3390/jcm13041041. PMID: 38398354; PMCID: PMC10889405.

Sigron, G.R.; Britschgi, C.L.; Gahl, B.; Thieringer, F.M. Insights into Orbital Symmetry: A Comprehensive Retrospective Study of 372 Computed Tomography Scans. J. Clin. Med. 2024, 13, 1041. https://doi.org/10.3390/jcm13041041

Sigron, G.R.; Rüedi, N.; Chammartin, F.; Meyer, S.; Msallem, B.; Kunz, C.; Thieringer, F.M. Three-Dimensional Analysis of Isolated Orbital Floor Fractures Pre- and Post-Reconstruction with Standard Titanium Meshes and “Hybrid” Patient-Specific Implants. J. Clin. Med. 2020, 9, 1579. https://doi.org/10.3390/jcm9051579

Sillmann YM, Monteiro JLGC, Eber P, Baggio AMP, Peacock ZS, Guastaldi FPS. Empowering surgeons: will artificial intelligence change oral and maxillofacial surgery? Int J Oral Maxillofac Surg. 2025 Feb;54(2):179-190. doi: 10.1016/j.ijom.2024.09.004. Epub 2024 Sep 27. PMID: 39341693.

Singer R, Papadopoulos T. There Is no Universal Standard of Beauty. Aesthetic Plast Surg. 2024 Aug 5. doi: 10.1007/s00266-024-04266-w. Epub ahead of print. PMID: 39103640.

Singh AK, Khanal N, Chaulagain R, Sharma N, Thieringer FM. Is the Pre-Shaping of an Orbital Implant on a Patient-Specific 3D-Printed Model Advantageous Compared to Conventional Free-Hand Shaping? A Systematic Review and Meta-Analysis. J Clin Med. 2023 May 12;12(10):3426. doi: 10.3390/jcm12103426. PMID: 37240532; PMCID: PMC10219303.

Singh P, Bornstein MM, Hsung RT, Ajmera DH, Leung YY, Gu M. Frontiers in Three-Dimensional Surface Imaging Systems for 3D Face Acquisition in Craniofacial Research and Practice: An Updated Literature Review. Diagnostics (Basel). 2024 Feb 14;14(4):423. doi: 10.3390/diagnostics14040423. PMID: 38396462; PMCID: PMC10888365.

Sipilä, R., Mäkelä, M. & Komulainen, J. Highlighting the need for de-implementation – Choosing Wisely recommendations based on clinical practice guidelines. BMC Health Serv Res 19, 638 (2019). Doi:10.1186/s12913-019-4460-z

Sivam A, Enninghorst N. The Dilemma of Reconstructive Material Choice for Orbital Floor Fracture: A Narrative Review. Medicines (Basel). 2022 Jan 13;9(1):6. doi: 10.3390/medicines9010006. PMID: 35049939; PMCID: PMC8778999.

Sivam A, Enninghorst N. The Dilemma of Reconstructive Material Choice for Orbital Floor Fracture: A Narrative Review. Medicines (Basel). 2022 Jan 13;9(1):6. doi: 10.3390/medicines9010006. PMID: 35049939; PMCID: PMC8778999.

Smith, B.; William, F.; Regan, J. Blowout fracture of the orbit: Mechanism and correction of internal orbital fracture. Am. J. Ophthalmol. 1957

Som PM, Naidich TP. Illustrated review of the embryology and development of the facial region, part 1: Early face and lateral nasal cavities. AJNR Am J Neuroradiol. 2013 Dec;34(12):2233-40. doi: 10.3174/ajnr.A3415. Epub 2013 Mar 14. PMID: 23493891; PMCID: PMC7965203.

Som PM, Naidich TP. Illustrated review of the embryology and development of the facial region, part 2: Late development of the fetal face and changes in the face from the newborn to adulthood. AJNR Am J Neuroradiol. 2014 Jan;35(1):10-8.

doi: 10.3174/ajnr.A3414. Epub 2013 Mar 14. PMID: 23493895; PMCID: PMC7966493.

STM2019 http://urn.fi/URN:ISBN:978-952-00-4036-9 referred 17th January 2025

Stoor P, Mesimäki K, Lindqvist C, Kontio R. The use of anatomically drop-shaped bioactive glass S53P4 implants in the reconstruction of orbital floor fractures--A prospective long-term follow-up study. J Craniomaxillofac Surg. 2015 Jul;43(6):969-75. doi: 10.1016/j.jcms.2015.03.029. Epub 2015 Apr 2. PMID: 25957104.

Stoor P, Suomalainen A, Lindqvist C, Mesimäki K, Danielsson D, Westermark A, Kontio RK. Rapid prototyped patient specific implants for reconstruction of orbital wall defects. J Craniomaxillofac Surg. 2014 Dec;42(8):1644-9. doi: 10.1016/j.jcms.2014.05.006. Epub 2014 May 23. PMID: 25139812.

Stucki J, Dastgir R, Baur DA, Quereshy FA. The use of virtual reality and augmented reality in oral and maxillofacial surgery: A narrative review. Oral Surg Oral Med Oral Pathol Oral Radiol. 2024 Jan;137(1):12-18. doi: 10.1016/j.oooo.2023.07.001. Epub 2023 Jul 13. PMID: 37723007.

Suojanen J, Järvinen S, Hodzic Z, Reunanen J, Leikola J, Stoor P. No differences in infections between patient-specific implants and conventional mini-plates in mandibular bilateral sagittal split osteotomy - Up to 3-year follow-up. J Craniomaxillofac Surg. 2019 Aug;47(8):1181-1184. doi: 10.1016/j.jcms.2018.10.009. Epub 2018 Oct 20. PMID: 31178267.

Suojanen J, Järvinen S, Kotaniemi KV, Reunanen J, Palotie T, Stoor P, Leikola J. Comparison between patient specific implants and conventional mini-plates in Le Fort I osteotomy with regard to infections: No differences in up to 3-year follow-up. J Craniomaxillofac Surg. 2018 Oct;46(10):1814-1817. doi: 10.1016/j.jcms.2018.07.011. Epub 2018 Jul 23. PMID: 30097411.

Suojanen J, Leikola J, Stoor P. The use of patient-specific implants in orthognathic surgery: A series of 30 mandible sagittal split osteotomy patients. J Craniomaxillofac Surg. 2017 Jun;45(6):990-994. doi: 10.1016/j.jcms.2017.02.021. Epub 2017 Mar 3. PMID: 28381373.

Suuronen R. Biodegradable fracture-fixation devices in maxillofacial surgery. Int J Oral Maxillofac Surg. 1993 Feb;22(1):50-7. doi: 10.1016/s0901-5027(05)80358-3. PMID: 8384646.

Swennen GR, Mollemans W, Schutyser F. Three-dimensional treatment planning of orthognathic surgery in the era of virtual imaging. J Oral Maxillofac Surg. 2009 Oct;67(10):2080-92. doi: 10.1016/j.joms.2009.06.007. Erratum in: J Oral Maxillofac Surg. 2009 Dec;67(12):2703. PMID: 19761902.

Swennen GR. Timing of three-dimensional virtual treatment planning of orthognathic surgery: a prospective single-surgeon evaluation on 350 consecutive cases. Oral Maxillofac Surg Clin North Am. 2014 Nov;26(4):475-85. doi: 10.1016/j.coms.2014.08.001. Epub 2014 Sep 12. PMID: 25220754.

Swennen GRJ, Schutyser F, Hausamen J-E. Three-Dimensional Cephalometry. A Color Atlas and Manual. Springer 2006.

Taalab DA, Shehab AF, Atef M, Shehab MF. Comparative study between patient specific titanium plates versus conventional miniplates for treatment of mandibular fractures: Randomized clinical trial. J Craniomaxillofac Surg. 2023 Apr;51(4):217-223. doi: 10.1016/j.jcms.2023.01.015. Epub 2023 Jan 28. PMID: 37068986. Operation time lower in mand fr

Takashima S, Tateishi J, Taguchi Y, Inoue H. Creutzfeldt-Jakob disease with florid plaques after cadaveric dural graft in a Japanese woman. Lancet. 1997 Sep 20;350(9081):865-6. doi: 10.1016/S0140-6736(05)62035-1. PMID: 9310612.

Tampu IE, Eklund A, Haj-Hosseini N. Inflation of test accuracy due to data leakage in deep learning-based classification of OCT images. Sci Data. 2022 Sep 22;9(1):580. doi: 10.1038/s41597-022-01618-6. PMID: 36138025; PMCID: PMC9500039.

Tan JM, Macario A. How to evaluate whether a new technology in the operating room is cost-effective from society's viewpoint. Anesthesiol Clin. 2008 Dec;26(4):745-64, viii. doi: 10.1016/j.anclin.2008.07.003. PMID: 19041627.

Van der Wel H, Kraeima J, Spijkervet FKL, Schepers RH, Jansma J. Postoperative skeletal stability at the one-year follow-up after splintless Le Fort I osteotomy using patient-specific osteosynthesis versus conventional osteosynthesis: a randomized controlled trial. Int J Oral Maxillofac Surg. 2023 Jun;52(6):679-685. doi: 10.1016/j.ijom.2022.09.005. Epub 2022 Oct 4. PMID: 36202719.

Vannier MW, Marsh JL, Warren JO. Three dimensional CT reconstruction images for craniofacial surgical planning and evaluation. Radiology. 1984 Jan;150(1):179-84. doi: 10.1148/radiology.150.1.6689758. PMID: 6689758.

Verbist M, Vandevelde AL, Geusens J, Sun Y, Shaheen E, Willaert R. Reconstruction of Craniomaxillofacial Bone Defects with 3D-Printed Bioceramic Implants: Scoping Review and Clinical Case Series. J Clin Med. 2024 May 9;13(10):2805. doi: 10.3390/jcm13102805. PMID: 38792347; PMCID: PMC11122134.

Voshol IE, van der Wal KG, van Adrichem LN, Ongkosuwito EM, Koudstaal MJ. The frequency of Le Fort I osteotomy in cleft patients. Cleft Palate Craniofac J. 2012 Mar;49(2):160-6. doi: 10.1597/09-224. PMID: 21526976.

Voshol, I.; van der Wal, K.; van Adrichem, L.; Ongkosuwito, E.; Koudstaal, M. The Frequency of Le Fort I Osteotomy in Cleft Patients. Cleft Palate-Craniofacial J. 2012, 49, 160–166. [Google Scholar] [CrossRef]

Vyas KS, Suchyta MA, Hunt CH, Gibreel W, Mardini S. Black Bone MRI for Virtual Surgical Planning in Craniomaxillofacial Surgery. Semin Plast Surg. 2022 Dec 7;36(3):192-198. doi: 10.1055/s-0042-1756451. PMID: 36506277; PMCID: PMC9729059.

Walker ET, Lightfoot E, Walshaw EG, Taylor R, Douglas J, Carter LM, Parmar JD. Quantitative assessment of bony orbital volume symmetry: CT analysis in the uninjured caucasian population. Br J Oral Maxillofac Surg. 2022 Sep;60(7):945-950. doi: 10.1016/j.bjoms.2022.02.002. Epub 2022 Feb 17. PMID: 35307274.

Wang T, Wessels L, Hussain G, Merten S, Discriminative Thresholds in Facial Asymmetry: A Review of the Literature, Aesthetic Surgery Journal, Volume 37, Issue 4, 1 April 2017, Pages 375–385, https://doi.org/10.1093/asj/sjw271

Watters TS, Mather RC 3rd, Browne JA, Berend KR, Lombardi AV Jr, Bolognesi MP. Analysis of procedure-related costs and proposed benefits of using patient-specific approach in total knee arthroplasty. J Surg Orthop Adv. 2011 Summer;20(2):112-6. PMID: 21838072.

Werlinger F, Villalón M, Duarte V, Acevedo R, Aguilera R, Alcocer D, Badillo O, Briones R, Condal C, Del Río M, García R, Herrera M, Jaramillo J, Merchan F, Nasi M, Osbén R, Rivera A, Riviello S, Rojas P, Vidal C, Rodríguez G, Schild S, Arroyo E, Alvarado MJ, Sepúlveda P, Cortés J. Trends of maxillofacial trauma: An update from the prospective register of a multicenter study in emergency services of Chile. Med Oral Patol Oral Cir Bucal. 2019 Sep 1;24(5):e588-e594. doi: 10.4317/medoral.22985. PMID: 31433390; PMCID: PMC6764707.

Wiesinger F, Ho ML. Zero-TE MRI: principles and applications in the head and neck. Br J Radiol. 2022 Aug 1;95(1136):20220059. doi: 10.1259/bjr.20220059. Epub 2022 Jun 10. PMID: 35616709; PMCID: PMC10162052.

Winegar BA, Gutierrez JE. Imaging of Orbital Trauma and Emergent Non-traumatic Conditions. NEuroimaging Clin N Am. 2015 Aug;25(3):439-56. doi: 10.1016/j.nic.2015.05.007. PMID: 26208419.

Wlodarczyk JR, Munabi NCO, Wolfswinkel E, Nagengast E, Higuch EC, Turk M, Urata MM, Hammoudeh JA, Yao C, Magee W 3rd. Midface Growth Potential in Unoperated Clefts: A Systematic Review and Meta-Analysis. J Craniofac Surg. 2022 May 1;33(3):774-778. doi: 10.1097/SCS.0000000000008296. Epub 2021 Oct 21. PMID: 34690318.

Wolford LM, Cassano DS, Cottrell DA, El Deeb M, Karras SC, Goncalves JR. Orthognathic surgery in the young cleft patient: preliminary study on subsequent facial growth. J Oral Maxillofac Surg. 2008 Dec;66(12):2524-36. doi: 10.1016/j.joms.2008.06.104. PMID: 19022133.

Wong Riff KW, Tsangaris E, Goodacre T, Forrest CR, Pusic AL, Cano SJ, Klassen AF. International multiphase mixed methods study protocol to develop a cross-cultural patient-reported outcome instrument for children and young adults with cleft lip and/or palate (CLEFT-Q). BMJ Open. 2017 Jan 11;7(1):e015467. doi: 10.1136/bmjopen-2016-015467. PMID: 28077415; PMCID: PMC5253569.

Wusiman P, Maimaitituerxun B, Guli, Saimaiti A, Moming A. Epidemiology and Pattern of Oral and Maxillofacial Trauma. J Craniofac Surg. 2020 Jul-Aug;31(5):e517-e520. doi: 10.1097/SCS.0000000000006719. PMID: 32569059.

www.choosingwisely.org Choosing Wisely: An Initiative of the ABIM Foundation Accessed 08 August 2024

Yang E, Chan SC, Al-Omari Y, Ward L, Yap TE, Jhass A, Pancholi R, Aziz A, Bentley CR, Perry M, Lee V. A Functional Radiological and Soft Tissue Classification to Predict Outcomes in Orbital Fracture Surgery in a Multidisciplinary "Real-World" Setting. Front Surg. 2021 Jul 27;8:693607. doi: 10.3389/fsurg.2021.693607. PMID: 34386516; PMCID: PMC8353087.

Young SM, Kim YD, Kim SW, Jo HB, Lang SS, Cho K, Woo KI. Conservatively Treated Orbital Blowout Fractures: Spontaneous Radiologic Improvement. Ophthalmology. 2018 Jun;125(6):938-944. doi: 10.1016/j.ophtha.2017.12.015. Epub 2018 Feb 3. PMID: 29398084.

Young SM, Sundar G, Lim TC, Lang SS, Thomas G, Amrith S. Use of bioresorbable implants for orbital fracture reconstruction. Br J Ophthalmol. 2017 Aug;101(8):1080-1085. doi: 10.1136/bjophthalmol-2016-309330. Epub 2016 Dec 2. PMID: 27913446.

Zheng R, Ren D, Xie C, Pan J, Zhou G. Normality mediates the effect of symmetry on facial attractiveness. Acta Psychol (Amst). 2021 Jun;217:103311. doi: 10.1016/j.actpsy.2021.103311. Epub 2021 Apr 29. PMID: 33933836.

Zieliński R, Malińska M, Kozakiewicz M. Classical versus custom orbital wall reconstruction: selected factors regarding surgery and hospitalization. J Craniomaxillofac Surg 2017; 45:710–715.

Zong CL, Shi YL, Jia JQ, Ding MC, Chang SP, Lu JB, Chen YL, Tian L. A retrospective study to compare the treatment outcomes with and without surgical navigation for fracture of the orbital wall. Chin J Traumatol. 2021 Feb;24(1):11-17. doi: 10.1016/j.cjtee.2020.10.002. Epub 2020 Nov 17. PMID: 33246880; PMCID: PMC7878449.